

OXFORD Medical Publications

OXFORD

LOOSE-LEAF

SURGERY

OXFORD

LOOSE-LEAF

SURGERY

BY VARIOUS AUTHORS

EDITED BY

F. F. BURGHARD, AND ALLEN B. KANAVEL

M.S. (LOND.), F.R.C.S. (ENG.), COLONEL, A.M.S.

LECTURER ON SURGERY AND SURGEON TO KING'S COLLEGE HOSPITAL, CONSULTING SURGEON TO THE CHILDREN'S HOSPITAL, PADDINGTON GREEN, LONDON, ENG.

A.B., M.D., LIEUT. COL. M.C., N.A.

ASSOCIATE PROFESSOR OF SURGERY NORTHWESTERN UNIVERSITY MEDICAL SCHOOL, ATTENDING SURGEON WESLEY AND COOK COUNTY HOSPITALS, CHICAGO, ILL.

IN FIVE VOLUMES

OVER 1800 ILLUSTRATIONS

VOL. IV

NEW YORK

OXFORD UNIVERSITY PRESS

AMERICAN BRANCH: 35 WEST 32ND STREET

LONDON, TORONTO, MELBOURNE, AND BOMBAY

1918

W.C
100

COPYRIGHT, 1918
BY
OXFORD UNIVERSITY PRESS
AMERICAN BRANCH

THE QUINN & BODEN CO. PRESS
RAHWAY, N. J.

PREFACE

SURGERY is no longer "a mere mechanic art." Out of the old surgery which placed so great a stress upon technique a new surgery is being evolved, a new conception is being formed, the application of which belongs to no passing event, the future of which no one can prophesy.

Functional surgery, if one may use the term, belongs to all the future. Take, for example, abdominal diagnosis, where the mechanism of pain is a question of vast complexity, and the evaluation so essential to diagnosis. Again, the latter-day investigation of anæsthesia opens a new field and warns the surgeon that every function of the nervous system must be given detailed consideration. The study of antiseptics has linked Ehrlich's conception of chemical action with the daily technique of the operating room and extended the domain of bacteriology in the scientific treatment of wounds. It is such advances as these that we have attempted to incorporate with the portrayal of the technique of various surgical clinics. The foundation was found in Burghard's Surgery, whose various contributors in collaboration with the editors have added proved procedures from American clinics and revised the various chapters in the light of the developments in surgical practice produced by experience in war.

The loose-leaf form of the Oxford Surgery will permit the editors to present the future changes in British surgery and incorporate the best thought of the leading American clinics.

The originality and individuality obtained in these volumes will be sought rather than a colourless enumeration of operative procedures. Categorical enumeration of operations of historical interest only and procedures not demonstrated by actual experience to be of value will be avoided.

The editors wish to express to the various contributors and to those whose contributions are being prepared for future insertions the appreciation of the surgeons of America and Great Britain for their unstinted and unselfish labour during a time when they are so occupied by duties necessitated by the exigencies of war.

F. F. BURGHARD.
ALLEN B. KANAVEL.

CONTRIBUTORS TO THIS VOLUME

F. F. BURGHARD, M.S. (Lond.), F.R.C.S. (Eng.)
Colonel A.M.S. Surgeon to King's College Hospital; Consulting Surgeon to the Children's Hospital, Paddington Green.

Operations upon the Male Genital Organs

HAROLD J. STILES, M.B., F.R.C.S. (Edin.)
Lieutenant-Colonel R.A.M.C.(T.). Surgeon to Chalmers Hospital, Edinburgh, and to the Royal Hospital for Sick Children, Edinburgh.

Operations upon the Breast

W. SAMPSON HANDLEY, M.D., M.B., F.R.C.S.
Captain R.A.M.C.(T.). Hunterian Professor of Surgery and Pathology in the Royal College of Surgeons of England; Surgeon to Putney Hospital.

Malignant Disease of the Breast

SIR RICKMAN GODLEE, Bart., M.S. (Lond.), F.R.C.S. (Eng.)
Senior Surgeon to University College Hospital; Consulting Surgeon to the Hospital for Consumption, Brompton.

Operations on the Thoracic Wall and its Contents

M. S. MAYOU, F.R.C.S. (Eng.)
Surgeon to the Central London Ophthalmic Hospital; Ophthalmic Surgeon to the Bolingbroke Hospital.

Ophthalmic Operations

HUNTER F. TOD, M.A., M.D. (Cantab.), F.R.C.S. (Eng.)
Aural Surgeon to the London Hospital.

Operations upon the Ear

W. DOUGLAS HARMER, M.D., (Cantab.), F.R.C.S. (Eng.)
Surgeon to the Throat and Nose Department, St. Bartholomew's Hospital.

Operations upon the Larynx and Trachea

SIR StCLAIR THOMSON, M.D., F.R.C.P. (Lond.), F.R.C.S. (Eng.)
Professor of Laryngology and Physician for Diseases of the Throat, King's College Hospital, London.

Operations upon the Throat and its Accessory Cavities

CONTENTS

SECTION I

OPERATIONS UPON THE MALE GENITAL ORGANS

By F. F. BURGHARD, M.S. (Lond.), F.R.C.S. (Eng.), Colonel A.M.S.
Surgeon to King's College Hospital; Consulting Surgeon to the Children's Hospital, Paddington Green

CHAPTER I

OPERATIONS UPON THE PENIS

PAGES

Operations for Hypospadias, 3; *Formation of a New Urethra in the Glans Penis,* 4; *Formation of a New Penile Urethra,* 8. Operations for Epispadias, 14. Circumcision, 16. Amputation of the Penis, 19, *Partial,* 21; *Complete,* 25 3–29

CHAPTER II

OPERATIONS UPON THE SCROTUM AND CORD

The Radical Cure of Hydrocele, 30. Operations for Varicocele, 33. Operations upon the Vas Deferens: *Vasectomy,* 35; *Vasorrhaphy,* 35 30–37

CHAPTER III

OPERATIONS UPON THE TESTICLE

Orchidopexy, 38. Epididymectomy, 45. Castration, 48. Epididymitis, 50. Seminal Vesicles, 51. Vesiculectomy, 52 38–57

SECTION II

OPERATIONS UPON THE THORAX AND ITS CONTENTS

PART I

OPERATIONS UPON THE BREAST

By HAROLD J. STILES, M.B., F.R.C.S. (Edin.), Lieutenant-Colonel R.A.M.C.(T.)

Surgeon to Chalmers Hospital, Edinburgh, and to the Royal Hospital for Sick Children, Edinburgh

CHAPTER I

OPERATIONS UPON THE BREAST

PAGES

Operations for Carcinoma, 61. Modifications of or Additions to the Operation, 86, *for Ulcerating or Fungating Carcinomas,* 86; *for Extensive Disease in the Axilla,* 86; *Removal of the Supraclavicular Glands,* 87. Dangers, 89. Prognosis as regards Permanent Recovery, 89. Excision of the Mamma without opening the Axilla, 91. Partial Resection of the Mamma, 95. Plastic Restoration of the Breast, 97. Operations for Acute Abscess of the Mamma, 99 . 61–100

CHAPTER II

MALIGNANT DISEASE OF THE BREAST

By W. SAMPSON HANDLEY, M.D., M.B., F.R.C.S., Captain R.A.M.C.(T.)

Hunterian Professor of Surgery and Pathology in the Royal College of Surgeons of England. Surgeon to the Putney Hospital

Etiology, 101. Clinical Classification of Breast Cancer, 101. Permeation and Infiltration Contrasted, 103. The First Sign noted by the Patient, 105. Diagnosis, 107. Principles of the Operation for Breast Cancer, 112. Post-operative Treatment, 114. Causes of Death, 114. Radium Treatment, 115. Open-air and Drug Treatment, 115. Sarcoma of the Breast, 116 101–117

PART II

OPERATIONS UPON THE THORACIC WALL AND ITS CONTENTS

By SIR RICKMAN GODLEE, Bart., M.S. (Lond.), F.R.C.S. (Eng.)

Senior Surgeon to University College Hospital; Consulting Surgeon to the Hospital for Consumption, Brompton

CHAPTER III

OPERATIONS UPON THE THORACIC WALL AND THE MEDIASTINA

PAGES

Operations for Injuries of the Chest: *for Surgical Emphysema*, 121; *for Wounds of the Lung and the Great Vessels*, 121; *for Hernia of the Lung*, 122. Operations for Caries and Necrosis of the Bony Walls of the Thorax, 122. Removal of Tumours of the Chest-wall, 124. Operations for Mediastinal Abscess, 126 121–126

CHAPTER IV

OPERATIONS FOR THE REMOVAL OF FLUIDS FROM THE PLEURAL CAVITIES

Exploration of the Chest, 127. Low-pressure and High-pressure Operations, 129. Intratracheal Anæsthesia, 133. Operations for Serous Effusions, 136. Operations for Empyema, 138. Thoracoplasty, 147. Operations for Chylothorax, 157 127–157

CHAPTER V

OPERATIONS UPON THE LUNGS

Operation for Abscess of the Lung, 158. Operations for Bronchiectasis, 160. Operation for Tuberculous Abscesses, 162. Removal of Foreign Bodies in the Lung, 163. Operation for Actinomycosis of the Lungs, 166. Operation for Hydatid Disease of the Lung and Thorax, 167. Operation for Dermoids of the Interior of the Thorax, 167. Removal of Tumours of the Lung and Mediastinum, 169. Removal of Tumours of the Mediastinum, 170 158–170

CHAPTER VI

OPERATIONS UPON THE PERICARDIUM, THE HEART, AND THE PULMONARY ARTERY

The Repair of Wounds of the Pericardium and Heart, 171. Paracentesis and Opening of the Pericardium, 178. Cardiolysis, 180. Removal of Clots from the Pulmonary Artery, 181 171–183

CHAPTER VII

OPERATIONS UPON THE DIAPHRAGM AND FOR SUBDIAPHRAGMATIC AND HEPATIC ABSCESS

PAGES

Repair of Injuries of the Diaphragm, 184. Operation for Subdiaphragmatic Abscess, 185. Operation for Abscess of the Liver, 189 . . 184–192

SECTION III

OPHTHALMIC OPERATIONS

By M. S. MAYOU, F.R.C.S. (Eng.)

Surgeon to the Central London Ophthalmic Hospital; Ophthalmic Surgeon to the Bolingbroke Hospital

CHAPTER I

GENERAL CONSIDERATIONS APPLICABLE TO OPERATIONS UPON THE EYE

General Preliminaries to an Operation, 195. Local Preparation of the Patient, 199. Making and Healing of Wounds in the Globe, 201—*Purification of Hands*, 201; *of Instruments*, 201; *Direction of Incision*, 202; *Position of Incision*, 202; *Dressings*, 204; *Bandaging*, 204 195–205

CHAPTER II

OPERATIONS UPON THE LENS

Surgical Anatomy, 206. Discission or Needling, 208—*for Cataract*, 208; *for High Myopia*, 209. Capsulotomy, 211. Evacuation, 213. Evulsion of the Capsule, 214. Extraction of the Lens, 214. Modifications, 220; *Delivery of the Lens by Irrigation*, 223; *Extraction of the Lens in its Capsule*, 223; *Subconjunctival Extraction*, 225. Couching, 230 206–231

CHAPTER III

OPERATIONS UPON THE IRIS

Iridotomy, 232. Alternative Methods—*Kuhnt's Operation*, 233; *Ziegler's*, 234. Iridectomy—Optical Iridectomy, 235; Glaucoma Iridectomy, 238—for small Growths of the Iris, 246; for Prolapse of the Iris, 247. Transfixion of the Iris, 247. Division of Anterior Synechiæ, 248 232–248

CHAPTER IV

OPERATIONS UPON THE SCLEROTIC

PAGES

Anterior Sclerotomy, 249. Sclerectomy, 250. Posterior Sclerotomy, 254. Formation of new Lymph Paths by Silk Thread Drains, 255. Paracentesis of the Anterior Chamber, 257. For Penetrating Wounds of the Globe, 258. Electro-magnet Operations—*with Small Magnet*, 261; *with Giant Magnet*, 263 249–263

CHAPTER V

OPERATIONS UPON THE CORNEA AND CONJUNCTIVA

Removal of a Foreign Body from the Cornea, 264. Cauterization of the Cornea, 264. Operations for Conical Cornea, 265. Removal of Tumours involving the Cornea, 267. Tattooing the Cornea, 267. Scraping Calcareous Films, 267. Operations upon the Conjunctiva —*Removal of Foreign Bodies*, 268; *for Pterygium*, 268; *Expression*, 269; *Conjunctivoplasty*, 269; *Removal of Tarsal Cysts*, 270 . . 264–270

CHAPTER VI

OPERATIONS UPON THE EXTRA-OCULAR MUSCLES

Squint Operations, 271. Tenotomy, 272. Advancement, 275 . . 271–278

CHAPTER VII

ENUCLEATION OF THE GLOBE AND ALLIED OPERATIONS

Enucleation, 279; Evisceration, 281. Mules's Operation, 283. Frost's Operation, 283. Operations upon the Socket after Removal of the Eye—*Paraffin Injection*, 284. Operations for Restoration of a Contracted Socket—*Skin-grafting*, 285; *Inclusion of Flaps* (*Maxwell's Operation*), 285 279–286

CHAPTER VIII

OPERATIONS UPON THE EYELIDS

Surgical Anatomy, 287. Suture of Wounds of the Eyelids, 287. Operations for Ankyloblepharon, 288; for Symblepharon, 288. Upon the Palpebral Aperture, 289—*Canthoplasty*, 289; *Canthotomy*, 289; *Canthorrhaphy*, 289; *Tarsorrhaphy*, 290; Ptosis Operations, 291; *Shortening the Eyelid by Excision of a portion of the Tarsal Plate*, 291. *Attachment of the Lid to the Occipito-frontalis Muscle*, 292. Advancement of the Levator Palpebræ Muscle, 296. Grafting a portion of the Superior Rectus into the Lid, 297 . . . 287–298

CHAPTER IX

OPERATIONS FOR ENTROPION, REPAIR OF THE EYELIDS, TRICHIASIS, AND ECTROPION

PAGES

Electrolysis, 299. Skin and Muscle Operation, 299. Rectification of a Faulty Curvature of the Tarsus—*Burow's Operation*, 300; *Streatfeild's Operation*, 300. Transplantation of the Lash-bearing Area—Arlt's Operation, 302. Ectropion Operations, 303—for Passive Ectropion, 304; *Snellen's Suture Method*, 304; *Fergus's Operation*, 304; *Kuhnt's Operation*, 305; *Argyll Robertson's Operation*, 306. For the Active or Cicatricial Form, 307; *V-Y Operation*, 308; *Denonvillier's Operation*, 308; *Fricke's Operation*, 309; *Thiersch's Skin-grafting*, 311. Repair of large Losses of Substance from the Eyelids, 311; *De Vincentiis' Operation*, 311; *Dieffenbach's Operation*, 312 299–313

CHAPTER X

OPERATIONS UPON THE LACRIMAL APPARATUS

For the Relief of Lacrimal Obstruction, 314—*Dilatation of the Canaliculus*, 314; *Slitting the Canaliculus*, 315; *Syringing the Lacrimal Duct*, 316; *Probing the Lacrimal Duct*, 316; *the Insertion of Styles*, 317. For Obliteration of the Canals, 318; *Obliteration of the Canaliculi*, 318; *Excision of the Lacrimal Sac*, 318. Opening a Lacrimal Abscess, 321; Operations upon the Lacrimal Gland—*Removal of the Palpebral Portion*, 322; *Removal of the Orbital Portion*, 323. Operations upon the Orbit—Exploration of the Orbit (Krönlein's Method), 323; Evisceration of the Orbit, 325; Opening an Orbital Abscess, 325 314–325

SECTION IV

OPERATIONS UPON THE EAR

By HUNTER F. TOD, M.A., M.D. (Cantab.), F.R.C.S. (Eng.)

Aural Surgeon to the London Hospital

CHAPTER I

EXAMINATION OF THE EAR: GENERAL CONSIDERATIONS WITH REGARD TO OPERATIONS

Examination of the Ear, 329—*Sources of Illumination*, 329; *Technique of Examination*, 330; *Method of cleansing the Ear*, 331. General Considerations with regard to Operations—*Preliminary Surgical Toilet*, 333; *Anæsthesia*, 334. Position of Patient and Surgeon, 337 329–337

CHAPTER II

OPERATIONS UPON THE EXTERNAL AUDITORY CANAL

PAGES

Operations for Furunculosis, 338. Removal of Exostoses from the External Meatus, 340. Removal of Foreign Bodies—*by Syringing*, 346; *by Instruments*, 347; *by Post-aural Incision*, 350; *by Operation upon the Mastoid*, 351. Operations for Stenosis of the External Meatus, 352. Operations for Atresia, 354; for Aural Polypus, 355 338–358

CHAPTER III

OPERATIONS UPON THE TYMPANIC MEMBRANE AND WITHIN THE TYMPANIC CAVITY

Surgical Anatomy of the Tympanum, 359. Paracentesis, 360. Artificial Perforation of the Tympanic Membrane, 364. Division of the Anterior Ligament, 365. Division of the Posterior Fold, 365. Intratympanic Operations, 366; *Division of Adhesions*, 366; *Tenotomy of the Tensor Tympani*, 370; *Tenotomy of the Stapedius*, 371. Removal of Granulations from the Tympanic Cavity, 372. Operations upon the Ossicles—*Direct Mobilization*, 373; *Removal of the Ossicles*, 375. Removal of the Stapes, 385 359–387

CHAPTER IV

OPERATIONS UPON THE EUSTACHIAN TUBE

Catheterization, 388. Passing of the Eustachian Bougie, 394. Washing out the Tympanic Cavity through the Eustachian Tube, 396 . 388–397

CHAPTER V

OPERATIONS UPON THE MASTOID PROCESS: WILDE'S INCISION AND SCHWARTZE'S OPERATION

Surgical Anatomy, 398. History of the Mastoid Operation, 400. Wilde's Incision, 402. Schwartze's Operation, 403. Treatment of Special Conditions—*in an Infant*, 414; *Sub-periosteal Abscess*, 414; *Bezold's Mastoid Abscess*, 414; *Necrosis*, 415; *Osteomyelitis*, 415 . 398–415

CHAPTER VI

THE COMPLETE MASTOID OPERATION

Methods of Operation, 417; *Küster-Bergmann (Schwartze-Stacke) Operation*, 418; *Wolf's Operation*, 422; *Stacke's Operation*, 423; *Preservation of the Ossicles and Tympanic Membrane*, 424. The Formation of Post-meatal Skin Flaps, 426. Closure of the Wound.

PAGES

429. Skin-grafting after the Mastoid Operation, 430. After-treatment of the Case, 436. Difficulties and Dangers of the Operation, 438. Results, 440 416–442

CHAPTER VII

OPERATIONS UPON THE LABYRINTH

General Considerations, 443. Indications, 447. Surgical Anatomy, 449. Methods of Operating, 449; *Curetting a Localized Lesion of Wall*, 450; *Opening the Vestibule*, 451; *Inferior Vestibulotomy*, 452; *Extirpation of the Labyrinth*, 453. Intracranial Division of the Acoustic Nerve, 458 443–459

CHAPTER VIII

OPERATIONS FOR EXTRA-DURAL ABSCESS AND MENINGITIS OF OTITIC ORIGIN

On Intracranial Complications in General, 460. Operations for Extra-dural Abscess, 461. Operations for Meningitis of Otitic Origin, 464. Technique of Haynes's Operation, 471 460–473

CHAPTER IX

OPERATIONS FOR TRANSVERSE SINUS THROMBOSIS OF OTITIC ORIGIN

General Considerations, 474. Exposure of the Transverse Sinus, 477. Opening of the Transverse Sinus, 478. Ligature of the Jugular Vein, 482. Exposure of the Jugular Bulb, 490 474–496

CHAPTER X

OPERATIONS FOR INTRACRANIAL ABSCESS OF OTITIC ORIGIN

Indications, 497. Operation, 499. After-treatment, 507. Complications, 508. Prognosis and Subsequent Progress, 508. Recurrence of Symptoms, 509 497–510

SECTION V

OPERATIONS UPON THE LARYNX AND TRACHEA

By W. DOUGLAS HARMER, M.C. (Cantab.), F.R.C.S. (Eng.)
Captain R.A.M.C.(T.)
Surgeon to the Throat and Nose Department, St. Bartholomew's Hospital.

CHAPTER I

ENDOLARYNGEAL OPERATIONS

PAGES

Indications, 513. Operation by Indirect Laryngoscopy, 515. Operation by Direct Laryngoscopy, 517 513–524

CHAPTER II

EXTRA-LARYNGEAL OPERATIONS

Thyrotomy, 525. Hemi-laryngectomy, 533. Anatomy of the Laryngeal Lymphatics, 534. Total Laryngectomy, 536. Comparative Results of Extra-laryngeal Operations, 540. Thyrotomy, 542. Hemi-laryngectomy, 544. Total laryngectomy, 544. Infrathyreoid Laryngotomy, 548 525–555

CHAPTER III

OPERATIONS UPON THE TRACHEA

Tracheotomy, 556; *in Diphtheria,* 565; *in Conditions other than Diphtheria,* 583. Tracheo-fissure and Resection of the Trachea, 585 . 556–587

CHAPTER IV

INTUBATION OF THE LARYNX

Intubation *v.* Tracheotomy in Diphtheria, 588. Indications, 591. Operation, 592. Difficulties, 594. After-treatment, 595. Complications, 597 588–597

CHAPTER V

TRACHEOSCOPY AND BRONCHOSCOPY

Indications, 598. Tracheoscopy, 600. Upper Bronchoscopy, 602. Lower Bronchoscopy, 603. Complications, 603. Results, 606 . . . 598–606

SECTION VI

OPERATIONS UPON THE NOSE AND ITS ACCESSORY CAVITIES

By Sir StCLAIR THOMSON, M.D., F.R.C.P. (Lond.), F.R.C.S. (Eng.)
Professor of Laryngology and Physician for Diseases of the Throat, King's College Hospital, London

CHAPTER I

GENERAL CONSIDERATIONS IN REGARD TO OPERATIONS UPON THE NOSE AND NASO-PHARYNX

PAGES

Sources of Illumination, 609. Local Anæsthesia, 612. Local Ischæmia, 613. Bleeding and its Control, 614. The Protection of the Lower Air-passages from the Descent of Blood, 616. Shock, 617. Sepsis and other Complications, 618. Asepsis, 618. After-treatment, 619. Cleansing the Nose, 619. After-results, 620 609–620

CHAPTER II

OPERATIONS FOR INJURIES, DEFORMITIES, FOREIGN BODIES, AND RHINOLITHS: OPERATIONS UPON THE CONCHÆ (TURBINALS): OPERATIONS IN SYPHILIS AND LUPUS

Operations for Injuries to the Nose—Fractures of the Nasal Bones and Septum, 621. For Congenital Occlusion of the Nostrils, 622. Removal of Foreign Bodies, 624; of Rhinoliths, 626. Operations upon the Conchæ, 626; *upon the Inferior Concha*, 627; *upon the Middle Concha*, 632. For the Results of Syphilis—*Sequestrotomy*, 634; *Post-syphilitic Adhesions of the Velum*, 635. For Tuberculosis, 636 621–636

CHAPTER III

OPERATIONS UPON THE NASAL SEPTUM

For Deformities—*Removal of Spurs*, 637; *Perforating the Septum*, 638. For Simple Deviation, 638; *Gleason-Watson Operation*, 639; *Asch's Operation*, 639; *Moure's Operation*, 639. For Combined Bony and Cartilaginous Deformity—Submucous Resection, 641. Complementary Operations, 650. For Perforation of the Nasal Septum, 651. For Abscess, 653. For Hæmatoma, 653 637–653

CHAPTER IV

OPERATIONS FOR REMOVAL OF NASAL GROWTHS THROUGH THE NOSTRILS: OPERATIONS FOR OBTAINING DIRECT ACCESS TO THE NASAL CAVITIES AND NASO-PHARYNX

PAGES

Removal by the Snare, 654. Removal by Forceps and Curettes, 656. Lateral Rhinotomy (Moure's Operation), 659. Rouge's Operation, 663. Combination of Moure's and Rouge's Operations, 666. Extension of Rouge's Operation to allow of Access to the Maxillary Antrum, 666. Other Methods, 666 654–666

CHAPTER V

OPERATIONS UPON THE ACCESSORY NASAL SINUSES

Operations upon the Maxillary Sinus—*Catheterizing the Maxillary Sinus*, 667. *Puncturing from the Nose*, 667; *from the Alveolar Margin*, 669. *Operation through the Canine Fossa only*, 672; *the Caldwell-Luc Radical Operation*, 672; *Drainage through the Nasal Wall only*, 678. Operations upon the Frontal Sinus—*Catheterizing and Washing out the Frontal Sinus*, 679; *Opening the Frontal Sinus in Acute Suppuration*, 683; *Killian's Operation*, 683; *the Ogston-Luc Operation*, 692; *Kuhnt's Operation*, 694. Operations upon the Sphenoidal Sinus, 694; *Sounding and Washing out*, 694; *Opening the Sphenoidal Sinus*, 697. Operation in Multiple Sinus Suppuration, 700 667–701

CHAPTER VI

OPERATIONS INVOLVING THE NASAL PART OF THE PHARYNX: OPERATIONS FOR RETROPHARYNGEAL ABSCESS: OPERATIONS FOR ADENOIDS

Methods of obtaining Access to the Nasal Part of the Pharynx through the Nose, 702; through the Mouth, 703. Retropharyngeal Abscess, 705. Removal of Adenoids, 706 702–713

LIST OF ILLUSTRATIONS

FIG.		PAGE
1.	Repairing the Penile Urethra by means of the Prepuce	5
2.	Repairing the Penile Urethra by means of a Penile Flap	7
3.	Duplay's Operation for Hypospadias	9
4.	Bucknall's Operation for Hypospadias. *The incisions*	10
5.	Bucknall's Operation for Hypospadias. *The penis secured to the scrotum*	11
6.	Bucknall's Operation for Hypospadias. *The arrangement of the sutures*	12
7.	Bucknall's Operation for Hypospadias. *Final stage*	13
8.	Formation of the Urethra in Cases of Epispadias	15
9.	Paring away the Prepuce in Circumcision	18
10.	The Superficial and Deep Inguinal Lymph Glands	20
11.	Amputation of the Penis. *Transfixing the penis*	22
12.	Amputation of the Penis. *The stump*	23
13.	Amputation of the Penis. *The flap in position*	24
14.	The Parts concerned in Amputation of the Penis. *Superficial layer*	26
15.	The Parts concerned in Amputation of the Penis. *Deep layer*	26
16.	Complete Removal of the Penis. *First stage*	27
17.	Complete Removal of the Penis. *Second stage*	28
18.	Complete Removal of the Penis. *Third stage*	29
19.	Complete Removal of the Penis. *Final stage*	29
20.	Excision of the Tunica Vaginalis for the Radical Cure of Hydrocele	32
21.	Anastomosis of the Vas Deferens	36
22.	Cheyne's Testicle Frame	42
22-A.	Operation for Undescended Testicle	43
22-B.	Operation for Undescended Testicle	44
23.	Dissection of the Front of the Chest and Axilla to show the Relation of the Quadrants of the Breast to the Subjacent Muscles	62
24.	Incision for the Complete Operation for a Carcinoma occupying the Upper Outer Quadrant of the Breast	71
25.	The Complete Operation for Carcinoma of the Mamma. *Reflection of the flaps*	72
26.	Further Stage of the Complete Operation for Carcinoma of the Mamma. *Division of the pectoralis major*	74
27.	Further Stage of the Complete Operation for Carcinoma of the Mamma. *Exposure of the Axilla*	75
28.	Further Stage of the Complete Operation for Carcinoma of the Mamma. *Division of the pectoralis major*	76
29.	Further Stage of the Complete Operation for Carcinoma of the Mamma. *Clearing the axilla*	77
30.	Further Stage of the Complete Operation for Carcinoma of the Mamma. *The axilla cleared*	78
31.	Cicatrix left after Complete Operation for Cancer of the Mamma	82

FIG. PAGE

32. Incisions for Removal of Part or the Whole of the Breast . . . 93
32-A. Photograph of Patient after Restoration of Breast by Fat Transplant 97
32-B. Steps of Operation in the Transplantation of Fat in the Restoration of the Breast 98
33. Exploring Trochars 128
34. Aspirator Trochars 128
35. Sauerbruch's Chamber 130
36. Brauer's High-pressure Apparatus 131
36-A. Apparatus for Intratracheal Insufflation 134
37. A Simple Siphon Arrangement 137
38. Periosteum Elevator suitable for clearing the Rib 140
39. Vertical Incision for Empyema 141
40. Second Stage of the Operation for Empyema 142
41. Flanged Tube 143
42. Mr. Bilton Pollard's Empyema Tube 144
43. Front and Back Views of an Old Empyema 148
44. Completed Thoracoplasty on the Patient shown in Fig. 43 . . . 149
44-A. Chronic Empyema 151
44-B. Muscle Implantation Operation, Second Step 152
44-C. Muscle Implantation Operation, Third Step 153
44-D. Muscle Implantation Operation, Fourth Step 154
44-E. Muscle Implantation Operation, Fifth Step 155
45. Much-branched Bronchiectasis, unfavourable for Operation . . 160
46. Large Cavity resulting from Bronchiectasis, favourable for Operation . 161
47. Lateral and Back Views of a Boy whose Bronchiectatic Cavity was cured by Operation 161
48. Dermoid Cyst of the Mediastinum after Eleven Operations . . 168
49. A Wound of the Heart which passed through the Ventricular Wall without entering the Ventricle 171
50. An Extensive Rent in the Right Ventricle caused by a Crush . . 172
51. A Wound of the Heart caused by a Blow from the Fist . . . 173
52. Wound of the Heart following a Fall 174
53. Dissection to illustrate the Operation for dealing with Wounds of the Heart 175
54. Dissection shown in Fig. 53 completed 176
55. Parts in contact with the Sternum and Costal Cartilages viewed from behind 179
56. Dissection to explain Trendelenburg's Operation for removing Clots from the Pulmonary Artery 182
57. Window of the Operating Theatre, King's College Hospital . . 196
58. A Nernst Projection Lamp 197
59. Lang's Eye Speculum 200
60. Undine for washing out the Conjunctival Sac 201
61. Cataract Extraction 202
62. Sympathetic Ophthalmia 203
63. Cystoid Scar after Iridectomy for Glaucoma 203
64. An Eye Bandage 204
65. A Pressure Bandage 204
66. A Lens three weeks after Needling 206

FIG. PAGE
67. Anatomy of the Anterior Segment of the Eye 207
68. Eye Speculum 209
69. Fixation Forceps 209
70. Secondary Cataract 211
71. Capsulotomy. *The method of incising the capsule* 212
72. Capsulotomy. *The method of dividing a dense band* 212
73. Iris Forceps 215
74. Iris Scissors 215
75. A Vectis 215
76. Pagenstecher's Spoon 215
77. Lens Extraction 216
78. The Knife entering the Anterior Chamber in Cataract Extraction . 217
79. Making the Counter-puncture in Cataract Extraction 217
80. Incision and Iridectomy in Cataract Extraction 218
81. Opening the Capsule with Forceps in Cataract Extraction . . . 219
82. Cataract Extraction. *Replacing the Iris* 220
83. Cataract Extraction. *The method of button-holing the Iris* . . 221
84. McKeown's Irrigation Apparatus for washing out the Anterior Chamber 222
85. Subconjunctival Extraction 225
86. Iridotomy 233
87. Iridotomy 233
88. Iridotomy by Ziegler's Method 234
89. Iridotomy by Ziegler's Method 235
90. Iridotomy by Ziegler's Method 235
91. Optical Iridectomy 236
92. Optical Iridectomy 237
93. Optical Iridectomy 238
94. The Normal Angle of the Anterior Chamber 239
95. The Angle of the Anterior Chamber from a Case of Recent Glaucoma . 240
96. The Angle of the Chamber in a Case of Chronic Glaucoma . . . 241
97. Iridectomy for Glaucoma 242
98. Iridectomy for Glaucoma 243
99. Iridectomy for Glaucoma 243
100. Iridectomy for Glaucoma 244
101. Iridectomy for Glaucoma 245
102. Prolapse of the Iris through a Punctured Wound of the Cornea . . 247
103. Elliott's Trephine 250
104. Trephining the Sclera. *Showing the position of the trephine opening* . 251
105. Trephining the Sclera. *Showing the tissue removed* 251
106. Lagrange's Operation for the Production of a Cystoid Scar in Chronic Glaucoma 253
107. Lagrange's Operation for Chronic Glaucoma 253
108. Insertion of a Silk Drain into the Subretinal Space 257
109. Hollow Needle used for Paracentesis of the Anterior Chamber . . 258
110. Author's Chair for the Localisation of Foreign Bodies in the Eye by the X-rays 260
111. Small Electro-magnet for extracting Pieces of Steel from the Eye . 262
112. Giant Electro-magnet 263
113. Electro-cautery 265

FIG. PAGE
114. Tattooing Needles 267
115. Graddy's Forceps 269
116. Tenotomy 273
117. Tenotomy by the Open Method 274
118. Prince's Forceps for Advancement 276
119. Advancement by the Three-stitch Method 277
120. Enucleation 280
121. Mules's Operation. *First step* 282
122. Mules's Operation 282
123. Maxwell's Operation for Contracted Socket. *First step* . . . 286
124. Maxwell's Operation. *Final step* 286
125. Canthorrhaphy 290
126. Harman's Operation for Ptosis 294
127. Panas' Operation for Ptosis 295
128. Ptosis Operation. Advancement of the Levator Palpebræ . . . 296
129. Ptosis Operation. Advancement of the Levator Palpebræ . . . 297
130. Treacher Collins's Entropion Forceps 300
131. Lid Clamp 301
132. Streatfeild's Entropion Operation 301
133. Arlt's Operation for Trichiasis 302
134. Snellen's Sutures 304
135. Ferguson's Operation for Slight Ectropion of the Lower Lid . . 305
136. Modified Kuhnt's Operation for Severe Ectropion. *Second step* . 306
137. Modified Kuhnt's Operation. *Fourth step* 306
138. Argyll Robertson's Operation for Ectropion. *Second step* . . . 307
139. Argyll Robertson's Operation for Ectropion. *Final step* . . . 307
140. V-Y Operation for Ectropion of the Lower Lid due to a Scar. *First step* 308
141. V-Y Operation for Ectropion. *Final step* 308
142. Denonvillier's Operation for Ectropion of the Lower Lid. *First step* 309
143. Denonvillier's Operation for Ectropion 309
144. Fricke's Operation 310
145. De Vincentiis' Operation to replace the Loss of the Medial Portion of the Lower Lid 312
146. De Vincentiis' Operation completed 312
147. Modified Dieffenbach's Operation to replace the Loss of the whole Lower Lid. *First step* 313
148. Modified Dieffenbach's Operation. *Third step* 313
149. Canaliculus Dilator 315
150. Canaliculus Knife 315
151. Lacrimal Syringe 316
152. Muller's Retractor for Excision of the Lacrimal Sac 319
153. Axenfeld's Retractor for Excision of the Lacrimal Sac . . . 319
154. Excision of the Lacrimal Sac 320
155. Excision of the Lacrimal Sac 320
156. Excision of the Palpebral Portion of the Lacrimal Gland . . . 322
157. Clar's Lamp 329
158. Gruber's Aural Speculum 330
159. Angular Spring Forceps 330
160. Examination of the Ear 331

FIG.		PAGE
161.	Aural Forceps holding Cotton-wool	331
162.	Milligan's Intratympanic Syringe	332
163.	Neumann's Syringe for Subcutaneous Injection	335
164.	Burkhardt-Merian's Aural Instrument	339
165.	Crocodile Forceps	348
166.	Imray's Scoop for extracting a Foreign Body	349
167.	Aural Probe	356
168.	Wilde's Aural Snare	356
169.	Wilde's Snare being passed round an Aural Polypus	357
170.	Wilde's Snare gripping the Neck of a Polypus	358
171.	Polypus arising from the Attic Region	358
172.	Anatomical Preparation of the Middle Ear	360
173.	Paracentesis Knife held in position in the Hand	362
174.	Tympanic Membrane showing Incision in Acute Suppuration of the Middle Ear	363
175.	Line of Incision in Acute Suppuration of the Attic	363
176.	Lines of Incisions in Intratympanic Operations	365
177.	Cutting through Intratympanic Adhesions	367
178.	Free Edge of Tympanic Membrane cut through	368
179.	Sexton's Instrument	369
180.	Method of using Siegle's Speculum	369
181.	Division of Intratympanic Adhesion with Excision of Handle of Malleus	370
182.	Schwartze's Tenotomy Knife	371
183.	Lucae's Probe	374
184.	To show Sites of Perforation in Attic Suppuration and Caries of the Ossicles	375
185.	Removal of the Malleus by Wilde's Snare. *First position*	378
186.	Removal of the Malleus by Wilde's Snare. *Second position*	378
187.	Delstanche's Ring-knife	378
188.	Removal of Malleus by Delstanche's Ring-knife	379
189.	Ludewig's Incus Hook	380
190.	Zeroni's Incus Hook	380
191.	Removal of Incus by Zeroni's Hook	380
192.	Pfau's Attic Punch-forceps	381
193.	Removal of Lateral Attic-wall with Forceps	382
194.	Diagrammatic Section to show Correct and Wrong Positions of Incus Hook	384
195.	Eustachian Catheter	389
196.	Passing the Eustachian Catheter	390
197.	Passing the Eustachian Catheter	390
198.	Passing the Eustachian Catheter	391
199.	Passing the Eustachian Catheter	391
200.	Author's Graduated Eustachian Bougie	394
201.	Left Temporal Bone, showing Anatomy of the Middle Ear and Mastoid Process	399
202.	Diagram showing Position of Skin Incisions in Post-aural Operations	405
203.	Schwartze's Operation	406
204.	Schwartze's Operation	408
205.	Schwartze's Seeker	409

FIG. PAGE
206. Schwartze's Operation completed 410
207. The 'Radical' Mastoid Operation 418
208. Stacke's Protector 419
209. The 'Radical' Mastoid Operation 420
210. Pfau's Curette for the Auditory Tube 421
211. The 'Radical' Mastoid Operation completed 421
212. Wolf's Operation 422
213. Stacke's Operation 423
214. Post-meatal Skin Flaps (*Author's method*) 425
215. Post-meatal Skin Flaps 426
216. Closure of Wound after 'Radical' Mastoid Operation . . . 427
217. Körner's Post-meatal Flap 428
218. Panse's Post-meatal Flap 428
219. Stacke's Post-meatal Flap 428
220. Skin-grafting of Mastoid Wound Cavity after Operation . . . 432
221. Ballance's 'Stopper' for pushing in the Graft 432
222. Pipette for sucking Air and Fluid from beneath the Graft . . . 433
223. Skin-grafting of Mastoid Wound Cavity after Operation . . . 433
224. Skin-grafting of Mastoid Wound Cavity after Operation . . . 434
225. Posterior Portion of Skin Graft covering Outer Surface of Wound Cavity 434
226. Operation upon the Labyrinth 451
227. Extirpation of the Labyrinth 452
228. Diagrams to illustrate the Areas concerned in A, Double Vestibulotomy; and B, Inferior Vestibulotomy with partial removal of the Cochlea 453
229. Intracranial Division of the Acoustic Nerve. *First stage* . . . 458
230. Intracranial Division of the Acoustic Nerve. *Second and third stages* 459
231. Method of Removal of Bone by the Forceps 467
232. Haynes's Operation. The Position of the Skin Incision . . . 471
233. Haynes's Operation. The Trephine Opening and the Grooves cut into the Foramen Magnum 472
234. Haynes's Operation. The Incision through the Dura Mater with exposure of the Arachnoid 472
235. Haynes's Operation. Completion of Operation; the Arachnoid has been divided and the Cisterna Magna opened 472
236. Diagram to show the usual Points at which the Transverse Sinus is primarily infected 479
237. The Transverse Sinus exposed and opened 481
238. Incision for Exposure of the Jugular Vein 485
239. Exposure of the Jugular Vein high up 486
240. Ligature of the Jugular Vein low down in the Neck 487
241. Free Exposure of the Transverse Sinus, which has been incised, with Ligature of the Jugular Vein 488
242. Topography of the Auditory Region of the Skull 500
243. Exploration for a Temporo-sphenoidal Abscess 501
244. Exploration for a Cerebellar Abscess 506
245. Skiagram showing a Tumour of the Larynx 514
246. Horsford's Instrument for transfixing the Epiglottis 516
247. Multiple Papillomata of the Larynx 518

FIG.		PAGE
248.	Tube-spatulæ used for Laryngoscopy	519
249.	Direct Examination of the Larynx by Bruenings' Counter-pressure Method	521
250.	Intrinsic Tumour of the Larynx	526
251.	Extrinsic Tumour of the Larynx	526
252.	Thyrotomy	529
253.	Total Laryngectomy	537
254.	Total Laryngectomy. Gluck's Method	539
255.	Modified von Bruns's Phonation Tube	547
256.	Infrathyreoid Laryngotomy	549
257.	Instruments for Laryngotomy	550
258.	Laryngotomy Canula fitted with Inner Tube	551
259.	Kuhn's Peroral Intubation Apparatus	554
260.	Intratracheal Ether Apparatus of Boyle and Gask	555
261.	Skiagram showing an Angular Tracheotomy Tube in the Trachea	557
262.	Anatomy of the Larynx and Trachea and the Position of Incisions for the Operations in this Region	563
263.	Tubes for Tracheotomy	566
264.	Trachea showing Ulceration caused by a Badly Fitting Tube	576
265.	Stenosis following Tracheotomy	578
266.	Tubes used in the Treatment of Stenosis of the Larynx	579
267.	Trachea showing Ulceration into the Innominate Artery after Tracheotomy	580
268.	Aneurysm of the Aorta perforating the Trachea	581
269.	Sarcoma of the Trachea	586
270.	Instruments for Intubation of the Larynx	592
271.	Skiagram of Normal Bronchial Tree	599
272.	Instruments for Bronchoscopy	601
273.	Instruments for Bronchoscopy	602
274.	Upper Bronchoscopy with the Patient in the Dorsal Position	604
275.	Lower Bronchoscopy with the Patient in the Dorsal Position	605
276.	Laryngoscope Lamp	610
277.	Clar's Electric Light	611
278.	Frontal Search-light	611
279.	Meyer's hollow Vulcanite Nasal Splint	622
280.	Krause's Trocar and Canula	623
281.	Nasal Punch-forceps	623
282.	Post-nasal Forceps	624
283.	Nasal Dressing Forceps	625
284.	First Step in removing the Anterior End of the Inferior Concha, which is seen to have undergone Polypoid Degeneration	627
285.	Nasal Scissors	628
286.	Amputation of the Posterior End of the Inferior Concha	630
287.	Nasal Spokeshave	631
288.	First Step in the Removal of the Anterior End of the Middle Concha	633
289.	Second Step in the Removal of the Anterior End of the Middle Concha	633
290.	Cresswell Baber's Nasal Saw	637
291.	The Gleason-Watson Operation for Deformity of the Septum	639
292.	Asch's Cutting Scissors	640
293.	Lake's Rubber Splint	640

FIG. PAGE
294. Bayonet Knife 644
295. Incision for Submucous Resection of the Septum 644
296. Making the Incision from the Convex Side in Submucous Resection of the Septum 645
297. Dull-edged Detacher 645
298. Denudation of the Septum in Submucous Resection 646
299. Complete Denudation of the Deviated Septum 646
300. Ballenger's Swivel Septum Knife 647
301. The Method of employing Ballenger's Swivel Septum Knife . . 647
302. Submucous Resection of the Septum 648
303. Submucous Resection of the Septum 649
304. Submucous Resection of the Septum 649
305. Semi-diagrammatic Transverse Section of the Nose 651
306. Operation for Perforation of the Septum 652
307. Nasal Snare 654
308. Luc's Nasal Forceps 657
309. Tongue Clip 658
310. Incisions for Lateral Rhinotomy (Moure's Operation) . . . 660
311. The Area of Bone removed in Lateral Rhinotomy 661
312. Lateral Rhinotomy 662
313. Rouge's Operation. *First stage* 664
314. Rouge's Operation. *Second stage* 665
315. Catheterizing the Maxillary Sinus 667
316. Lichtwitz's and Moritz Schmidt's Antrum Needles 668
317. Puncturing the Maxillary Sinus 668
318. Maxillary Sinus Drills 669
319. Solid Rubber Obturators 669
320. Maxillary Sinus Nozzle 669
321. Washing out the Maxillary Sinus from an Alveolar Opening . . 670
322. The Incision in the Caldwell-Luc Operation upon the Maxillary Sinus 672
323. The Caldwell-Luc Operation upon the Maxillary Sinus . . . 673
324. Opening the Maxillary Sinus from the Nose 674
325. Ostrone's Punch-forceps 675
326. The Opening into the Maxillary Sinus from the Inferior Meatus of the Nose 676
327. Denker's Operation 677
328. Catheterizing the Frontal Sinus 680
329. Radiograph to show the Value of the Röntgen Rays 681
330. Radiograph showing Canula in the Frontal Sinus 682
331. Killian's Operation upon the Frontal Sinus 684
332. Killian's Operation upon the Frontal Sinus 685
333. Periosteal Elevators 686
334. Killian's Triangular Curved Chisel 686
335. Citelli's Bone-forceps 687
336. Hajek's Bone-forceps 687
337. Killian's Operation upon the Frontal Sinus 688
338. Radiograph of the Sphenoidal Sinus 695
339. Radiograph of the Sphenoidal Sinus 696
340. Catheterizing the Sphenoidal Sinus 697
341. Killian's Long Nasal Speculum 698

FIG. PAGE
342. Radiograph showing a Probe in the Sphenoidal Sinus . . . 699
343. Sphenoidal Punch-forceps 700
344. Adenoid Curette 709
345. The Removal of Naso-pharyngeal Adenoids 709
346. Removal of Naso-pharyngeal Adenoids 710

SECTION I

OPERATIONS UPON THE GENITO-URINARY ORGANS

OPERATIONS UPON THE MALE GENITAL ORGANS

BY

F. F. BURGHARD, M.S. (Lond.), F.R.C.S. (Eng.), Colonel A.M.S.

Surgeon to King's College Hospital; Senior Surgeon to the Children's Hospital, Paddington Green

CHAPTER I

OPERATIONS UPON THE PENIS

OPERATIONS FOR HYPOSPADIAS

Indications. Some form of plastic operation is required for all cases of defect in the floor of the urethra in which there is an impediment to the act either of micturition or coitus. There is no need to operate when the penis is moderately straight and has not undergone the downward deflexion commonly met with in marked cases of the deformity, neither is operation called for when the urethra opens at the base of the glans; in these cases the stream of urine can be projected normally and does not spray out and wet the patient as it does when recurvation exists. At the same time, however, it must be remembered that these are the easiest cases in which to secure a good cosmetic result, and the surgeon is not infrequently asked to operate upon them when the patient is grown up and is desirous of having the parts restored to their natural condition as nearly as possible.

When, however, the urethra opens further back than the junction of the middle with the anterior third of the penis, operation is always advisable. In most of these cases there is so much recurvation of the organ that the urine cannot be projected in an unbroken stream, but is sprayed out so that the parts are continually wet and in a state of chronic irritation that is most unpleasant and distressing; moreover, fertile intercourse is practically impossible.

The most suitable age for operation. As a rule, operation should be delayed until the patient is about six years of age; before that time the parts are so small and the inconvenience to the child is so slight as to render it unnecessary and inadvisable to endanger the chances of a successful result by operating when the parts are so delicate. The real difficulty in the operation lies in this smallness of the parts, which renders many of the operations recommended for this condition impracticable. It must also be remembered that it is difficult to repeat these operations, should they not be successful at the first attempt; the parts, already scanty, are occupied by dense fibrous tissue which effectually precludes the satisfactory raising of flaps and their accurate coaptation and suture.

When the urethra opens close to the root of the penis, and the organ is markedly recurved, it will be well to commence treatment when the child is about five years old; the first year may be devoted to straightening the organ (*vide infra*). A considerable time should be devoted to this part of the procedure, as the success of the rest of the operation depends largely upon it; as free incisions may have to be made, it is advisable that the cicatricial tissue resulting from them should have time to disappear as completely as possible before the final stages are undertaken, so that the parts may be supple and the flaps easily raised.

If the meatal orifice be immediately behind the glans, it is well to wait until the child is at least eight years old before operating. In this case even more than in the previous one it is most essential to have the parts as large as possible if the result is to be successful, and there is no objection to delay, since the child does not suffer from the abnormal position of the opening. In both classes of cases the operation should be practised before the onset of puberty. For this there are two chief reasons: the first and most important is that erections of the organ occurring after the operation in adolescents may seriously jeopardize the success of the operation, and the other is that the physiological development occurring at puberty materially helps to perfect the final result of the operation.

Methods of operating. The cases requiring operation may be divided into two groups, *viz.* those in which only the portion of the urethra traversing the glans is defective, and those cases in which the urethra opens on the under surface of the penile portion, generally near the peno-scrotal junction or even as far back as the perineum. In the latter group of cases the operative procedure usually consists of at least two stages, of which one is that for restoration of the glandular urethra.

FORMATION OF A NEW URETHRA IN THE GLANS PENIS

Much ingenuity has been expended on this operation and many unnecessarily complicated methods have been introduced. If a plastic operation be really required, which is generally only the case when it is to form part of a more extensive operation, the urethra in the glans penis can usually be restored by one of the following simple methods:—

From the redundant prepuce. When the urethra opens on the under surface of the base of the glans, the characteristic 'hooded' prepuce is present (see Fig. 1, A), and this may be made use of for repairing the urethra. This hood or fold of the prepuce overhangs the glans like a monk's cowl, and by putting it on the stretch and thrusting a narrow bistoury through it from the mucous to the cutaneous surface,

a large buttonhole-like aperture (see Fig. 1, B) is cut, and through this the glans itself is made to pass backwards as the hood of the prepuce is brought forward over it (see Fig. 1, C). The preputial flap thus becomes converted into a sort of apron below the frenal surface of the glans and can be utilized to furnish the floor of the new urethra, the roof of which

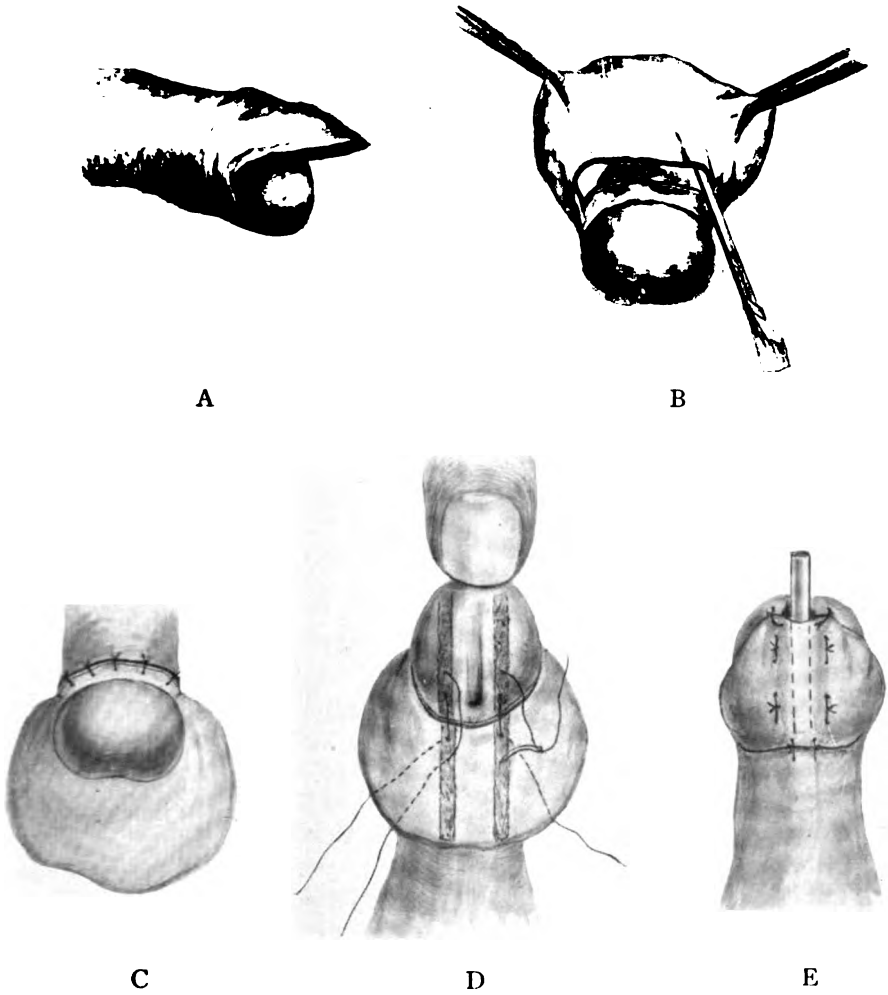

FIG. 1. REPAIRING THE PENILE URETHRA BY MEANS OF THE PREPUCE. A shows the 'hood' of redundant prepuce, B the incision made through it, and C the appearances when the glans penis has been passed through it. D shows the areas made raw upon the glans and the corresponding surfaces on the prepuce, and the method of inserting the sutures, while in E is seen the result when the sutures have been tied and the preputial flap trimmed up.

is provided by the slight groove which marks the normal situation of the urethra, and which is present even in the most severe cases.

A fine india-rubber Jaques's catheter (No. 6) is laid into this groove and its end is passed down the urethra for an inch or two; a narrow strip of the mucous membrane covering the under surface of the glans is then made bare on each side of the catheter from the level of the urethral orifice to the tip of the organ; the simplest way of doing this is to remove the mucous membrane with one snip of a fine pair of scissors. The flap or apron of prepuce is now laid over the catheter so as to form the floor of the urethra, and two small strips of skin are removed from it in a similar manner exactly opposite the raw surfaces already made on the glans (see Fig. 1, D). The raw surfaces on the glans on each side of the catheter are then approximated to the corresponding raw surfaces upon the preputial flap by fine horsehair sutures mounted upon the smallest fully-curved needles obtainable. Each suture should pass beneath the raw surface upon the glans parallel with its long axis, and the ends emerging from this should transfix the preputial flap at the corresponding points from its urethral to its cutaneous surface. Two or more of these sutures are passed on each side (see Fig. 1, E).

It now only remains to join the posterior or lower margin of the preputial flap to that of the abnormally situated meatus. The latter is seized with catch-forceps, and its inferior margin is put well upon the stretch and pared away with fine curved scissors. This separates the mucous from the cutaneous surface, and the corresponding margins of the lower edge of the preputial flap are sutured to these with very fine catgut. Special care should be taken to approximate the mucous membrane of the urethra accurately to the corresponding surface of the preputial flap. The sutures should be passed so that the ends emerge from and are tied on the under aspect of the penis.

The new urethral orifice may be fashioned to the operator's taste by making raw corresponding surfaces of the skin and the prepuce and suturing them together. It is well to make the new meatus unduly large, in order to allow for contraction. The catheter is secured in position by a single catgut suture passing through it and the adjacent prepuce.

After-treatment. No dressing is necessary. The child lies upon his back with a cradle to keep the bedclothes from contact with the parts, and his legs fastened to the cradle so that he cannot roll over on to his face; his hands should be tied so that he cannot interfere with the wound. He should have a warm bath twice daily, after which the parts should be dabbed dry and dusted with boric acid powder. Alternate stitches may be removed on the fourth day, and all the sutures may be

taken out by the end of the eighth day. The catheter over which the urethra is fashioned, which is secured in place by a single stitch passing through the preputial flap, should be kept in position for five days. It does not cause either cystitis or urethritis if the parts be thoroughly purified before the operation and if it be not passed down the urethra for more than 2 inches.

From the skin on the under surface of the penis. This is a very useful method for restoring the anterior end of the urethra in the minor degrees of the deformity in adults who desire the operation.

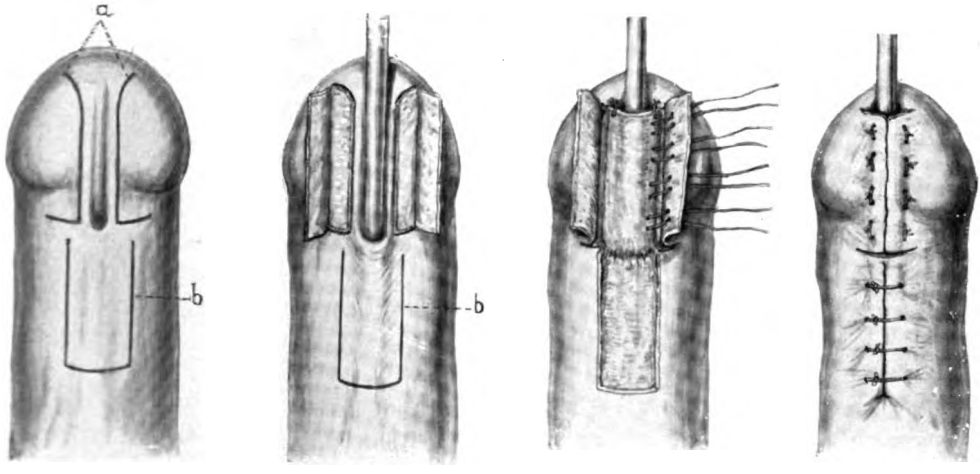

FIG. 2. REPAIRING THE PENILE URETHRA BY MEANS OF A PENILE FLAP. A shows the incisions for the flap *b*, as well as those from the glans *a*, beneath which the flap is to be placed. These flaps are shown reflected in B, while in C the penile flap is turned up into position and the retaining sutures have been inserted on one side. The result is shown in D.

It is simpler than the one just described, but it is only suitable for older subjects in whom the soft parts at the disposal of the surgeon are more voluminous. The operation consists in raising a rectangular apron-like flap of skin from the under surface of the penis below the urethral orifice, and turning this upwards over a catheter in the groove in the glans so that its cutaneous surface looks inwards and forms the floor of the new urethra (see Fig. 2, C). A small lateral flap is raised from each side of the glans and beneath these the apron-like flap is inserted. They are then brought together to form the outer or cutaneous covering of the new urethra (see Fig. 2, D).

The author has practised both these methods in suitable cases with the best results; as far as his experience goes, one of them suffices for

most cases of this type. Many others have been advocated, most of which have been tried with disappointing results. Beck's ingenious plan of freeing the anterior end of the urethra, dissecting it up for an inch or more, and then thrusting it through a tunnel bored in the glans with a trochar demands not only a urethra of good size and firm consistency, but also much operative dexterity and extreme delicacy of manipulation; sloughing of the isolated urethra may easily take place. The plan of Esmarch and Kowalzig (see Fig. 8), in which lateral incisions are made on the under surface of the glans, and between them a catheter is laid, and the edges of the gutter thus made are refreshed and brought together, is theoretically good but most difficult to carry into practice. Owing to the extreme tension, much granulation occurs even if no suppuration follows, and the new urethra is full of dense fibrous tissue.

FORMATION OF A NEW PENILE URETHRA

It is upon the cure of the more severe forms of hypospadias that the greatest ingenuity has been expended. The author has tried most of the methods, and has found nearly all of them open to serious objections. Duplay's classical operation, the details of which are shown in Fig. 3, which is so simple and apparently satisfactory on paper, is practically useless; the parts are too small and the tissues are not sufficiently abundant. It is often difficult to draw the flaps together without strangulating the penis, and some amount of sloughing is quite common in this form of operation. Hamilton Russell's method (*Brit. Med. Journ.*, 1900, vol. ii, p. 1432) is most ingenious, but the chance of sloughing of the narrow strips of skin out of which he fashions the new urethra is so great as to prevent the operation from coming into common use. C. H. Mayo (*Jour. Amer. Med. Assoc.*, April, 1901) fashions a tube with a cutaneous lining from the skin of the dorsum of the penis; this is drawn through from the dorsum to the neighbourhood of the urethral orifice beneath the skin, and, when its vitality is assured, its lower end is fastened to the urethra at a subsequent operation, while its upper end furnishes the new meatus. This is an operation of great delicacy and difficulty, and for reasons already given is hardly likely to be used frequently.

Straightening the penis. Before a plastic operation can be undertaken with any prospect of success, the penis must be straightened if it should have the characteristic recurved form often met with in hypospadias. This downward flexion of the organ is largely due to a thick band of fibrous tissue running along the middle line just below the septum between the corpora cavernosa; there may also be shortening of the under surface of the sheath of the corpora cavernosa itself, and the effect of this is to bend the organ downwards so that the

urine impinges upon the tip of the organ as it is ejected, and becomes sprayed out. Before proceeding to perform a plastic operation it is essential to straighten the organ, which may be effected by a judicious use of a tenotome. The penis is seized in the left hand and pulled straight so that the tense bands on the under surface are easily identified; they are nicked transversely in one or more places until the organ can be made to lie flat upon the abdominal wall without any tension. In some cases the skin of the under surface of the penis, corresponding to what will be the roof of the new urethra, is

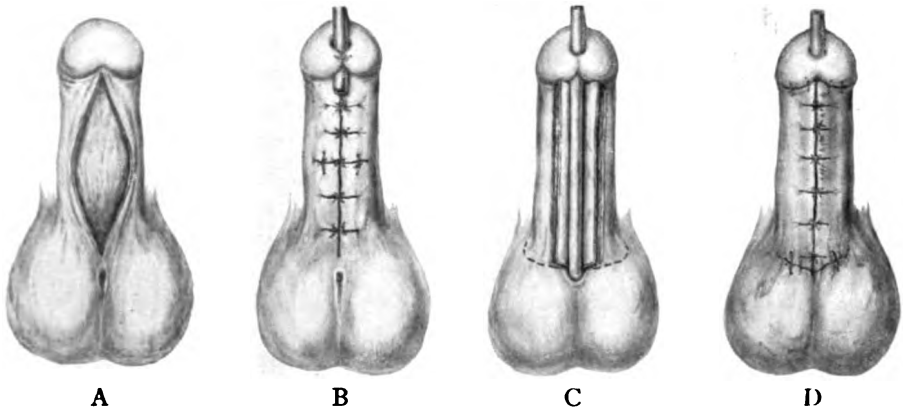

FIG. 3. DUPLAY'S OPERATION FOR HYPOSPADIAS. A and B show the preliminary stages, in which the penis is straightened and the urethra in the glans is repaired. The straightening is effected by a transverse incision which gives a lozenge-shaped space when the penis is pulled straight and is sewn up so as to produce a vertical cicatrix. C and D show the flaps raised on each side and united over a catheter and then covered in by drawing flaps across to meet over them.

so contracted that it must be divided also, and this, of course, gives rise to small diamond-shaped incisions when the organ is put on the stretch. These incisions are best closed by minute Thiersch's skin-grafts; it is well not to allow healing by granulation, as this is sure to be followed by re-contraction. The grafts, however, will not take satisfactorily unless the penis be kept in the straightened position, and, in order to ensure this, the author secures it to the abdominal wall by two sutures in such a way as to put the under surfaces of the corpora cavernosa fully upon the stretch. A fold of boric lint is placed between the abdominal wall and the dorsal surface of the penis, so as to prevent irritation from decomposing sweat. It is also a good plan to pass a rubber catheter an inch or so down the urethra, and to secure it there by a suture; this enables the urine to be led away from the grafted

area and considerably facilitates their taking. No dressing is applied; the bedclothes are kept from the parts by means of a cradle, and the child's hands are secured so that he cannot interfere with the wound.

This is an excellent way of performing an essential part of the operation, but it is important to take sufficient time over it and, if necessary, to perform it in several stages. The chief point to be guarded against is the production of granulating surfaces, since these will be followed by fibrous tissue which may take on a keloid character and so defeat the objects of the operation. If necessary, a year may be spent over this part of the operation.

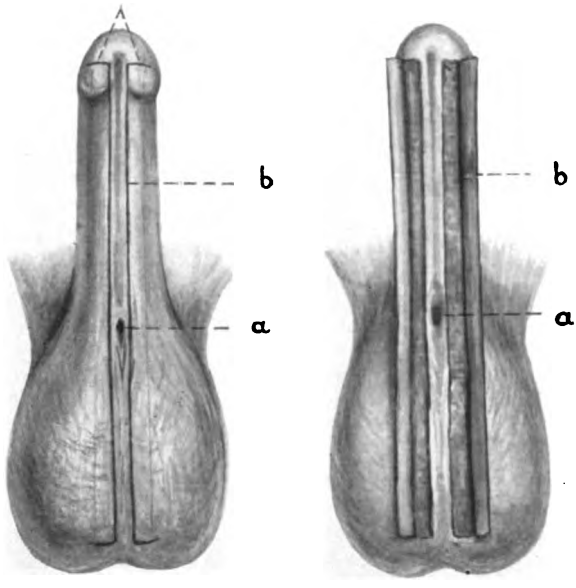

FIG. 4. BUCKNALL'S OPERATION FOR HYPOSPADIAS. *The incisions.* *a* is the urethral orifice, *b* the vertical, and *c* the horizontal incisions for the flaps.

Bucknall's operation. After trying all the operations enumerated on p. 8, the one that has given the most satisfaction in the author's hands is that suggested by Mr. R. T. H. Bucknall and described by him in the *Lancet*, 1907, vol. ii, Sept. 28. This has given admirable results in three cases, and the ease with which it can be done is in agreeable contrast to the difficulty of some of the other methods. The functional result is excellent, whilst the appearance of the organ after the operation leaves nothing to be desired. It is done as follows:—

First stage. The urethral orifice is taken as the fixed point, and from this incisions are made for equal distances (see Fig. 4, A) upwards and downwards. The incisions upwards run parallel to each other and to the long axis of the organ, and are at such a distance apart as the operator judges will give a sufficiently wide new roof to the urethra, which is to be formed by the skin of the under surface of the penis. On each side of these incisions narrow flaps are raised by carrying outwards, from the upper end of each, horizontal incisions about ¼ inch in length.

The vertical incisions are prolonged downwards over the anterior surface of the scrotum, at least as far below the urethral orifice as they extend above it, and similar flaps are raised by carrying horizontal incisions outwards at their lower ends. It is advisable to make the incisions below the urethral orifice slightly longer than those above it, in order to allow for the greater retractility of the scrotal skin.

The lateral flaps are dissected up on each side from the horizontal incision above to that below, taking care to raise them to the same distance throughout. They are then turned outwards so that the appearances seen in Fig. 4, B, are presented, *viz.* a narrow central strip of skin having the urethral orifice at its centre; the upper half of this forms the roof, the lower half the floor of the new urethra. Outside this is a broad raw surface, the outer vertical half being formed by the raw surface of the reflected flaps, the inner by the raw surface from which they have been raised. A No. 6 soft Jaques's catheter is now taken, and its end is cut off obliquely and inserted for ½ inch down the urethral orifice, which must be incised to admit it if necessary. The rest of the catheter is laid along the lower half of the median cutaneous strip, and the penis is brought down into contact with the scrotum so that the upper half of the median cutaneous strip lies over the catheter and forms the roof of the new urethra. The appearances seen in Fig. 5, C, are then presented, each lateral flap being flexed upon itself near its centre and forming a broad flange at the side of the penis.

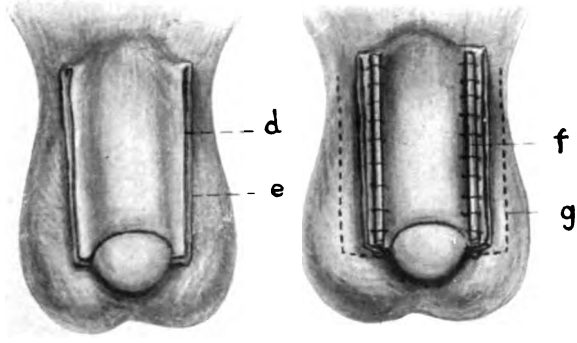

FIG. 5. BUCKNALL'S OPERATION FOR HYPOSPADIAS. *The penis secured to the scrotum.* *d* and *e* are the superposed edges of the flap *b* shown in the preceding figure. *f* is the drainage tube around which the sutures are fastened, and *g* is the scrotal incision for liberating the penis in the subsequent stage of the operation. For the sake of clearness the catheter is not shown *in situ*.

The next step is to suture the flaps, which must be done with great care, as the sutures must not only fasten each lateral skin flap, but must also approximate the margins of the median cutaneous strips above and below so as to form a complete urethra surrounding the catheter; Fig. 6 shows how this is done. The sutures, which should be of the

finest horsehair mounted upon the smallest needles obtainable, are first introduced from the under surface of one of the lateral flaps or flanges near to its angle of reflection. It emerges from the raw surface and is made to pick up the adjacent margin of the inferior median cutaneous strip; it then takes up the corresponding edge of the upper median cutaneous strip, passes from the raw to the cutaneous surface of the upper half of the lateral flap or flange, and is finally made to transfix both halves of the lateral flap or flange from the upper to the lower cutaneous surfaces just external to the point at which it was introduced (see Fig. 5, D). About four or five of these sutures are introduced on each side, and it is well to keep the ends long until they are all in position so that accuracy of insertion may be ensured. Finally, they are tied over a fine piece of drainage tube.

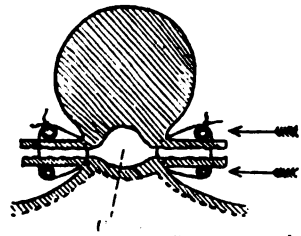

FIG. 6. BUCKNALL'S OPERATION FOR HYPOSPADIAS. *The arrangement of the sutures.* *u* is the lumen of the newly formed urethra. The arrows point to the pieces of drainage tube over which the sutures are tied.

If desired, the edges of the groove in the glans penis can be made raw and sutured to a corresponding raw area where it lies in contact with the scrotal skin; but as a rule this is best left to a later stage of the proceedings, when one of the operations previously described can be adopted.

The catheter is secured in position by a fine horsehair stitch and is left long enough to drain into a bottle. The child is put back to bed without any dressings, the bedclothes being kept off by a cradle over the pelvis and the hands being fastened out of the way.

No special after-treatment is necessary. The sutures are retained in position until the fifth day, when alternate ones may be removed; on the seventh or eighth day they may be all removed if primary union has occurred. The catheter may remain in for a week; it does not give rise to any inconvenience.

Second stage. The result of the first stage of the operation is to fix the penis firmly to the anterior surface of the scrotum, at the same time providing a tube or tunnel lined with epithelium throughout, along which the urine can pass, and which is continuous behind with the normal urethra without the intervention of any stricture or diverticulum. The object of the second stage of the operation is to raise the organ into the erect position, free it from the scrotum, and, at the same time, provide its under surface with a cutaneous covering.

With this object in view, the incisions shown in Fig. 5, D, are made; they should go well wide of the margin of the penis and should be parallel

to it and of the same length. By following Mr. Bucknall's description in the first case done by the author it was found that these lateral flaps were not wide enough to allow them to be folded round the under surface of the freed penis so as to meet in the middle line without tension. They should be made very wide, as it is most important that they should meet without any tension, and it is immaterial to the union of the wound in the scrotum how wide they are.

When these flaps have been raised, the penis must be separated from the scrotum by a little careful dissection, during which it is advisable to insert a fine bougie down the urethra in order to define it and so avoid button-holing it when dissecting up the penis.

The operation is completed by wrapping the scrotal flaps around the body of the penis and suturing them together in the middle line (see Fig. 7, E). The raw surface on the scrotum is closed by a few sutures, and the raw surface left at the angle of reflection of the penis from the scrotum is sutured as shown in Fig. 7, F.

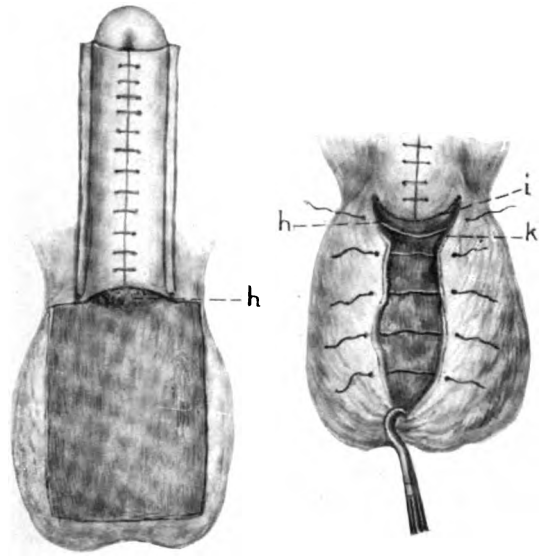

E F

FIG. 7. BUCKNALL'S OPERATION FOR HYPOSPADIAS. *Final stage.* Shows how the new urethra is closed in by flaps dissected up from the scrotum. The raw area, *h*, must be carefully closed by suturing the edges of the skin, *i* and *k*.

No catheter need be used, as the patient can micturate normally; no dressing is necessary, as the penis maintains an erect position. The sutures are removed at the end of the week, and the fashioning of the urethra in the glans can be undertaken as soon as union has occurred throughout.

This operation is very simple and easy to perform when a thorough understanding of it has been acquired. It seems to be quite an ideal operation for those cases in which the urethra opens at the peno-scrotal junction; in two cases of this kind done by the author the result was perfect. When the opening is further back in the perineum the operation is more difficult, but the idea of providing a complete cutaneous lining

to the urethra continuous with the normally existing one is an excellent one, and does away with one of the greatest objections to other plastic operations of this kind.

Difficulties. The only practical difficulty met with in the operation was making the scrotal flaps meet around the penis in the final stage of the operation. As mentioned above, this was subsequently overcome by cutting much wider flaps than those originally suggested by Mr. Bucknall. A theoretical objection which occurs to the author, but which there has not yet been time to verify by experience, is the possibility of the development of hairs along that portion of the floor of the urethra derived from the median raphe of the scrotum. It is possible that this may not occur, partly from the fact that hairs do not develop freely along the raphe, and partly on account of the early stage at which the operation is performed; but, should experience show that this does occur, the author would suggest that it can be easily remedied in future by first preparing a surface free of hairs along the median raphe by means of Thiersch's skin grafts. When this has become properly established it will be easy to perform the operation in the usual manner and there will then be no possibility of hairs developing.

OPERATIONS FOR EPISPADIAS

This condition is much rarer than the preceding one and is far less amenable to treatment. The deformity is always more marked, the penis being rudimentary and recurved upwards, and the affection is almost invariably associated with ectopia vesicæ. As has been pointed out by Mr. Thompson Walker, a plastic operation having for its object the restoration of the vesical cavity cannot provide a satisfactory sphincter vesicæ, and therefore complete functional restoration of the penis and its urethra is an impossibility. The surgeon's aim is merely to provide a channel down which the urine can be conducted to the urinal which the patient has to wear for the rest of his life. This of course only applies to the operations that aim at restoring the vesical cavity. In the more modern methods, in which the bladder is extirpated and the ureters are implanted into the rectum, plastic operations upon the urethra are not called for.

As in the operation for hypospadias it may be necessary to divide the procedure into two stages, the first being straightening the stunted and recurved penis, while the true plastic operation is performed at the second. Straightening the penis is far more difficult and less satisfactory in epispadias than in hypospadias. In spite of free division of the corpora cavernosa it is extremely difficult to keep the organ properly stretched

during the process of cicatrization, and, as suppuration and free granulation commonly result from the irritation to which the wound is subjected, the after-condition is worse than before the operation. If the operation be attempted, its main lines will follow those of the operation for hypospadias. The closure of the urethra cannot well be effected by any modification of Bucknall's method (see p. 10), since the middle line of the abdomen is occupied either by the protruded mucous membrane of the bladder or by the cutaneous flaps which cover it in; therefore Duplay's classical method is usually followed (see Fig. 3), the flaps being taken from the dorsal instead of the under surface of the penis. For reasons already given (see p. 8) this method is unsatisfactory, and the

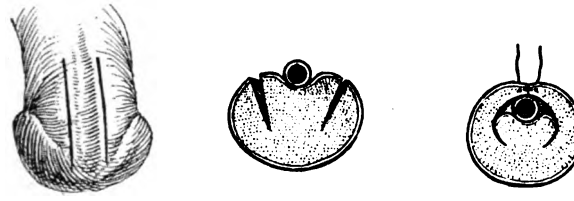

FIG. 8. FORMATION OF THE URETHRA IN CASES OF EPISPADIAS. In A are shown the incisions, which extend deeply, as seen in B. The catheter is then laid in position, and the final stage is seen in C.

author has on one occasion formed a covering to the urethral groove by superposed skin flaps turned in, one from either groin. The flaps were cut with a long pedicle which was left unsevered until they had become firmly adherent in their new position, when they were trimmed off in the usual manner. The first flap had its cutaneous surface downwards and its raw surface upwards, the second was applied so that its raw surface was in apposition to the raw surface of the first and its cutaneous surface was therefore outwards and formed the skin of the penis. The result was not very sightly, but was quite efficient.

If it be desired to form a fresh urethra through the glans, this may be done by the same flap, or by the method of Esmarch (see Fig. 8).

The proximal end of the newly formed urethra requires to be joined up to the reconstituted bladder-wall. This may be done at the time the new urethra is formed, but, on the whole, it is better to postpone it until healing of the flaps has taken place. A catheter is then introduced into the bladder, or preferably a median perineal section is performed and the urine drained away; the adjacent margins of the urethra and the skin covering the bladder in the region of its anterior wall are pared and sutured with fine horsehair.

CIRCUMCISION

Indications. (i) *Phimosis.* Although the operation is frequently recommended for all cases of phimosis whatever their degree, and although there is much to be said in favour of operation in these cases from the point of view both of cleanliness and morality, it is by no means absolutely necessary except when the preputial ring, *i.e.* the junction of the mucous with the cutaneous surface, is normally, or has become pathologically, so narrow and unyielding that it is impossible to withdraw it over the glans. A long narrow prepuce does not *per se* require to be removed, although extra care is required for proper cleanliness and to avoid balanitis. Should this latter condition supervene, the first effect of the inflammation is to thicken the prepuce, to make its orifice relatively narrower, and to convert the case into one of acquired phimosis. Unless the prepuce be slit up, severe ulceration possibly ending in gangrene may occur. This, however, is not a true circumcision, which should not be done under these circumstances (*vide infra*).

(ii) *Soft chancre beneath a long prepuce.* Here the conditions are very similar to those in balanitis beneath a redundant prepuce, but the danger of gangrene is greater. In some of these cases circumcision allows the soft sore to be excised completely along with the redundant prepuce, but as a rule simple slitting up of the prepuce is to be preferred to circumcision (*vide infra*).

Contra-indications. It is not advisable to do a complete circumcision when there is acute inflammation going on beneath the prepuce; the most that should be done in these cases is to slit up the prepuce so that free drainage and proper exposure of the subjacent parts may be secured. Infection of the cut surfaces is almost certain to occur, and, if a complete circumcision has been done, this may result in a foul wound encircling the whole organ, giving rise to wide destruction and serious cicatrization afterwards.

This operation should always be done at the earliest age possible; if performed a few days after birth there is hardly any disturbance following it, and it is extremely simple, provided that great care be taken to arrest all bleeding before the patient is left, as hæmorrhage is most dangerous at such an early age. In an adult the operation is more troublesome, chiefly on account of the variations in size of the organ subsequently.

Operation. This small operation, which is generally left to dressers and house surgeons, is difficult to perform really neatly and satisfactorily; the most common defect in the operation is the presence of a tender redundant mass in the neighbourhood of the frenum, which may granu-

late for weeks before healing takes place; it disappears very slowly but eventually becomes unrecognizable. A line of ulceration surrounding the penis owing to imperfect union of the flaps is another objectionable feature not infrequently seen.

It is probable that the classical method of performing this operation is somewhat to blame for the ugly results so often seen. In this plan the separated blades of a pair of dressing forceps are made to embrace the glans penis parallel to and immediately in front of the corona. The blades are gently closed upon the skin, in doing which the glans is allowed to slip back so that when the blades are closed they press the prepuce together in front of it. The portion of the prepuce in front of the forceps is shaved off with a sharp knife, and the forceps are then removed and the shortened prepuce is allowed to retract. This exposes the corresponding mucous surface of the prepuce which has not been divided, and this is slit up from the preputial orifice back to the level of the skin section and the redundant portion pared away. The skin and mucous surfaces are then brought into apposition throughout by fine sutures of catgut or horsehair.

There are two objections to this method. The first is that the mucous membrane must be cut in a slanting direction from behind downwards and forwards towards the tip of the organ; in other words, the line of section must be parallel to the corona. If care be taken to place the forceps parallel with the corona and to keep them so during the approximation of their blades, it is possible no doubt to make the line of section correctly and to divide the mucous membrane subsequently so that the mucous and cutaneous surfaces will meet everywhere without tension and without the risk of leaving a raw granulating surface in the neighbourhood of the frenum; even then, however, it is necessary to insert sutures in the neighbourhood of the frenum, and these are irritating and are followed by the formation of a tender swelling. The second objection is that with this method it is difficult to gauge the exact amount of tissue that should be removed. The amount actually removed will vary largely according to the state of the organ at the time of the operation; on the one hand, it is common to see so much removed that the organ is almost bereft of skin, while on the other, most surgeons have been called upon to operate a second time owing to the fact that after the first operation the glans has retracted beneath the skin, which has then become contracted in front of it, giving rise to a secondary phimosis. Another less important objection is that a beginner may press the blades of the forceps too tightly together and damage the skin so much that it sloughs subsequently. This error can be avoided by placing the forceps a little further forward on the prepuce and cutting through the latter

behind their blades instead of *in front* of them, so that the compressed portion of the prepuce is removed along with the free end.

The method which offers the best results even in the most inexpert hands is the following: After the patient has been anæsthetized, a pair of catch-forceps is placed on the preputial orifice on each side of the mid-dorsal line, and a probe or the closed blades of a pair of fine blunt-pointed scissors are inserted between it and the glans and pushed backwards to the corona so as to separate any adhesions between the two. Then, while the assistant pulls the forceps well forward, one blade of the scissors is

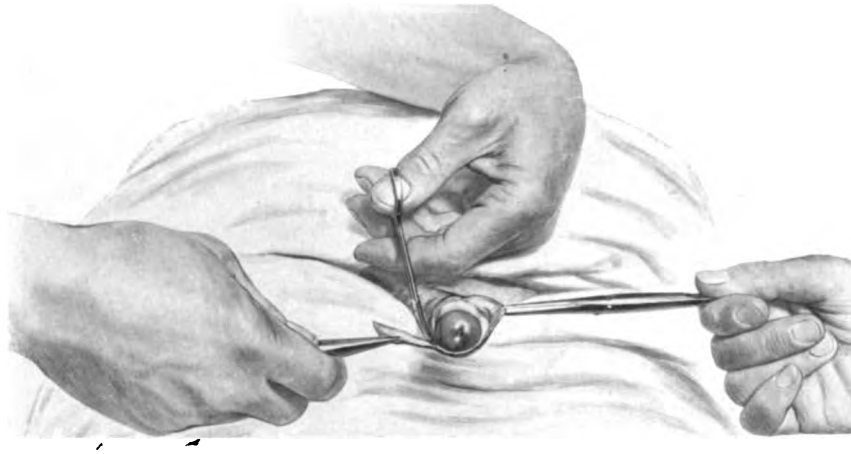

FIG. 9. PARING AWAY THE PREPUCE IN CIRCUMCISION.

passed beneath the prepuce and the other above it and the foreskin is slit up in the middle line right back of the corona with a single cut; this divides the mucous and cutaneous surfaces back to the same level. The two preputial flaps are now reflected, all adhesions between them and the glans separated, and any retained smegma removed. It will then be seen how much of the redundant tissue need be removed; as a rule very little suffices, and it is always advisable to leave enough to just cover the corona so as to prevent undue irritation. In order to pare off the redundant prepuce the parts should be put on the stretch as shown in Fig. 9, and the surgeon, using a pair of blunt-pointed fine curved scissors, pares away as much of both the cutaneous and the mucous surfaces of the prepuce as he deems necessary parallel to the

corona. As the scissors travel round from the dorsum to the frenum they approach more nearly the free margin of the prepuce, and it is a good plan not to carry the incision quite up to the middle line of the frenum; if it be made to terminate about a sixth of an inch from the middle line on each side, the terminal branches of the frenal artery are not divided and there is no necessity to insert sutures in the immediate neighbourhood of the frenum, which avoids a good deal of swelling and irritation.

After the mucous membrane has been pared away on each side, a few fine horsehair or catgut sutures, preferably the latter, bring the edges into accurate apposition. This is quite easy, since the cutaneous and mucous surfaces have been everywhere cut on the same level. About six sutures suffice in a young child, but a larger number should be used in an adult, as it conduces greatly to the success of the operation to have the raw edges in apposition everywhere. In a child no dressing is necessary; a warm boric fomentation is laid over the genitals and is renewed every time the child's diaper is changed. In an adult a strip of dry sterilized gauze may be wound round the incision and allowed to dry on; this dressing may be soaked off next morning in the bath. After this it will only be necessary to apply a little boric acid powder and wrap the organ loosely in gauze to prevent chafing.

After-treatment. An adult should remain in bed or on the couch for four or five days with the parts protected by a cradle and the penis resting upon a few folds of boric lint. In an infant the ordinary routine of life need not be interrupted after the anæsthetic has been recovered from. The sutures, if of catgut, will probably soften and fall out spontaneously; if they have not separated by the fourth day they should be removed in the case of an infant, while in an adult they may be retained until the end of the week. In adults also the bowels must be carefully regulated, and it will be well to insist on a low diet without alcohol; the administration of a nightly draught containing bromide of potassium and other sedative drugs is valuable, as it tends to subdue erections.

AMPUTATION OF THE PENIS

Indications. Epithelioma is the only condition for which amputation of the penis is likely to be required, but there are two points of much interest which have to be taken into consideration before the surgeon operates. The first question is the form that the amputation shall take in any given case, and the second question is whether the inguinal glands should be removed at the time of the operation whether they be enlarged or not.

The type of operation required will be determined largely by the ex-

tent of the disease when the case comes under notice. The penile lymphatics are collected into two main groups, a very extensive one from the glans and a network from the skin, both of which empty into large lymphatic trunks which follow the dorsal vein of the penis and at the

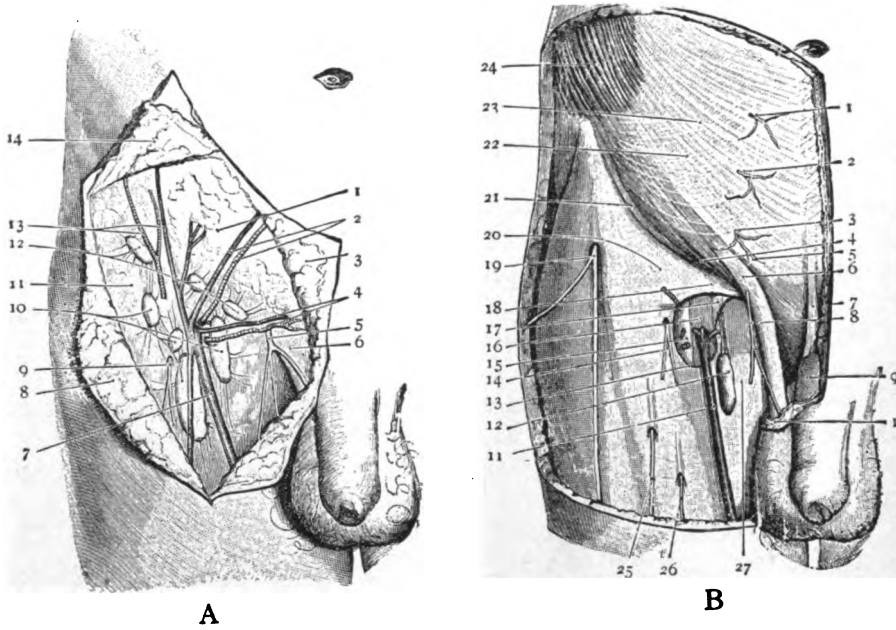

FIG. 10. THE SUPERFICIAL AND DEEP INGUINAL LYMPH GLANDS. A, *The superficial glands*: 1, Deep layer of the superficial fascia; 2, Superficial epigastric vessels; 3, Superficial layer of the superficial fascia; 4, Superior external pudic vessels; 5, Ilio-inguinal nerve; 6, Spermatic cord; 7, Internal saphenous vein; 8, Superficial layer of the superficial fascia; 9, Genito-crural nerve; 10, Femoral glands; 11, Deep layer of the superficial fascia; 12, Inguinal glands; 13, Superficial circumflex iliac vessels; 14, Superficial layer of the superficial fascia.

B, *The deep lymphatic glands:* 1, 2, 3, Cutaneous branches of the lumbar nerves; 4, 5, Pillars of the external abdominal ring; 6, Spermatic cord; 7, Suspensory ligament of the penis; 8, Ilio-inguinal nerve; 9, Penis; 10, Scrotum; 11, Internal saphenous vein; 12, Deep femoral gland; 13, Saphenous opening; 14, Genito-crural nerve; 15, Femoral artery; 16, Femoral vein; 17, Crural sheath; 18, Falciform ligament; 19, External cutaneous nerve; 20, Iliac portion of the fascia lata; 21, Poupart's ligament; 22, Intercolumnar fascia; 23, External oblique aponeurosis; 24, External oblique muscle; 25, 26, Middle cutaneous nerve; 27, Pubic portion of the fascia lata. (*Cunningham.*)

root of the organ pass on each side to the inguinal and external iliac glands. The lymphatics from the skin empty into the superficial inguinal glands, whilst those from the glans pass into the deep inguinal group and thence into the external iliac glands through the crural canal.

It follows from these considerations, therefore, that it is unnecessary to remove the entire organ if only the free end of it be involved, and, as the disease usually starts in the neighbourhood of the glans, a partial amputation is nearly always sufficient. If the amputation be performed ¾ inch behind the furthest limit of the growth it will suffice. The entire organ need only be removed when the disease has spread so far back that it is impossible to get well free of it without detaching the crura from the rami of the pubes.

The question as to the removal of the inguinal glands is one that has only come into prominence recently. The distribution of the penile lymphatics has been given above, and the positions of the inguinal glands are shown in Fig. 10. From a consideration of these facts, it is evident that operations for cancer of the penis cannot be satisfactory unless undertaken before the infection has passed from the deep inguinal glands to the external iliac group through the crural canal; when this has happened, the disease has passed beyond reach. Therefore the inguinal glands should be removed in all cases of cancer of the penis, whether they be enlarged or not. It would no doubt also be better to remove the lymphatics from the dorsal surface of the penis at the same time, but this is obviously a matter of difficulty, and in practice is apparently not necessary. Advantage should be taken of the incision for the removal of the inguinal glands to excise the lymphatic area in the skin, passing from the dorsum of the penis to the superficial inguinal glands.

PARTIAL AMPUTATION OF THE PENIS

Indications. (i) *Cancer of the penis not extending further back than* 1 *inch from the corona.*

When the disease extends further back than this, the complete operation (*vide infra*), followed by suture of the urethra to the skin of the perineum, will probably be preferable to the discomfort which is likely to ensue if the penis be amputated at the peno-scrotal junction, as this leads to great retraction of the urethral orifice and constant trouble in micturition.

(ii) *Extensive warty growths in the penis in elderly patients.* Here the operation may be done to free the patient from a constant source of trouble and a fruitful cause of malignant disease.

The simplest method of amputating the penis is to make a circular sweep around the organ, dividing all the structures at one cut. This, however, leaves a puckered cicatrix that it is difficult to adjust properly and in which granulation may exist for a considerable time before

healing is complete; moreover, since the urethra is in the centre of this area, considerable contraction of the orifice may result.

Amputation by a ventral flap. A better procedure is to fashion a single flap, either from the dorsal or, preferably, from the ventral aspect of the organ; this can be folded over the end of the stump, and provides a satisfactory covering for it. Most surgeons recommend a flap cut from the dorsal surface, but the author prefers to fashion it from the under surface, because the line of union of the flap is thus removed from contamination by the urine during micturition; the point, however, is not of material importance. A ventral flap should be used when the

FIG. 11. AMPUTATION OF THE PENIS. *Transfixing the penis.*

choice lies with the surgeon, but if the situation of the disease necessitates a dorsal flap, this may be made use of without hesitation.

It is usual to control the circulation in the organ by encircling its base with a piece of rubber tubing drawn sufficiently tight. This is an unimportant detail, since firm compression of the root of the penis by the assistant's fingers is quite sufficient if the surgeon operates reasonably quickly.

The first point in the operation itself is to prevent the foul cancerous mass contaminating either the fingers of the surgeons or the skin of the stump, and for this purpose nothing is better than to sear the surface of the growth thoroughly with the actual cautery; after this, the glans is wrapped in several layers of gauze soaked in 1 in 20 carbolic lotion, with a piece of sterilized jaconet outside. This is fixed round the end of the penis beyond the proposed line of amputation by tying it tightly

with a stout ligature. No contamination of the wound can then occur during the later stages of the operation.

After the parts have been shaved, and the skin over the groins has been purified, an assistant seizes the end of the penis and holds the organ vertical whilst the surgeon marks out a U-shaped flap from its under surface by means of a vertical incision along the middle of each lateral aspect of the organ, united by a transverse cut across the under surface. The corners of the flap thus marked out should be rounded off, and its base should be opposite the proposed point of sec-

FIG. 12. AMPUTATION OF THE PENIS. *The stump.*

tion of the corpora cavernosa. A few touches with a sharp knife suffice to raise the flap from the underlying parts, and it is then folded back upon itself, whilst the surgeon, feeling for the line of demarcation between the corpus spongiosum below and the corpora cavernosa above, transfixes the penis with a narrow-bladed bistoury between these two structures on a level with the base of the flap already raised; the blade of the knife is kept parallel to the under surface of the corpora cavernosa. The edge of the knife is then turned towards the corpora cavernosa, and these structures are severed completely at right angles to the long axis of the organ by a rapid sawing movement (see Fig. 11). The corpus spongiosum is then dissected down towards the tip of the penis for about ½ inch and cut across; this leaves the stump with the corpus spongiosum cut longer than the corpora cavernosa (see Fig. 12).

The bleeding proceeds chiefly from the dorsal artery, but occasionally

the arteries of the septum bleed freely; they are easily arrested by torsion or ligature, however. Before the flap is sutured in position it must be perforated to allow the urethra to pass through it; this is done by thrusting the knife through the flap at a suitable spot, and the urethra, divested of as much of the corpus spongiosum as possible, is pulled out through it (see Fig. 13). A few fine horsehair sutures secure the flap, and, in order to prevent circular contraction of the newly formed meatus, the urethra is split up with scissors on each side, and the superior and inferior lips thus formed are sutured to the opening in the skin through which it emerges.

FIG. 13. AMPUTATION OF THE PENIS. *The flap in position.*

No dressing is needed, if the bedclothes be kept from contact with the parts by means of a cradle; micturition will take place normally, and the parts should be bathed with warm boric lotion after the act. The wound should heal by first intention, but careful watch must be kept to see that no contraction of the newly formed meatus occurs; any tendency to this can be met by passing twice weekly a conical metal bougie 2½ inches long, and graduated in size from Nos. 8 to 11 English.

Removal of the inguinal glands. This should be done on both sides and as thoroughly as in the corresponding operation for cancer of the breast. A crescentic incision with its convexity downwards is commenced just below the external abdominal ring, carried outwards across the groin and up again to Poupart's ligament within an inch of

the anterior superior iliac spine; the lowest point of the incision should be about 3 inches below Poupart's ligament. The flap thus marked out is raised well up to Poupart's ligament; it is held back by an assistant while the glands are dissected out as far as possible in one mass. It will generally be advisable to tie and divide the internal saphenous vein just before it joins the femoral; the dissection should be carried up well inside the saphenous opening, and the gland occupying the crural canal should be removed also. Every effort should be made to remove the glands in one mass, and if the one in the crural canal be adherent it is better to abandon the operation, as this implies such widespread infection that little good is likely to result.

When the glands have been removed, the flap is replaced and sutured in position, with a drainage tube at the most dependent spot for the first twenty-four or forty-eight hours. There is often free oozing from the various veins joining the internal saphenous.

Difficulties and dangers. The operation is simple and presents few difficulties; the chief is hæmorrhage, but even though no tourniquet be used, this is not of any importance if the operator be quick in his manipulations. The author prefers to use no tourniquet, as the compression exercised by india-rubber tubing drawn sufficiently tight to stop the circulation is apt to give rise to severe bruising of the erectile tissue, ending in troublesome chordee. If the surgeon knows where to look for the vessels, *viz.* on the dorsum in the middle line and on either side of the septum about half-way down, the bleeding points can be picked up easily and twisted or tied. It is important to stop all bleeding before suturing the flap, as otherwise blood may be extravasated beneath it and prevent union. Some surgeons pass a bougie in order to define the urethra prior to the transfixion of the penis; this is not only unnecessary but objectionable, for the surgeon can always make out the whereabouts of the corpus spongiosum by touch, and passing a metal instrument down the urethra is very likely to carry infective material into the neighbourhood of the wound.

COMPLETE AMPUTATION OF THE PENIS

Indications. This operation is generally done for recurrent epithelioma of the penis. It is rare for a patient to neglect to seek advice for epithelioma before the disease has spread far. When, however, the mischief extends much more than an inch backwards from the corona, and certainly when it extends as far back as the peno-scrotal junction, it will be advisable to remove the organ completely in order to make sure of getting beyond the disease. This operation,

like the previous one, should always be combined with excision of the inguinal glands on both sides; it has the advantage that not only are the primary growth and the inguinal glands removed, but the whole of the cutaneous lymphatic tract is taken away also.

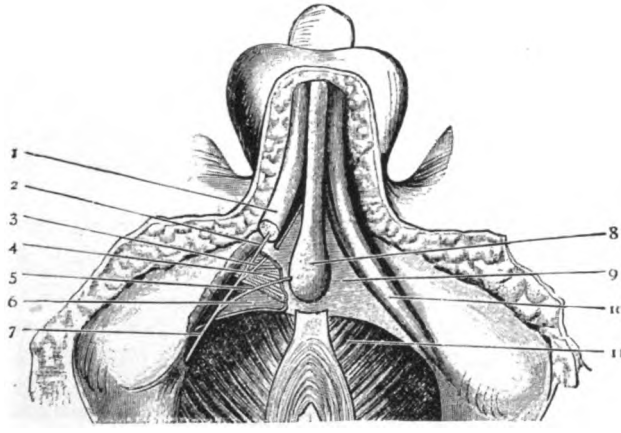

FIG. 14. THE PARTS CONCERNED IN AMPUTATION OF THE PENIS. *Superficial layer.* 1, Corpus cavernosum; 7, Pudic nerve with branches to the corpus cavernosum, 2, the dorsum of the penis, 3, and the bulb, 5; 4, Compressor urethræ muscle; 6, Triangular ligament (deep layer); 8, Bulb; 9, Triangular ligament (superficial layer); 10, Crus penis; 11, Levator ani muscle.

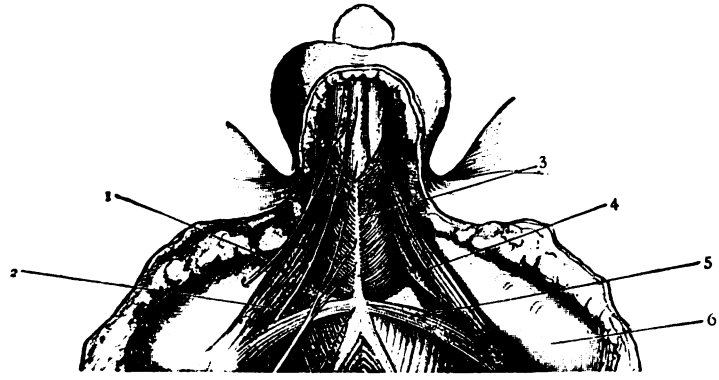

FIG. 15. THE PARTS CONCERNED IN AMPUTATION OF THE PENIS. *Deep layer.* 1, Perineal branch of the small sciatic nerve; 2, Anterior superficial perineal nerve; 3, Bulbo-cavernosus muscle; 4, Erector penis (ischio-cavernosus) muscle; 5, Transversus perinei muscle; 6, Tuber ischii.

The operation here described for complete amputation of the penis follows in the main the lines laid down by Mr. Pearce Gould (*Lancet*, 1882, vol. i, p. 821).

Operation. The parts are shaved and thoroughly purified from the hypogastric to the anal region, including also the upper third of each thigh; the compress put on overnight for purification of the front of the abdomen and thighs may remain undisturbed during the first part of the operation.

The patient is put in the lithotomy position and an incision is carried down in the middle line from the peno-scrotal junction to the mid-point of the perineum, and deepened until the corpus spongiosum is reached and defined. This should then be cut across well behind the growth

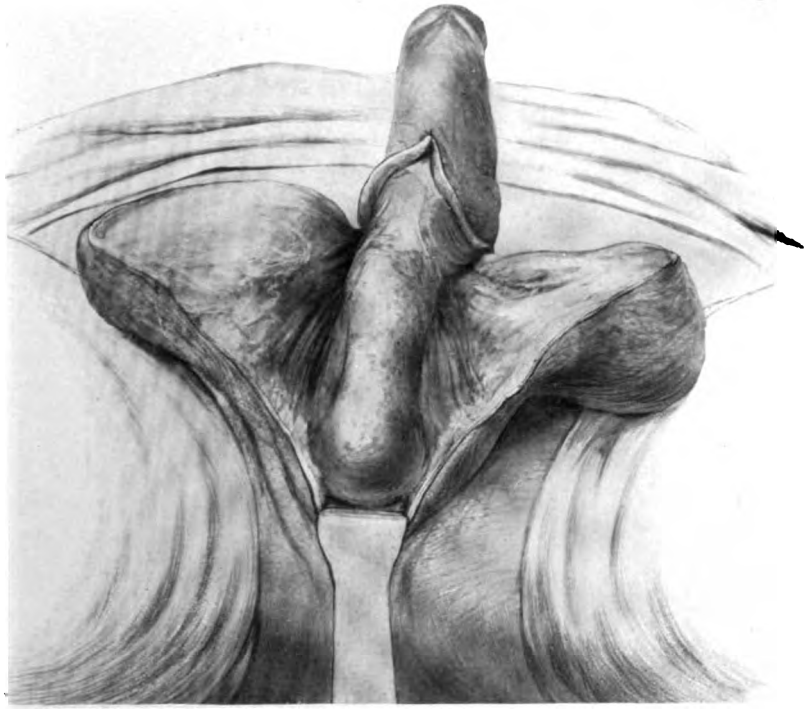

FIG. 16. COMPLETE REMOVAL OF THE PENIS. *First stage.* The scrotum has been split and the bulb exposed.

(which should be prevented from contaminating the wound by the measures described on p. *22*), and along the urethra is passed a steel sound which renders it prominent and enables the surgeon to dissect it away from the corpora cavernosa with a few touches of the knife as far as the triangular ligament; it is left hanging in the wound for future use. The surgeon now turns to the crura, which are traced downwards and backwards from the main body of the penis to their attachments to the rami of the pubes. Each crus is carefully and completely dissected off the bone throughout its full extent. The best instruments with which to

do this are stout blunt-pointed scissors and a Farabeuf's rugine; a good deal of oozing generally accompanies this part of the operation.

When the crura have been detached completely, the root of the penis is encircled by an elliptical incision which is carried up to the symphysis. The suspensory ligament is found and divided, and the penis is dissected downwards. The dorsal vessels are secured as they pierce the triangular ligament, and the whole organ can then be removed. The operation is

FIG. 17. COMPLETE REMOVAL OF THE PENIS. *Second stage.* The urethra has been cut across just beyond the bulb.

completed by removing the inguinal glands on each side, using for the purpose the incision described on p. 24. It is an advantage, however, in this case to make the incision so that the cutaneous lymphatic area between the penis and the inguinal glands is removed by it.

At the end of the operation the divided urethra is brought down into the perineum, cut off to an appropriate length, and stitched to the lips of the wound about an inch in front of the anus. The remainder of the incision is united throughout (see Fig. 19). It is best to insert a small drainage tube at the base of the scrotum for forty-eight hours; the latter should be enveloped in large dressings, but the region of the urethral orifice should be left free.

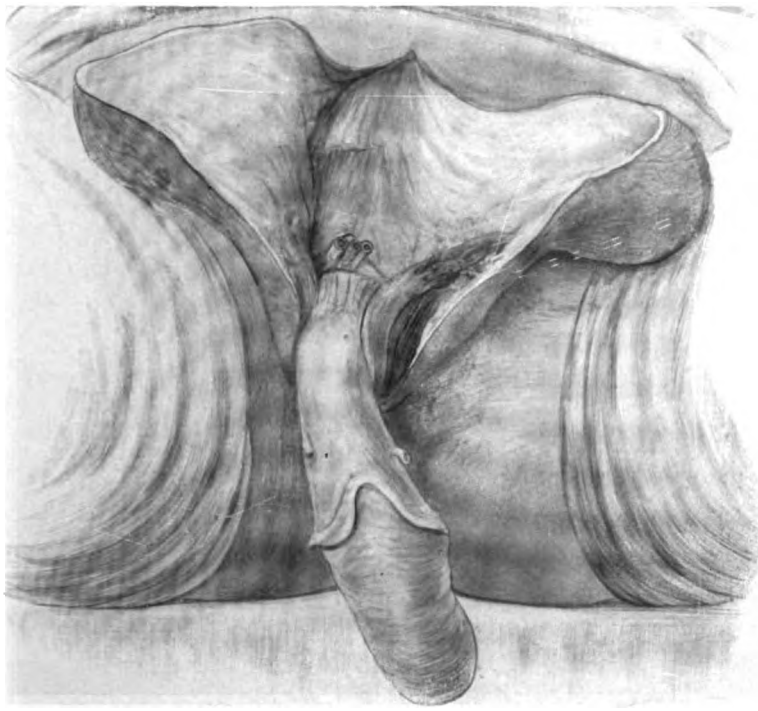

FIG. 18. COMPLETE REMOVAL OF THE PENIS. *Third stage.* The crura have been detached, the dorsal vessels of the penis secured and divided, along with the suspensory ligament of the penis.

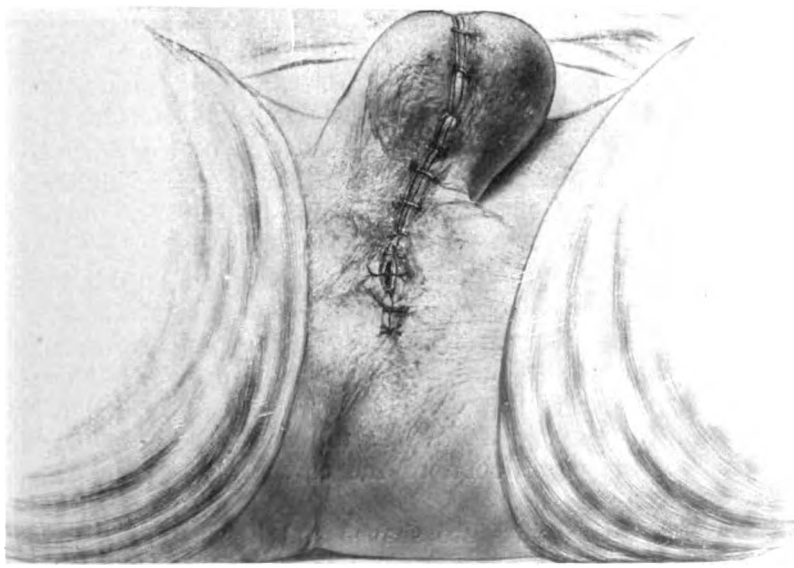

FIG. 19. COMPLETE REMOVAL OF THE PENIS. *Final stage.* The wound has been sutured. The orifice of the urethra is seen in the perineum.

CHAPTER II

OPERATIONS UPON THE SCROTUM AND CORD

THE RADICAL CURE OF HYDROCELE

Indications. (i) In all hydroceles in which a radical cure by other methods, such as the injection of iodine or carbolic acid, has been attempted unsuccessfully.

(ii) In all cases in which the sac-wall is much thickened, or in which the hydrocele is not translucent. Here the milder injection methods are almost sure to fail, and it is better to perform the excision operation without having recourse to them.

(iii) In all cases in which the patient is very anxious to make sure of a radical cure without delay. By adopting the method described below, a radical cure at the end of a few days can be promised with reasonable certainty.

Only two methods of operating call for special remark: they are excision of the parietal layer of the tunica vaginalis, and eversion of the tunica vaginalis. Of these the former, which aims at removing all the removable part of the tunica vaginalis which is the primary seat of the trouble, is obviously the sounder in principle, whilst it is undoubtedly the more satisfactory in practice. Eversion of the tunica vaginalis, as its name implies, aims at turning the tunica vaginalis inside out and fastening it in that position by a few sutures. This has the objection that, whilst it entails nearly as extensive a cutting operation as the other, it does nothing to diminish the secreting area. Since recurrences have been known after imperfectly performed excisions of the tunica vaginalis, it follows that the eversion method is likely to be inferior to the other, while cases have occurred in which the sutures used to retain the tunica vaginalis in its everted position have given rise to troublesome constriction of the cord: this method, therefore, will not be described.

Operation. The parts are shaved and thoroughly purified, and the penis is wrapped in a sterilized cloth and kept out of the way. The skin of the scrotum is made as tense as possible, as in puncturing

a hydrocele, and a vertical incision is made over the upper and front part of the scrotum just of sufficient length to enable the enlarged scrotal contents to pass through it in its stretched condition. The anterior surface of the hydrocele is then carefully cut down upon, the object being to divide the successive coverings of the testis evenly and equally throughout the length of the wound, without opening the cavity of the tunica vaginalis itself; this demands a sharp knife and a light touch, but it facilitates the steps of the operation greatly, as premature opening of the hydrocele leads to collapse of its walls and to greater difficulty in identifying and removing the parietal layer. As the layers are divided, the hydrocele with the testicle are gradually squeezed out of the wound and are received in a sterilized cloth and thus shut off from contact with the scrotum below and behind it. When the surgeon recognizes that he has cut down to the tunica vaginalis itself, all the coverings superficial to it are stripped off with a flat blunt dissector as far back around the hydrocele as possible, the object being to clear the tumour right up to the reflection of the tunica vaginalis on to the testicle, while the sac is still distended with fluid and thus easily definable.

The tunica vaginalis is now opened up and the fluid allowed to escape, the margins of the incision are held aside with catch-forceps, and the entire parietal layer of the tunica vaginalis is clipped off right up to its reflection on to the epididymis; care is required to define this line exactly, especially at the globus minor. As a rule there is little bleeding during the division of the coverings of the hydrocele; there is, however, fairly free oozing from the cut surface of the reflected tunica vaginalis, and this must be arrested carefully. A number of ligatures will be required, and, if necessary, adrenalin may be applied to the oozing surface. It is also useful to swab over the visceral layer of the tunica vaginalis with undiluted carbolic acid; the author always adopts this as an additional precaution against recurrence.

The testicle, which now shows the appearance depicted in Fig. 20, is returned inside the scrotum, the wound in which has so contracted that it is only just large enough to admit it. A fine drainage tube should always be inserted, as otherwise a very unpleasant scrotal hæmatoma may result and may lead the patient to think that his hydrocele has not been cured. The wound should be secured by two or three fine horsehair or silkworm-gut sutures, between which Michel's metal clips may be inserted. A continuous suture should not be employed, as the scrotum contracts so as to render proper approximation with a continuous stitch uncertain.

The drainage tube should be secured in place by a suture or a safety-

pin, as otherwise it may slip into the scrotum and be lost. A large mass of dressing should be applied and should be bandaged on tightly so as to exercise a certain amount of pressure upon the scrotal tissues.

The drainage tube may be removed at the end of twenty-four hours, when it is a good plan to apply a collodion dressing, which keeps the scrotum well contracted, so that there is less fear of hæmorrhage occurring into it. The scrotum should be supported on a pillow, and the patient should remain in bed for at least five days after the operation; he may then get up, wearing a suspensory bandage, but should keep quiet for a few days longer.

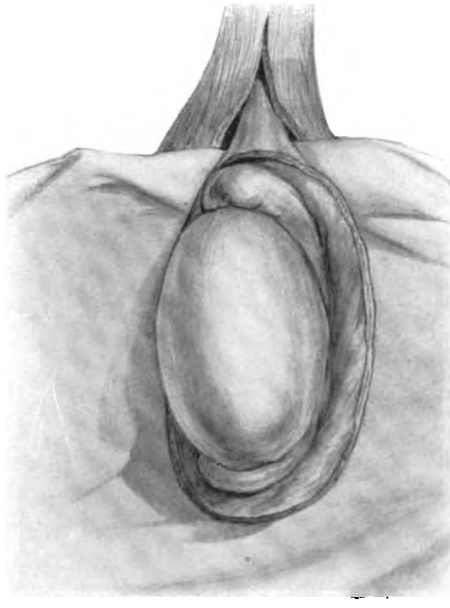

FIG. 20. EXCISION OF THE TUNICA VAGINALIS FOR THE RADICAL CURE OF HYDROCELE.

Complications. The chief complication to be feared is the occurrence of free venous oozing into and between the various scrotal coverings, which causes a large diffuse hæmatoma; the best way of avoiding this unpleasant and fairly frequent complication is to follow strictly the steps of the operation given above, cutting straight down to the tunica vaginalis before any attempt is made to strip the soft parts off, and then to strip the coverings off the tunica vaginalis *en masse* before the latter is opened. This avoids tearing up the coverings unduly, which is a frequent cause of a diffuse hæmatoma. It is also essential to stop all bleeding before the wound is closed, and great care should always be devoted to this; finally, the introduction of a drainage tube is essential if the surgeon is to make sure of avoiding a hæmatoma.

Results. The results of the operation may be said to be eminently satisfactory; the author has never known a case of recurrence in his own practice, nor has he ever met with a case in which a patient sought relief for recurrence after this operation had been performed by another

surgeon. Septic complications are extremely unlikely to occur, especially if undiluted carbolic acid be used as recommended above; healing is rapid, and the patient is generally well by the tenth day.

BOTTLE OPERATION

Andrews has revived interest in the bottle operation, the technique of which is as follows:

An incision is made over the spermatic cord at the inguino-scrotal junction. This incision is carried down to the structures of the cord. The length of the incision depends upon the size of the hydrocele sac. By blunt dissection, preferably with the tip of the gloved finger, the structures of the cord and hydrocele sac with the testis are removed from the scrotum. In the case of a large hydrocele it is preferable to withdraw the fluid, thus not necessitating such a large skin incision. After the tumour has been displaced from the scrotum, an incision is made into the hydrocele sac, draining off all the fluid and turning the testicle through the opening. In the case of excessively large sacs a portion of the sac may be excised. A few stitches are placed to keep the sac everted, thus retaining the testicle out of its former tunica vaginalis. The testicle is then replaced without covering into the scrotum and the wound is closed without drainage.

OPERATIONS FOR VARICOCELE

The radical cure for varicocele aims at the obliteration of as many of the branches of the pampiniform plexus as possible, leaving only a sufficient blood-supply to the testicle to ensure its proper nutrition. Ligature and excision of the veins is the only operation that needs consideration here.

Indications. (i) *For all persons suffering from varicocele who desire to enter the public services.* To these the presence of varicocele is a bar, and the operation is therefore a necessary preliminary.

(ii) *In cases where there is a history of recurrent attacks of phlebitis and thrombosis* in a varicocele which otherwise does not give rise to many symptoms. It is essential here to remark that the operation should be done during a quiescent period, as otherwise a troublesome spreading thrombosis may occur at the seat of the ligature.

(iii) *In certain cases of sexual hypochondriasis associated with the presence of varicocele.* These cases need the most careful discrimination and the most cautious prognosis; but it occasionally happens that a patient suffering from a varicocele gets the most extravagant notions

as to the serious and progressive nature of his complaint, and nothing will satisfy him but the removal of the diseased veins. It is true that these cases generally suffer from other neurotic affections either before or after the operation, which is by no means always advisable for all melancholic individuals who are the subject of a varicocele; it is only when the varicocele assumes undue importance in the patient's eyes that its removal will be called for.

(iv) *When the patient is about to proceed to a hot damp climate where he will be out of reach of surgery for a considerable time.* Here the operation may be a justifiable and useful prophylactic.

Operation. The operation is extremely simple and satisfactory if properly done, but mistakes may be made which may seriously interfere with the patient's progress, and may even endanger his life. The most rigid attention to asepsis is necessary throughout; the purification of the genital area should always be attended to most carefully, and it is a good plan to fasten the penis out of the field of operation by passing a suture through the prepuce and attaching it to the skin of the opposite thigh. The greatest care must be taken to see that the material with which the veins are ligatured is aseptic, and any surgeon who has the least doubt as to the reliability of his catgut had better employ fine silk, which should be boiled for at least a quarter of an hour immediately before the operation. Another point of much importance is to avoid unnecessary hæmorrhage. The secret of success in this operation is to attack the veins high up, where they are not only converging to form a few main trunks, but are also lying in a defined tube of fat and fascia distinct from the vas; here they may be surrounded with a ligature without much risk of bleeding.

An incision 2 inches long is made with its centre over the lower edge of the external abdominal ring, which can always be identified, and through which the cord can be felt escaping; the incision should never be lower than this. The cord is recognized immediately the superficial fascia has been divided and, after its superficial coverings have been carefully cut through by incisions parallel to its long axis, the whole cord is hooked out either with the finger or on an aneurysm needle. The bundle of veins is isolated from the vas, secured with two stout ligatures placed about an inch apart, and the intervening portion removed with scissors. The ligatures may be made to transfix the cord if this be very bulky, but when there is not much fat it is quite safe to encircle the veins in a single loop. There is little likelihood of the ligature slipping if care be taken to divide the vessels some little distance beyond it. The vas always retains sufficient blood-supply if the

normal line of separation between the veins and the vas be followed and the latter structure be not dissected off too cleanly.

The testicle now hangs supported only by the vas, and to prevent too great a dragging on this, it is the general practice to leave one end of each ligature long and to tie these loosely together; or a suture may be passed through the structures of the cord beyond each ligature and fastened. All bleeding is arrested and the wound is sewn up with a few horsehair sutures. No drainage tube is necessary if care be taken to arrest the hæmorrhage, and if no tearing of the veins has taken place during the operation. Good firm pressure is applied over the wound by dressings kept in position by a spica bandage. The patient is usually in bed for about a fortnight.

OPERATIONS UPON THE VAS DEFERENS

VASECTOMY

This operation was at one time practised as a substitute for castration for the cure of enlarged prostate, but has now fallen so completely into disuse that it is unnecessary to describe it here; its place has been taken by enucleation of the prostate, which is more certain in its action and more favourable in its results.

VASORRHAPHY

Indications. (i) Immediate suture of the vas is necessary should that structure be divided in the course of an operation affecting the cord, such as a radical cure of hernia or varicocele. In the author's experience this accident is most likely to occur in the operation for radical cure of inguinal hernia in young children. In them the vas is very delicate, often runs a tortuous course, and has a very intimate connexion with the hernial sac; consequently it is liable to be divided when the sac is separated from the constituents of the cord. In an adult who is the subject of a recurrent inguinal hernia, it is often difficult to avoid damaging the vas during the second operation for radical cure, since the tissues of the cord are often densely matted together and the whereabouts of the vas may be a matter of uncertainty until it has been divided accidentally.

(ii) Rupture of the vas by an injury rarely occurs, and is very difficult to diagnose when it happens. A plastic operation, however, should be done with the object of restoring the continuity of the vas if the condition be recognized. The operation would still be called for if the diagnosis were only made some considerable time after the receipt of the injury.

The author has twice had to repair a vas deferens accidentally divided in the course of an operation for radical cure of hernia. The first case

was in a young child, the second in an adult during a radical cure for recurrent hernia after a previous operation followed by profuse suppuration. Both operations were successful in the sense that accurate adaptation of the sutured ends was effected and that no atrophy of the testis had occurred two years after the operation; the functional condition of the organ, however, could not, of course, be ascertained.

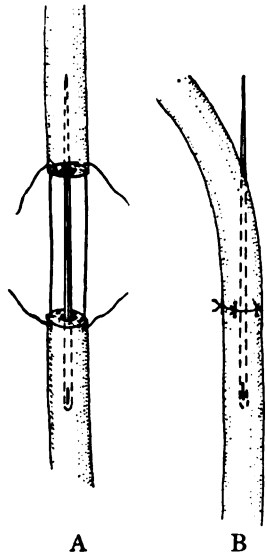

FIG. 21. ANASTOMOSIS OF THE VAS DEFERENS. A shows the needle *in situ* and the sutures introduced; B shows the operation completed, before withdrawal of the needle.

In each case the method employed was the one described below, for the main idea of which the author is indebted to the account of a case recorded by W. J. and C. H. Mayo in the *Annals of Surgery*, 1895, vol. xxi, p. 35. Several other methods have been described and figured, but the vas is such a small structure, and its lumen is so minute, that those plastic operations based upon the splitting open of one end and the implantation of the other into it are attractive only in theory; in practice they are of little use.

Operation. The cut ends of the divided vas are sponged clean of blood and a fine, straight, round intestinal or common sewing-needle is introduced, eye first, down the lumen of one of its divided ends. It is immaterial which end is chosen, but the needle employed must be of such a size that it can just be passed down with fair ease, and that when an inch of it is in the lumen of the vas it is a moderately tight fit. The point of the needle is now introduced into the lumen of the other end of the cut vas, and the latter is threaded over it (see Fig. 21, A). The point of the needle soon pierces the wall of the vas and is allowed to protrude from it, and then the two ends are pushed together until they meet; the lumen on each side of the division is thus in accurate apposition. It now only remains to secure the ends in place while they are on the needle (see Fig. 21, B). Four sutures of the finest catgut obtainable, threaded upon correspondingly small needles, are introduced at each of the four cardinal points. This secures the ends, but for greater safety it is well to wrap them round in the fibrous tissues of the cord as in a sort of splint, securing this with a fine catgut stitch.

The vas is now laid down in place and the tissues are brought together over it with fine catgut sutures; the needle is then withdrawn

from the vas by traction upon its point and the skin wound is stitched up without a drainage tube. W. J. and C. H. Mayo used catgut knotted at the points where the thread emerged from the vas, while Lydston (*Annals of Surgery,* vol. xliv) used silkworm-gut for threading through the lumen of the vas; the end of this was brought out either through the skin or into the wound, and it was left in position for about ten days and then removed by traction. In the brothers Mayo's case the catgut of course remained *in situ* until it was absorbed. The reason why the needle is preferred by the author is, that it is easier to thread down the lumen of the vas, it is stiffer to work upon, and so makes a most excellent temporary splint, while if it be left in position until the soft parts are sutured over the vas, there appears to be no necessity to maintain any foreign substance as a splint *in situ* any longer.

CHAPTER III

OPERATIONS UPON THE TESTICLE

ORCHIDOPEXY

Indications. (i) In all cases of retained or misplaced testis in which the organ does not descend lower than the entrance of the scrotum.

In children it is common to find the testis suspended near the external abdominal ring, but capable of being pulled down to the bottom of the scrotum, only to slip up again directly the traction is relaxed. These cases should never be operated upon unless the condition be complicated with a hernia, at any rate before puberty; as the onset of puberty occurs, the organ becomes heavier, the cord stretches, and the testis tends to assume its normal position at the bottom of the scrotum. Should puberty pass without the testis assuming its normal position, however, operation is advisable.

(ii) In every case of misplaced or retained testis in which there is a coexisting inguinal hernia.

The age at which the operation should be done is of considerable importance. If possible it should be performed before the onset of puberty, since the testis ought to be in its normal position by the time it is assuming its virile characters. At the same time the child must be old enough to obey orders and to be quite clean in his habits, as the least sepsis is fatal to the success of the operation. On the whole, eight or nine is perhaps the best age. The operation may be done after the onset of puberty, but in that case more difficulty is experienced in bringing the testis down into position, there is more chance of want of development from deficient blood-supply afterwards, and there is considerably more discomfort occasioned by the after-treatment.

Choice of operation. There are three operations at the surgeon's disposal: *viz.* complete removal or castration, permanent incarceration of the testis within the abdominal cavity, for which the fanciful name of 'orchido-cœlioplasty' has been coined, and true orchidopexy or suture of the testis into its normal position. Of these methods the author invariably chooses the last in every case in which it is possible, and he has not yet met with a case in which it is impossible. Castration was formerly practised under the erroneous impression that

retained testes were always functionally useless. The author long ago discovered the inaccuracy of this view when examining a retained testis removed in the course of a difficult radical cure of a hernia in a man of 55. The testicle contained large numbers of active spermatozoa and showed no other signs of abnormality than its small size. Since then there has been an opportunity of examining four other adult retained testes, and in all of them active spermatozoa were present. Castration is therefore clearly unjustifiable in this affection.

In 1892-3 the author, in five cases, made use of the method which is now termed orchido-cœlioplasty, and which he then believed to be original with him, *viz.* placing the testis inside the abdomen and closing the abdominal ring. The operation seemed a good one and the immediate results were promising, but luckily its weak points became apparent before enough cases had been operated upon to justify its publication. Two years after operation an adult patient contracted gonorrhœa, and the attack of acute peritonitis that accompanied the gonorrhœal epididymitis in the affected organ led to the decision that, should circumstances ever demand inclusion of the testis in the abdominal cavity again, division of the vas should accompany it. A second case—a schoolboy, aged 11—showed another weak point in the operation. About eleven months after the operation he was kicked in the abdomen, and an alarming attack of peritonitis followed, and a large localized swelling, which turned out to be a hæmatocele, ensued. In a case operated upon by a colleague, an acute hydrocele formed during a severe attack of bronchitis, and this gave rise to acute peritonitis.

This method, therefore, should be reserved for those cases in which true orchidopexy (*vide infra*) cannot be performed, and in doing it particular care must be taken to see that the testis is returned well inside the abdominal cavity and not only just inside the internal ring. In the latter situation it is not only very liable to injury, but it may act as a dilator in forcing the internal ring and producing a hernia. It also seems advisable to divide the vas in order to avoid the possibility of the spread of infection from the urethra. Division of the vas is not followed by atrophy of the testis if the vessels and nerves be left intact; it only entails loss of procreative power in the organ affected.

The third method, *viz.* orchidopexy, is the one that an increasingly large experience, both in children and adults, shows to be the best. It is true that it has had many objections urged against it. The chief of these are put forward by Mr. E. M. Corner (*Diseases of the Male Generative Organs,* The Oxford Medical Manuals, 1907, p. 88), and are as follows:—

After quoting 'a recent' (but in the author's experience quite in-

accurate) estimate that perfect success followed the operation in 30% of cases between the ages of 5 and 13 and only 10% at later periods of life, he states that the testicles thus sutured 'have not the necessary congenital capital to develop fully; they must always remain small.' While, owing to a slight uncertainty as to what 'congenital capital' may be, the first part of this statement must necessarily be a matter of opinion, the second is one of fact, and the author has seen many cases, some nearly twenty years after the operation, that disprove it. The second objection advanced is that 'the cord must be freed; a proceeding not without danger to the vessels, injury to which means non-development of the gland.' In a properly performed operation the vessels are certainly not interfered with to such an extent as to lead to non-development subsequently, and those who have had much experience in the wide removal of veins in varicocele operations will agree that in them the vascular supply of the testis may be quite as much interfered with as in cases of orchidopexy without any risk of non-development ensuing. In orchidopexy the testis often hangs from a slender stalk consisting of the vas and its vessels only, but in the author's experience this operation has never been followed either by sloughing or non-development.

The third objection is that the cord, which has been freed in order to draw the testicle down, must cicatrize, and will be likely to pull the gland upwards again. Exactly how this is to be effected it is difficult to discover. If it be inferred that, owing to the formation of granulation tissue, the cord will contract in the vertical direction only, the important fact is overlooked that cicatrization will occur all around the cord, and this will cause it to form adhesions right down to the bottom of the scrotum, which should effectually prevent retraction. The fourth objection is that vessels not directly severed at the operation may be stretched so tightly as to impede the return of blood through them, and that, further, their walls may be so damaged as to lead to post-operative thrombosis. Whilst not denying the possibility of these accidents, the author would suggest that they are not altogether unconnected with sepsis, which is well known to have been a great foe to this operation in its early days. The same remark applies with still greater force to the fifth and last objection, which is that the sutured testicle is very prone to suffer some subacute or chronic orchitis 'as a result of the impeded vascular return.' This condition occurs after operations upon the testicle no doubt, but its cause is generally sepsis and not a mere mechanical one.

Against this very formidable array of objections may be placed the fact that the author has never seen a case of sloughing or atrophy of the testis in the many operations that he has performed in adults and

in children, and although the majority of cases have not been followed up sufficiently carefully to warrant any statistical statement of the results, yet the uniform success obtained in those that have been seen years after the operation leads him to recommend the operation to those who are sufficiently sure of their aseptic precautions to warrant them performing it.

Operation. A slightly oblique incision about 1 inch in length is made parallel with the long axis of the inguinal canal just over the external abdominal ring, and the structures covering the cord are exposed and the testis is identified. The coverings of the cord are divided by an incision parallel with that through the skin until the tunica vaginalis is reached and opened. In practically all cases this is continuous with the peritoneal cavity, and often contains a hernia. The testis is now lifted out of its bed, and it and the vas are freed as far up as the internal abdominal ring. The testicle is pulled upon in order to see how far down it can be pulled; this will put upon the stretch a portion of the processus vaginalis, which must be divided by careful snips of the scissors, thus allowing the vas to straighten. The latter structure is generally long enough to allow the testicle to reach to the bottom of the scrotum, but it runs a tortuous course, the real factor impeding the descent of the testis being the shortened processus vaginalis and the tube of fascia containing the pampiniform plexus, which will need to be divided to the extent requisite to allow the testicle to be brought down; it is often necessary to divide all the vessels except the artery of the vas and its companion veins, and the testis has therefore a very narrow pedicle. When the testicle has been brought down as low as this manœuvre will permit, it sometimes happens that it is necessary to separate the vas from the back of the epididymis and thus to invert the testis, making the globus major the lowest portion of the organ; this, however, is not usually necessary.

The next step is to make a bed for the testis in the corresponding undeveloped half of the scrotum. This may be done by thrusting the index-finger through from the wound down into the bottom of the scrotum. This gives room enough for the testis to be inserted, but it will not remain in position there unless some method of tethering it in position be employed. After trying various methods, the author has found none so convenient or so simple as the wire frame introduced by Sir Watson Cheyne (see Fig. 22). In order to secure the testis to the transverse bar of this apparatus a medium-sized silk thread is passed through the tissues at the bottom of the organ, taking care not to transfix the epididymis. The two ends of this suture are then threaded together into the eye of a large straight needle, which is passed down along the finger introduced into the newly-made cavity in the scrotum and is made

to emerge from the bottom of the scrotum at its lowest limit. The needle is then unthreaded and the two ends of the silk thread are pulled upon and thus made to draw the testicle down as far as it will come. The ends of the thread are now passed round the transverse bar of the wire frame and tied in a bow. When replacing the testicle in the scrotum before making traction upon the ligature, it is important to see that the vas is not twisted, as otherwise gangrene of the testis may occur.

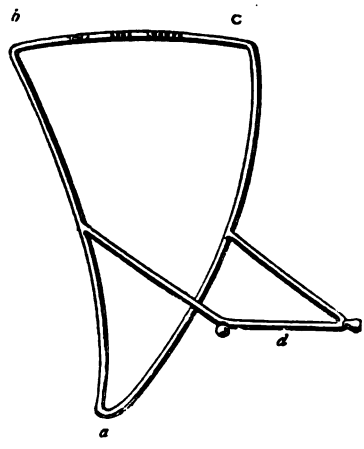

FIG. 22. CHEYNE'S TESTICLE FRAME. The suture is fastened to the transverse bar *d*. Sterilized tapes are fastened to the points *a*, *b*, and *c* to keep the frame in position; *a* rests on the mid-point of the perineum, *b* and *c* on either side of the mid-line in the hypogastric region.

When the testicle has thus been secured, every oozing point should be tied with fine catgut, and the skin wound closed without a drainage tube. The ordinary dressings are applied to the affected side of the scrotum and the point through which the ligature emerges from it.

The patient should stay in bed for a fortnight, and careful watch is kept upon the ligature to see that it is always tight. It is a good plan to increase the tension slightly every second day by untying the knot and refastening it. Sometimes the traction causes the silk thread to cut its way out about the tenth day: if this does not occur, it may be pulled through by traction upon one end.

It has been definitely proven that the vas in practically all cases is of sufficient length but that the testicle may be held up by the spermatic artery and veins. If it is impossible to get sufficient length to the cord structures, Bevan has suggested that the spermatic artery and veins be transected, thus allowing the testicle to be placed in the pocket previously prepared in the scrotum. The internal oblique and conjoined tendon are sutured to the shelving portion of Poupart's ligament over the vas and the separation of the external oblique sutured.

It should be remembered that an undescended or misplaced testis is usually atrophic; the destruction of the greater part of the blood supply by dividing the spermatic artery tends to further devitalize this highly organized structure. Wolfer has advocated a modification of the technique as described by Bevan as follows:

The inguinal canal is opened as in the Bassini operation for the cure

of inguinal hernia. A pocket is then prepared in the scrotum by stretching the parts with the fingers and packing a large piece of gauze into this fossa, leaving it in position until the testis is prepared. The testis is then found, and here, at times, some difficulty is encountered. If the organ

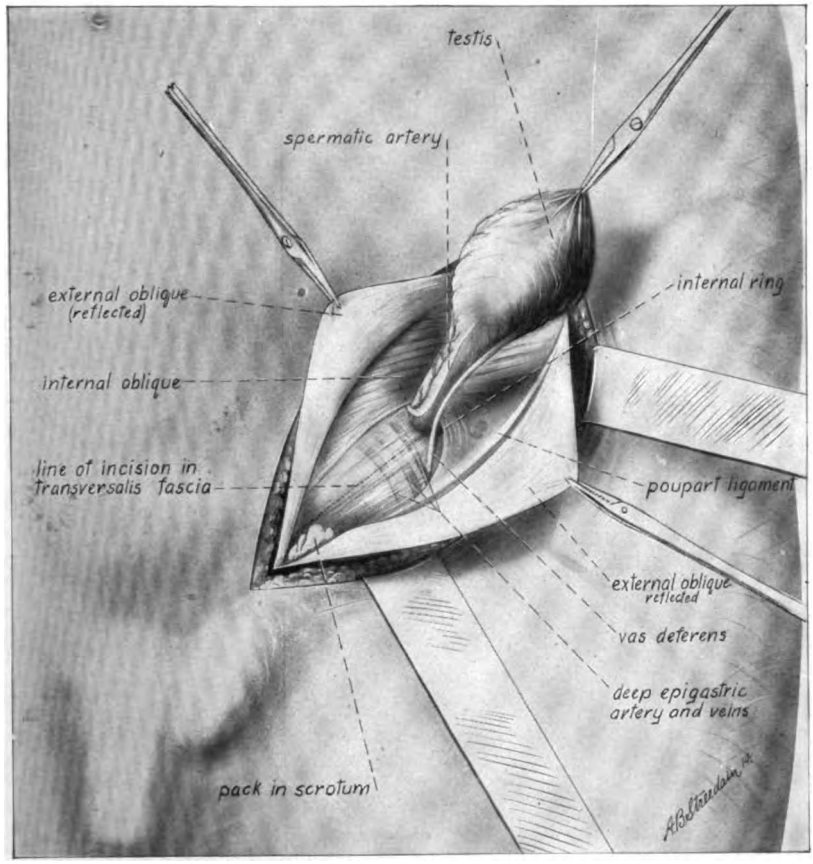

FIG. 22A. OPERATION FOR UNDESCENDED TESTICLE. Showing testicle freed, the gauze pack in scrotum, position of deep epigastric vessels, and the course of the vas and the spermatic artery. (*Wolfer.*)

lies within the internal ring, it may be hard to reach. The ring may have to be enlarged, but usually the testicle can be delivered by picking up and freeing the structures emitting from the internal ring—the remnant of the gubernaculum ligament—using gentle traction on them and pressure on the abdomen just above the inguinal region. The cord is then freed, separating the vas from the rest of the structures. It will be

readily seen that the vas leads downward and to the median side, while the other structures lead upward and outward.

The deep epigastric vessels, usually two veins and the artery, are readily found lying in the transversalis fascia, just median to the internal

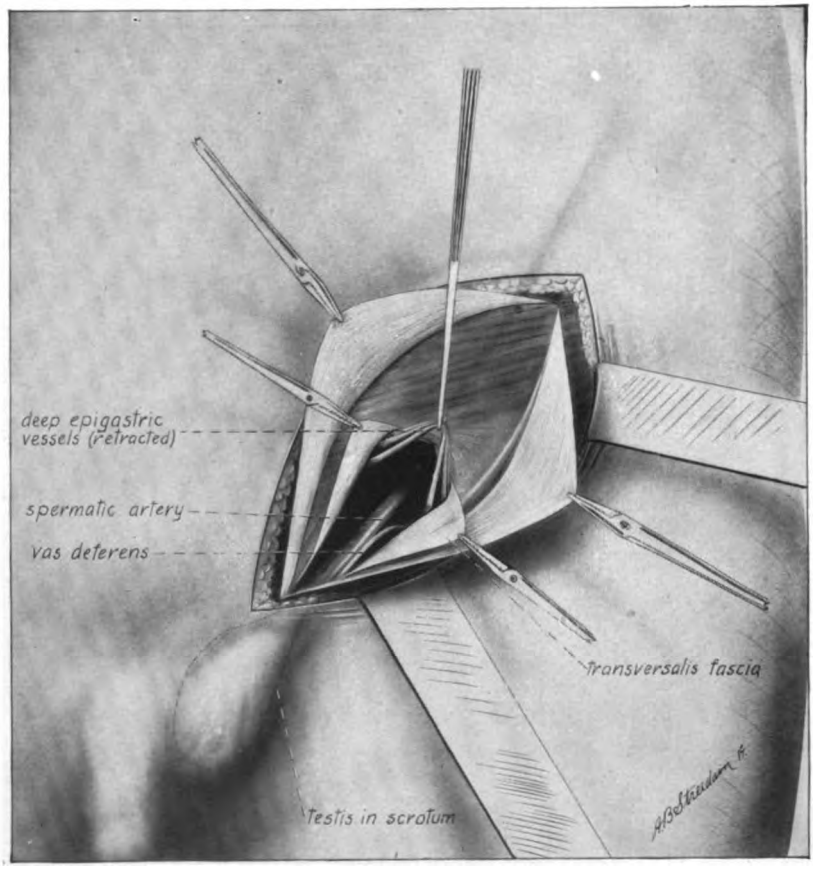

FIG. 22B. OPERATION FOR UNDESCENDED TESTICLE. Shows testicle placed in pocket in scrotum. (*Wolfer.*)

ring (see Fig. 22A). By blunt dissection these vessels are easily freed and held out of the way with a blunt hook. The transversalis fascia is then cut down to the pubes. The testis is drawn behind the deep epigastric vessels. The vas will now follow down behind Poupart's ligament. The structures which extend upward and outward are freed from the peritoneum and dealt with as in the Davison operation—pushed behind the bulge of the peritoneum. Here care must be exercised, as quite often the peritoneum is thin and easily torn. Again, when a

hernial sac is present and it has been excised, the ligature may tear off by tension and the peritoneum is torn before one becomes aware of the fact. Congenital herniæ quite often are found associated with undescended testes. In these the sac is separated from the spermatic structures and enough of it is reserved to make a tunica vaginalis for the testicle, the rest being ligated and excised. When, by posterior displacement of the spermatic structures, sufficient length has been given the cord to allow the testis to be placed in the lower part of the scrotum, the gauze pack is removed from the scrotal fossa and the testis placed in the pocket prepared for it (see Fig. 22B).

Wolfer has not found it necessary to fasten the testis in the scrotum aside from placing a catgut suture from the periosteum and tissues over the pubic spine to the inner border of Poupart's ligament; in other words, the testis is simply retained in the scrotum by obstructing the scrotal outlet. Instead of using fascial flaps to enlarge the scrotum, as suggested by Thompson, Wolfer simply insists on the patient massaging and stretching the tense wall several times daily after the wound has healed, thus giving the testis ample room.

EPIDIDYMECTOMY

Indications. Epididymectomy, or excision of the epididymis, is only called for in certain cases of tuberculous disease of the testis. The merits of this operation and its indications have been much disputed, and even at the present day its exact position cannot be said to be defined. The plan of performing early castration for unilateral tuberculous disease of the testis is rejected by many surgeons in favour of the more logical one of excising the tuberculous area in the affected organ, mainly on the ground that it is thereby possible to remove the tuberculous disease radically without any risk of destroying the internal secretion of the testis; a matter of importance should the opposite testicle eventually become destroyed. More recently still, however, there is a tendency to dispense with even so limited an operation as this, and to employ curettage of the affected area combined with open-air treatment and the injection of tuberculin. A review of personal experience and a study of the literature on the subject indicate the following as the principal conditions for which the operation may be required:—

(i) All cases of tuberculous disease attacking the epididymis of the remaining testis after removal of its fellow. Castration is out of the question here, since the patient would be deprived thereby of the secretion of his remaining testis. The only alternative to epididymectomy is incision and scraping combined with treatment by tuberculin.

(ii) When there is advanced tuberculous disease either in both testes or in the survivor of two, the operation may be performed in combination with scraping or excision of tuberculous foci from the body of the testis. In these cases the results are not very satisfactory, but the operation is to be preferred to castration, which entails the loss of the internal secretion of the testis.

(iii) In early cases of unilateral or bilateral disease strictly limited to the epididymis, where there is a prospect of removing the disease completely without sacrificing the testicle.

In both of these last two groups of cases the great difficulty is to determine whether the body of the testis be affected or not, and it is probable that some of the unsatisfactory results recorded after the operation are due to the fact that the epididymis alone has been removed when the body of the testis has been affected simultaneously. Since a proper selection of cases is essential for successful treatment, and since it is impossible to tell by palpation whether the body of the testis be affected or not, the author has been in the habit for the last two years of incising the body of the testis freely in order to ascertain this point. He was led to it partly by the considerations just mentioned, and partly by noting that, in cases of wounds of the body of the testis in which the organ is split completely open, there is no apparent bad after-result after suture of the cut edges of the tunica albuginea. The practice has been to incise the tunica albuginea freely, so as to split open the body of the testis much in the same way as the kidney is explored; this enables the operator to see at once whether there be any affection of the body of the testis; if so, appropriate measures can be adopted. Under these conditions epididymectomy becomes as sound and radical an operation as castration itself, while it is free from the serious results that may follow the latter operation. Mr. R. J. Godlee, in his Bradshaw Lecture on 'Tuberculosis of the Genito-Urinary Organs' (*Brit. Med. Journ.*, 1907, vol. ii, p. 1702), says: 'I have given up removing every tuberculous testicle, however quiescent, if no sign of the presence of tubercle could be found elsewhere, because it has so often led to disappointment, the patient returning before long with the opposite testicle affected. I do not hesitate to remove one testicle which is completely disorganized, both body and epididymis, if it is causing much pain or inconvenience, and under such circumstances would take away as much of the vas as can easily be got at; but in most cases removal of the epididymis appears to be the better practice and equally efficacious. Thorough curetting often gives excellent results.'

Numerous statistics have been prepared to show the relative frequency with which tuberculous disease occurs in both testicles, but these are

very conflicting, and it is certain that the disease may recur in the opposite testicle in spite of early castration. It is therefore of little value to quote statistics as to the relative frequency of recurrence after epididymectomy and after castration. There is probably not much difference in this respect between the two operations. A more important point is the frequency with which the body of the testis is implicated by the time that the mischief in the epididymis is sufficiently pronounced to be detected. The best series of figures is given by Réclus, who found by post-mortem examination that both portions of the testis were involved in 48 out of 68 cases. This high proportion may surprise those who have been in the habit of merely palpating these cases and finding the lesion apparently limited to the epididymis in the large majority of cases. The author confesses, however, that since he has had the opportunity of obtaining more precise knowledge by laying open the body of the testis, his opinion upon the matter is much more in accord with Réclus' statistics.

Operation. An incision from 2 to 3 inches long is made over the front of the scrotum parallel with the long axis of the testicle. If any portion of the skin be adherent, or if there be a sinus present, the affected area is enclosed in two elliptical incisions and removed. The tunica vaginalis is opened and the testicle is exposed. Removal of the epididymis is usually easy when there is no tuberculosis of the body also; the important point is to preserve the blood-supply of the testis derived from the internal branch of the spermatic artery, which reaches the body of the testis in the angle between it and the epididymis at the upper part of its inner aspect. The reflection of the tunica vaginalis binding the globus minor to the body of the testis is divided on each side with a knife or scissors, and the epididymis is peeled up from the back of the body of the testis until the globus major is reached, when the vas deferens is divided on a level with the upper border of the testicle, care being taken to free it entirely from the vessels before this is done. The globus major is peeled off the body of the testis as completely as possible, after dividing the tunica vaginalis on each side; its actual connexion with the testis is ligatured and the epididymis is then cut away completely.

The body of the testis is now incised vertically along its posterior aspect; the incision need not extend more than a third of the distance through the organ unless tuberculous deposits be encountered. Incision of the tunica albuginea at once displays any tuberculous infection present, and the affected area can be clipped out cleanly with fine sharp-pointed scissors.

The edges of the divided tunica albuginea are brought together with

a few fine catgut sutures, all bleeding points are ligatured, and a small drainage tube is inserted down to the bottom of the scrotum, the wound in which is secured by interrupted silkworm-gut or Michel's metal sutures. The drainage tube is removed in the course of twenty-four hours.

CASTRATION

This is an operation which should not be undertaken lightly. There are two distinct ill results produced by the removal of a testicle: one is the loss of procreative power, the other the loss of the internal secretion of the testis with its important psychological sequelæ. Neither of these results is serious provided that only one testicle be removed; the seriousness of the case lies in the fact that the other organ may become destroyed subsequently.

Indications. (i) *For new growths of the testis.* Castration is the best treatment for this condition, whether the growth be innocent or malignant; in the latter case the operation should be undertaken immediately the diagnosis is made, since these growths are very malignant, and all practical surgeons realize how gloomy the prognosis is in these cases. The only hope is in early operation, and therefore an immediate exploratory incision should be practised if there be the least doubt as to the nature of any tumour of the testis.

(ii) *For certain cases of tuberculosis of the testis.* The cases requiring castration demand careful discrimination. It is generally admitted that it is legitimate to remove a tuberculous testicle that is completely disorganized, and is the cause of pain or annoyance to the patient, provided that there be on the opposite side sufficient healthy testicular structure to maintain the internal secretion of the organ; for instance, it would be unjustifiable to remove a testicle, however disorganized, if it were the sole remaining one. The other condition for which castration was at one time widely recommended, *viz.* early tuberculous disease limited to one testicle, has been discussed in connexion with epididymectomy (see p. 45), and it would seem that the latter operation, if properly carried out, is on the whole the preferable procedure in these cases.

(iii) The operation has been occasionally performed for *misplaced testis:* it should, however, only be resorted to when orchidopexy is impossible, the patient is advanced in years, and the testis is much atrophied.

(iv) Castration has been performed in order to effect a sound *radical cure of an inguinal hernia.* Such an extreme measure can, however, hardly ever be called for nowadays. Should it be impossible to avoid wounding the vas, the testis should still be left *in situ;* should the organ

be misplaced, as a result of a previous attempt at a radical cure, it would appear better to free it and place it in the abdomen after dividing the vas so as to prevent the possibility of infection along it (see p. 39). This preserves the internal secretion of the testis, whilst it enables the abdominal ring to be closed entirely. At one time, when recurrence of hernia after a radical cure was common, an adherent testis was one of the chief obstacles to a successful second operation.

(v) Castration was largely practised at one time for the cure of *enlarged prostate;* it has, however, now given place to enucleation, which is more certain in its results and safer in its action. As double castration was necessary to produce any marked effect upon the prostate, the psychological results were formidable, and many deaths occurred as a result of it.

(vi) Castration has been performed for *syphilis,* but generally under a misapprehension as to the nature of the case; there is no necessity to perform the operation for the cure of syphilitic testis. For cases of injury castration is practically never required; the parts should be cleansed and the wound in the tunica albuginea closed by suture. It is very important to retain the internal secretion of the testis, even though the vas be divided. Castration has also been performed for old hæmatocele of the tunica vaginalis. There is, however, no reason why this drastic operation should be performed for such a condition; incision and drainage, combined with removal of the lining membrane of the sac, should be quite sufficient to effect a cure.

Operation. A free incision is made from just above the external abdominal ring down to the bottom of the scrotum. Should there be any part of the scrotum adherent to the testis, this should be included in elliptical incisions and removed. The incision is deepened down to the tunica vaginalis, but the latter cavity should never be opened, as infective material may be contained in it and may contaminate the wound. The finger is passed round the tissues of the cord and, working downwards, frees the testicle and its ensheathing tunica vaginalis from the scrotal tissues. The whole organ is then drawn outside the wound and can be removed after ligature and division of the cord; this should be done in two parts, the vessels being taken up in one ligature, whilst the vas is secured in another. This latter structure should be isolated up to the abdominal cavity in all cases before it is tied and cut across. In cases of tuberculous disease the external oblique aponeurosis should be slit up so as to expose the internal ring fully, and the peritoneum should be stripped off the vas as far into the abdomen as possible before the former is ligatured and divided. In cases of malignant disease it is well to isolate all the structures of the cord as far up as possible before

they are ligatured and divided; the vessels are followed up towards the loin and tied as high up as possible, while the vas is traced as near to the base of the bladder as the operator can reach and divided there. The internal abdominal ring may be slit up, if necessary to facilitate this step of the operation.

The surgeon may occasionally desire to make an exploratory incision into the testicle to ascertain whether a given swelling be malignant or not before he removes it. In this case no incision should be made into the testis until it and its tunica vaginalis has been delivered through the scrotum, as mentioned above, preparatory to ligature and division of the cord. It should then be wrapped in a sterilized towel interposed between it and the scrotal wound, and, after being surrounded with swabs on all sides to catch any fluid that may escape, the incision is made into it. Should this show the swelling to be malignant, a large pair of clamp-forceps is put upon the cord, and the testicle, still enveloped in the sterilized cloth, is removed by a single stroke of the knife below this, so that there is no risk of infecting the wound in the scrotum. The structures of the cord are then dealt with in the usual way by transfixion and ligature, as described above, after they have been isolated as far inside the abdomen as possible.

All bleeding points are ligatured and a medium-sized drainage tube is inserted at the bottom of the scrotum, and the inguinal canal is closed completely by a few catgut sutures. The drainage tube is removed in forty-eight hours.

EPIDIDYMITIS

The treatment of acute gonorrheal epididymitis when persistent has seemed to give better results by the application of drainage than by any other method. Pirogoff recognized this fact and punctured the inflamed epididymis as far back as 1852. H. Smith in a publication in 1864 mentioned a series of 1,000 cases in which he punctured the acutely inflamed epididymis with beneficial results. It is apparent that the value of drainage in this condition was lost sight of until Hagner published his technique in 1906. It is as follows:

The junction of the epididymis with the testicle is defined and an incision about two inches long is made through the scrotal skin along this line. The tunica vaginalis is opened and such fluid as may be present in its cavity escapes. The swollen epididymis with the testicle is delivered. The epididymis is now punctured in many places with a narrow-bladed knife in the inflamed area. The punctures must penetrate the infiltrated fibrous covering and the body of the epididymis must be

entered by the point of the knife. If pus escapes from the punctures, the opening through which it makes its exit is to be enlarged and the cavity from which it comes is washed out with a corrosive sublimate solution of 1 : 1,000 strength by means of a syringe.

If the punctures do not yield pus after the puncture has been made through the fibrous covering, they should be probed with a small probe or director. In this way at times foci can be opened which may have escaped puncture with the knife. The epididymis should be squeezed and its surface and that of the testicle and tunica vaginalis sponged with a corrosive sublimate solution of a strength of 1 :1,000 followed by a sterile saline solution. The testicle is then replaced. A puncture is made at the bottom of the scrotum through which a rubber dam drain is placed in such a way that it lies along the outer side of the whole length of the epididymis. The skin wound is then closed by passing two silkworm-gut stay sutures through the skin, dartos, and tunica vaginalis and tied over rubber tubes one on either side of the wound. The tunica vaginalis incision is closed by continuous fine catgut suture and the skin incision by a subcutaneous silkworm-gut suture. A sterile dressing and a supporter are applied. The stay sutures are to be removed at the end of the first twenty-four hours, their purpose having been to prevent the dartos from retracting and thus causing ecchymosis in the lax scrotal tissue. The drainage dam is removed on the second day. Most cases are up on the third or fourth day. The silkworm-gut suture is usually removed on the eighth day. In many of the cases the catgut knot works out, which delays perfect healing. If the two silkworm-gut stay sutures prevent all bleeding from the dartos, as they usually do, the catgut suture of the tunica vaginalis may be omitted.

SEMINAL VESICLES

Squier, Fuller, Voelcker, Cabot, Legueu, Schede, and many others have described various operative procedures for drainage or removal of the seminal vesicles. Caulk in *Surgery, Gynecology, and Obstetrics* has summarized these views as follows:

The great majority of chronic inflammatory processes in the vesicles are capable of being clinically cured without surgical means. Routine massage and applications usually effect a prompt amelioration. There are a few cases, however, in which after conscientious local, palliative treatment, our efforts prove fruitless; these cases are the ones mentioned previously which present numerous diverticulæ and severe inflammatory infiltrations which will not soften and drain. These cases require surgical measures for their relief.

Squier in his recent article sums up the surgical indications in three words: Pus, pain, and rheumatism. (1) Under the first he includes (*a*) the acute cases, developing in the course of gonorrhœa, often mistaken for prostatic enlargement; (*b*) cases of recurrent epididymitis following acute urethritis and vesiculitis; (*c*) cases of chronic vesiculitis which simulate spermatorrhœa; and (*d*) those in whom the discharge from the urethra occurs during defecation and who have resisted faithfully carried out non-operative treatment. (2) Under pain he includes the various referred symptoms mentioned in a previous paragraph. He reserves surgery, however, for cases which resist local treatment. (3) In the rheumatic group he includes acute, subacute, chronic, and the deforming types of arthritis in which a definite relationship can be determined between the joint and the vesicle. Fuller has reported an astounding number of cures in chronic joint involvement by means of vesiculotomy. Cabot would reserve operations on the seminal vesicle for cases of crippling arthritis.

Concerning tuberculosis of the seminal tract, opinions differ. As tuberculosis is generally secondary to an epididymitis, epididymectomy is the operation which is usually employed, and most operators believe that the vesicles, under proper hygienic and tuberculin treatment, get well. The method of treating the vas differs with different operators; some remove it only to the external ring, some open it to the canal and follow it as far as possible; other more radical surgeons believe in excision, not only of the epididymis and vas, but also of the corresponding vesicle; some of the even more radical add to this surgical mutiny the ablation of the prostate. At this time, we feel that the general profession does not regard seminal vesiculectomy for tuberculosis a wise surgical procedure. Some surgeons practise injecting the vas with antiseptic solutions for their beneficial effect on the vesicular cavities. For this, argyrol and collargol have been most frequently employed. This is of questionable value. As carcinoma of the seminal vesicle is practically always secondary to carcinoma of the prostate, it is removed in conjunction with the prostate in the so-called complete prostatectomy in which the vesicle, prostate, bladder neck, and membranous urethra are removed *in toto*. This applies only to early carcinomatous processes in the vesicles.

SURGERY

We shall now attempt to give a summary of the various operative techniques on the vesicles. These may be divided into: vasotomy with injections of the vesicles, vesiculotomy, and vesiculectomy. Vasotomy,

heralded by Belfield, has been employed by him in many cases of vesiculitis. It does not at present seem to have a substantial hold on the profession in the surgery of these organs. He has reported excellent results and others have corroborated his statements. The technique is simple, consisting in making a small scrotal vasotomy and allowing argyrol, collargol, or some other solution to find its way into the cavities of the vesicles. Owing to its simplicity it seems to be an operation which should be more frequently employed, and seems indicated particularly in many of the chronic discharges which are not benefited by local treatment. After the injection the wound may be closed entirely, or, as Belfield practises it frequently, a tube may be left in the vas for repeated injections.

Seminal vesiculotomy and vesiculectomy may be performed either perineally or through the ischiorectal region. The perineal approach is by far the most commonly employed. The usual steps are as follows: with the patient in the lithotomy position, a Y-shaped incision is made somewhat similar to Young's perineal incision for prostatectomy; the apex of the prostate is exposed, then there are various modifications by different men. In order to bring down the vesicles, Young uses a tractor similar to the one he employs in prostatectomy work, excepting that it is longer and passes directly into the bladder from the meatus. By means of rotating this instrument against the symphysis, he is able to bring the vesicles nicely into the wound, and he is at liberty to undertake whatever he deems necessary.

Squier, after exposing the apex of the prostate and by traction, is able to pull the vesicles down for a satisfactory exposure. After the apex of the prostate has been exposed, and either the tractor or the tape is inserted, the prostate is brought into the wound and the rectum separated, dissection being between the two layers of Denonvillier's fascia. When the vesicles are exposed they will be found to be covered by the same fascial layers which cover the prostate. These must be divided before the vesicle can be attacked. After division of the fascia, the prostate, vesicles, and vas can be examined. There is usually a perivesicular exudate which occasionally makes exposure difficult. One can then open and drain the vesicles in any place desired, or can remove any part of the vesicle wall which may seem necessary. It is very frequently necessary also to incise the ampullæ of the vasa. This operation should be used on both vesicles and vasa. After one has incised the vesicles, he may consider his operation complete, or he may drain the prostate also at the same time if it seems advisable. Tubes and gauze drainage are used. The gauze should be placed into the incised cavities and the tube down to this region. The wound is partially closed by

bringing together the levator ani muscles with catgut, and the skin with either catgut or silk.

Fuller's operation, which was the first to be done on the seminal vesicles and the one which has been used probably more than all the others combined on account of the numerous operations which he has done, is an entirely different exposure from the one above described. He places his patients on a flat table in the knee-chest posture, with knees well separated, thigh and knee-joints sharply flexed, with an attendant at either side of the patient to maintain the position. Originally he used a rectal tampon, but latterly this has been discarded. His incision consists of two divergent cuts on either side of the anus. This incision is deepened through the fat and fascia, care being taken in deepening the transverse incision to keep far enough away from the anus so as not to injure the sphincter. The forefinger is inserted into the rectum, with the ball of the finger pressing down against the anterior rectal wall. He then cuts through the levator ani muscles and the visceral layer of the pelvic fascia. The finger also acts as a guide to prevent rectal injury. He then enters the space between the prostate and the rectal wall by blunt dissection with the finger. Fuller states that by this process of dissection it is easy to separate the rectal wall from the seminal vesicles and posterior wall of the bladder. After this is done, a grooved director is passed under the guide of the index-finger to the tip of the seminal vesicle. A scalpel is then passed in the wound, and the tip of the vesicle opened. This incision is then divulsed with the finger and the vesicle laid open. Fuller says that this operation is not bloody and no vessels require ligation. The cavities of the vesicles are packed with gauze and two soft rubber drainage tubes inserted between the gauze and the rectal wall. The wound is partially closed. The gauze is removed at the end of the fifth day, the drainage tubes on the ninth or tenth day. This operation, which has accomplished a great deal in the hands of its originator, is done entirely by the sense of touch, and is one which does not appeal to the average surgeon when he realizes that the field can be so completely exposed by the operation previously described.

The operation proposed by Voelcker, which he claims gives the best approach, is through the ischiorectal fossa. The patient is placed on the abdomen, an incision made near the coccyx and passed through the ischiorectal fossa behind the beginning of the sacrum. In the first layer, the undermost part of the gluteus maximus muscle will be cut through with the ligamentum tuberoso-sacrum. In the second layer the levator ani muscle and the pelvic fascia appear, which cover the rectum, prostate, and bladder. In this layer, numerous veins are to be seen, and a clean incision is made in the fascia between these vessels. One can draw the

rectum away from the posterior part of the bladder, exposing first one, and then the other seminal vesicle. In this way, Voelcker states that the free access to the vesicle is given and one can either incise or remove according to the indications. He has operated on the seminal vesicles by this method with no mortality. He observed no trouble with the healing of the wound, but one hæmorrhage occurring in his experience.

Any of these operations can be employed for removing the vesicles and ampulla of the vas, seminal vesiculectomy. As the vessels come to the upper and outer pole, it is always well to begin the dissection in this locality and ligate the vessels first, then the vesicle may be shelled out of its bed, dependent upon whether or not there are dense adhesions, otherwise seminal vesiculectomy is the same as the previous operation. The perineal method has been employed by Cabot, Barney, Young, Squier, Legueu, Gueillot, and Ullman; the parasacral by Schede, Routier, and Rydygier.

Seminal vesiculectomy may be done by the inguinal route according to the method of Villeneuve, Baudet, and Duval. These authors incise the inguinal canal, open it throughout its length, then open the transversalis fascia and strip the peritoneum up until the vas is reached. This canal is followed to the tip of the vesicle by gentle traction. The vesicle is then seized with a forceps and removed. This operation is more complex and difficult, in that it is more likely to prove dangerous to the peritoneum, ureter, and pelvic plexus, as exposure is difficult.

Another method is the suprapubic approach, which was reported by Young in 1900 in the *Annals of Surgery*. With a mid-line suprapubic incision, the bladder is opened, and the ureters catheterized. Rectovesical —the peritoneum is stripped back from the bladder and the vesicles are reached in this manner. This operation is more complex and is not employed in the chronic inflammatory conditions, even by its author, who finds perineal approach much more adequate and simple. We have been unable to gather definite mortality statistics, but from personal communication with many, it is certain that the mortality is practically *nil.* Injury to the rectum has not been striking. There is, however, one decided consideration in operations upon the vesicles, and that is the crippling of the sexual powers in many cases. There have been many cases of impotence occurring after these operations. This makes the more conservative surgeons loth to undertake the operation, reserving it for cases which have resisted all other treatment, or for cases of deforming arthritis. We have no statistics as to the comparative effects of vesiculectomy and vesiculotomy on the sexual powers.

The operations upon the vas deferens are usually those done in conjunction with other operations upon the genital tract, particularly in con-

junction with epididymectomy. The principal operations upon the vas are: vasotomy, vasectomy, vaso-vasotomy, vaso-epididymotomy, and ligation for recurrent epididymitis.

In anastomosing the vas following injury or after excision of structure, Christian and Sanderson have reported satisfactory results by placing a piece of catgut in the lumen before closure. They claim that this prevents the tendency to stricture.

Vaso-epididymotomy, proposed by Dr. Martin of Philadelphia for the cure of sterility, is the most important surgical operation on the vas. The operation is of course not serious, but extremely delicate and not always effective. The technique as described by its author is as follows: Before the operation is undertaken, strictures, posterior urethral lesions, and chronic inflammation of the seminal vesicles and vas should be cured. The patency of the vas from the epididymis to the prostatheic urethra should be assured by an injection into the lumen of the vas of the watery emulsion of inert pigment which, when passed with the urine or expressed by massage of the vasal ampulla, may be recognized readily. This preliminary operation may be accomplished under local anæsthesia by means of either an ordinary hypodermic syringe, the needle of which is blunt, or the syringe used by oculists for washing out the lachrymal duct. The vas is held just beneath the skin by the fingers of an assistant; the line of incision is infiltrated; the vas is exposed, slit longitudinally, and from 20 to 30 drops of the injection are driven in. A large injection is likely to occasion severe pain at the base of the bladder (Belfield). If the pigment does not appear either in the urine, in the seminal discharge, or as a result of massage, anastomosis between the vas and epididymis will be futile.

Caulk believes it is better to cut the vas obliquely, split it upward for a quarter of an inch, and sew this wide-stretched lumen to the opening made either in the epididymis, or, if spermatozoa are not found there, in the testicle. The microscopist should be at hand to examine the fluid which exudes from the epididymis when it is opened. This opening is made by the pinching up of a very small portion of it in a pair of conjunctival rat-tooth forceps and snipping this portion off with a pair of eye-scissors curved on the flat. Usually a little blood and yellowish fluid will exude. This, taken up on a cover glass, will show innumerable spermatozoa. If spermatozoa are not present, other openings must be made into the epididymis or testicle until spermatozoa are found. The anastomosis between the cut ends of the vas and epididymis may be made by means of four sutures carried by fine curved eye-needles. Either silk or fine silver wire answers the purpose well. The suture is carried from without into the wall of the vas, and from within out of the wall of the

epididymis. The tying down of the sutures completes the anastomosis. The approach to the epididymis and vas is made through the posterior scrotal wall. It usually does not require the application of a single ligature. The veins should be carefully avoided; otherwise troublesome and painful thrombosis will develop. Dr. Martin and others have reported satisfactory cures. Dr. Hagner of Washington reports an anastomosis of the vas of one side to the globus major of the other side in a patient who had had a previous double vaso-epididymotomy.

SECTION II

OPERATIONS UPON THE THORAX AND ITS CONTENTS

PART I

OPERATIONS UPON THE BREAST

BY

HAROLD J. STILES, M.B., F.R.C.S. (Edin.),
Lieutenant-Colonel R.A.M.C.(T.)

Surgeon to Chalmers Hospital, Edinburgh, and to the Royal Hospital for Sick Children, Edinburgh

CHAPTER I

OPERATIONS UPON THE BREAST

OPERATIONS FOR CARCINOMA

BEFORE describing the operative treatment of cancer of the mamma, it is necessary to refer shortly to the more important anatomical and pathological observations which have led to the development of the modern extensive operation.

SURGICAL ANATOMY

The breast tissue proper consists of a central part, the corpus mammæ, and of a peripheral portion made up of branching processes which become more and more subdivided as they extend into the paramammary fat, until finally they become continuous with the connective-tissue septa of the subcutaneous fatty tissue. The breast, therefore, has no distinct capsule. In the young adult nullipara the corpus mammæ is compact, well defined, and contains but little intramammary fat, while the peripheral processes are relatively small. In the multipara the corpus mammæ contains more fat and the peripheral processes extend more widely into the paramammary fat.

The breast tissue has a much wider distribution than was generally supposed. The extent and arrangement of the parenchyma is well demonstrated by treating the breast with a 5% solution of nitric acid. If slices of the fresh organ be placed in this solution for a few minutes and then washed under running water, the albumin of the epithelial cells of the parenchyma is coagulated, while the connective tissue is rendered transparent, homogeneous, and somewhat gelatinous. The ultimate lobules of the parenchyma now appear as little opaque, sago-like bodies, 1–2 millimetres in diameter, arranged in grape-like clusters around the terminations of the finer branches of the ducts.

The tooth-like processes which pass from the anterior surface of the corpus mammæ are attached to the skin by fibrous prolongations known as the suspensory ligaments of Cooper. The parenchyma is prolonged into these processes, and in spare women, with well-developed mammæ, it may reach almost to the skin.

Vertically the breast tissue extends from the second rib to the sixth costal cartilage at the angle where it begins to sweep upwards to the sternum; the horizontal diameter reaches from the edge of the sternum opposite the fourth costal cartilage to the fifth rib in the mid-axillary line. The inner hemisphere rests almost entirely on the pectoralis major; at its lowest part it overlies the upper part of the aponeurosis covering

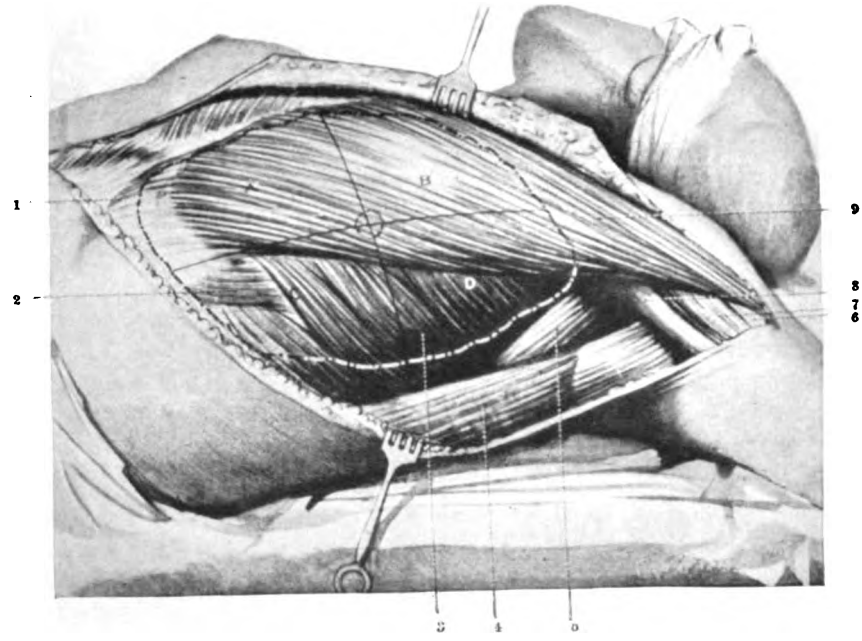

FIG. 23. DISSECTION OF THE FRONT OF THE CHEST AND AXILLA TO SHOW THE RELATION OF THE QUADRANTS OF THE BREAST TO THE SUBJACENT MUSCLES. 1, Left costal margin; 2, External oblique muscle; 3, Serratus magnus muscle; 4, Latissimus dorsi muscle; 5, Subscapularis muscle; 6, Short head of the biceps; 7, Coraco-brachialis muscle; 8, Sheath of the axillary vessels; 9, Pectoralis major muscle. The dotted line denotes the extent of the breast; the areas A, B, C, and D correspond to its four quadrants.

the rectus and external oblique muscles. The upper half of the outer hemisphere rests upon the greater pectoral, on the edge of the lesser pectoral, and to a slight extent on the serratus magnus, upon which it extends upwards into the axilla as high as the third rib, where it comes into relation with the pectoral group of axillary lymphatic glands situated upon the inner wall of the axilla. The remainder of the outer hemisphere rests almost entirely upon the serratus, except the lowest

part, which overlaps the fleshy digitations of the external oblique arising from the fifth and sixth ribs. It follows, therefore, that about one-third of the whole mamma lies inferior and external to the axillary border of the pectoralis major. These relations have been dwelt upon in detail because the surgeon must cut beyond the limits here mentioned if he wishes to remove the whole of the breast tissue.

According to Heidenhain, in a breast which is the seat of an ordinary scirrhous cancer, there are present throughout the whole gland proliferative changes in the epithelium of the parenchyma and in the interacinous connective tissue which must be looked upon as precancerous, and which are sooner or later destined to develop into active malignant disease. While admitting the truth of the above statement in exceptional instances, the writer's pathological observations have led him to conclude that when cancer manifests itself in a portion of breast tissue which has been left behind as the result of an incomplete operation, the so-called recurrence generally originates in the same way as it does in the extrinsic tissues, *viz.* by the proliferation of cancer cells which have found their way into the lymphatics from the primary tumour. This question, although of great interest to the pathologist, is of less importance to the practical surgeon, since, in removing all the lymphatics of the breast, he must of necessity also remove all the parenchyma. The aim, therefore, of the operator should be to remove not only the breast tissue but also as much of the surrounding tissues as anatomical and pathological research has shown to be likely to contain the lymphatics along which the cancer cells have disseminated. Unfortunately, it is impossible in any given case to say definitely to what extent this dissemination may have taken place, and herein lies the difficulty and uncertainty in the operative treatment of the disease.

Lymphatics. The lymphatic system of the mamma consists of five sets of vessels which communicate freely with one another: (1) A cutaneous set including those of the nipple and areola. (2) the subareolar plexus of Sappey, which receives efferents from the skin as well as those intramammary lymphatics which accompany the main lactiferous ducts. (3) The intramammary lymphatics proper, which, after forming a network around the lobules, run for the most part along with the blood-vessels in the interlobular connective tissue. While some of the efferent intramammary lymphatics open, as above stated, into the subareolar plexus, the majority pierce the posterior surface of the gland to join the retromammary lymphatics. According to Poirier and Cunéo, some of the lymphatics which proceed from the upper hemisphere ascend over the clavicle to join the supraclavicular glands. (4) The lymphatics of the subcutaneous tissue superficial to the mamma form part of the gen-

eral subcutaneous lymphatic system of the chest and upper part of the abdomen; they anastomose on the one hand with the intramammary and deep fascial lymphatics, and on the other hand with the lymphatics of the skin, the channels of communication occupying for the most part the ligaments of Cooper. (5) The retromammary lymphatics occupy the loose retromammary cellular tissue and the deep fascia which covers the muscles subjacent to the mamma. They form the deep fascial lymphatic plexus which Heidenhain and the writer have shown plays such an important rôle in the local dissemination of the disease. The recent researches of Handley have still further demonstrated the importance of these lymphatics. According to this observer, when the lymphatic plexus of the deep fascia becomes involved the disease permeates it by a process of continuous growth which is centrifugal and practically equal in all directions. An important point to note, too, is that this plexus may become infected before the tumour has become adherent to the pectoral fascia, and is probably also the plane along which the disease spreads occasionally to the opposite axilla. 'Later on permeation spreads into the smaller muscular and cutaneous tributaries which drain vertically into the plexus and so infects the adjoining layers to a depth which reaches its maximum opposite the centre of the primary growth' (Handley). The small nodules which then occur at the junction of the skin and subcutaneous tissue are generally due to a superficial extension of the disease from the breast along the lymphatics contained in the ligaments of Cooper, or they represent 'accidental efflorescences of growth which have extended upwards from lymphatics of the deep fascia which have become permeated with cancer cells.' Handley has also shown that it is by the centrifugal permeation of the plexus which occupies the fascia covering the anterior sheath of the upper part of the recti and linea alba in the epigastric triangle that the disease generally reaches the peritoneal cavity and the liver. 'The cancerous permeation extends along the numerous finer anastomoses which, piercing the parietes, connect the lymphatic plexus of the deep fascia with the subendothelial lymphatic plexus of the pleura and peritoneum, and with the mediastinum and portal glands. . . . Unfortunately the microscopic growing edge is not clinically recognizable, and the surgeon cannot determine for each case as it comes before him how far the circle of fascial permeation has extended. If the case is a very early one, permeation may still be confined entirely within the limits of the breast. If it is moderately early, only a small area of the pectoral lymphatic plexus, an area perhaps not so large as the diameter of the breast, may have been invaded. But if the case, though still operable, is late, or if the cancerous epithelium is proliferating with more than

average rapidity, the permeated area of the deep fascial plexus may already have passed considerably beyond the margin of the breast.

'Since there are no satisfactory clinical means at present of fixing the limit of fascial permeation in a given case, the only safe rule is to remove a very wide circle of the deep fascia round the growth, and a smaller circular area of skin' (Handley).

The researches of Handley have led him to add to the radical operation the further routine step of removing the subcutaneous tissue and aponeurosis covering the recti over an area corresponding to the epigastric triangle.

With regard to the relative amount of skin and deep fascia which should be removed in the routine operation, Handley's researches confirm the original view of the writer that in the early stage of carcinoma of the breast, *i.e.* before the skin has become tacked down over the tumour, it is not necessary to remove an excessive amount of skin. It is important, however, to remove a wide area of subcutaneous tissue and deep fascia. Upon this point Handley writes as follows: 'The area of skin taken away in the operation should obviously be no larger than is necessary and no healthy skin should be removed. It has already been shown that cancer does not spread in the plane of the skin, but, nevertheless, free removal of skin is necessary, owing to the vertical extension to the skin after a time, and over a smaller area, of the growth which is spreading in the deep fascia. The necessary conditions can usually be fulfilled by the removal of a circular area of skin 4 to 5 inches in diameter with the growth at its centre. The very extensive ablation of skin carried out by some surgeons is based upon erroneous ideas of the pathology of dissemination and is not found practically to improve the result of the operation. . . . It is a fortunate circumstance that breast cancer spreads primarily in the parietes along the deep fascia and only secondarily involves the skin. For while removal of the skin has, in some hands, reached its furthest possible limits without any corresponding improvement in results, it is possible to remove the deep fascia over a wider area than is yet the usual custom. The removal of a maximal circular area of deep fascia centred upon the primary growth is a step absolutely essential to the completeness of the operation, except in very early cases. . . .

'It is only when the tumour is situated below the nipple that the latter should occupy the centre of the ablated skin. When the cancer is situated at the sternal margin of the breast the subcutaneous tissue and deep fascia must be excised for a considerable distance beyond the opposite edge of the sternum, while if it occupies its lower margin the fascia must be dissected off the rectus and external oblique, further down

towards the umbilicus. If, on the other hand, the growth be situated in the axilla, it will be necessary to excise the deep fascia as far as, or it may be even beyond, the cephalic vein as well as further back over the outer surface of the latissimus dorsi.'

The axillary lymphatic glands. The number of axillary lymphatic glands which may be met with in patients suffering from cancer of the mamma is often far in excess of that usually described by anatomists. This is accounted for by the fact that some of them are no larger than a pin's head, while others are frequently found to have undergone such marked adipose transformation that they are very liable to be mistaken for ordinary fat globules. Both these varieties are just as liable to become malignant as are the more typical glands. The early stage of glandular infection is, of course, microscopic, so that the absence of enlargement and induration of the glands is no proof of their freedom from malignancy.

While the pectoral group, which lies along the lower border of the pectoralis minor, is generally the first set to become infected, it must be remembered that the apical or subclavicular group may alone be affected. When the tumour is situated either at the lower or at the axillary border of the breast the subscapular group may be the first to become infected; when, on the other hand, the tumour involves the inner hemisphere this group generally escapes, or is infected only at a late stage of the disease.

From the operative point of view the subclavicular glands are by far the most important. Although diseased, it is often impossible to feel them by palpation through the floor of the axilla; they not infrequently give rise, however, to a feeling of deep-seated resistance or nodular induration when firm pressure is made over the infraclavicular triangular depression which corresponds to the intermuscular space between the clavicular origins of the pectoralis major and deltoid muscles. It is important that the operator should be familar with the topographical relations of these glands. They lie in close relation to the superior thoracic artery, which ramifies in the cellular tissue and fascia covering the upper two intercostal spaces. When diseased they are liable to become adherent to the sheath of the highest part of the axillary vein. Above the glands are the clavicle and subclavius muscle, while immediately below them is the upper border of the pectoralis minor; in front of them we have, of course, the pectoralis major and the costo-coracoid (coraco-clavicular) membrane. It is in the region occupied by these glands that recurrence was so frequently met with when the operator contented himself with leaving the muscles and trusting to clearing the axilla from below.

The pectoral muscles. We are indebted to Halsted for adding to the routine operation the removal of the pectoralis major muscle. This step is called for in the first place to obtain the necessary access for the removal of the subclavicular glands and fatty cellular tissue and fascia at the apex of the axilla, and in the second place, because Rotter has shown that the perforating branches of the internal mammary and of the superior thoracic arteries, after piercing the pectoralis major, pass through the retromammary tissue into the substance of the breast, and that these vessels are accompanied by paravascular lymphatics which are efferent for the breast. After piercing the pectoralis major these lymphatics occupy the retropectoral fascia and ascend between it and the pectoralis minor to open into the subclavicular glands. Rotter pointed out, too, that at an early stage of the disease and before the tumour has become adherent to the pectoral fascia, the cancer cells may be conveyed by these channels through the retromammary fat and pectoral muscle to small lymphatic glands situated in the fascia upon the posterior surface of the pectoralis major, as well as by the more generally recognized channels to the axillary glands. He found that dissemination had taken place by the former route in a third of the forty cancerous breasts he examined. These paravascular efferent lymphatics only pass through the sternal portion of the muscle, so that the clavicular fibres need not be removed in every case. In the cases in which the subclavicular glands are alone involved, it is no doubt along these retropectoral paravascular lymphatics that the infection travels.

The sternal portion of the pectoralis major and the pectoralis minor should therefore be removed as a matter of routine, (1) because either they or the glands and fascia behind and between them are liable to be infected, and (2) because it is only by their removal that the surgeon is able to thoroughly clear the subclavicular space. It is unfortunate that students in the dissecting-room are encouraged to dissect the axilla from below; by approaching it from the front, after removing the sternal fibres of the pectoralis major and then the pectoralis minor, they would gain a much better conception of what is meant by a thorough clearance of the axilla, and they would have the additional advantage of being able to trace the blood-vessels and nerves from their origin to their distribution.

The serratus magnus. As a considerable part of the outer hemisphere of the breast lies upon this muscle, it is obviously important to remove the deep fascia covering it as well as that covering the upper digitations of the external oblique muscle of the abdomen. Unfortunately the fascia here is thin and tends to adhere to the muscles, especially where they interdigitate and where the lateral branches of the intercostal

vessels and nerves pierce the fascia. If the tumour be adherent to the fascia there should be no hesitation in removing along with it a wide area of the serratus, a portion of the adjacent external oblique, and, if necessary, a portion of the posterior thoracic nerve.

INDICATIONS FOR OPERATION

Except in the presence of special contra-indications depending for the most part on the general health of the patient, the radical operation should be performed whenever there is even a remote possibility of obtaining a permanent cure.

With regard to *palliative operations* in advanced cases no definite rules can be laid down. Each case must be judged on its own merits. Speaking generally, however, it may be said that palliative operations should be the exception rather than the rule, and they should not be undertaken unless there is every reason to believe that the patient's life will thereby be prolonged, or that the operation is likely to remove, or at any rate ameliorate, the mental or physical distress, such as is occasioned, for example, by the presence of a foul and painful ulcer.

The *operation is contra-indicated* (1) in the acute or inflammatory cancer, the so-called mastitis carcinomatosa of Volkmann; (2) in cancer *en cuirasse;* (3) when the tumour is associated with multiple lenticular disseminations in the skin surrounding it; (4) when the tumour is firmly fixed to the chest-wall; (5) in an elderly patient the subject of an old-standing atrophic or diffuse cicatrizing carcinoma; (6) when the glandular mischief in the axilla or in the neck is obviously so extensive as to preclude all possibility of a permanent cure, and when no palliative benefit is to be expected from a partial removal of the disease.

THE OPERATION

Preparation of the patient. The disinfection should not be confined merely to the pectoral and axillary regions, but should include also the neck, the shoulder, the upper arm, the abdomen down to the level of the umbilicus, and the back of the corresponding side of the chest as far round as the spinal column. A carbolic compress should not be applied over such an extensive skin area for some hours before the operation, on account of the readiness with which this drug is absorbed by the skin. If the skin be disinfected the night before the operation it should be covered simply with sterilized towels (or gauze) kept in position by a bandage. In nervous patients the writer is satisfied that it is not necessary to disinfect the skin the night before the operation, provided it be thoroughly done while the patient is under the anæsthetic. Repeated disinfection of the skin is the reverse of beneficial, as it only

serves to stir into activity the organisms in the deeper layers of the skin, and at the same time to diminish its resistance to infection.

For the preliminary cleansing of the skin the writer prefers a solution containing spirits of green soap and lysol. An advantage of this mixture is that all the time the skin is being mechanically cleansed with the soap, the lysol, which is a penetrating antiseptic, is also being well rubbed in. After washing off the above mixture with normal saline solution the skin is scrubbed with a large gauze swab freely soaked with Harrington's solution,[1] which is then removed either with sterile normal saline or with dry sterile gauze.

Dry sterilized sheets should be arranged so as to cover the whole of the operating table and the patient, except, of course, the immediate field of operation. A sterilized triangular handkerchief is applied to the head so as to cover up the hair completely, and a large moist gauze swab is placed across the neck. The upper extremity on the same side, enveloped in a sterilized sheet from the tips of the fingers to the middle of the upper arm, is held abducted to a little beyond a right angle by a nurse, who should wear a sterilized overall. The anæsthetist, who wears sterilized cotton gloves, should be screened off from the field of operation by a sterilized sheet, and, if he be an expert at his work, there is no need for the patient's face to be exposed to the view of the surgeon.

The anæsthetic. Except in patients who are very feeble and debilitated, or who are the subjects of cardiac mischief, the writer prefers to perform the operation under chloroform rather than under ether, as the bleeding is much less with the former drug, and less than half the number of artery forceps and ligatures are required. The operation can therefore be more quickly performed under chloroform, and a comparatively short chloroform anæsthesia, with little bleeding, produces no more shock than a more prolonged operation under ether. If ether be used it should be given by the open drop-method, a sixth to a quarter of a grain of morphine and a hundredth of a grain of atropine being given half an hour before the operation.

The operation is from beginning to end a strictly anatomical one, and it will be described step by step exactly as the writer is in the habit of performing it. It may be remarked, however, that as long as the operation is sufficiently radical, and founded on our present scientific knowledge of the paths of dissemination of the disease, the exact order of the steps in the technique is a matter of secondary importance.

The skin incision. In the development of the modern operation a good deal of attention has been devoted to the planning

[1] Commercial alcohol (94%), 640 c.c.; hydrochloric acid, 60 c.c.; water 300 c.c.; corrosive sublimate, 0.8 gramme.

of the skin incision. While it is better to err on the side of removing too much rather than too little skin, it is essential to bear in mind that whatever be the size and shape of the area of skin ablated, the part which overlies the tumour, and not necessarily the nipple, should occupy its centre. It is a mistake always to make the skin incision coequal with the outline of the mammary prominence; to do so in the case of a tumour placed at the circumference of the mamma would result in the sacrifice of an unnecessary amount of skin in one direction, and, what is still more important, in the removal of too little skin in the neighbourhood of the tumour. The tendency to depart too much from the wide elliptical incision with well-prolonged extremities has not always been in the direction of improvement.

The incision should be planned with the object of removing not only the breast and axillary contents, but also for the purpose of removing a still wider area of the circummammary fat and deep fascia. The objection to some of the incisions which have been recommended for the radical operation is that while they remove an unnecessary amount of skin in the average case, they do not allow of a sufficiently free removal of the subcutaneous tissue and deep fascia beyond the circumference of the breast.

The entire incision may be described as consisting of three parts, *viz.* (*a*) an ablation or delimiting portion, (*b*) an axillary portion, and (*c*) an epigastric portion.

(*a*) When the tumour is placed behind the areola, *the ablation incision* should take the form of a wide ellipse, or of an oval, placed with its long axis parallel to the lower border of the pectoralis major. The width of the ellipse will depend partly on the size and configuration of the mamma, and more especially on whether the skin is tacked down to the tumour, and if so, to what extent. If the skin be freely movable over the tumour, the ellipse need not necessarily include the whole of the mammary prominence, but if the skin be at all involved the ablation incision should be more or less circular, as it is wiser to err on the side of removing too much rather than too little skin, and all question as to the possibility of subsequent closure of the wound should be kept in the background.

When the tumour is placed at or near the circumference of the breast, the delimiting portion of the incision must be modified so as to bring the tumour as nearly as possible in the centre of the ablated area. This can easily be done by simply bowing out one side of the ellipse well beyond the tumour, or, what is often more convenient, by adding to the delimiting incision a more or less V-shaped incision so as to remove an additional triangular area of skin with its base formed either by the

upper or the lower segment of the main incision, depending on which hemisphere the tumour is situated in (see Fig. 24).

When the triangle is taken from the upper flap, the lower one, which is always the more redundant, can often be made to fill in the gap; if, however, the triangle be taken from the lower flap, the wound can sometimes be closed completely by suturing it in a T-shaped fashion. The various plastic methods employed for partially or completely closing the wound will be referred to later.

(*b*) *The axillary portion of the incision* extends from the upper and outer angle of the ablation incision along, or a little above, the anterior

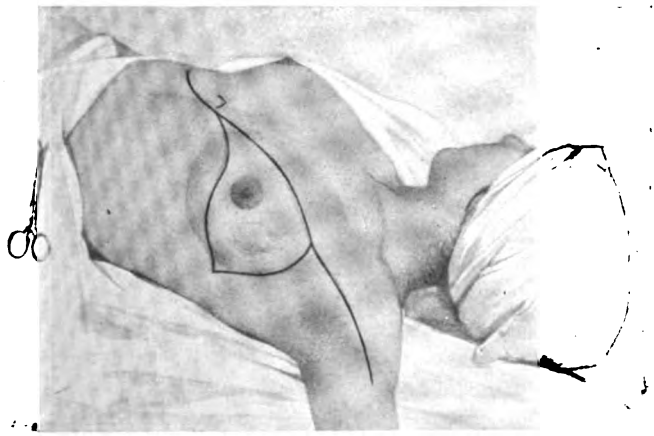

FIG. 24. INCISION FOR THE COMPLETE OPERATION FOR A CARCINOMA OCCUPYING THE UPPER OUTER QUADRANT OF THE BREAST.

fold of the axilla to a point an inch or so below its junction with the upper arm.

(*c*) *The epigastric portion of the incision,* for the necessity of which we are indebted to Handley, is carried from the lower and inner angle of the delimiting incision downwards and inwards across the epigastric triangle to end at the opposite costal margin 2 to 3 inches below the infrasternal notch.

Reflection of the upper flap. The upper flap, which should be reflected first, is dissected upwards as far as the lower border of the clavicle and inwards to the opposite edge of the sternum. While this is being done the assistant facilitates the process by grasping the edge of the flap with suitable grip-forceps so as to keep it stretched upwards. It is both time-wasting and superfluous to apply forceps to any but the more freely bleeding points.

Securing the pectoral branches of the acromio-thoracic axis. These vessels, which arise from the thoracic axis (thoraco-acromial) a little below the middle of the clavicle, descend behind and at right angles to the interval between the sternal and clavicular fibres of

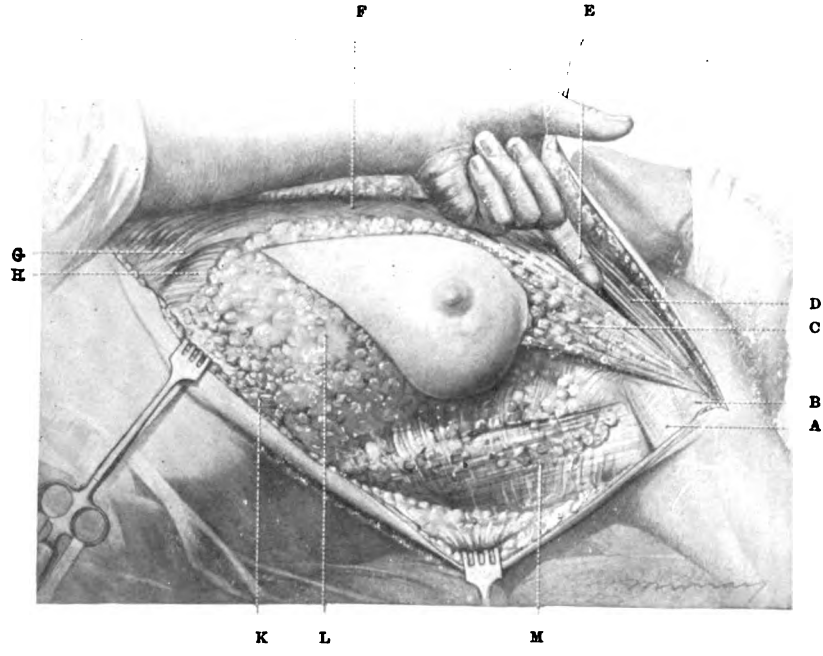

FIG. 25. THE COMPLETE OPERATION FOR CARCINOMA OF THE MAMMA. *Reflection of the flaps.* Shows the extent to which the upper and lower flaps must be reflected in order to remove the whole of the breast tissue, and a still wider area of superficial and deep fascia. The forefinger is inserted in the interval between the clavicular and sternal origins of the pectoralis major so as to hook forwards the pectoral branches of the acromio-thoracic axis and branches of the external anterior thoracic nerve. A, Fascia covering the coraco-brachialis muscle; B, Fascia covering the short head of the biceps muscle; C, Breast tissue covering the sternal fibres of the pectoralis major; D, Clavicular fibres of the pectoralis major; E, Pectoral branches of the acromio-thoracic axis and branches of the external anterior thoracic nerve; F, Sternum; G, Infrasternal notch; H, Aponeurosis covering the rectus abdominis muscle; K, External oblique muscle; L, Breast tissue; M, Fascia covering the latissimus dorsi muscle.

the pectoralis major. To reach them this interspace is opened up first with the handle of the knife, and then with the left index-finger, which is thrust deeply through the costo-coracoid (coraco-clavicular) membrane so as to hook the vessels forwards along with the external anterior thoracic nerve; these are then divided between two artery forceps. By

this preliminary step one of the main sources of blood-supply to the breast is controlled at an early stage of the operation. Before proceeding to the next step the flap is covered with a large gauze swab wrung out of hot normal saline solution.

Reflection of the lower flap. The assistant now grasps and pulls the mamma towards him while the surgeon dissects back the lower flap to a little beyond the edge of the latissimus dorsi. The upper part of the flap is reflected so as to expose the outer wall of the axilla and the adjacent portion of the upper arm. During this part of the dissection it must be kept in mind that the lower part of the axillary vein lies immediately under the deep fascia, and that with the arm abducted the vessel is projected forwards by the head of the humerus. The lower part of the flap should be dissected down so as to lay bare the superficial fascia of the epigastric triangle as well as that covering the upper digitations of the external oblique muscle of the abdomen.

In dissecting back the flaps care should be taken to keep as close to the skin as is consistent with its vitality, otherwise one is very liable to cut into the breast tissue. This is especially important in the case of the lower flap, as the pectoral group of lymphatic glands when enlarged and diseased often lie close beneath the integuments covering the base of the axilla. If a malignant gland be accidentally cut into, it should be immediately removed, and, to avoid infecting the wound with cancer cells, a fresh knife should be taken.

Division of the insertion of the pectoralis major. The arm is slightly lowered by the nurse so as to relax the pectoralis major, the sternal fibres of which are divided from without inwards close to their insertion, the left forefinger being passed beneath the fibres so as to hook them forwards away from the axillary vessels.

Detachment from the chest-wall of the sternal portion of the pectoralis major along with the breast, the circummammary fat, and the deep fascia. The upper border of the sternal portion of the pectoralis major is grasped by the operator's left hand and put on the stretch, while the right detaches the subcutaneous fat and the origin of the pectoralis major from the sternum and costal cartilages from above downwards, the assistant meanwhile applying forceps to the perforating branches of the internal mammary vessels, if possible before they are divided. When the lower end of the sternum has been reached, the circummammary fat and deep fascia are dissected off the epigastric triangle along with the upper part of the anterior sheath of the recti, the muscular branches of the superior epigastric artery being clamped. Next, the fat and deep fascia, along with the lower and outer part of the breast, are cleanly dissected off the upper

digitations of the external oblique, the lower part of the serratus magnus, the pectoralis minor, and, finally, off the inner and posterior walls of the axilla as far back as the latissimus dorsi. The breast and pectoral muscle, with their deep surfaces directed upwards, are turned backwards

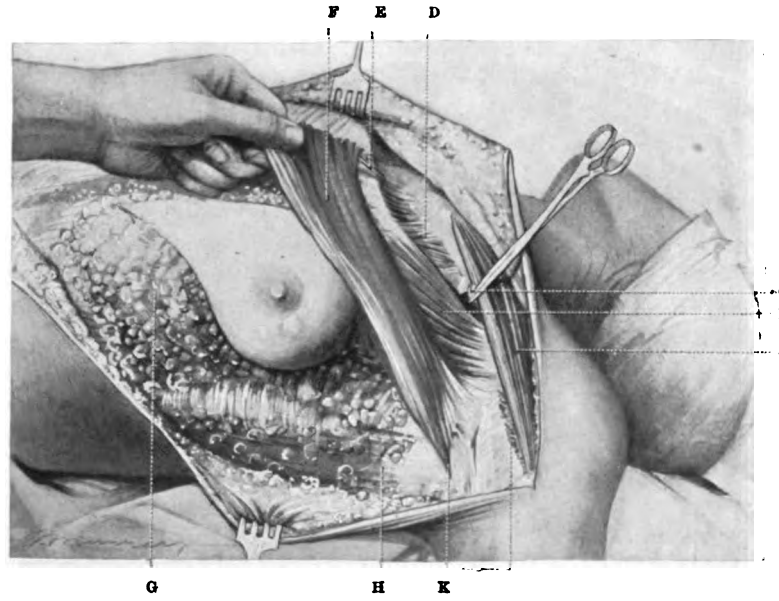

FIG. 26. FURTHER STAGE OF THE COMPLETE OPERATION FOR CARCINOMA OF THE MAMMA. *Division of the pectoralis major.* The pectoral branches of the acromio-thoracic (thoraco-acromial) axis are clamped and divided; the upper part of the sterno-chondral origin of the pectoralis major is detached, exposing the upper part of the pectoralis minor and the first intercostal space. A, Clavicular fibres of the pectoralis major; B, Pectoralis minor; C, Pectoral branches of the acromio-thoracic (thoraco-acromial) axis; D, First external intercostal muscle; E, Anterior perforating branch of the internal mammary artery; F, Upper part of the sternal portion of the pectoralis major turned downwards so as to expose its deep surface; G, Breast tissue; H, Latissimus dorsi muscle covered by fascia; K, Cut surfaces of the sternal fibres of the pectoralis major divided close to their insertion.

over the posterior fold of the axilla, and left attached to the remaining fascia and fatty contents of the space.

Removal of the pectoralis minor. With a few touches of the knife the fascia at the upper and lower borders of the pectoralis minor is divided, and the finger is passed under the muscle close to its origin so as to hook it forwards while it is being detached from the ribs. The muscle is then reflected upwards and outwards and removed by dividing it close to its insertion into the coracoid process. Blunt dissection may be

employed to free the under surface of the muscle as it crosses the axillary vessels. The blood-vessels which supply the muscle will be found to enter its deep surface close to its insertion.

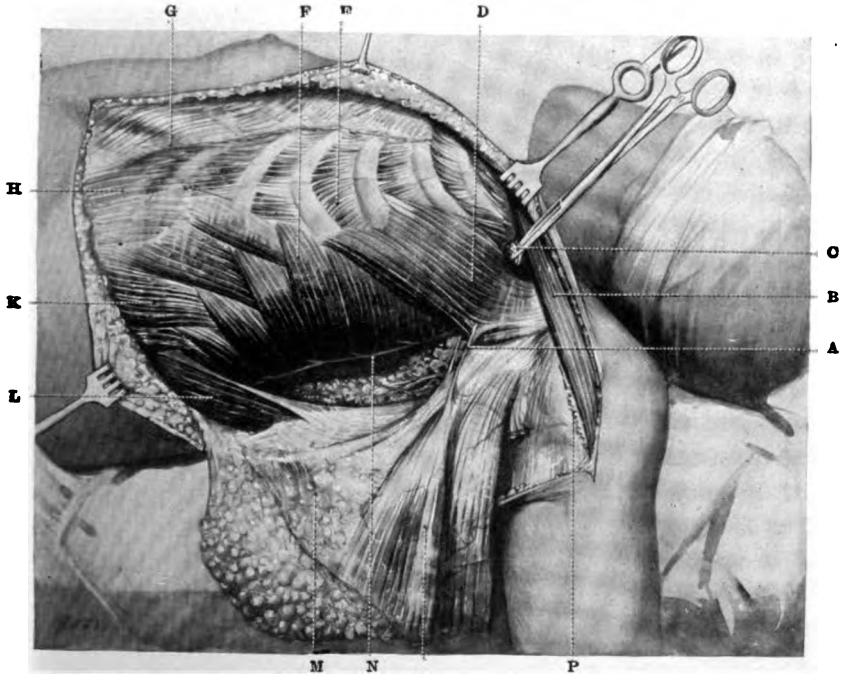

FIG. 27. FURTHER STAGE OF THE COMPLETE OPERATION FOR CARCINOMA OF THE MAMMA. *Exposure of the axilla.* The sternal portion of the pectoralis major, along with the breast, circummammary fat, and deep fascia, has been detached from the muscles of the chest-wall from within outwards and from below upwards, and folded back over the posterior fold of the axilla. The pectoralis minor is still in position. A, Internal anterior thoracic nerve; B, Clavicular fibres of the pectoralis major; C, Pectoral branches of the acromio-thoracic (thoraco-acromial) axis; D, Pectoralis minor; E, External intercostal muscle; F, Serratus magnus; G, Infrasternal notch; H, Left rectus abdominis muscle; K, External oblique muscle; L, Latissimus dorsi muscle; M, Retromammary fascia; N, Posterior thoracic nerve; O, Posterior surface of the pectoralis major; P, Divided sternal fibres of the pectoralis major.

Dissection of the axilla. The whole of the anterior wall of the axilla having been removed, the operator now proceeds to make a clean dissection of the axilla from above downwards, and not from below upwards as in the old operation.

The clavicular fibres of the pectoralis major are retracted upwards while the operator clears away the cellular tissue and fascia covering the upper two intercostal spaces. In continuing the dissection inwards

towards the vein the remains of the costo-coracoid (coraco-clavicular) membrane are removed along with the infraclavicular glands and fat. The sheath of the upper part of the axillary vein and the small superior thoracic vessels are also removed. Every particle of fatty tissue must be cleared away as high up as the sheath of the subclavius muscle, the first rib, and the subclavian vein, and when the subclavicular glands

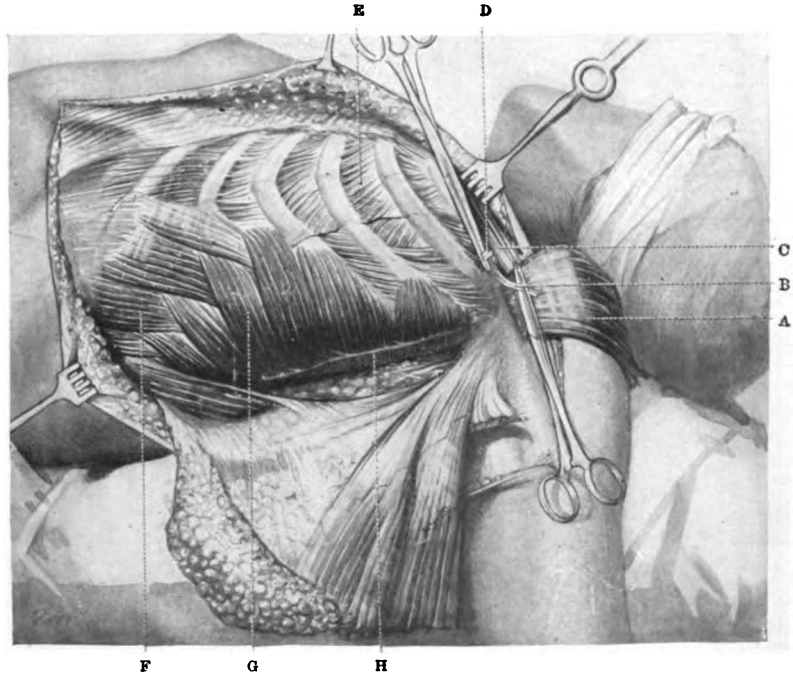

FIG. 28. FURTHER STAGE OF THE COMPLETE OPERATION FOR CARCINOMA OF THE MAMMA. *Division of the pectoralis minor.* The pectoralis minor has been detached at its origin and thrown upwards, exposing the blood-vessels which enter its deep surface close to its insertion. A, Deep surface of the pectoralis minor with blood-vessels, B, entering it; C, Clavicular fibres of the pectoralis major; D, Pectoral branches of the acromio-thoracic (thoraco-acromial) axis; E, External intercostal muscle; F, External oblique muscle; G, Serratus magnus muscle; H, Posterior thoracic nerve.

are extensively involved the clavicular fibres of the pectoralis major must be removed. The cephalic vein need not be injured. Not infrequently the axillary artery is freely exposed as well as the vein, and when the acromio-thoracic (thoraco-acromial) axis has to be ligatured, care must be taken not to divide it too close to its origin from the axillary. In separating the fat and glands from the remainder of the axillary vein the dissection should be carried from above downwards

and from without inwards. The sheath of the vessel should also be removed. Before dividing the tributaries of the vein, forceps are applied to them close to their termination, a stump being left to form a pedicle only just long enough to prevent the ligature from slipping. When the subscapular vessels are reached, at the level of the lower

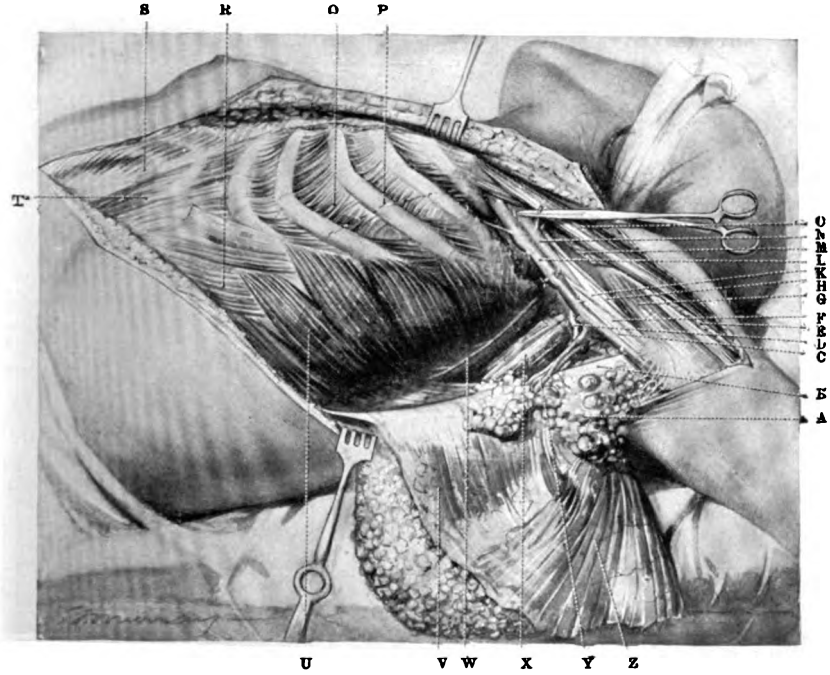

FIG. 29. FURTHER STAGE OF THE COMPLETE OPERATION FOR CARCINOMA OF THE MAMMA. *Clearing the axilla.* The pectoralis minor muscle has been removed and the axilla has been cleared from above downwards. A, Axillary fat and lymphatic glands; B, Tendon of the latissimus dorsi; C, Ulnar nerve; D, Long subscapular nerve; E, Cut edge of the pectoralis major; F, Internal cutaneous nerve; G, Coraco-brachialis muscle; H, Musculo-cutaneous nerve; K, Median nerve; L, Axillary vein; M, Cut edge of the pectoralis minor; N, Axillary artery; O, Clavicular fibres of the pectoralis major; P, Third rib; Q, External intercostal muscle; R, External oblique muscle; S, Infrasternal notch; T, Rectus abdominis muscle; U, Serratus magnus; V, Retromammary fascia reflected from the serratus magnus; W, Posterior thoracic nerve; X, Subscapularis muscle; Y, Subscapular vessels; Z, Posterior surface of the pectoralis major.

border of the subscapularis muscle, they are divided between two forceps at a little distance from the main vessels, and their distal portions are removed along with the fat and glands which surround them. During this procedure the dorsal (circumflex) scapular vessels are clamped and divided, but the long subscapular nerve can generally be isolated and preserved. When the subscapular chain of glands is especially implicated,

as is liable to be the case when the tumour is situated in the lower and outer margin of the breast, it is often necessary to remove the nerve along with the vessels. Unless the glands at the posterior wall of the axilla be extensively involved, it is seldom necessary to interfere with the structures which leave the axilla by passing through the quadrilateral

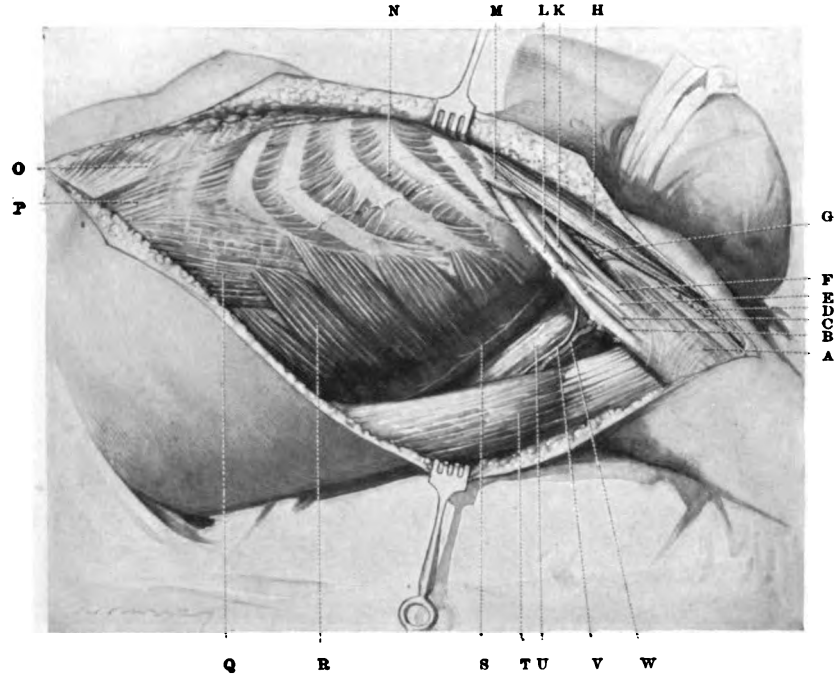

FIG. 30. FURTHER STAGE OF THE COMPLETE OPERATION FOR CARCINOMA OF THE MAMMA. *The axilla cleared.* The breast, the pectoral muscles, and deep fascia have been removed and the axilla cleared. A, Coraco-brachialis muscle; B, Ulnar nerve; C, Internal cutaneous nerve; D, Cut edge of the pectoralis major; E, Median nerve; F, External cutaneous nerve; G, Cut edge of the pectoralis minor; H, Clavicular fibres of the pectoralis major; K, Axillary artery; L, Axillary vein; M, Subclavius muscle; N, External intercostal muscle; O, Infrasternal notch; P, Rectus abdominis muscle; Q, External oblique muscle; R, Serratus magnus muscle; S, Posterior thoracic nerve; T, Latissimus dorsi; U, Subscapularis muscle; V, Long subscapular nerve; W, Subscapular artery.

intermuscular space, *viz.* the posterior circumflex (humeral) vessels and the circumflex (axillary) nerves. The musculo-spiral (radial) nerve is sometimes exposed, but it is not likely to be injured.

Having exposed the axillary vein in its whole extent, the clearing out of the axilla is completed by making a clean dissection of its inner and posterior walls, that is to say, by cleaning the serratus magnus, the subscapularis, and the axillary portion of the latissimus dorsi. When

the axilla is comparatively free from disease, the fatty fascia can usually be stripped off the subscapular muscle by gauze dissection carried in a direction from above downwards and from without inwards. Unlike the long subscapular nerve, the middle subscapular is closely bound down to the muscle and is, therefore, protected from injury. The anterior part of the serratus having already been cleansed at an earlier stage of the operation, *viz.* when the lower and outer quadrant of the breast and deep fascia is dissected off the chest-wall, only the fat and fascia covering the posterior part of the muscle and the gutter-like interval between it and the subscapularis remains to be cleansed. The posterior thoracic nerve, which is met with at this stage of the dissection, can generally be preserved. The lower part of the gutter is bounded externally by the inner surface of the latissimus dorsi, between which and the serratus is a quantity of fatty tissue containing a plexus of veins formed by the anastomosis between the veins of the chest-wall and those which go to form the subscapular vein. In securing these vessels with forceps care should be taken not to include the branches of the long subscapular nerve just where they are about to enter the latissimus dorsi.

The breast and axillary contents, which are attached only in the region of the posterior fold of the axilla, are now completely detached by dissecting them off the outer aspect of the latissimus dorsi, and from the adjacent subcutaneous tissue at the attachment of the axillary portion of the lower flap. The nearer the primary tumour approaches the axillary margin of the breast, the further back should the fat and deep fascia be removed beyond the edge of the latissimus dorsi.

Either at this stage, or immediately before suturing the wound, it is a good plan, especially in well-nourished patients and in those possessing an abundance of breast tissue, to put the lower flap on the stretch with its raw surface directed upwards, while the operator, with a pair of large scissors curved on the flat, trims away any excess of the subcutaneous tissue upon its deep surface.

Before leaving the axilla the operator returns to its apex for the purpose of clearing out the recess which extends upwards behind the vessels towards the root of the neck. The vessels themselves are retracted upwards and outwards, and in clearing the space the upper part of the posterior thoracic nerve is again encountered; it is here accompanied by a vein which may give a little trouble if it is injured close to the axillary, into which it opens high up on its posterior aspect. When all the fatty tissue has been removed it will be found that the space does not extend uninterruptedly into the root of the neck, but that it is roofed in by a fairly well defined fascia. Unless the disease is advanced it is

comparatively seldom that one finds the glands in this situation palpably diseased. If they should be, and if they are at all adherent to the apical fascia, it is advisable to clear out the supraclavicular triangle even although the glands in it are not obviously diseased.

As a rule, it will be found a comparatively easy matter to separate malignant glands from the axillary vein, provided one keeps inside the sheath. When, however, the sheath as well as the glands are firmly adherent to the vein, a portion of the latter must be resected. As a result of this procedure there is often a certain amount of œdema of the arm, but this is not likely to be permanent as long as suppuration does not occur, and provided also that the cephalic vein and the portion of the main trunk proximal to it are left uninjured.

Handley has shown that the persistent brawny swelling of the arm is not due to pressure of diseased glands on the vein, but to cancerous permeation followed by perilymphatic fibrosis and destruction of the lymph-vascular system of the deep fascial lymphatic plexus of the whole circumference of the upper arm, the result being that the lymphatic system of the breast is completely cut off from that of the trunk. In these distressing cases Mr. Handley has had good results from the 'introduction into the subcutaneous tissue of the swollen arm of a number of buried silk threads, running longitudinally upwards from the wrist to terminate in the loose and healthy areolar tissue in and beyond the axilla, and spaced out at convenient intervals around the limb,' an operation which he proposes to designate as lymphangioplasty (see Vol. I, p. 538).

The axillary artery and main nerves, being separated from the glands by the axillary vein, are seldom involved until the disease has reached an advanced stage. It is true that a portion of the artery may be removed without gangrene occurring, but the probability is that in the cases calling for such a procedure the disease is so advanced that recurrence is practically inevitable. In one case, in order to remove the glandular disease, the writer was obliged to divide the acromio-thoracic (thoraco-acromial) artery so close to the main trunk that the latter had to be ligatured immediately above and below the origin of the vessel. No harm resulted, but the patient died ultimately of recurrence.

Ligature of the vessels and drainage. Before closing the wound all bleeding should be arrested, special care being taken to see that the ligatures are applied to the perforating branches of the internal mammary in such a way that they do not slip. In all cases in which the wound can be completely closed it is certainly wiser to drain the axilla by introducing a tube through a stab opening in the posterior flap immediately in front of the latissimus dorsi, about the level of the angle

of the scapula. The tube, which should be 3 or 4 inches in length and about the thickness of the little finger, is placed along the gutter formed by the junction of the inner and posterior walls of the axilla; it should not be so long as to cause pressure on the axillary vessels, and it is better to fix it to the skin opening with a suture rather than simply to transfix it with a safety-pin.

Closure of the wound. If the operation be performed by the long incision and extensive flap dissection above described, it is safe to assert that in cases in which the skin is neither visibly nor palpably involved the edges of the wound can generally be approximated. When, however, the skin is involved, and especially when the tumour is peripheral, some ingenuity and experience are called for in order to close the wound. In cases in which extra skin has been removed in the sternal region, the axillary flap, which is often a little redundant, can sometimes be made to fill in the gap. It not infrequently happens, however, that in attempting to close the gap by dragging the lower flap inwards, it becomes so tightly stretched across the axilla as to interfere with the abduction of the arm. To overcome this difficulty the lower flap must in the first place be dissected well back beyond the posterior fold of the axilla, and at the same time well freed from the upper part of the inner aspect of the upper arm. Having done this, an incision about 3 inches in length is carried backwards into the flap at right angles to the main incision, beginning at a point about 2 inches below the apex of the axilla. By this extra incision the skin which roofs over the axilla can be turned downwards and inwards and stretched across the chest-wall so as to meet the upper flap. The V-shaped gap which is left in the axillary portion of the lower flap is filled in by bringing down the somewhat triangular projection of the upper flap which exists at the junction of the ablation and axillary portions of the main incision (see Fig. 31). By this procedure, which is as simple as it is valuable, the redundant skin of the axilla is utilized to fill in the gap without leaving behind a tight band which would interfere with abduction of the limb by anchoring the upper arm to the side of the chest. Mr. Handley objects to making the original axillary incision along the anterior fold of the axilla on the ground that it leaves a cicatrix which, by its contraction, is liable to interfere with abduction by dragging on the arm. The writer has almost invariably carried his incision a little in front of the anterior fold of the axilla, and he has always found that the complication referred to by Mr. Handley is effectually prevented by the additional incision above described. Mr. Handley prefers to curve the axillary portion of the incision downwards towards the posterior fold. The advantage, however, of including the skin of the axilla in the lower

rather than in the upper flap is that it can be more conveniently made use of for plastic closure of the wound.

When the tumour is situated towards the outer margin of the breast, and a more or less V-shaped or tongue-like additional portion of skin has been ablated from the lower flap, the gap in it can sometimes be filled in simply by dissecting the flap considerably further back and closing the deficiency by uniting its edges at right angles to the main wound. In other cases, especially when an extra amount of skin has been removed towards the inner margin of the breast and the addition

FIG. 31. CICATRIX LEFT AFTER COMPLETE OPERATION FOR CANCER OF THE MAMMA. A plastic closure of the wound was effected by turning in a flap from the axilla in the manner described on p. 81. The dots have been placed at the extremities of the various parts of the cicatrix.

of a straight incision carried backwards into the lower flap at right angles to the main wound is not sufficient to meet the case, a flap may be dissected up from the lateral aspect of the chest and turned inwards, according to the following method introduced by Warren. An incision is carried from the edge of the posterior flap at the level of the lower part of the axilla at right angles to the long axis of the main wound for about 3 inches, after which the knife is carried vertically downwards parallel to the edge of the main incision for about 4 inches. The somewhat tongue-shaped flap is then dissected down and turned forwards and inwards across the gap so that its extremity may be stitched to the inner edge of the main wound. In some cases, instead of making one large

flap as described above, it is more convenient to turn in two smaller ones according to the earlier method employed by Warren.

Another method which contributes towards the closure of the gap is to undermine the upper inner flap more extensively, and to dissect the opposite breast off the pectoralis major muscle, so that it can be dragged over towards the affected side. The anterior perforating branches of the opposite internal mammary artery are divided and must be ligatured. The extent to which the size of the gap can be reduced by this plan is rather disappointing unless it be carried to an extreme degree, which is undesirable on account of the deformity which it produces.

When the skin is so extensively involved that a large 'dinner-plate' incision is called for, it is impossible, especially in spare women, to close the wound completely by any plastic operation, however skilfully planned. Having closed the wound as far as possible, the raw surface which remains should be covered with Thiersch grafts taken from the front of the patient's thigh. This should be done at the same operation rather than subsequently, and if the assistant has had some experience in cutting the grafts, and has them ready prepared by the time the surgeon has completed the suturing, the process adds very little to the duration of the operation and practically nothing to its risk. The grafts should be cut as large as possible; they should be applied with their edges slightly overlapping, and before applying the dressing care should be taken to see that all air-bubbles are pressed out from beneath them, and that their edges are well flattened out. The grafted area should be covered with silver foil, according to the plan originally introduced at the Johns Hopkins Hospital, or with strips of gutta-percha tissue. The raw surface left on the thigh is covered with either of these materials, over which is applied a sterilized gauze compress, fixed either with a bandage or with strips of adhesive plaster applied spiral fashion.

In closing the wound the writer prefers to use interrupted sutures. They take rather longer to introduce than a continuous suture, but they possess the advantage of allowing a certain amount of the wound exudate to escape between them, and they are better adapted for plastic work. Silkworm-gut is used for the deeper sutures, while horsehair will be found most suitable for the intervening superficial sutures.

Dressing of the wound. To cleanse the large skin area previous to the application of the dressing, a good plan is to cover the whole of the front of the chest and upper abdomen with a large gauze swab soaked in a 1% solution of lysol. By pressing the wet gauze firmly against the skin, it will be found on removing it that the surface is freed from blood. Any excess of lysol is then wiped off and a large square of several-ply gauze, wrung out of warm normal saline or a

very weak carbolic or sublimate solution, is applied over the front of the chest and abdomen, well down below the umbilicus. Over this is placed a liberal supply of sublimated wool. The patient is then carefully rolled well over towards the sound side while a similar dressing is applied to the back, care being taken to see that plenty of sublimated wool is used, as it is here that the wound exudate is most likely to reach the surface. Before applying the posterior dressing, however, the soiled sheet upon which the patient has been lying should be removed and a clean one substituted. Too much stress cannot be laid on the importance of applying the dressing over a wide area after the operation for cancer of the breast. In addition to covering the chest and axilla the dressing should extend down to the pelvis and well up to the neck; an extra pad of wool is placed over the base of the axilla, and the upper arm should be covered in down to the elbow. The dressing is secured in position by means of two or three domet bandages which should be carried over the top of both shoulders.

The limb should be placed with the upper arm abducted to the level of the shoulder, the forearm being left free and merely comfortably supported on a pillow in the pronated position with the elbow flexed to about a right angle. No splint is required if the shoulder and upper arm be surrounded with plenty of wool secured in position by a well-applied domet bandage, but if the patient be unduly restless for the first few hours after the operation, the upper arm may be secured to a sand-bag placed between it and the chest-wall. This position of the limb, which was advocated by the late Mr. Edward Cotterill, is a great improvement on the old method of bandaging the arm to the chest—indeed it is safe to say that if the limb be maintained in the abducted position from the outset the functional results are all that can be desired.

AFTER-TREATMENT

As the operation is necessarily a severe one, a slight degree of shock is inevitable. This, however, can readily be combated by the introduction of a liberal amount of normal saline into the rectum by the drop-method introduced by Murphy; a quart should be introduced immediately after the patient has been put back to bed, and, if necessary, this should be repeated once or twice, at intervals of six hours.

If due care be exercised in ligaturing the bleeding points, any reactionary hæmorrhage which occurs should not be sufficient to call for active treatment. It is only in the event of a ligature slipping that it may be necessary to open up the wound for the purpose of suturing the bleed-

ing point. It not infrequently happens, however, that the normal exudate is sufficiently copious to soak through even an abundant dressing. In such a case it is seldom necessary to change the dressing until it is time to remove the drainage tube; it usually suffices to place beneath it a sheet of sublimated wool thickly dusted with boracic powder.

Most authorities recommend that the drainage tube should be removed at the end of forty-eight hours, some even at the end of twenty-four hours. During recent years the writer has been in the habit of leaving the tube in for three days, in order that the patient may be left undisturbed until she is better able to bear the fatigue of having the dressing changed. Another advantage of leaving the tube in for an extra day is that, owing to the division of the main lymphatics at the apex of the axilla, the escape of lymph may continue for some days, while in exceptional cases the flow amounts practically to a lymphorrhœa. When this occurs a special gauze pad should be so arranged as to exert pressure over the infraclavicular region and the apex of the axilla.

The removal of the tube and the first change of dressing should be carried out in such a way as to prevent the possibility of infecting the wound, and at the same time with as little disturbance of the patient as possible. Two assistants are necessary, one of whom should support the arm while the other keeps the dressing in position during the application of the bandage. The patient need not be raised into the sitting posture until the bandage is about to be applied. After cutting and turning aside the bandage a sterilized sheet is spread over the bedclothes below the wound, so as to prevent any possibility of their coming into contact with it. The dressing is then removed from the front of the chest and a fresh one applied, the same care being taken as at the operation to see that it extends well wide of the wound. With the patient next turned gently towards the sound side the tube is removed, after which the posterior part of the dressing is drawn out and a sterilized sheet is pushed in below the patient so as to protect the skin from the bedclothes. The bandage is then applied, the arm being maintained as before in the abducted position. A little sublimated iodoform-bismuth paste may be smeared over the drainage opening, and it is an advantage to wipe the apex of the axilla with a swab moistened with a carbolic or sublimated solution; there is no need, however, to swab the whole wound area with an antiseptic lotion.

After the third day the patient is generally strong enough to be propped up in the sitting posture for the greater part of the day. She may move the forearm to any extent provided that she does not move the shoulder as well. The dressing need not be changed again until a week later, that is to say, until the tenth day after operation. As a rule, all the

stitches may be removed, but should the skin at some part of the wound be considerably stretched, the stitches in that particular region should be left in for a few days longer. Should there be a tendency to sloughing at the seat of tension, a little sublimated iodoform-bismuth paste may be applied to keep the region aseptic, and a little of the same material may be smeared over the stitch openings. The axilla is bathed with a little lysol, or a 5% solution of carbolic, and a dry sterile gauze dressing is applied. After this dressing the patient may be allowed up in a chair for an increasing period each day. A few days later the dressing may be dispensed with, all that is necessary being to protect the recent scar by stitching a sheet of boric lint inside whatever garment is worn next the skin. It is safe to allow the patient to leave the hospital on the twelfth or fourteenth day.

MODIFICATIONS OF OR ADDITIONS TO THE OPERATION

Ulcerating or fungating carcinomas. When operating on fœtid ulcerating or fungating carcinomas of the breast, it is the duty of the surgeon to do all in his power to prevent septic infection, a very dangerous complication if the whole wound becomes involved.

If the ulcer be small it may be disinfected either with the actual cautery or by means of the free use of pure carbolic acid. When, however, the ulcerating area is more extensive or when it is replaced by a large fungating and septic mass, it has been the writer's practice, in cases in which there is a possibility of obtaining a permanent cure, to do the operation in two stages. At the first operation only the diseased area and breast are removed, care being taken not to open up the axilla. The wound may be partly sutured, but no attempt should be made to close it entirely. Ten days or a fortnight later, when the wound is covered with healthy granulations, the operation is completed by removing the pectorals and clearing out the axilla in the usual way.

When the disease in the axilla is extensive. When the disease in the axilla is obviously extensive and it is questionable how far it is possible to remove it, the proper course to adopt is to begin the operation by exposing the axilla. This is done by making a T-shaped incision, one limb of which corresponds to the anterior fold of the axilla, while the other is carried from its centre upwards and slightly inwards to the junction of the inner and middle thirds of the clavicle. After reflecting the flaps the base of the axilla is opened into by dividing the deep fascia along the lower border of the pectoral muscles, while the subclavicular region is exposed by opening up the interval between the sternal and clavicular fibres of the pectoralis major, the pectoral branches

of the thoracic axis being hooked up with the forefinger and divided between two artery forceps. By retracting the two portions of the pectoralis major and opening up the interval as widely as possible, the costo-coracoid membrane is divided and the upper border of the pectoralis minor is exposed and retracted downwards.

The infraclavicular glands and the first part of the axillary vessels are now exposed, and if it be already evident that the disease is irremovable the operation should not be proceeded with unless the conditions are such that a radical operation is likely to prove sufficiently palliative and life-prolonging to make it justifiable. In order to decide this question it will generally be necessary to cut across both pectoral muscles so that the extent of the disease may be more fully investigated. The writer has one patient alive and apparently free from recurrence three years after operation, the glands in her case being so fixed to the axillary vein that three inches of it had to be resected.

If the disease in the axilla be so extensive that it is deemed useless to perform even a palliative operation, the wound should be closed without interfering with the breast itself. If, on the other hand, all visible disease in the axilla can be removed by resecting a portion of the vein, the operation should be completed by removing the breast in the radical manner already described.

Removal of the supraclavicular glands. Surgeons are by no means at one as regards the indications for removing the supraclavicular glands. Halsted, in a valuable paper published in the *Annals of Surgery*, July, 1907, deals with the results of 232 radical operations performed at the Johns Hopkins Hospital. 'The neck operation was done in 101 cases primarily and in 18 secondarily. . . . In 14 patients the glands of the neck as well as the axilla were involved. Three of these, or 7%, were, it seemed, definitely cured.' In each of these three cases the glands were cancerous both to the naked eye and microscopically.

According to Halsted, the operator 'should surely perform the supraclavicular operation, barring, of course, special contra-indications, (1) in all cases with palpable, operable, neck involvement; (2) when the apex of the surgical axilla is involved. When mid-axillary involvement is demonstrable at the operation apical implication is almost certain, and hence (3) in these cases also the neck should be typically cleaned of its lymphatics, as high, at the very least, as the bifurcation of the carotid. We find ourselves for the past two years again performing the neck operation in most cases. We omit it in hopeless cases, in most "duct cancers," and in some carcinomata of emphatically adenomatous type in which the axilla at operation is not macroscopically involved.'

In the present state of our knowledge, it is probable that the majority of surgeons will regard the third indication as insufficient, and there are so many exceptions to the other two as to make the neck operation the exception rather than the rule. Meyer does not appear to be in favour of clearing out the supraclavicular space at the time of operation in the absence of clinical evidence of the presence of cancerous glands in this region.

In the cases operated on by Meyer in which the supraclavicular glands were involved, none of the patients lived longer than nine months after the operation. In spite of this Meyer is of opinion that if the supraclavicular glands are enlarged they should be removed in every instance. He points out that diseased supraclavicular glands are met with more frequently when the primary tumour occupies the upper hemisphere, especially if the skin and subcutaneous tissue be involved as well.

Rodman invariably explores the neck in growths situated in the upper part of the breast because, as he points out, some of the lymphatics from the upper hemisphere pass superficial to the clavicle to join the supraclavicular glands, and the latter may be involved early in the history of cancerous growths located in the upper hemisphere. The writer is of opinion that the supraclavicular region should be cleared in those cases in which the glandular infection has extended upwards along the posterior thoracic nerve *behind* the axillary vein into the root of the neck.

When diseased glands can be felt to extend inwards behind the sternomastoid muscle so as to occupy the angle between the subclavian and internal jugular veins, it is probably wiser not to operate. In these cases it is highly probable that the disease at the inner part of the root of the neck is an extension upwards of infection already existing in the mediastinum. In all probability, too, by this time the disease has already reached the venous system through the thoracic and right lymphatic ducts. Too much must not be expected, therefore, from neck operations, either primary or secondary, in the treatment of cancer of the breast. Should cancerous supraclavicular glands already exist when the patient first presents herself for treatment, each case must be judged on its own merits, and before deciding to operate every attempt should be made to exclude mediastinal, pulmonary, hepatic, and osseous metastasis. If an operation be deemed advisable, the neck should first be explored, and should it be found impossible to remove all the disease, the breast operation should not be proceeded with unless there is reason to believe that it will prolong life and diminish suffering.

To gain access to the supraclavicular glands the upper limb of the T-shaped incision already described for exposing the infraclavicular glands is prolonged upwards along the posterior border of the lower

half of the sterno-mastoid muscle. Or, instead of carrying the incision upwards from the axillary extension of the breast incision, the supra-clavicular region may be exposed by a separate angular incision, one limb of which is placed parallel to, and a little in front of, the lower half of the posterior border of the sterno-mastoid, while the other limb corresponds to the middle two-fourths of the clavicle. The triangular flap thus marked out is dissected upwards and backwards.

The further steps in the dissection for the removal of these glands have already been described by the writer in his article on excision of tuberculous glands.

DANGERS OF THE OPERATION

Considering the size of the wound and the severity of the operation the immediate mortality is remarkably low. Out of 2,133 operations collated by Rodman from the practice of twenty-one American surgeons, between the years 1893 and 1903, the death-rate was less than 1%. The writer has had one death as the result of the operation in upwards of 150 patients operated on by him; the cause of death was sepsis, which occurred during the organization period of a hospital in which the technique had been out of date. The other complications which have proved fatal are pneumonia and bronchitis, hæmorrhage, shock, and pulmonary embolism. To minimize the risk of pulmonary complications the temperature of the operating theatre should not be below 65° F. The field of operation should be surrounded with dry sterile sheets in preference to wet carbolic towels, and the operation should not be unduly prolonged. If ether be the anæsthetic employed it should be administered by the open method rather than by the Clover apparatus. In elderly patients with a tendency to bronchitis, chloroform should be used in preference to ether.

PROGNOSIS AS REGARDS PERMANENT RECOVERY

The *ultimate results* of the operation are, of course, influenced by the variety of the cancer, the extent of the disease, and the thoroughness of the operation.

Sir Watson Cheyne's results, published in 1904, show that 50 to 55% of the patients operated on by him were alive and well six to thirteen years after operation. These statistics do not include cases in which it was obviously impossible to remove all the existing disease.

This subject was dealt with by various surgeons at the Meeting of the American Surgical Association in 1907. Halsted, after excluding

sixty-five cases in which it was obvious that all the disease could not be removed, gave the results in 232 cases in which the complete subclavicular operation was performed at the Johns Hopkins clinic. The eighteen cases which could not be traced were tabulated as dead of the disease. In the sixty-four cases in which no glandular involvement was discovered it was found that in fifteen (23.4%) the disease remanifested itself either in the form of a local recurrence or of a metastasis. As pointed out by Halsted, these cases show the necessity for wide operation even although the disease is in the early stage. No less than 80% of the patients in whom glandular involvement could not be demonstrated were free from signs of the disease for three years. Of the 110 cases with axillary involvement and negative neck involvement, twenty-seven cases, or 24.5%, were cured for periods ranging from sixteen to three years. By adding eleven untraced cases with axillary involvement to the 110 in which the result was definitely known, the percentage of cures in this category was reduced to 22.4%. Halsted comes to the conclusion that in the early stage of the disease the modern extensive operation cures two out of three patients, while three out of four patients succumb who are operated on after the axillary glands have become demonstrably involved.

Willy Meyer, of New York, gave the end results of eighty-four patients operated on by himself during the twelve and a half years previous to the meeting. 44% lived from three to twelve and a half years after operation; 50% died of the disease within three years after operation, eight of these from internal metastasis without any local or regional recurrence.

At the same meeting Drs. Greenough, Simmons, and Barney gave, in a joint communication, the end results of 376 primary operations for carcinoma of the breast performed at the Massachusetts General Hospital during the ten years prior to January 1, 1904.

As regards the *extent of involvement,* it was found that when the tumour was not adherent to the skin, 32% of cures were obtained as against 16% when the tumour was adherent. Only 11% of successes were recorded when the tumour was adherent to the chest-wall, whereas 21% were free from recurrence when no such adhesion existed.

'Enlarged glands in the axilla were felt before operation in 236 cases, with 12% freedom from recurrence. No glands were felt in 117 cases, with 29% successful results. This suggests that absence of palpable enlargement of the axillary glands is a favourable indication, in spite of the fact that the glands removed as a routine measure are almost invariably found to be malignant.' Palpable enlargement of the glands above the clavicle occurred in forty cases, of which only two survived, and those were cases in which the enlarged glands were removed and

found not to be cancerous on microscopic examination. No cases recovered in which palpably enlarged cancerous glands were detected in the neck. All the six cases in which both breasts were involved died of the disease. Of sixty-six cases in which the tumour had progressed to ulceration, 6.6% of recoveries took place, while of 316 cases in which no ulceration was present, 21% were free from later recurrence.

With regard to the influence of the *variety of the cancer,* medullary carcinoma gave 16% of cures, scirrhous cancer 23%, adenocarcinoma 47.6%, colloid cancer 66%. 28% of cures were obtained after operations for cancer in lactating breasts. It is interesting to note that only 12.5% of cures were obtained in Paget's disease.

The statistics of these authors showed also the extent to which the results were influenced by the *amount of skin removed.* 'In sixty-seven of the complete operations so much skin was taken that a plastic operation or skin graft was necessary to close in the defect. The end results of these cases (19.4% free from recurrence) were better than those in which the skin edges were readily drawn together (11.7% free from recurrence), but showed most conspicuously in the matter of recurrence in the scar; 57.6% of the plastic operations remained free from local recurrence in the scar, while only 44% of the sutured wounds were thus successful.'

With regard to *late recurrence,* 'eighty-eight cases passed the three-year period without recurrence, but of these seventeen (19%) showed metastasis later—exactly the percentage found by Schröder from a study of the cases at the Rostock clinic.'

Ransohoff, as the result of investigation by Labhardt, Koenig, Poulsen, Schröder, and Wunderli, has come to the conclusion that 'of those who have safely passed the three-year limit, about 20% succumb later to recurrence *in loco* or to visceral, bone, or gland metastases.'

According to Smith, although 40 to 50% of cases appear to be free from the disease three years after the operation, the percentage of permanent cures without this limitation falls to 17%, and Barker asserts that 30% of those living three years after operation ultimately die of the disease.

EXCISION OF THE MAMMA WITHOUT OPENING THE AXILLA

Indications. The more important conditions for which this operation is performed are: Diffuse lobular (parenchymatous) mastitis, especially when associated with the presence of multiple cysts; certain

cases of diffuse interstitial mastitis; tuberculous mastitis; cases of acute suppurative mastitis in which the breast tissue has been largely destroyed, and in which the organ is riddled with old-standing sinuses. The operation is also indicated when the breast is the seat of a neoplasm which, at first simple and slow growing, has taken on a more active growth, and when there is the slightest suspicion of local malignancy. Under this heading are included tumours of the fibro- and myxo-adenomatous type which are not truly encapsulated, as well as those which show signs of becoming sarcomatous, while of the tumours of the epithelial type must be mentioned those duct and cyst papillomata which show a tendency to invade the adjacent breast tissue.

Operation. The breast may be excised either with or without the removal of a portion of skin surrounding the nipple.

1. When the nipple and a portion of skin are removed, the typical incision takes the form of an ellipse with the nipple more or less in its centre (see Fig. 32, A). The direction of the ellipse is generally placed so that its long axis is a little nearer the horizontal than the vertical diameter of the organ, while its length as well as its width will depend, of course, on the size and configuration of the mamma. When the breast is pendulous the lower edge of the ellipse should be carried further away from the nipple than the upper edge, so as to bring the resulting cicatrix as low down as possible. Care should be taken to taper away the extremities of the ellipse sufficiently to prevent 'humping' of the skin by the suturing of the ends of the wound. Needless to say the typical incision may have to be departed from when the skin is involved at some distance from the nipple, or when sinuses are present.

In spare women, when the breast is neither well developed nor pendulous, care must be taken not to make the ellipse unnecessarily wide, as the extra tension required to close the wound is calculated to give rise to a broader cicatrix than would otherwise be the case. If the ellipse be made too wide the only way to minimize the mistake is to lengthen the incision so that the flaps may be more extensively undermined.

In dissecting the flaps off the breast it is of little or no moment which is taken first. The only advantage in beginning with the lower flap is that there is no chance of the field being obscured by blood trickling down from above. When the flaps have been dissected up sufficiently, the breast itself is seized with the left hand and rapidly dissected off the pectoralis major and serratus magnus, the separation being made in the loose cellular plane which intervenes between the deep surface of the corpus mammæ and the pectoral fascia. In the absence of special indications it is not necessary to remove the pectoral fascia.

In stripping off the breast it is well to begin at its inner margin and to cut with long rapid sweeps of the knife, carried mainly parallel to the fibres of the pectoral muscle, in a direction from above downwards in removing the right breast, from below upwards when the left breast is being removed. The bleeding is comparatively slight. A few vessels, chiefly veins, are divided in the subcutaneous tissue, while the only arteries worthy of being caught up are the two or three uppermost perforating branches of the internal mammary, the long thoracic, and one or two cutaneous branches of the intercostal arteries where they perforate the fascia covering the serratus magnus.

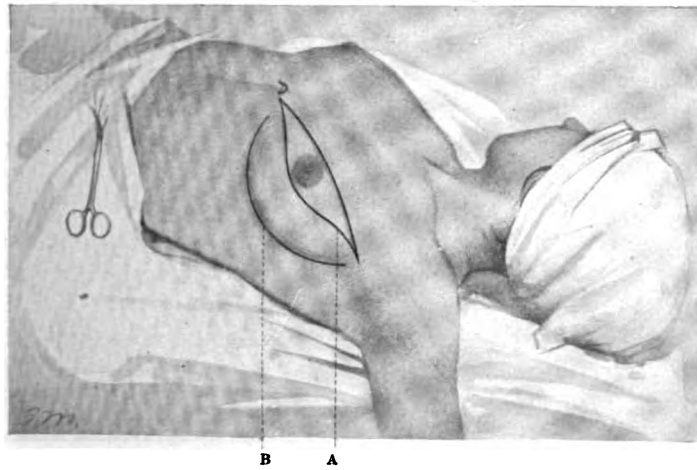

FIG. 32. INCISIONS FOR REMOVAL OF PART OR THE WHOLE OF THE BREAST. A, Elliptical incision for the removal of the breast without opening the axilla; B, The Thomas-Meyer incision for removal of a simple tumour, a cyst, or a portion of the breast by the retromammary route.

If the edges of the wound are to be united by a closely applied continuous suture without drainage, great care must be taken to ligature even the smallest bleeding points, otherwise a hæmatoma is liable to form under the flaps, especially if the vomiting which results from the anæsthetic be accompanied by much straining. When no drainage is used it is wiser to close the wound with an interrupted suture, preferably of silkworm-gut or horsehair. As a rule, to be on the safe side, it is better to introduce a small drainage tube through a puncture opening in the lower flap.

In applying the dressing the shoulder is included and the axilla well padded, but the arm should not be bandaged to the chest. By means of a modified spica bandage the arm is kept slightly abducted, and the

movements of the shoulder are at the same time sufficiently restricted. If a tube has been introduced it should be removed on the third day, after which the patient is allowed up with the arm supported in a sling.

If in performing the above operation the surgeon wishes to explore the axilla, all that is necessary is to prolong the outer extremity of the incision so as to divide the axillary fascia, after which the lower borders of the pectoral muscles are exposed and retracted upwards. 'Exploration' of the axilla, however, is an unscientific procedure, as the absence of visibly enlarged and palpably indurated glands is no proof of the absence of microscopic disease. Hence, if there is any question as to the possibility of glandular infection, the axilla should be cleared, and to do this thoroughly the pectoral muscles must be removed.

2. When the nipple and skin are healthy and non-adherent, it is often advisable, especially for cosmetic reasons, to excise the breast without removing the nipple. This procedure is peculiarly applicable in removing the breast for the diffuse form of chronic lobular mastitis associated with multiple cystic disease.

The operation is performed by making a semilunar incision along the thoracico-mammary furrow for an extent corresponding to the edge of the lower and outer hemisphere of the breast. The upper extremity of the incision ends at or immediately behind the anterior fold of the axilla (see Fig. 32, B). If the breast be large and pendulous, it is advisable, instead of making a simple curved incision, to remove a crescentic portion of skin.

The semilunar flap, which should include as much of the premammary fat as possible, is dissected off the corpus mammæ, care being taken not to button-hole it in detaching the nipple and areola. Before the operator attempts to dissect out the inner part of the organ, the circumference of the outer hemisphere is defined and freed, after which this half of the organ is dissected up off the serratus and pectoralis major as far inwards as possible. The operator now seizes the outer hemisphere with the left hand and pulls it well towards him while he undermines the skin covering the inner hemisphere, the assistant at the same time keeping the skin flap drawn well upwards. After the breast has been removed, the assistant everts the flap and protrudes its subcutaneous surface well into the wound, so that the bleeding points may be exposed and ligatured. The perforating branches of the internal mammary artery should be sought for and ligatured, otherwise a hæmatoma is liable to form after the flap has been sutured back into position. In any case, it is wiser to employ drainage, either by means of a strip of gauze or a small rubber tube.

The after-treatment is the same as described above.

PARTIAL RESECTION OF THE MAMMA

This operation is most frequently called for in the treatment of the localized form of chronic lobular (parenchymatous) mastitis with or without the presence of cysts, in the adherent fibro-adenomatous tumour-like growths due to chronic inflammatory hyperplasia of a lobule of the glands, in localized interstitial mastitis, in gummatous mastitis, and, more rarely, in the localized form of tuberculosis of the mamma. It is also the most satisfactory method of dealing with all simple cysts of the breast which are large enough to give rise to discomfort. The wall of all cysts of the breast is so intimately related to the surrounding fibrous stroma of the organ that it is impossible to remove it without taking away the portion of the organ in the immediate neighbourhood.

Operation. If the portion of breast tissue to be removed be situated either in the outer or in the lower hemisphere, the resection is best carried out by the retromammary route, a method first introduced by Galliard Thomas, and further elaborated by Warren. A curved incision is made along the thoraco-mammary fold, the length and position of the wound depending, of course, on the size and situation of the portion of breast to be removed (see Fig. 32, B). Even when the disease is situated in the upper and inner quadrant it is generally possible, by increasing the length of the incision, to deal with it by the same route; if not, a straight incision which radiates from the nipple must be made directly over the wedge to be removed. After the outer edge of the pectoralis major has been reached and the retromammary cellular space has been opened up to the full extent of the wound, the operator or his assistant grasps the breast in such a way as to protrude its posterior surface into the wound. The surgeon, after carefully palpating the breast tissue to ascertain how much should be removed, seizes the affected area with volsella or other suitable grip-forceps, and by means of two radial incisions resects a wedge-shaped portion, the apex of the wedge being directed towards the nipple. As pointed out by Warren, the wedge removed should not include the adipose layer which lies in front of the mamma, as its presence helps to prevent a subsequent depression. If a cyst of considerable size should be accidentally opened into, the further steps of the operation may be facilitated by stuffing the cavity with a strip of gauze. Should the cyst contain an intracystic epithelial growth, or should small cysts be revealed on the cut surface of the adjacent breast tissue, the question of the removal of the whole breast will have to be considered.

In excising a cyst or fibro-adenomatous nodule embedded in breast

which contains a good deal of adipose tissue, and which is less firm and compact than usual, it is often more convenient to carry out the resection by means of scissors than with a knife. The portion of breast removed should always be very thoroughly sliced up and examined in a good light, to make sure that the indurated area does not contain a small atrophic scirrhus, or the earliest stage of an adenocarcinoma, the latter condition being the form of malignant disease into which chronic parenchymatous mastitis (chronic cystic mastitis of König) is liable to develop, should the proliferating epithelial cells penetrate the walls of the acini and invade the surrounding connective tissue. It is in this class of case that the diagnostic value of the writer's nitric acid test is so helpful.

The oozing from the cut surface of the breast may be a little troublesome, as the application of ligatures to the small vessels of the breast tissue is often difficult in consequence of the compact nature of the fibrous stroma in which they are embedded. The breast tissue on either side of the V-shaped incision is approximated with a double row of buried catgut sutures, one adjusting the anterior edges of the wound and the other its posterior lips. When the corpus mammæ is poorly developed a single row of sutures is sufficient. By bringing the cut surfaces of the breast tissue firmly and accurately in contact, no space is left into which blood may accumulate, nor is any depression left on its surface.

When the operation is being done for cystic mastitis, Warren recommends that the remaining segments of the gland be incised by a series of radiating incisions, so as to lay open and bring about permanent disappearance of the smaller cysts. Cysts, the size of a pea, are snipped out with scissors. The number of radial incisions will depend largely on the amount of gland tissue present: as a rule, three or four are sufficient.

The writer is inclined to think that most surgeons will agree with him that when, in addition to a large cyst, or a cluster of smaller ones, others still smaller are scattered throughout the breast, the whole organ had better be removed. To leave a number of scars in the substance of a breast the seat of cystic parenchymatous mastitis is not only calculated to render the organ abnormally sensitive and tender, but, what is more important, leaves the patient with a breast which is both physiologically and mechanically damaged, and which, in consequence, is more liable to undergo malignant degeneration.

PLASTIC RESTORATION OF THE BREAST

In those cases in which it is possible to excise the entire contents of the breast in cystic disease instead of doing a complete resection it may be

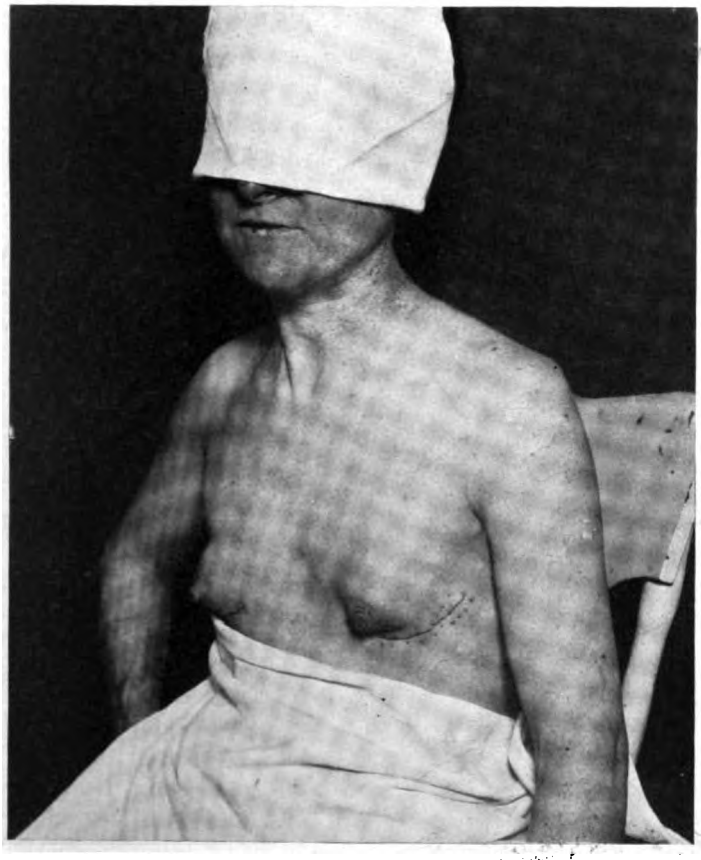

FIG. 32A. PHOTOGRAPH OF PATIENT AFTER RESTORATION OF BREAST BY FAT TRANSPLANT. (*Kanavel.*)

found advisable to so operate as to permit of a restoration of the normal contour of the breast. This may be done by the transplantation of fat after the removal of the cystic disease. Kanavel and others have described operations for this purpose. The technique employed by Kanavel is as follows:

An incision is made at the dependent portion of the breast in the crease, about 4 inches in length. Sutures are then placed concentrically about 2 inches from the nipple, so that the surrounding skin is brought

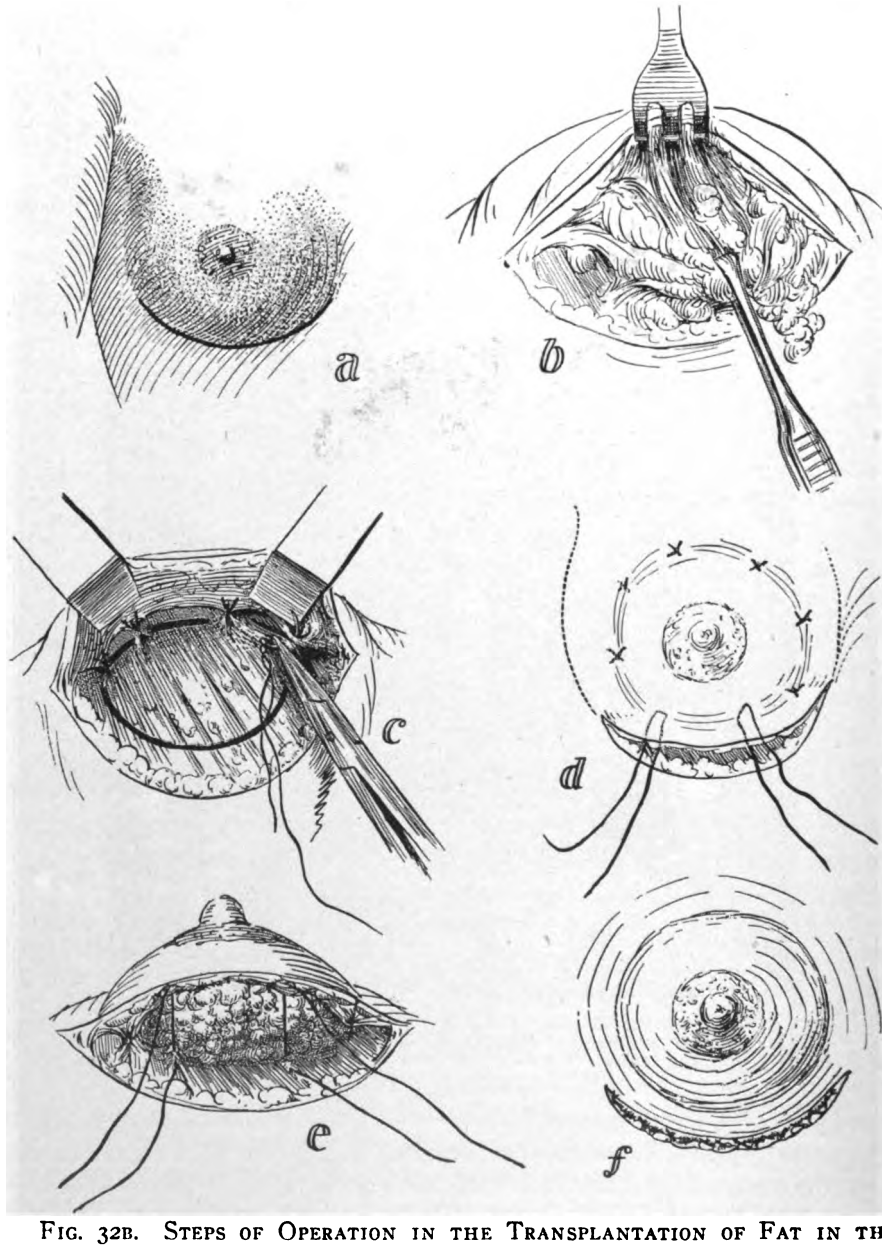

FIG. 32B. STEPS OF OPERATION IN THE TRANSPLANTATION OF FAT IN THE RESTORATION OF THE BREAST. (*Kanavel.*)

intimately in contact with the underlying muscle, and into this central area a transplant of fat of sufficient size to restore the contour of the

breast, ordinarily 2½ inches in diameter and 1 inch in thickness, is inserted. The remaining sutures surrounding this are then placed so that the fat transplant is held firmly in position. The skin is closed by a subcuticular stitch. Over the whole is placed a compression pad, the centre of which has been removed so that the fat may be held firmly in the position desired. The technique of the procedure is understood from the illustration presented, and the results to be obtained may be seen by the photograph of the patient herewith presented (see Figs. 32A and 32B).

OPERATIONS FOR ACUTE ABSCESS OF THE MAMMA

A *premammary abscess* should be opened early by a comparatively small incision radiating from the nipple. The healing is hastened by curetting the wall of the cavity with a sharp spoon. If the abscess be small, one or two strands of iodoform worsted or gauze are introduced in preference to a drainage tube. These may be removed on the third day, after which healthy granulation and cicatrization rapidly occur, so that in many cases nursing of the infant need not be abandoned.

Care must be taken to distinguish between a simple localized engorgement of the breast and the early stage of an *intramammary abscess.* If an incision be made in the former condition severe hæmorrhage may result. In cases of doubt the milk should be examined for micro-organisms, and the indurated area should be carefully palpated morning and evening in search of any sign of softening or deep fluctuation. As soon as either is discovered, no time is to be lost in having recourse to the knife. Every possible means must be taken to prevent contamination of the abscess with saprophytic organisms, otherwise the abscess will go on discharging for a lengthened period, and persistent sinuses are liable to form. A general anæsthetic should be administered, as the part is much too tender to admit of the skin being thoroughly purified without it. The incision should have a direction radiating from the nipple, with the double object of sparing the vessels as well as the ducts. It should be made directly over the softened or fluctuating area of the phlegmon, and it should be at least large enough to readily admit the finger, which must be introduced into the cavity in order to freely break down the sloughing remains of the intralobular septa which separate the various loculi of the abscess. One or more counter-openings are often necessary, as free drainage is all important.

Phlegmonous inflammations of the breast should be treated on the same principle as those occurring elsewhere, and the surgeon will do better to err on the side of too free, rather than of too limited, incisions. If outlying suppurative foci are present, the wound should be opened

out with retractors, and the foci removed with a sharp spoon, aided, if necessary, by scissors. If the infective process be allowed to extend from one lobe to another the whole gland may become destroyed. The wound, if larger than is necessary to admit a large drainage tube, may be partially closed by the introduction of one or two deep silkworm-gut sutures. The drainage tubes should not be kept in longer than is necessary, as they tend to favour the formation of sinuses. Irrigation of the abscess at the time of operation with a hot weak antiseptic or sterile lotion has the advantage of washing away a quantity of sloughing tissue, while at the same time it arrests the bleeding. If the hæmorrhage proves troublesome the cavity should be firmly packed.

A moist antiseptic dressing is applied next the skin, and over this a liberal amount of sublimated wool. The bandage should be applied so as to exert as much pressure as the patient can comfortably bear.

An acute *retromammary abscess* should be opened through an incision at the margin of the lower and outer quadrant. After the pus has been evacuated, the breast, which had been previously floated up, may sink down and interfere somewhat with the drainage; when this happens, a second incision should be made towards the sternoclavicular margin of the breast.

When *persistent sinuses* remain after puerperal mastitis the history is generally somewhat as follows: The sinuses have existed for several months or even for a year or so; they date back from the last puerperium, or, it may be, from the one before. The original abscess, which had been allowed to burst spontaneously, or had been imperfectly drained, was allowed to become infected with saprophytic organisms, and a succession of abscesses formed at different parts of the breast.

To bring about healing of the sinuses the patient should be anæsthetized, the sinuses should be thoroughly scraped, swabbed out with pure liquid carbolic acid, and stuffed with iodoform gauze. If the sinus be long and blind, it should either be laid freely open, or a counter-opening should be made and the channel stuffed. If this does not suffice, the whole sinus, along with a wedge of adjacent breast tissue, should be excised, and the surfaces brought together with catgut. Should the sinus proceed from a firm and deeply-seated induration, the possibility of superimplanted malignant disease must be kept in mind. In such a case the axilla should be carefully examined, and, if there be any doubt about the diagnosis, the surgeon must obtain the consent of the patient to remove the whole breast, should further investigation at the time of operation reveal a state of malignancy. When the breast is riddled with a network of anastomosing sinuses, excision of the whole organ is the only course open to the surgeon.

CHAPTER II

MALIGNANT DISEASE OF THE BREAST

BY

W. SAMPSON HANDLEY, M.D., M.B., F.R.C.S.
Captain R.A.M.C.(T.)

Hunterian Professor of Surgery and Pathology in the Royal College of Surgeons of England. Surgeon to the Putney Hospital.

ETIOLOGY

ONE out of every three cases of malignant disease in the female affects the breast. Among males only one case of cancer in a hundred affects this organ. The upper and outer quadrant is the seat of election, though no part of the breast is exempt. The liability of married and unmarried women to cancer is about equal. It seems likely that irritative pressure, as by the steel springs of corsets, may be a factor in causation.

A blow upon the breast may be followed within a short time by the development of a carcinoma, and a history of injury is present in about 10% of cases. These facts are of considerable medico-legal importance. Cancer is unknown before puberty and becomes common only after 40. It is most frequently seen in the years coming just after the menopause. There is much evidence that chronic mastitis is the most important factor predisposing to breast cancer. Victor Bonney found chronic mastitis present in all the breasts removed for early carcinoma which he examined. Duct papilloma of the breast, if unhealed, passes in the course of years into carcinoma.

Clinical classification of breast cancers. Breast cancers are clinically divided into medullary cancer, scirrhus, and atrophic scirrhus. A medullary cancer is produced if the epithelium multiplies very rapidly while at the same time the formation of stroma is restricted in amount. A soft, bulky tumour is thus produced in which evidence of fibrosis and contraction is absent. The exact opposite to this condition obtains in atrophic scirrhus, a form of growth most often seen in old age. Here the epithelium proliferates but slowly, whilst stroma formation and

fibrosis predominate, and a scar-like growth results, sometimes not forming a palpable lump, although the whole breast is slowly puckered and atrophied.

Intermediate between these two forms of growth and more frequent than either is the ordinary scirrhus, where the processes of epithelial formation and stroma formation are more equally balanced. A tumour of moderate size and of stony hardness results.

Microscopic varieties of breast cancer. Carcinoma may originate from the acini, or secreting recesses of the breast, which are lined by cubical epithelium. It is then called spheroidal-celled carcinoma. It may arise from the columnar epithelium lining the ducts of the breast, and is then called columnar-celled or duct carcinoma.

Mr. Lenthal Cheatle has shown that many so-called spheroidal-celled carcinomata are originally columnar and originate in the ducts.

Usually a carcinoma of the breast begins at one particular point, but sometimes it appears to light up throughout an extensive area of the breast. This is most likely to occur in an area previously the seat of chronic mastitis. Carcinomata of this type are multi-centric in origin and are often particularly malignant. They are generally called diffuse carcinomata.

Dissemination of breast cancer. It is the most striking feature of breast cancer that deposits similar in nature to the primary growth may ultimately be found scattered irregularly in distant parts of the body. Only a few years ago it was believed that particles of the primary growth, after passing through the axillary and supraclavicular glands and reaching the blood-stream, lodged themselves in different parts of the body and so produced secondary growths. The evidence goes to show, however, that such particles as do reach the blood are generally destroyed and that breast cancer spreads mainly by the lymphatics.

The carcinomatous epithelium infiltrating the interstices at the edge of the primary growth soon finds its way into the small lymphatic vessels. Growing along these in a tendril-like fashion—a process which the writer has termed permeation—the cancer cells reach the pectoral lymphatic plexus lying behind the breast. This plexus forms an easy route for the extension of permeation, and a continually increasing area of the plexus—an area forming a circle with the primary growth as its centre—is infiltrated. This fact is of fundamental importance in the operative treatment of breast cancer.

After a time the tributary lymphatics of the fascial or pectoral plexus, coming from the skin above or from the muscles beneath are in their turn infiltrated by permeation, but the area of skin and muscle affected is smaller than the implicated area of deep fascia.

Infection of the axillary glands. At some stage in the process just described cancer cells intrude from the smaller lymphatics into the large trunk lymphatics which run to the axillary glands. As soon as this happens little emboli of cancer cells are carried to the glands by the current of lymph. Later this fact is made clinically evident by enlargement of the axillary glands, but it must be clearly understood that, as far as general infection is concerned, the axillary glands are a cul-de-sac, a barrier to the spread of dissemination.

Visceral dissemination. The extension of permeation along the muscular tributaries to the fascial plexus beneath the breast ultimately takes the cancer cells through the parietes to the sub-serous—*i.e.* sub-pleural or sub-peritoneal—lymphatic plexuses by processes which are subtle, microscopic, and slow. Ultimately, it may be after a few months or after twenty years, cancer cells escape from the sub-serous plexuses into the pleural or peritoneal cavity. They are thus placed at last in a position to attack the viscera far and wide, and within a few months the patient's death follows from widespread visceral metastases.

The danger point in regard to the invasion of the abdomen is, as I have shown, the epigastric angle where the fascial lymphatic plexus is separated from the sub-peritoneal lymphatic plexus only by the linea alba and sub-serous fat. It is here that cancer most frequently reaches the abdominal cavity. The first evidence of its having done so is often found in the pelvis, for gravity carries the infected cancer cells down to the pelvis, where they produce secondary deposits in the ovaries or the pouch of Douglas. Hence it is necessary not to omit a pelvic examination prior to operation if the disease is at all advanced.

PERMEATION AND INFILTRATION CONTRASTED

Some recent writers have used the terms permeation and infiltration indiscriminately, and it will be well to lay down clearly the differences between these two modes of spread of carcinoma and to indicate their relative importance.

INFILTRATION.	PERMEATION.
In point of time the earliest disseminative process.	In point of time, begins after infiltration.
Best seen at the edge of the primary growth, as defined by the naked eye.	Best seen at the *microscopic growing edge, which*, in cases, may be situated, in apparently normal tissues, 6 in. or more from the apparent edge of the primary growth.

The cancer cells are spreading along the tissue interspaces, *e.g.* between fat cells or between adjoining fibrous bundles.

If infiltrating cancer cells intrude into a capillary lymphatic vessel the process of infiltration merges into that of permeation.

Infiltration is a very slow process, because of the resistance offered to the passage of cancer cells through the cramped and tortuous tissue interspaces.

Infiltration, on account of its slowness, is of relative unimportance as a factor in general dissemination.

The lymphatic vessels, not the lymphatic spaces, are filled up and choked by solid cords of cancer cells. The tissue interspaces are free from cancer cells.

If a permeated lymphatic ruptures, the cancer cells set free may infiltrate the surrounding tissues. Thus permeation may lead to infiltration.

Permeation is a more rapid process than infiltration, because the cancer cells are growing with little resistance along the open lumen of the lymphatic vessels.

Permeation may carry cancer cells to a very considerable distance from the primary tumour, and is capable of traversing the minute anastomotic lymphatic plexuses. It is accordingly the principal factor in general dissemination.

Summary.—Three main processes are concerned in dissemination: (*a*) permeation; (*b*) infiltration; (*c*) transcœlomic implantation. Less important parts are played by (*d*) lymphatic embolism, which leads only to gland deposits, and (*e*) blood embolism.

Lymphatic obstruction in breast cancer. Some of the later signs of cancer are produced by lymph stasis in the tissues owing to permeation and fibrosis of the lymphatics. Lymphatic œdema of the skin produces the appearance of pig-skin or peau d'orange. The early stage of the condition called cancerous pachydermia, or cancer *en cuirasse*, is also due to lymphatic œdema, combined later with nodular infection of the skin by cancer. The swollen and œdematous arm so frequently seen in the late stage of breast cancer (brawny arm) is also a manifestation of lymphatic obstruction. The serous effusions in the pleura or peritoneum, which so often usher in the final stage, are also caused by lymphatic block.

Pathological classification of the signs of breast cancer. The signs of breast cancer can be divided into classes:—

a. Those dependent upon the presence of the primary growth and upon its infiltrative tendencies (fixity of the tumour in the breast; adhesion to skin and fascia).

b. Those dependent upon permeation and subsequent fibrosis of the lymphatics of the surrounding districts (dimpling of the skin, shrinking of the breast, elevation and retraction of the nipple).

c. Those dependent upon lymphatic obstruction (orange-rind skin, brawny arm, serous effusions).

d. Those dependent on fibrosis and failure of nutrition in the central parts of the older deposits (ulceration of primary growth, ulceration or umbilication of the older secondary deposits).

e. Those dependent upon the formation of satellite or metastatic nodules:—

1. In the lymphatic glands, from lymphatic embolism.
2. In continuity with the primary growth, as terminal outcrops of long lines of lymphatic permeation.
3. In the viscera and serous membranes, from invasions of the serous cavities and subsequent transcœlomic implantation.
4. Those resulting from blood embolism.

The first sign noticed by the patient. In four-fifths of the cases the patient seeks advice because she finds a lump in the breast. As a rule, in its early stage no pain or, at the most, an occasional twinge is felt in the lump, a fact which frequently leads patients to defer seeking advice. Sometimes the lump is first felt in the axilla. Discharge or bleeding from the nipple, retraction of the nipple, discolouration or puckering of the skin, contraction or ulceration of the breast, swelling of the arm, pain in the spine, hip or abdomen, fracture of the femur and abdominal swelling, or signs of paraplegia—each of these conditions may be exceptionally the first sign noticed by the patient. It is very important to recognize that a lump in the breast which proves to be a carcinoma may not present any character which implies its malignancy prior to operation. Any well-defined solid lump in the breast in a woman over forty should be explored without delay.

If the services of a pathologist skilled in making frozen sections can be obtained, the growth should be examined immediately at the time of operation, and if necessary the complete operation for cancer should be at once performed. Failing immediate examination, the small incision should be sewn up and further steps deferred until the result of the pathological examination is known.

The various signs of breast cancer must now be more closely considered. The lump in the breast is usually very definite and easily palpable with the flat hand, a point of distinction from the vague indurations of chronic mastitis. It is characteristically single, of stony hardness and fixed in the substance of the breast; but to this rule there are many exceptions, and in its early stage a small carcinoma may be movable and quite indistinguishable from an innocent tumour.

Dimpling, or retraction of the skin, is one of the earliest and therefore perhaps the most valuable of the signs of carcinoma. In its early stage

it requires a practised eye and hand to detect the slighter degrees of this sign. The finger and thumb placed firmly on the skin on opposite sides of the growth are to be slowly approximated. In carcinoma the convex fold of skin which is thrown up by this manœuvre presents upon its summit a slight and shallow circular depression. In other cases a definite fold may fail to appear and may be replaced by a number of parallel wrinkles.

Dimpling of the skin may sometimes be demonstrated by pushing the whole breast towards the suspected area of skin. If this area is attached to an underlying tumour a local depression appears upon it. In the earlier stages of dimpling, the skin still moves over the subjacent growth, but later on an area of skin becomes firmly fixed to the growth. At this stage the appearance of pig-skin or peau d'orange is usually seen. The orifices of the sweat ducts and sebaceous follicles become unduly large and obvious, a phenomenon which depends upon lymphatic œdema of the skin.

Growths which are situated deep in the breast early become fixed to the pectoral fascia, and it is important to appreciate the exact method of eliciting this sign. The arm should be raised above the head, so as to make taut the fibres of the great pectoral. The growth is now grasped and is moved to and fro in a direction parallel to the fibres of the muscles; partial or complete fixation may thus be detected. Movements at right angles to the fibres are, of course, present even when the growth is firmly fixed to the muscle.

When a carcinoma is present in the breast the processes of fibrosis which occur round it often lead to local flattening of the curved contours of the breast. Lenthal Cheatle was the first to draw attention to this sign.

Enlargement of the axillary glands is often already present when the patient first seeks advice. This is an unfortunate fact, for the prognosis is much more favourable if the growth has not yet infected the glands. The affected glands are hard and mobile. A characteristic point is that they are not tender, differing in this respect from the enlarged glands which may be found in chronic mastitis. In late cases the glands become fixed to the skin, or even to the thoracic wall. In examining the axilla for glands the hand is made into a cone and pressed up along the outer wall of the armpit. The finger tips are then transferred to the inner wall and are slowly drawn downwards still firmly pressing upon it. As they descend the enlarged glands can be felt to slip past the finger tips. In many cases, especially if the growth is situated immediately beneath it, the nipple becomes first flattened and then indrawn, so that a conical depression replaces an elevation. Moreover,

the whole breast is often drawn up towards the pectoral fascia, so that the nipple on the affected side is higher than the sound nipple. This sign indicates extensive permeation of the breast lymphatics.

The signs so far described may all be met with in the operable stage of the disease. Those now to be dealt with show that the prospect of operation is already overclouded. Ulceration of the growth follows adhesion of the growth to the skin. The ulcer has a sloughy, irregular base, and thickened, rampart-like edges. If its surface is neglected it may become extremely foul, giving rise to a thin offensive discharge, or sloughs may form upon it and serious bleeding may occur. Pain in the breast is met with in the later stages, especially when ulceration has already occurred. It should be more generally known to the public that cancer in its early stages is painless. Nodular invasion of the surrounding skin, if extending more than two inches from the primary growth indicates that the growth is beyond the range of operation. Enlargement of the supraclavicular glands, though an unfavourable sign, does not stamp the case as inoperable if the glands are still mobile. More than one case in my series remains free from recurrence five years or more after the removal of such glands.

Diagnosis. It must be clearly understood that in the most favourable stage for operation, before adhesion to the skin has developed, cancer of the breast is not clinically recognizable; hence a doubtful tumour of the breast occurring in a patient over 30 years of age should always be explored and microscopically examined. This does not apply to the vague indurations characteristic of chronic mastitis, which can be pronounced innocent with certainty by anyone of considerable experience. The conditions which may simulate cancer are chronic mastitis, a deep cyst or fibro-adenoma, especially if surrounded by an area of chronic mastitis, a gumma of the breast, or tuberculosis.

The diagnosis between chronic mastitis and cancer may here be summed up in tabular form:—

Chronic Mastitis.	Carcinoma.
A mobile induration uniformly and finely granular, only vaguely palpable with the flat hand.	A definite lump fixed in the breast and easily palpable with the flat hand.
Indurations often multiple.	A single lump.
Indurations sector-shaped, mapping out the limits of one or more lobes of the breast.	The lump is more or less rounded and does not respect the anatomical boundaries which separate adjoining lobes.
Indurated areas often tender and may be the seat of pain.	Lump neither painful nor tender.

The indurated areas do not adhere to skin or to fascia.	Lump usually (but not necessarily) shows signs of adhesion to skin or fascia, or both.
Axillary glands only slightly enlarged, often distinctly tender, not hard.	Axillary glands often (but not necessarily) enlarged, hard, and not tender.
Nipple not retracted.	Nipple may be retracted.
Skin normal.	Skin may present the orange-rind appearance.

It must, however, not be forgotten that cancer may arise in an area of chronic mastitis. A local lump in a sector-shaped area of granular induration may be a cyst, a fibro-adenoma, or an early carcinoma. Multiple lumps will probably prove to be cysts; a single one, especially if fixed, is often a carcinoma and must be at once explored. If the indurations are vague, sector-shaped, and uniformly and finely granular and free from adhesions, a carcinoma can be excluded. In doubtful cases an experienced opinion should be sought, for routine operations in chronic mastitis are to be deprecated. A cyst deeply buried in a voluminous breast may simulate a carcinoma very closely, for such a cyst rarely gives a sign of fluctuation, and the absence of enlarged axillary glands and of adhesion to skin or fascia does not satisfactorily exclude carcinoma. A cyst can be diagnosed with certainty by puncturing with a trochar, but since a carcinoma not infrequently arises in the breast tissue just outside a cyst, dependence upon this method of diagnosis is not to be recommended: certainty can be reached only by exploration and histological examination. The same difficulties met with in cases of deep cyst also confront the surgeon in a deeply situated fibro-adenoma, especially if it is surrounded by an area of chronic mastitis. Here also exploration is imperative.

Gumma of the breast, which in its early stage produces a vague granular induration like that of mastitis, may later on very exactly simulate a carcinoma. A definite lump appears which becomes adherent to skin and fascia, and peau d'orange may be present. Absence of enlargement of the axillary glands does not help very much to distinguish the condition from carcinoma, but as a rule in cases of gumma of the breast other tertiary lesions are present; there is a history of syphilis and the blood will possibly give a Wassermann reaction. The appearance in a hard lump of a central spot of softening is very significant as confirming a suspicion of gumma, and, of course, the effect of treatment with iodide is very marked in a case of gumma.

Tubercle of the breast runs a course very similar to that of gumma. At first there is a vague mastitic induration, then a hard lump which becomes adherent to skin and fascia, then a central area of softening

which heralds the bursting of an abscess. In tubercle it is likely that the axillary glands will be enlarged. Though it may occur at any age, it is usually found in patients below the cancer age. Exploration may, however, be necessary to supply the diagnosis.

Scarring in the breast, the result of a former abscess, may lead to a suspicion of carcinoma, but the history of suppuration, the presence of a scar upon the skin, and the absence of a definite tumour will avert a mistake. The diagnosis between carcinoma and sarcoma is not of practical importance.

UNUSUAL FORMS OF BREAST CANCER

Medullary or soft carcinoma. In this form of growth the signs of contraction which characterize scirrhus are absent and a large lobulated growth of soft consistence is rapidly formed. Adhesion to the skin and peau d'orange are present over an extensive area; ulceration soon supervenes and a fungating mass of growth protrudes. Sloughing, sepsis, and hæmorrhage may occur, and rapid dissemination leads quickly to a fatal result. Such growths are found especially in young women, and it would be impossible to distinguish them from sarcoma except by a microscopical examination.

Atrophic scirrhus. In some cases, especially in old women, the fibrotic processes of stroma formation are sufficiently active to control and almost, but not quite, to strangle the proliferating cancerous epithelium. In these cases a puckered scar, to which the skin may be attached, slowly forms in the breast. The whole breast becomes shrunken and the nipple indrawn, but no definite tumour can be felt. This form of cancer is usually painless and it is only by accident that the patient notices the local puckering and adhesion to the skin. These signs may persist for many years before any further development takes place, but ultimately—perhaps after 20 years—it is likely that ulceration will supervene and death from dissemination will occur, unless in the meantime some non-malignant condition terminates life. In deciding whether to operate upon an atrophic scirrhus, an especially complete and careful examination must be made, for the disease may be much more advanced than appears on the surface. Sometimes a spontaneous fracture of the femur, a deposit in the spine, or an abdominal, pelvic, or hepatic tumour may be the first sign of atrophic carcinoma to attract attention.

Peripheral carcinoma. Cancers beginning in an outlying lobule of the breast, separate from the main mass of the mamma, are known as peripheral carcinomatosis. Sometimes they may originate in a super-

numerary mamma. The prognosis of these growths is rather bad, for usually they occur beyond the boundaries of the great pectoral muscle and in close contact with the intercostals; thus the growth soon becomes adherent to the intercostals and penetrates to the pleura. Moreover, operations for peripheral carcinoma have nearly always violated the rule that the primary growth must form the centre of the field of operation and of the area of tissue removed, a rule which the writer believes to be of cardinal importance in breast surgery.

Acute cancer of the breast. In young and apparently healthy women there sometimes occurs a particularly virulent form of breast cancer, often developed during lactation. It is accompanied by an erythematous blush of the skin over the tumour; the whole breast is usually invaded and all the signs of inflammation are present. A large tumour rapidly involves the entire breast and is found firmly fixed to the skin and fascia. General dissemination rapidly takes place; and death supervenes within a period of 6 weeks to 3 months. In such cases operation is useless. In its early stage an acute carcinoma may be mistaken for acute mastitis, or for mammary abscess, but in mammary abscess the breast is not fixed to the chest wall as is the case in acute carcinoma.

Impalpable carcinoma. A carcinoma may originate in the breast and may be present for years without giving rise to a palpable tumour: nevertheless, the enlargement of the axillary glands occurs and these cases were formerly described as primary cancer of the axillary glands. If on removal the glands are carcinomatous, and if no other primary focus can be found, the breast should be removed on the assumption that a minute carcinoma will be found in it.

It must not be forgotten that a primary growth originating at the axillary edge of the breast may be mistaken for an enlarged axillary gland.

Mobile carcinoma. It is often stated or assumed that carcinoma of the breast always becomes fixed to its surroundings, but this is only the case if the growth is actively infiltrating. Some carcinomata of the ordinary spheroidal-celled type have a low infiltrative power, and the layer of stroma which separates them from their surroundings may form a definite fibrous capsule almost like that of a fibro-adenoma. In these cases, and for obvious reasons, *i.e.* because the tumour is not anchored to its surroundings by numerous infiltrating outgrowths, the growth remains mobile, and enucleation may be possible, though not as easy as in the case of fibro-adenoma, for which the tumour may be mistaken, even after enucleation. Exceptional though these cases are, it is of much importance to recognize their existence, since the mistake

to which they give rise may be disastrous for the patient's future. An apparent fibro-adenoma first appearing in a woman over 40 years of age is more likely than not to prove to be a carcinoma. The facts of the preceding paragraph make it imperative that all tumours of the breast after removal must be subjected to microscopic examination; naked eye examination is not sufficient.

Duct carcinoma. A carcinoma of the breast may originate in the columnar epithelium of the duct and is then called duct carcinoma or columnar-celled carcinoma.

The disease may arise either in the large ducts or in the smaller ones. When a carcinoma begins in the large ducts the breast is found riddled with caseous areas which are the dilated ducts filled with necrotic debris of cancerous epithelium. Outside these spaces there is seen an irregular cancerous infiltration of the tissue spaces. This form of growth originates in duct papillomata which have undergone malignant degeneration. Such a typical duct carcinoma is usually seen in women over forty years of age, generally beneath the nipple. Retraction of the nipple is usually absent and the growth is slow to become adherent to its surroundings and to infect the axillary glands. There is usually a history of long-standing discharge from the nipple. Prognosis after operation is hopeful.

Mr. Lenthal Cheatle has shown that many cases of so-called spheroidal-celled carcinoma are really carcinomata originating from the columnar epithelium of the smaller ducts. In these cases the epithelium loses its columnar character and becomes indistinguishable from the epithelium of the acini. Until this stage is reached the microscope shows a small, regularly proliferating duct-like space lined with columnar cells. It seems probable that malignant degeneration may occur simultaneously in the small ducts and in the acini.

Carcinoma of the male breast. The male breast is liable, though in a much smaller degree, to all the diseases which affect the female breast. In males, carcinoma occurs later in life than in females, and it is a hundred times less frequent. The disease begins as a button-like induration, which is mobile and situated beneath the nipple. Later on all the signs of carcinoma of the breast become manifest in order. Unfortunately in the male breast the disease is usually seen late and in most of the cases ulceration has set in before advice is sought. The disease must be treated with the same vigour and decision in the male as in the female. The small size of the breast and of the primary lesion itself, must be held responsible for the unwisely restricted operation frequently performed for cancer of the male breast. The operation should be just as free and extensive as in the case of the female breast,

and when this becomes the rule, the prognosis of cancer of the male breast, at present a bad one, will probably improve greatly.

Exploratory incision previous to operation. Bloodgood has stated that a permanent cure can never be expected in a case of cancer of the breast excised at an interval after an exploratory operation to determine the nature of the lump. This statement is much too sweeping, for my own experience includes cases of this nature still free from recurrence in intervals of 5-7 years. There can, however, be no doubt that it is better to combine an exploratory operation with the radical procedure. In all doubtful cases the services of a skilled pathologist should be secured so that a frozen section can be made from a piece of the growth excised for examination. The small wound is swabbed with carbolic acid and tightly sewn up. Instruments, gloves, and towels are changed and the radical operation is begun as soon as the pathologist reports malignancy. This, however, may be a 'counsel of perfection,' since few pathologists possess the necessary extensive experience of this mode of examination, which has been advocated chiefly in this country by Dr. Ernest H. Shaw. In many cases a naked eye inspection of a portion of the growth clears up any doubts which may exist. A carcinoma may creak under the knife, but more usually it is impossible to shell the tumour out of its bed. Radiating fibrous processes firmly anchoring the tumour to the surrounding fat are very characteristic. The colour is grey or pinkish grey owing to early necrobiotic processes in the carcinoma cells. This contrasts with the yellowish tint of chronic mastitis and with the whitish enucleable fibro-adenoma. The breast in chronic mastitis is tough and leathery, while a carcinoma is hard and rather friable. The surface of a scirrhus becomes concave after it has been cut owing to retraction of its fibrous elements.

Principles of the operation for breast cancer. Many methods have been devised for the removal of cancer of the breast. They should all be tested by certain general principles determined by the mode of dissemination of the disease. The object is not amputation of the breast,—a very objectionable phrase as applied to cancer operation,—but as I have elsewhere expressed it: the 'removal intact of the permeated area' of the lymphatic vascular system which surrounds the primary growth, in one piece with the lymphatic glands which may have been embolically infected along the trunk lymphatics. It must be borne in mind that permeation tends to spread in an ever-widening circle from the point of origin of the growth; that point, therefore, must be the centre of the area of tissues ablated. Remembering also that permeation spreads primarily in the plane of the deep fascia and only secondarily extends to the subcutaneous fat and the muscles, it is obviously neces-

sary that the removal must be most extensive in the plane of the deep fascia. Smaller circular areas of skin and of muscle also require removing to meet the secondary invasion of these layers.

Most methods of operating on carcinoma of the breast either remove an unnecessary amount of skin or an inadequate amount of deep fascia.

Choice of cases for operation. If the surgeon aims at a favourable statistical record he will obviously refuse operation to all except the earliest cases of cancer, but if, as should be the case, he considers only the interests of the individual patient, he will not refuse operation unless the case is evidently hopeless. Apparently advanced cases may do well and even if internal recurrence takes place the patient is probably saved from the distress of an ulcerated growth at the cost of an operation which involves little distress and little danger to life.

A distinction should be drawn between early and late cases in this respect that in the early cases operation should be urged and in the late cases merely offered.

Cases in which operation should be refused:

(*a*) When the primary growth has become attached to the bony thorax.

(*b*) In the presence of cancer *en cuirasse*, or of subcutaneous nodules or skin infiltration situated more than 2 inches from the primary growth.

(*c*) If there is a fixed mass of growth in the axilla, evidently adherent to its walls.

(*d*) If there is marked œdema of the arm.

(*e*) If the supraclavicular glands are enlarged, hard, and fixed.

(*f*) If there is evidence of visceral or bone metastases.

(*g*) If there is incurable constitutional disease—tuberculosis or diabetes, for example,—likely to be fatal in a few years at most, or to lead to a post-operative fatality.

(*h*) In the acute forms of carcinoma.

A thorough and complete examination should always precede the operation for breast cancer. It is important specially to remember that angular curvature of the spine, nodules in the epigastric parietes, deposits in the ovaries and in Douglas's pouch, or evidence of thickening of the great trochanter may negative an operation in cases which appear otherwise suitable.

For the details of the operation for breast cancer a larger work on surgery, or a monograph such as the writer's, should be consulted.

The question of removing the supraclavicular glands. Halsted regards the clearing of the supraclavicular glands as a frequent, if not invariable part of the operation. My own feeling is rather that

the supraclavicular triangle should not be touched unless the glands in it are definitely enlarged.

Enlargement of the supraclavicular glands, if the glands are still mobile, does not negative the operation for breast cancer. I have several cases in which these glands were removed at an interval after the primary operation, the patients remaining well five years or more, subsequently.

Post-operative treatment. My experience indicates the necessity of a prophylactic course of X-rays begun as soon as possible after the operation wound has healed. Most of my cases of local recurrence are included in a small fraction of cases which have accidentally escaped post-operative treatment. It is also important to see that the patient lives a healthy life and gets as much fresh air as possible. The ideal is a prolonged course of open air treatment on sanatorium lines.

Causes of death in breast cancer. As a rule in breast cancer multiple deposits are found after death, but the disease may run its course in rare cases as a local process throughout. When there is evidence of visceral deposits it is usually safe to say that the patient's life will not be prolonged for more than a year, often for not more than six months.

Death may occur from general dissemination, from exhaustion, from septic absorption, from deposits in the brain, from pleural and pericardial effusions, from ascites, from paraplegia due to spinal deposits, and in rare cases as the direct result of bleeding from the ulcerated growth. Intercurrent diseases, especially pneumonia and erysipelas, are responsible for a certain number of deaths. The average duration of life after the appearance of the growth is stated by Campiche and Lazarus-Barlow to be about four years.

TREATMENT OF INOPERABLE BREAST CANCER

The past few years have produced two agencies of considerable importance in the treatment of inoperable cancer, namely X-rays and Radium.

X-rays in breast cancer. The prophylactic employment of X-rays after operation should be a routine measure. When the disease has passed beyond the range of operation X-rays are still of importance in causing fibrosis and sometimes the healing of deposits in the skin and subcutaneous tissues, whether ulcerated or not. Visceral and other deep deposits are apparently uninfluenced by X-rays; the rays, however, may do good in such cases by relieving pain.

Radium treatment. Whereas X-rays can be employed over a wide superficial area, the action of Radium, while apparently even more powerful in the immediate neighbourhood, is of restricted range. Thus Radium should be chosen in preference to X-rays for cases in which there are only one or two localized recurrent foci. Furthermore it must be remembered that the action of Radium varies inversely as the square of the distance and that therefore it falls off rapidly. If its action at a distance of one inch be taken as a unit, at the distance of two inches the action has fallen to one-fourth and at three inches to one-ninth. Thus it is evident that a dose of Radium rays which can pass through the normal tissues of the skin without injuring them, is unlikely to have a destructive action on subjacent cancerous foci. In other words, Radium cannot be used efficiently as a surface application to the skin. The Radium tube must be buried in the tissues and preferably in the middle of the mass of cancer cells to be treated. Used in this way Radium has proved very effective for dealing with isolated recurrent deposits.

Open-air treatment. Patients with cancer should, if possible, live in the country and spend most of their time in the open air. Regular open-air treatment on sanatorium lines appears to be beneficial in the more chronic cases of inoperable cancer.

Drug treatment. A resort to opium as soon as pain begins to assert itself is a practice much to be deprecated. The drug interferes with the action of the stomach, bowels and kidneys, and impairs the general health. Aspirin, or phenacetin with caffeine given at night will often suffice to produce sleep. Cannabis indica may also be tried. The use of opium should be postponed until the last stage of the disease. It may then be given, preferably as the Liquor Opii Sedativus, in rapidly increasing doses.

Lymphatic œdema of the arm. Lymphatic œdema of the arm, or brawny swelling, is a frequent complication of the late stages of breast cancer. At first the œdema pits on pressure, later it becomes solid. This condition is attended by heavy constant pain, often referred to the back of the elbow. In the early stages elevation of the arm during the night will afford relief. The use of the arm must be severely restricted, since exercise will increase its blood supply and consequently the amount of lymph produced. Massage and treatment by heat or light must be avoided for the same reason. This condition is due to obliteration of the lymphatics about the shoulder by permeation and subsequent fibrosis. In carefully selected cases the operation of lymphangioplasty introduced by the writer may afford great relief, though it is to be regarded as a palliative only. In suitable cases it produces relief from

pain within twenty-four hours, with a fall in the tissue tension and a rapid subsidence of the swelling. In cases where pressure has produced nerve paralysis power may return in the arm. The operation is contra-indicated if growth is present about the shoulder, or if the pain is a lancinating pain shooting down the arm and associated with the presence of supraclavicular glands. It should also be refused if pleural effusion is present. Relief from the operation can never be guaranteed with certainty: it is accordingly one which should be offered to the patient and not urged upon her.

Local treatment of ulcerated growths. All ulcerated malignant growths are prone to secondary infection by micro-organisms. As a result sloughing and offensive discharge occur. Cancerous ulcers therefore require careful antiseptic dressing with mild unirritating applications, such as Sanitas, boric lint or ointment, or flavin, 1 in 1000. If the ulcer is foul to begin with it should be cleaned out by hot fomentations and the application of 10-volume hydrogen peroxide or acetone.

Sarcoma of the breast. **Etiology.** Sarcoma of the breast sometimes develops at the site of and at a short interval after a single definite blow on the breast, a fact of some medico-legal importance. Besides these sarcomas of traumatic origin, there is no doubt that sometimes a fibro-adenoma, which has been present for years, may take on a rapid growth, forming in a few months a large tumour which may infiltrate through its capsule. When this stage is reached a large hemispherical tumour is rapidly formed which becomes adherent to skin and fascia and soon fungates through the skin. Sarcoma of the breast is, however, a much rarer tumour than was formerly thought. Many cases presenting the clinical signs of sarcoma prove on examination to be soft carcinomata. Sarcoma may occur at any age from childhood upwards, but Rodman finds that half the cases occur between the ages of 40 and 50.

Clinical signs of sarcoma. A typical sarcoma rapidly grows to a large size, and, unlike carcinoma, it is not accompanied by shrinkage or contraction of the tissues. It forms a large prominent hemispherical mass which soon involves the whole breast. Beneath the surface of the skin are seen large blue veins; and in the most acute cases pulsation is present in the growth. Adhesion to the skin and fascia is early and extensive. At the convexity of the swelling the skin becomes thin and reddened and finally gives way, exposing the neoplasm beneath, which then soon protrudes through the hole in the skin and forms a vascular, rapidly-growing mass from which hæmorrhage frequently occurs. Dissemination is the exception, but in some cases secondary

deposits are found not only in the axillary glands, but widely through the internal organs and the bones.

Treatment. The operation for sarcoma is practically the same as that for carcinoma, but owing to the extensive adhesion of the skin to the growth this layer must be more widely removed and in consequence skin grafting will often be necessary.

SECTION II

OPERATIONS UPON THE THORAX AND ITS CONTENTS

PART II

OPERATIONS UPON THE THORACIC WALL AND ITS CONTENTS

BY

RICKMAN J. GODLEE, M.S. (Lond.), F.R.C.S. (Eng.)

Surgeon to University College Hospital; Consulting Surgeon to the Hospital for Consumption, Brompton

CHAPTER III

OPERATIONS UPON THE THORACIC WALL AND THE MEDIASTINA

OPERATIONS FOR INJURIES OF THE CHEST

Surgical emphysema, whether arising from injury to the lung or some other part of the air-passages, at most requires to be provided with means of escape by means of punctures, but is usually best left alone, as it is sure to be absorbed. The only exceptions are where the swelling is very inconvenient from its size, when punctures will suffice, and the rare cases where it is accompanied by cellulitis, in which free incisions are called for.

Wounds of the lung, whether the result of bullet wounds, stabs, or fractured ribs, give rise to hæmorrhage and usually hæmoptysis. They are generally best treated by absolute rest and hypodermic injections of morphia, but if there is reason to think that the bleeding is continuing, and the loss of blood is becoming serious, it is good practice to make a free opening into the chest and to endeavour to stop the hæmorrhage by suture or ligature or tamponnade. In most cases it is probably wisest to use neither external sutures nor drainage tubes, though the former are needed if the wound be very large, and the latter if it be septic. Sufficient occlusion is obtained by means of a dry dressing kept in place with plaster. The further the injury is from the hilus of the lung, the more likely such treatment is to be effectual; in fact, wounds of the large vessels at the root of the lung are generally rapidly fatal. Hæmothorax requires no treatment unless serious pressure symptoms result. In this case a certain amount of the blood should be slowly withdrawn by an aspirator. Too rapid or too complete extraction may start the bleeding afresh. For this reason, and also because even severe cases often clear up remarkably well, it is generally recommended that the surgeon should be in no hurry even to aspirate, and still less to open the chest in search for the source of the bleeding.

Wounds of the great vessels. Wounds of the large arteries in the thorax are usually almost immediately fatal; but cases are recorded where the injury has not actually penetrated the vessel, and a traumatic aneurysm has resulted, and others in which the wound, though a penetrating one, has been temporarily plugged by the object which has inflicted the injury. There is at least one recorded case of successful

ligature of the innominate artery after partial resection of the sternum, and doubtless it would be the right practice in the rare cases that present themselves to deal in this way with a wound of any large vessel, either artery or vein, in the superior mediastinum. Indications for such operations will be found in the chapter dealing with the treatment of aneurysms, to which also the reader is referred for guidance as to the treatment of secondary aneurysms of the aorta.

For injuries to the *thoracic duct* see Vol. I, p. 538.

Hernia of the lung. It is convenient to discuss all forms of hernia pulmonis together.

Non-traumatic hernia of the lung results from some congenital or acquired weakness of the chest-wall. The signs should be unequivocal, but other conditions, such as lipomata in the posterior triangles and abscesses, have frequently been taken for herniæ. As a rule, no treatment is required, or merely the application of a pad, but it may be necessary to expose the tumour, and endeavour by some plastic operation to close the opening in the chest-wall.

Traumatic herniæ may exist with or without an external wound, and may be *immediate* or *consecutive*. Should a portion of lung protrude through an external wound, as sometimes happens if forced expiration with a closed glottis occurs at the moment of injury, the part which is protruded may swell and sphacelate. It may be possible to return this portion, if it be healthy, into the chest; but sometimes the better plan is to include it in a ligature and remove it, and then close the chest-wall if the wound be aseptic, or insert a tube if the wound be septic, or simply to apply a dry dressing without stitches or tube. The condition is a very rare one in civil practice.

OPERATIONS FOR CARIES AND NECROSIS OF THE BONY WALLS OF THE THORAX

It will be convenient to discuss the inflammatory diseases of the bony walls of the thorax, including the cartilages, together, and before passing to the treatment to say something about the pathology. Any of these structures may be affected by acute inflammatory changes as a part of general acute diseases, such as acute infective osteomyelitis or typhoid fever, and in such cases acute abscesses will develop.

These are, however, less common than the more chronic processes, most of which are tuberculous, but some result from typhoid fever.

An abscess resulting from caries or necrosis of the spine may follow one of the commoner routes, *i.e.* it may track downwards, guided by the anterior common ligament, and ultimately give rise to a psoas abscess, or it may pass directly backwards and appear as a dorsal abscess. But

sometimes a spinal abscess, even if originating from caries of the cervical spine, may burst into the pleura, or it may enter an intercostal space and, passing along it, point at the side or the front of the chest. This may lead to confusion of diagnosis, and if, as I have seen happen, it also bursts into the lung, a tympanitic abscess with a strong impulse on coughing results, which may baffle the diagnostic powers of the most experienced.

Caries and necrosis of rib and rib cartilage may affect the bone or cartilage, or start at the junction of rib and cartilage, or cartilage and sternum. In cases of necrosis a sequestrum forms and is embedded in an involucrum, except in the case of cartilage where no involucrum forms. The process is often confined to the deep surface, and the abscess then burrows in the subpleural connective tissue, giving rise to a localized 'peripleuritis.' Such abscesses may extend widely, involving secondary caries of other ribs or cartilages, and closely simulating empyemata. A similar burrowing process may take place below the pleura in the attachment of the diaphragm. More often, however, the process remains localized, and a cold abscess develops in the neighbourhood of the affected rib or cartilage.

Either surface of the sternum or the interior of the bone may be similarly affected, and caries of the joint between the manubrium and the gladiolus is common. If the abscess forms on the deep surface of the sternum it may extend into the mediastinum, causing one form of mediastinitis, or it may burst at the side of the sternum through an intercostal space, or it may track outwards between the pleura and the ribs, or it may point at the episternal notch or the epigastrium.

Bearing in mind therefore the great variety of these abscesses, it will be seen that it is difficult to lay down general instructions with regard to treatment, but there is one golden rule, *viz.* to avoid injuring the pleura if possible, as tuberculous pleurisy is likely to follow this accident.

If the abscess has started from the spine the track should be followed back until an opening as near as possible to the source of the disease is secured. This will involve removal of a portion of rib or ribs quite close to the spine, but may enable the surgeon to deal with the primary disease.

In the case of necrosis of rib it may be enough to remove the sequestrum; but if the disease be caries it is better to remove the affected portion completely unless this involves exposure of the pericardium, in which case scraping with a sharp spoon is indicated. In conducting these operations the utmost care should be taken to lay open all the ramifications of the abscess, which are often very complicated, and in my experience the best results are obtained by applying pure carbolic acid to the surface and treating it as an open wound. The use of sutures even to large wounds is, I think, a mistake.

Caries or necrosis of the anterior surface of the sternum requires no special comment. Abscess on the deep surface may call for trephining or cutting a hole in the bone with a gouge. Sometimes, however, an opening at the side of the sternum is sufficient. In this case the internal mammary artery is in danger. If wounded it will probably be necessary to remove a costal cartilage in order to secure it. If the joint between the manubrium and gladiolus be involved it must be scraped or gouged. This may lead to the complete severance of the two parts of the bone. The movements of the two parts during respiration are rather alarming, but I have not seen any permanent evil consequences follow.

REMOVAL OF TUMOURS OF THE CHEST-WALL

We have only to consider the operations for those tumours which involve the ribs and intercostal spaces or the pleura; those for the more superficial ones are dealt with in other parts of the work. It may, however, be mentioned in passing that some of those which will be referred to have originated in the more superficial structures.

The simple tumours of the ribs and sternum are such as occur in other bones, amongst which enchondromata, though far from common, are those most frequently met with. Many swellings diagnosed as enchondromata turn out to be examples either of tuberculous disease or of abnormality of shape or structure. The latter perhaps hardly deserve mention in a work on operative surgery, were it not that they are so often mistaken for new growths by the patient and sometimes even by the surgeon. If it be borne in mind that the third and fourth rib cartilages are especially liable to a marked prominence anteriorly, and that all the rib cartilages are in normal persons somewhat tender on pressure, and if it be also remembered that a bifid rib does really fill up the intercostal space either above or below, and finally, that these deformities are accentuated or made more obvious by loss of flesh, such mistakes in diagnosis should seldom occur. If, however, it be found during an operation that a supposed case of tumour is really an abnormally shaped rib, there is no doubt that the rib should be left alone and the patient frankly informed of the mistake. His—or probably her —pain and anxiety will disappear just as well as if the supposed tumour were removed.

In operating upon enchondromata or other simple tumours of the ribs there are no special rules for the shape or size of the incisions. It only needs to be stated that it is not well to work with too small an incision, as every effort will have to be made to avoid the wounding of the pleura. Should, however, a pneumothorax result, it will probably do no more harm than is involved in the immediate interference with respiration and the hampering of the surgical procedures; that is, sup-

posing it is possible, after the removal of the tumour, to make an air-tight closure of the opening in the chest-walls.

One of the less common tumours of the chest-wall is cystic hygroma. The nature of the growth will probably have been diagnosed before the operation is commenced, but it is not unlikely that the fact of its passing through one or more intercostal spaces has not been suspected. These cases should be dealt with like those occurring in the abdominal wall or other inaccessible places; *viz.* by removing the external part and leaving the rest alone. The disease is harmless except for the deformity it causes, which is here of no consequence, and for the attacks of acute inflammation resembling erysipelas to which it is liable, but which in this situation are very unlikely to occur. It is essential to maintain strict antiseptic precautions until the wound is absolutely closed, as otherwise the erysipelatous inflammation above mentioned may set in.

Malignant tumours of the chest-wall may be primary or secondary. The primary tumours are practically always sarcomata, often chondro- or myxo-sarcomata. If diagnosed early an attempt should be made to remove them freely with a considerable portion of the surrounding chest-wall. As this necessarily involves a free opening of the pleura, it would be very much aided by the employment of the high-pressure or low-pressure methods of operating (see p. 129). It is obvious that the risk involved in such a case as that of König, in which in removing a sarcoma of the sternum both pleuræ and the pericardium were opened, would thus be much diminished; it is interesting, however, to know that the operation in this case was not fatal. If it be found that the growth has involved the lung, it will be necessary to carefully estimate the amount to which the infiltration has taken place, and if it appear possible to do so, a portion of the lung may be taken away, either clamping or ligaturing it beyond the region affected, or by simply cutting it through with Paquelin's cautery. The former method is, on the whole, recommended. Air-tight closure of the chest-walls should, when practicable, be secured.

Primary tumours of the pleura are seldom likely to be diagnosable early enough to allow of any attempt being made for their removal.

Most of the cases of secondary tumours of the chest-wall are those of recurrences after the removal of cancers of the breast. If small and superficial it is the rule to remove them as widely as possible, endeavouring to avoid the opening of the pleura. But these operations are seldom satisfactory, as the lymphatic affection usually extends further than can be detected by the eye, and recurrence is almost invariable. I do not think that extensive resection of the chest-wall when infiltrated with cancer is an operation which ought to be undertaken.

The same may be said of those cases where the growth has originated in the lung and involved the chest-wall, the disease in these cases being

almost invariably so extensive that its removal is impossible, or if possible it is almost certain to be followed by recurrence.

OPERATIONS FOR MEDIASTINAL ABSCESS

Suppuration in the mediastinum may result from caries or necrosis of bone, or from the extension of suppuration from some distant part, as when a post-pharyngeal abscess, or one resulting from angina Ludovici, or that following tracheotomy, is conducted downwards by the deep fascia to the back of the sternum; or it may originate from some of the contents of the mediastinum, such, for example, as strumous glands, or from injury or disease of the trachea, bronchi or œsophagus, pericardium, &c. From these general remarks as to causation, it will be seen that the process is sometimes acute, and often of a diffuse character, necessitating prompt attempts at relief by trephining or resecting parts of the sternum, or by resecting ribs in the neighbourhood of the spine, and that the search for the pus is a difficult matter, and, even if successfully carried out, unlikely to save the patient's life. Sometimes the suppuration is chronic and accompanied by pressure symptoms like those of tumour. These cases do not demand such immediate treatment; the matter often reaches the surface by a process of burrowing, and the best place for the incision thus becomes apparent, probably at the episternal notch, in the posterior triangle, or through an intercostal space, or at the ensiform cartilage. But if the presence of pus be suspected, though its exact position is doubtful, it may be justifiable to open either the anterior or posterior mediastinum in the manner indicated in order to search for it. It is needless to say that great care must be adopted in exploring with the finger amongst the great vessels at the base of the heart, and that the use of an exploring trochar or fine forceps is inadmissible.

In the posterior mediastinum it is difficult to avoid injury to the pleura; but the operation is much confused if this accident should occur. The incision should be made near the middle line. If there be no guide to the locality of the abscess it is difficult to say which side should be selected, the dangers being about equal. Portions of enough ribs and a sufficient number of transverse processes should be removed to enable the surgeon to see as well as feel the parts exposed. It must be remembered that the front of the bodies of the vertebræ is 3 to 5 inches from the level of the skin, and that if the finger reaches to this depth it will be in close contact with the important structures that occupy the posterior mediastinum: aorta, pericardium, thoracic duct, &c., and that thus a mere exploratory operation is liable to be followed by a catastrophe from which there is no escape.

CHAPTER IV

OPERATIONS FOR THE REMOVAL OF FLUIDS FROM THE PLEURAL CAVITIES

EXPLORATION OF THE CHEST

If the physical signs justify the exploration of the chest it is usually wise to employ some form of aspirator. If it be quite certain that the fluid, if any, is the pus of an empyema, or that the two pleural surfaces are adherent, there is no objection to the use of exploring trochars. These are useful instruments in many cases of thoracic surgery, especially for penetrating the lung after the chest has been opened. They should be of various lengths and sizes, but should always have full-sized handles (see Fig. 33).

I strongly recommend the use of the bottle aspirator as opposed to any form of needle fixed to a syringe, or to Dieulafoy's aspirator, in which it is difficult to regulate the amount of negative pressure. The needle of the bottle aspirator is easy to manipulate; the amount of negative pressure can be regulated to a nicety, and it is readily cleaned. The only objection to its use is that it is rather cumbrous, but it seems to be forgotten that a small bottle is often more convenient than a large one. One great advantage beyond those already mentioned is that if fluid be found, the one puncture suffices for its evacuation. The needles, or rather trochars, should be of various sizes and lengths, but none less than 3 or more than 6 inches (see Fig. 34). They should always have a lateral as well as a terminal hole. They should be constructed throughout of metal, no leather washers being permissible, as they are constantly perishing and causing leakages at the joints.

A very slight negative pressure, or even none at all, should be made in the bottle until the supposed site of the fluid is reached. The mistake of producing an almost complete vacuum is commonly made, the result being that flakes of lymph are sucked into the tube, and the fluid, if present, is not evacuated.

The use of small hypodermic syringes or others of a similar nature cannot be too strongly deprecated. They are untrustworthy instruments,

and to my knowledge have often been the cause of pernicious and avoidable delay in treating a variety of thoracic diseases.

In exploring the chest the normal position of the thoracic and abdominal viscera and vessels must be borne in mind, as well as the fact that these may be much altered by disease. Inflammatory conditions of the pleura even when effusion is present are more likely to diminish the extent downwards of the pleural cavity than to increase it, because during the early painful stage of pleurisy full inspiration does not occur, and the diaphragmatic and costal pleuræ become adherent before the onset of effusion.

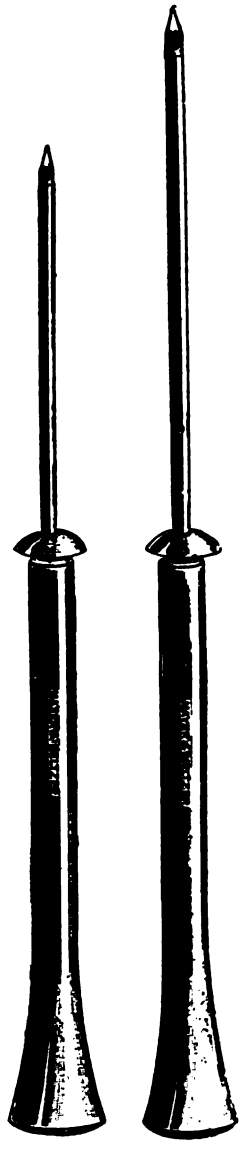

FIG. 33. EXPLORING TROCHARS. With large handles all of the same size. ¾ scale.

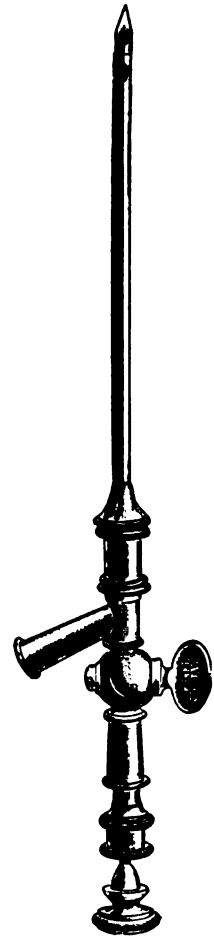

FIG. 34. ASPIRATOR TROCHARS. Suitable for exploring the chest. ¾ scale.

Through the lower intercostal spaces it is easy to reach the liver and spleen, and the splenic flexure of the colon has been inadvertently punctured. Puncture of the liver and spleen, while usually free from danger, has been followed by serious or even fatal hæmorrhage. The idea of exploring them in this way should never be entertained if there be any suspicion of leucocythæmia, hæmophilia, or any condition which may interfere with the coagulation of the blood.

Exploratory incision of the pleural cavity cannot be performed without producing a pneumothorax except with the aid of the 'high-pressure' or 'low-pressure' method of operating. It is described in the following section.

LOW-PRESSURE AND HIGH-PRESSURE OPERATIONS

Methods. Operations which involve the opening of the pleura have been hitherto, as far as possible, avoided on account of the fear of the evil consequences which may result from the production of a pneumothorax. It does not come within the scope of the present work to state what these dangers are, but it must be admitted that they are sometimes considerable, especially if the function of the opposite lung be in any way interfered with. At the same time, it is well known that small openings into the chest, allowing of the introduction of the fingers, and which necessarily produce a partial pneumothorax, may be made without danger, that even extensive wounds of the chest-wall are not necessarily fatal, and that in removing tumours of the chest-wall free openings have been made into the pleural cavity with only temporary interference with respiration. The pleura has thus remained to some extent a forbidden country as compared with the abdomen, the contents of which usually tend to protrude, or the skull, in which, as a rule, neither recession nor protrusion occurs.

Numerous devices have been made to obviate this difficulty; the simplest being the artificial production of adhesions, by suture, cautery, or caustics. This plan permits of the exploration by puncture or incision of the substance of the lung, but does not render possible the exploration of the pleural cavity itself.

It is only within the last four or five years that a new method of operating was suggested by Sauerbruch of Breslau, the principle of which consists in placing the patient's body in a chamber in which the atmospheric pressure can be lowered to any degree that may be required. The head remains outside and is subject to normal atmospheric conditions. It is thus possible, by regulating the amount of pressure inside the chamber, to ensure either that the lung remains in contact with the chest-wall when the pleura is opened, or to allow it to recede to any desired extent, or even, if desired, to make it protrude through the opening. It is obvious that this is an advance in surgery, and it has aroused much interest both in Europe and America, and has formed the subject of discussion at more than one surgical congress. The question of practicability at once arose. The apparatus is exceedingly costly, as may be gathered from the accompanying figure (see Fig. 35) reproduced from Lautenschläger's catalogue, and even if, in the course of time, the structure should be simplified and the cost reduced, it must always be a cumbrous affair, which could practically only be provided at a public institution, and it is hardly likely that even every large town in the country would be public-spirited enough to spend so much money in providing

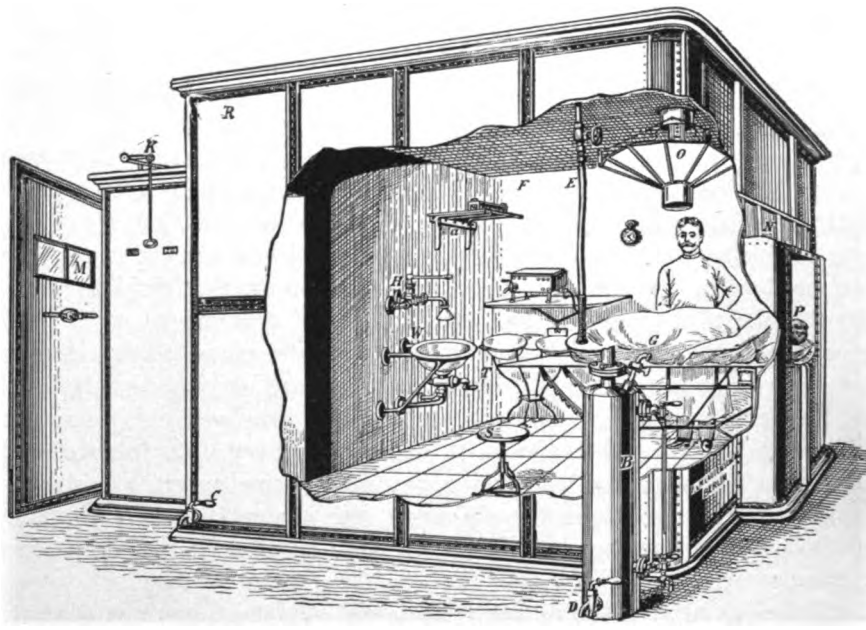

FIG. 35. SAUERBRUCH'S CHAMBER. R, the operating chamber, is made of iron plates, screwed together and painted inside with white enamel paint (it may, however, be supplied with windows, thus doing away with the necessity of artificial light, O). The floor is tiled and slopes so that water can escape by the tap C. There is an ante-room with double air-tight doors: the valve K, if opened, admits air into this antechamber and this allows of the opening of the outer door, M, which would otherwise be impossible. P is a projection through which the head and neck of the patient who is lying on the operating table, T, protrudes: his neck is surrounded by a closely fitting (almost air-tight) india-rubber collar. Above the projection P is a small window, N, through which the anæsthetist and the surgeon can communicate by signs; a telephone is also supplied for oral communication. G is an india-rubber bag which encloses the patient's body and is intended to maintain normal atmospheric pressure on the lower parts of the body; when secured in position (by means of cambric bandages) the tube E, which communicates with the outer air, is opened. W, H, A washing apparatus.

The low pressure is obtained by means of a powerful double-acting pump, which can be worked by steam, electricity, &c., and is by preference at some distance from the operating chamber in order to avoid vibrations: this apparatus is not shown.

If the doors and windows are hermetically closed, the necessary reduction of pressure (10 millimetres below normal atmospheric pressure) is obtained in from four to ten minutes, and can be rapidly either increased or diminished at pleasure. The amount of pressure must be observed on a water-pressure gauge, the position of which is immaterial. When the level of the water falls below 140 millimetres air enters the operating chamber through water contained in the vessel B. In this way the atmosphere is constantly renewed with moist and dust-free air and thus prolonged operation can be comfortably conducted. D is the tap for regulating the level of the water in the vessel B.

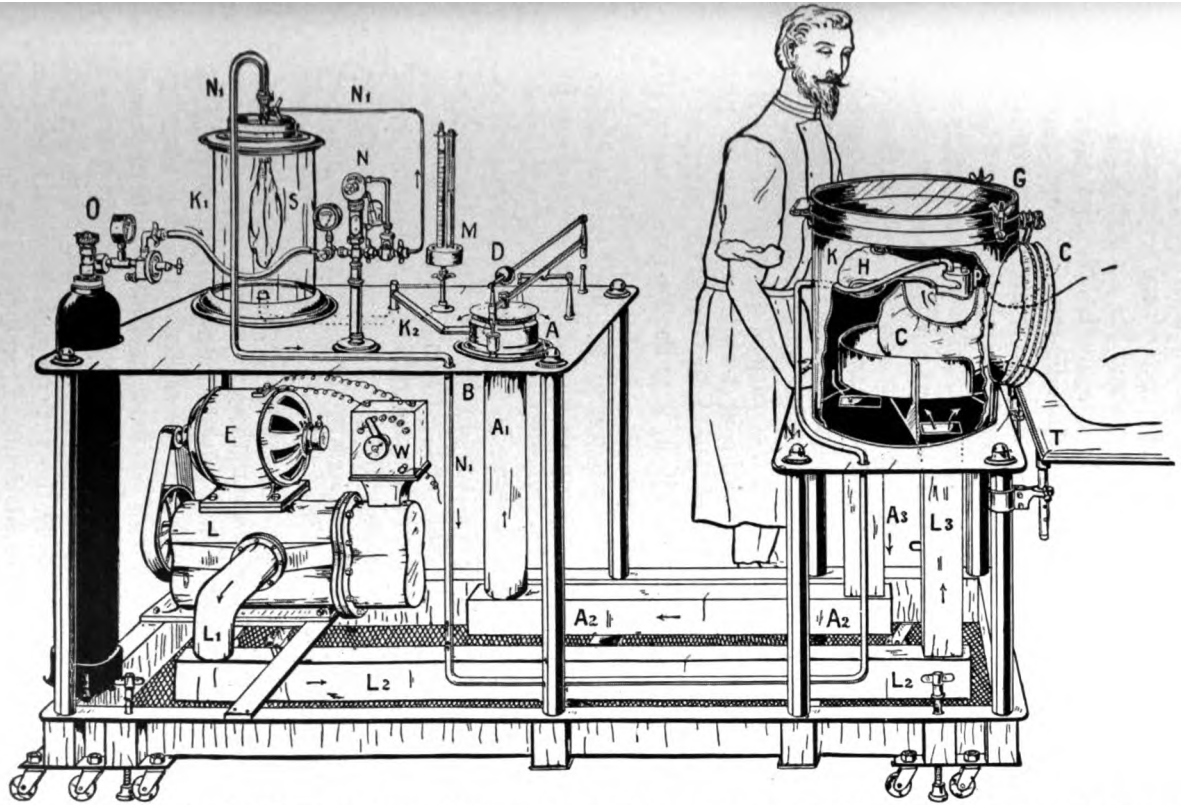

FIG. 36. BRAUER'S HIGH-PRESSURE APPARATUS. E, Electromotor; W, Starting-resistance and rheostat; L, Force-pump; L 1, L 2, L 3, Tube for conducting compressed air to high-pressure chamber; K, High-pressure chamber; A 3, A 2, A 1, Tube for conducting air from high-pressure chamber; A, Exit for air and apparatus for regulating the amount of the pressure; D, Weight for regulating the pressure; B, Water-brake piston, to avoid vibrations; M, Water manometer; O, Oxygen apparatus; N, Apparatus for the anæsthetic; S, Bag for holding the anæsthetic vapour; N 1, Tube for conducting the anæsthetic to the patient; P, Anæsthetic mask; K 1, Pressure regulator for the anæsthetic bag; K 2, Exit tube from pressure chamber K; G, Glass cover of high-pressure chamber—openable; C, C, Closely fitting covering or helmet and collar for patient's head and neck; H, Sleeves for the anæsthetist; T, Operating table.

for what is, after all, not a very large number of patients. Certainly no private individual would be likely to install one unless he had unusual opportunities of meeting with cases to be operated upon. There is, moreover, another objection to this low-pressure (*Unterdruck*) system. Not only must the patient's body, but the surgeon and his assistants also, be within the low-pressure chamber, while the anæsthetist, like the patient's head, is outside it. In case of respiratory difficulties the inconvenience of this arrangement is apparent. No oral communication except by telephone can take place between the surgeon and the anæsthetist, and in an emergency, such as in thoracic surgery is not uncommon, to resort to the telephone may be most undesirable, while to open a window for the interchange of words would raise the pressure inside the chamber to that of the outer air. If the opening in the chest were small it could, of course, be plugged, but if it were large it is likely that a suddenly caused pneumothorax would be added to the already present dangers of the patient. While, therefore, the advocates of the *Unterdruck* method can record some most interesting and important results, and while some of them still maintain its superiority to all others, one hears reports from many quarters that, for the reasons I have given, it is hardly practical, at all events at present, for general employment.

The possibility of preventing the collapse of the lung having, however, been demonstrated, attempts were made to obtain the same result in another way, *viz.* by increasing the pressure inside the lung instead of diminishing it outside. This high-pressure (*Überdruck*) method is associated with the name of Brauer, who in 1905 brought forward his method. I reproduce another figure from Lautenschläger's catalogue (see Fig. 36), a study of which will enable the reader to understand it and probably, if he desires it, to have a similar or possibly a simpler and less expensive one constructed, for even this, at the present time, costs something not far short of two hundred pounds. The advantage of this method over the other, besides the smaller size and more moderate cost of the apparatus, is that both the surgeon and the anæsthetist are in the open and free to communicate with one another, to resort to artificial respiration and adopt in concert any other procedures that the exigencies of the case may demand. The disadvantages which on first reading about the two methods appeared to me to outweigh all the advantages of it as compared with the *Unterdruck* method, but which those who have tried it do not say much about, is that the head of the patient and the hands of the anæsthetist are contained in a closed chamber, and I fail to see what would happen in the not unlikely contingency of the occurrence of hæmoptysis or vomiting, or the expectoration of the contents of an abscess. The anæsthetist must clearly have a copious supply of apparatus

—gag, forceps, mops, towels, &c.—within the chamber, and must be well trained to employ them under circumstances which to one who has not seen such operations would seem likely to be of great difficulty. It must be added that many surgeons speak highly of Brauer's apparatus, and appear to think that it will be found of practical utility.

Various suggestions have been made for simplifying these procedures, which must be mentioned without entering into details, in the hope that they may serve as hints to other surgeons who are working at the subject. Such are the production of high pressure after intubation, or the employment of a mask fitting tightly over the patient's face, or the administration of the anæsthetic vapour into a chamber like Brauer's without the hands of the anæsthetist, each of which appears to introduce some advantages, but perhaps an equal number of drawbacks.

The difference in pressure required is not large, on the average about 3-10 millimetres of mercury.

MELTZER-AUER INTRATRACHEAL ANÆSTHESIA

The most recent method for positive pressure is that devised by Meltzer and shows a wide range of applicability. In this method a loosely fitting catheter is inserted well within the trachea, at times as far as to the bifurcation. Through this tube either air or a mixture of air with ether vapour can be delivered in definite volumes under definite pressure. The most ready apparatus is that which is formed by an ordinary No. 9 foot-bellows of the glass blower, which delivers something less than 1 litre per full stroke. This can be connected with a two-way bottle containing ether, and if one chooses, a manometer may be inserted.

Meltzer has demonstrated that a tidal wave of air within the lung is not necessary, but by a more or less continuous distention of the lung providing there is proper air circulation within the trachea, the patient's aeration is not disturbed and perfect anæsthetization can be maintained. This simple method of loose catheterization of the trachea is used only when positive pressure is not desired. When positive pressure is desired the lung can be kept distended either by placing a rather snugly fitting catheter within the trachea or by placing the hand over the mouth and nose until there is some ballooning out of the cheek. In using a snugly fitting catheter within the trachea the pressure should never exceed 20 mm. It has been demonstrated that 5 mm. of pressure within the lung when the pleura is open is sufficient to maintain distention. Excessive intrapulmonary pressure not only tends to possible rupture of the lung but retards the return of blood and lymph to the

thorax and tends to produce shock within a comparatively short time. In the latter case a suitable safety device to prevent increased pressure is desirable. This can be simply a curved tube buried 20 mm. in a bath of mercury or a pop-type safety valve as designed by Connell.

TECHNIQUE OF INTRATRACHEAL INSUFFLATION

The patient is fully anæsthetized by the usual method. The head is then rotated well backwards down to the table and the shoulders are

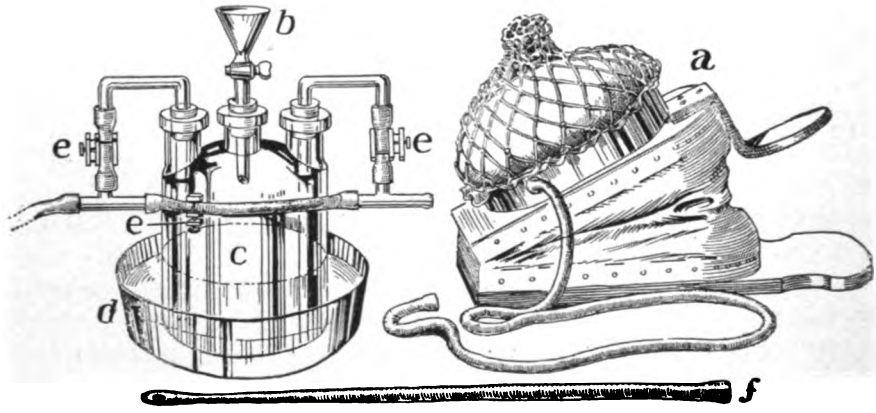

FIG. 36A. APPARATUS FOR INTRATRACHEAL INSUFFLATION. *a*, Glass-blower's bellows, which at one stroke should deliver 1 litre of air. *b*, Funnel through which ether is introduced into bottle, *c*. *c*, Bottle. *d*, Tray containing warm water for vapourizing ether. *e*, Clamps, the proper adjustment of which will supply either ether or ether-air vapour as it is to be desired. *f*, Tracheal catheter.

slightly elevated so that the plane of the face makes an angle of about 60° with the table. A direct laryngoscope, preferably of the Jackson type, is then inserted and a catheter passed by direct vision into the trachea. The size of the catheter will depend somewhat upon what type of anæsthesia is desired. In ordinary anæsthetization a loosely fitting catheter is all that is desired. If positive pressure is to be maintained, the catheter should be a 26 or 28 F. When one is positive that the catheter is well in the trachea, it can be fastened by a strip of adhesive plaster. The catheter is connected by a rubber tube with a two-way bottle (see Fig. 36A) containing ether, and this in turn is connected with a foot-bellows. The amount of air insufflated should be sufficient so that on inspiration no air is inhaled from the outside. This usually re-

quires from 18 to 20 litres per minute for an adult and may be delivered at about 20 mm. pressure. If one hears a sucking of air beside the catheter, the pressure should be somewhat increased.

Positive pressure may be maintained when opening the pleural cavity by either obstructing the return flow of air by placing the hand over the nose and mouth until the cheeks bulge or by increasing the delivery pressure to 60 or 70 mm. This method is undesirable in that the lungs are subjected to over-pressure. The tracheal catheter used may be as aforementioned, large enough to very snugly fit the trachea and thus obstruct the too easy return flow of air.

Indications. Having now discussed the methods by which thoracotomy can be practised without the production of pneumothorax, it remains to consider what cases are likely to be benefited by it.

(i) If it were felt that an extensive opening into the chest could be made without immediate danger or prospective disability, surgeons would feel justified in making exploratory openings as they make exploratory laparotomies where the presence of foreign bodies or possibly removable malignant tumours was suggested by the history, by the symptoms, or by radiography. The lung could be methodically handled all over, and it is conceivable that in the future growths may be more early diagnosed or completely removed. One reads about the removal of a tuberculous lobe of the lung, or a portion of a lung which is affected by limited bronchiectasis. One also hears about these operations being carried out antiseptically, but not having personal experience of such procedures I hesitate for the present to express an opinion as to the advisability or the feasibility of their performance. For the same reason I do not feel justified in attempting to describe the best way of dealing with the stump after pneumectomy, or the best position for the opening under different circumstances. Those who contemplate performing such operations would no doubt desire to consult the copious discussions which have taken place at the German Surgical Congress of 1907 and 1908, which may be found in their own special reports, or in less detail in the *Centralblatt für Chirurgie.*

(ii) Mediastinal growths and malignant tumours of the œsophagus have also been dealt with by these methods, but so far apparently with but little if any success.

(iii) The prevention of pneumothorax would be of great assistance to the surgeon in dealing with tumours of the chest-wall, and I think might sometimes be the means of avoiding danger to the patient when it is necessary to traverse the healthy pleura in opening a septic abscess—say a liver abscess—below the diaphragm.

(iv) Some very interesting cases have been reported of the employ-

ment of these methods in cases of wounds of the heart. The production of a pneumothorax diminishes the blood pressure, and, experimentally at all events, it appears to be possible in this way to limit the possible contraction of the heart muscle while the sutures are being inserted, and afterwards by doing away with the pneumothorax and closing the chest to allow things to return to their normal condition.

Before leaving this subject it is proper to mention a development of it which has been used for the purpose of drawing out the lung in the treatment of empyema. A tightly fitting india-rubber box is attached to the patient's side in which the air is exhausted to the desired amount, and in which some arrangement is made for the reception of the discharge. It is said that this can be made of such a size that the patient can wear it under his clothes, and that it has been found of real value in diminishing the time of closure of an empyema.

OPERATIONS FOR SEROUS EFFUSIONS

The time for drawing off a serous effusion must be determined by the physician; but I have never known harm to be caused by the removal of a small collection of fluid, and have often seen improvement follow on its performance.

Two *instruments* are available for the purpose: one, the *bottle aspirator* referred to above (see p. 127), and the other a needle like that employed with the aspirator, to which is attached a piece of india-rubber tube long enough to pass into a vessel placed upon the floor; this should be compressible by means of a clip, and weighted at the distal end. This is a very simple, inexpensive, easily cleanable, and efficient apparatus (Fig. 37). The negative pressure obtainable is sufficient for most, if not all cases. A simple perforated needle may be substituted for the more complicated one recommended; but it is possible to wound the lung with it.

Position of patient. If the effusion be a large one there is no advantage, but, on the contrary, there are serious disadvantages and some risk in sitting the patient up and puncturing behind. He should lie flat on his back in a comfortable position, not too close to the edge of the bed, and the needle should be passed through the lower part of a convenient intercostal space, say the sixth or seventh, in the mid-axillary line. Here the spaces are wide, the amount of tissue to traverse small, and there is no danger of striking a rib with the needle. If the needle be sharp and introduced with decision, the pain is trifling, but any form of local analgesia (except freezing the skin hard) is admissible. The needle should be long enough to reach the angles of the ribs and the posterior part of the pleural

sinus. It is needless to say that gravity has nothing to do with the process of evacuation by aspiration; the only essentials are that the end of the needle should be free in the fluid, and not obstructed by having lymph or lung sucked against the openings.

The fluid should be extracted very slowly, the pump of the aspirator being just kept at work, producing the smallest possible negative pressure in the bottle. A complete vacuum is likely to draw lymph or lung against or into the openings, and a rapid removal of the fluid is less safe and less comfortable for the patient than a slow one. It also causes a minor inconvenience, *i.e.* more frothing of the fluid.

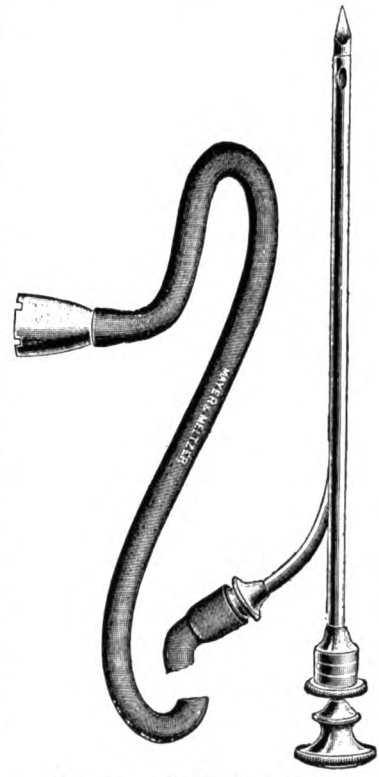

FIG. 37. A SIMPLE SIPHON ARRANGEMENT. ¾ scale.

It is not possible to remove the whole of the fluid except under the improbable circumstances of the lung and chest-walls being quite normal. Usually a time comes when a distressing and ungovernable desire to cough attacks the patient. When this occurs, the process should be stopped for a while and a piece of ice given him to suck. If the cough passes away, more fluid may be withdrawn. If not, the needle should be removed; the discomfort will probably not last more than half an hour. Another reason for stopping is the staining of the fluid with blood; this may occur in any case, and is usually of no consequence, but I have known it to lead to fatal internal hæmorrhage in a case of malignant disease.

Substitution of air and other fluids for the serum. It is no new suggestion that a complete removal of the fluid can be effected by the substitution of atmospheric air, that this adds no danger if the air be filtered, and that a negative pressure can be left within the chest by withdrawing any excess of air that may have entered. I have no personal experience of this method, and the reader is therefore referred to the animated discussions on this subject in the medical press; but I would remind those about to practise it that it does not follow, because air is rapidly absorbed by the healthy pleura in traumatic pneumothorax, that it will be as satisfactorily dealt with by the unhealthy serous membrane of

pleurisy; the behaviour of cases of tuberculous pneumothorax indeed would make one expect that the air would not be readily absorbed.

The treatment of chronic serous effusions has also given rise to much discussion. I will first deal with those in which repeated examination does not reveal the presence of tubercle, and in which the cause is therefore obscure. I have obtained good results from repeated tapping, the intervals varying from days to weeks or months in accordance with the rapidity of reaccumulation of the fluid. The injection of adrenalin or of substances like tincture of iodine in small quantities has been recommended, and if the fluid injected is aseptic or antiseptic, it is probably a safe procedure. A free opening into the chest and the introduction of a drainage tube has also been advised, but, though successful cases have been reported, I am convinced that it is a dangerous practice, and one that is liable to be followed by that incurable condition—a collapsed lung in the centre of a complete septic pneumothorax with an external opening.

In tuberculous cases I have obtained a moderate degree of success, but, it must be owned, no brilliant results, by inserting through an anterior intercostal space at the time of aspiration a second needle made to communicate by means of an india-rubber tube with a vessel containing boric acid lotion or normal saline solution. After prolonged irrigation the excess of fluid was drawn off by the aspirator. The success of this treatment, if it succeeds, must be open to the same explanations as are offered for the successful treatment of tuberculous ascites by incision with or without irrigation or sponging, amongst which that of Sir Almroth Wright at present holds the field.

OPERATIONS FOR EMPYEMA

The proper line of treatment depends upon whether the affection is complete or localized, upon the age and state of the patient, upon whether it is unilateral or on both sides, and a variety of other conditions which will appear in the sequel. Except in double empyema no delay in evacuating the pus is admissible.

Aspiration. Experience shows that occasionally in adults and frequently in children aspiration of an empyema, especially if repeated on two or three occasions—say, with the interval of a week—is followed by a cure. But this result cannot always be obtained, whereas a free incision in children is usually a successful operation and is followed by rapid healing. Speaking generally, the more quickly a cure can be effected, the better it will be for the lung, and therefore, considering the frequency with which it is not successful, aspiration cannot be recommended; though there are certain cases, such as double empyema, in which it may be advisable.

Recently following aspiration of the thoracic cavity irrigation has been resorted to, using Dakin's hyposulphite of soda solution. This has given very good results at the hands of some observers. Care must be used when the thoracic cavity is being irrigated that the solution is not too warm and that the cavity is not too rapidly filled or too rapidly emptied to prevent shock. It is ordinarily used, however, only after pleurotomy or costectomy following the usual Carrel technique. The tubes, supported by fine wire bound to the outside of the tube, are inserted in every direction and the fluid introduced at two-hour intervals.

Murphy advocated aspiration of the thorax and injection of 1 or at times 2 per cent. solution of formalin and glycerin. Usually the first injection was a very small quantity to test out the patient's tolerance to this mixture, usually not over 10 c.c. In cases of considerable irritation with rapid refilling of the chest subsequent aspirations were done to relieve the patient's condition. Weekly injections of this solution can be made, depending upon the reaction of the patient to the mixture. Increasing doses up to 20 c.c. can be used.

COMPLETE UNILATERAL EMPYEMA

This condition is seldom met with except when the sudden rupture of an abscess occurs into a previously normal pleura. In almost all other circumstances some part of the cavity is obliterated by adhesions: either the base of the lung is adherent to the diaphragm, or the inner surface to the mediastinum, or the back of it to the angles of the ribs, or the pleural sinus is obliterated, or patches of adhesions exist in other parts; but for practical purposes an empyema may be spoken of as complete when the whole of the chest-wall is available for the incision. A really complete empyema must be immediately evacuated in order to save life. If the lung be healthy and completely collapsed, the ultimate outlook is bad, and subsequent Estlander's operations (thoracoplasties) will probably be necessary. In such cases the apparatus mentioned on p. 129, in the section on 'high-pressure' and 'low-pressure' operations, seems to offer a chance of drawing the lung out to the chest-wall, and should certainly if possible be employed.

Much has been written about *the most favourable position to select for the incision*, and arguments have been brought forward in favour of lateral incisions which to me are unconvincing. I have no hesitation in recommending a posterior opening both on theoretical grounds and as the result of experience, the best place being, in my opinion, the region of the ninth or tenth rib, not far from the scapular line. I have often had to make a posterior incision when a lateral one has failed to effect a cure, but never to make a lateral one when a posterior one has proved

inefficient. An incision in the spot recommended will usually be found to be almost, if not quite, at the lowest part of the cavity, because the diaphragm has become adherent to the chest-walls before the effusion took place; and if it be not at the time actually the lowest part, it soon becomes so owing to the extension of this process. If a lower spot be chosen, the opening usually becomes valvular. The posterior incision ensures the best possible drainage both when the patient is recumbent and when the body is raised, and the theoretical objection that lying on the incision may be a source of much discomfort to the patient is not supported by experience.

The question of the advisability of removing a portion of rib has been the subject of prolonged but not very illuminating discussion. It cannot be denied that many cases may recover without interfering with a rib, that in a lateral incision the spaces may be so wide that it is not essential, that sometimes the patient is in so bad a state that any prolongation of the operation is a drawback, and that in very septic cases the risk of secondary hæmorrhage is increased; in the vast majority of cases, however, the slight prolongation of the operation is of no consequence, the large size of the opening obtained is of immediate advantage in enabling the surgeon to thoroughly explore the pleura, open up outlying pockets, and remove masses of lymph, and in the subsequent treatment, the pain caused by the contraction of the wound upon the drainage tube is prevented. In very septic cases the risk of secondary hæmorrhage may be minimized by dividing the intercostal artery and tying it in two places. I therefore recommend as a routine practice the removal of about 3 inches of one or, if necessary, two ribs.

Operation. If the pleura be much distended it is well to draw off the greater portion of the pus with the aspirator before beginning the operation, sometimes before the administration of the anæsthetic.

FIG. 38. PERIOSTEUM ELEVATOR SUITABLE FOR CLEARING THE RIB. ½ scale.

The patient should be placed on a high table with the affected side projecting rather beyond the edge of it, turned very little over on to his sound side. It is dangerous to turn him much on to the sound side, especially if there be much fluid or if the empyema has ruptured into a bronchus. The operator should sit if the table be a low one. If the condition of the patient be very bad, he may be placed upon the diseased side near the middle of the table, and the surgeon, in this case standing up, may operate from behind.

If a general anæsthetic be employed, chloroform, or chloroform and oxygen is usually the safest. The anæsthesia should not be so deep as to abolish the laryngeal reflex, and the surgeon should remind the anæsthetist that slight movements will not seriously impede the operation. Local analgesia produced by the injection of eucaine may be substituted for general anæsthesia if desired, and will probably be quite

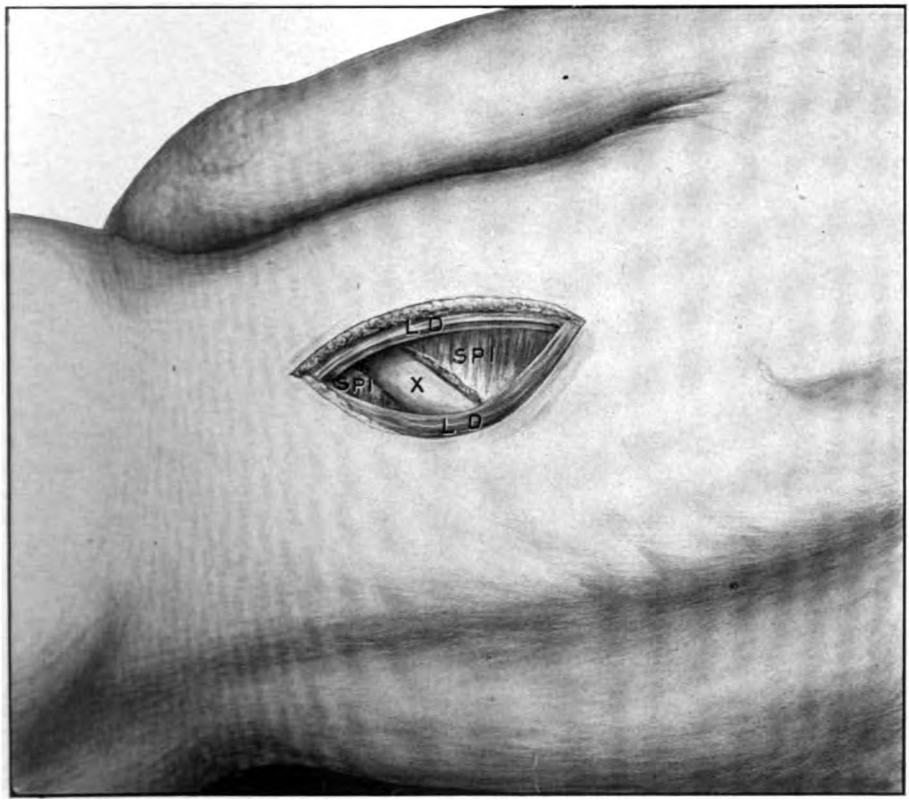

FIG. 39. VERTICAL INCISION FOR EMPYEMA. L.D., Latissimus dorsi; S.P.I., Serratus posticus inferior; X, Rib.

efficient. Freezing of the part, however, is satisfactory neither to the patient nor the surgeon.

I always now employ a *vertical* incision (see Fig. 39), and have discarded the oblique or transverse one. The latter involves a transverse division of the fibres of the latissimus dorsi, and unless great care be taken that the skin be not drawn up by raising the arm, is often found to be lower than the opening in the chest-wall when the operation is com-

pleted. Should the oblique incision have been selected, and this accident occur, it must be rectified by converting the incision into a ⊥-shaped one, as it is essential that the superficial and deep openings be opposite to one another. The vertical incision should be 3½ or 4 inches long, and should be followed by splitting the latissimus in the direction of its fibres for an equal distance and then dividing the serratus posticus in-

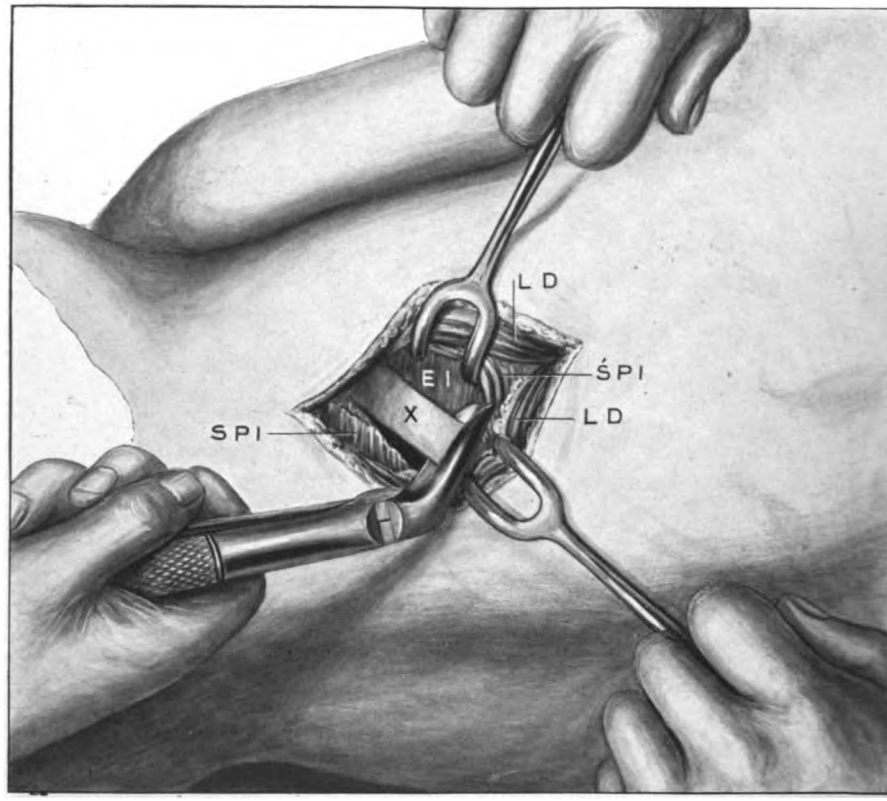

FIG. 40. SECOND STAGE OF THE OPERATION FOR EMPYEMA. L.D., Latissimus dorsi; S.P.I., Serratus posticus inferior; E.I., External intercostal muscle; X, Rib.

ferior across the direction of its fibres. The parts are then held widely apart by long retractors and the periosteum of the rib thus exposed divided for 3 or 4 inches. The periosteum is then separated from the rib by a blunt, slightly curved periosteum elevator (see Fig. 38) both on the superficial and deep surfaces, and the rib divided as far forwards and backwards as possible, the retractors being placed first forwards and upwards and then backwards and upwards as shown in Fig. 40.

Many special forceps and scissors have been invented for the purpose, which do not appear to me to be better than an ordinary pair of curved bone-forceps.

After the removal of the piece of rib any bleeding vessels are secured and, if it be thought advisable, the intercostal artery is divided and ligatured. The nerve should, if possible, be preserved, because, although its preservation sometimes is followed by neuralgic pain owing to the pressure on it by the tube, its division is sure to cause a patch of numbness in the area it supplies. The pleura is then opened either by the knife or a pair of dressing-forceps, and the gloved finger is at once inserted into the wound, partly for the sake of estimating the state of the lung before the fluid has escaped, and partly because it is advisable, if the amount of fluid be large, to allow it to escape gradually in order to avoid the shock that may result from its too sudden evacuation. After the fluid has escaped the state of the lung is again examined, and for this purpose, in my opinion, the most dexterous use of the probe is inferior to that of the finger. Lymph is extracted, and a search is made for pockets or secondary cavities which require opening up, or unusual conditions such as openings into lung or liver, carious bone, calcareous plates, the contents of a dermoid cyst, &c., and then the tube is inserted.

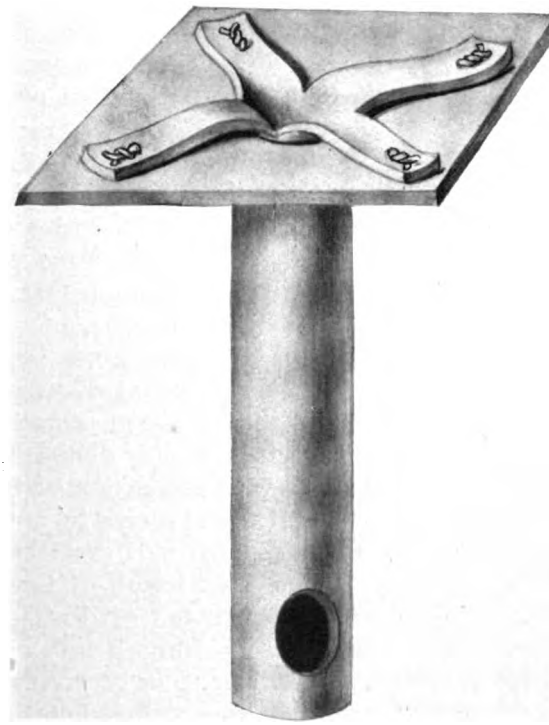

FIG. 41. FLANGED TUBE. The flange is attached with twisted silver wire; observe the position of the hole.

At this stage two large tubes, ½ to ⅝ inch in diameter, just long enough to project about 1 inch into the pleural cavity, and each provided with one large hole close to the proximal end, should be employed, and all anxiety about their slipping in or out may be avoided by stitching

them with two strong fishing-gut sutures to the skin after cutting the ends nearly flush with the surface of the skin. The only occasions in which long tubes are required are those of long cavities, the distal narrow part of which only has been reached by the incision. The calibre of the tubes, of course, may be regulated by the size of the cavity and the nature of the contents. Very free drainage is required for large stinking cavities, much less for small cavities, the contents of which are not greatly septic. Though I find two tubes convenient, I have no quarrel with those who prefer a single tube. There is no need to interfere with these tubes till a week after the operation, when a single flanged tube may be substituted for them (see Fig. 41). Smaller tubes may be used in the case of children, and in them, or when the cavity is small, the use of two tubes at first is not essential; but what is important in all cases is to secure absolutely free drainage during all stages of the treatment. A short tube, the length of the thickness of the chest-wall, provided with a flange at each end so that it can slip neither in nor out, is recommended by Mr. Bilton Pollard (see Fig. 42).

As a general rule, it is wise to use antiseptic dressings, but when the pus is foul it is more satisfactory, at all events for a time, to apply boric fomentations and to change them frequently. The mortality from operations on empyema has notably diminished since very free drainage has been aimed at and the introduction of the antiseptic treatment; but it must be remembered that the successful antiseptic management of such large discharging cavities demands great care and attention.

After-treatment. The length of time that the tube is to be retained depends upon the amount of discharge and the rapidity of the closure of the cavity. In children it may often be removed at the end of ten days, though it will often be necessary to drain for a much longer time. In adults it is seldom possible to remove it before six weeks, though I have known empyemata close in three weeks even in people of advanced age.

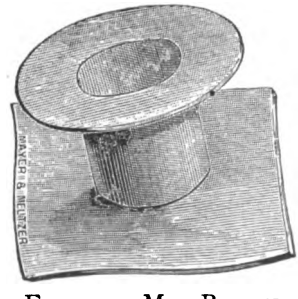

FIG. 42. MR. BILTON POLLARD'S EMPYEMA TUBE.

Occasionally it may be possible, if the discharge be very slight, to remove the tube even while a considerable cavity remains. In such a case the final closure is brought about by the absorption of the air which occupies the cavity after the external wound has closed. If this method be adopted it is wise to introduce a railroad catheter at intervals of a few days. If the fluid that escapes be clear serum and small in amount, it is safe to continue with this line of treatment; if, however, the fluid be pus, the tube should again be inserted for a time.

Patients that are doing well may leave their beds at the end of a week or ten days. They often do better when the erect posture is assumed than while recumbent.

Chest exercises, such as blowing into a bottle, are often useful. It is only by forced expiratory efforts while the glottis is closed that actual mechanical inflation of the collapsed lung can be brought about, though no doubt the function of the affected lung may be improved by forced respiratory movements if considerable adhesions of the lung to the chest-wall have taken place. Suggestions for drawing out the lung by atmospheric pressure are mentioned at p. 136.

If an empyema be unopened it may point through any one of the intercostal spaces. The commonest is the fifth, just external to the origin of the pectoralis major, but I have seen rupture occur through all the spaces and at any part. I have followed a track down to the first intercostal space in the axilla. Sometimes an empyema may rupture into the pericardium or passing through the diaphragm point at the lower part of the abdomen. It is said that one has at last entered the thigh and pointed at the ankle. It is not safe therefore to assume in any given case that it is not one of empyema because the orifice of the sinus is at some distance from the supposed seat of the mischief.

CONTINUOUS ASPIRATION

In order to facilitate drainage of the chest and to prevent collapse of the lung Perthes suggested continuous suction drainage. After resection of the rib a rather firm rubber tube or a specially prepared flange tube is inserted and the chest wall closed snugly about the tube and, if possible, sealed to prevent leakage. A suction apparatus is connected to this tube and continuous aspiration instituted by various means. Suction can be obtained by an apparatus connected with a water pump, as suggested by Perthes. In this apparatus it is well to have a mercury manometer inserted in order to regulate and at all times to have in view the negative pressure exerted in the pleural cavity. This should not exceed 30 mm. of mercury. If it is impossible to have running water at hand a system of siphon bottles can be used where suction can be obtained by water flowing from a bottle at a high elevation into a bottle at a lower elevation. This apparatus requires more attention due to the fact that as soon as the upper bottle is empty, suction is released and the process is at a standstill until the bottles are reversed.

DOUBLE EMPYEMA

Both sides of the chest have been opened at the same time without evil consequences; but this course is not to be recommended, because of the uncertainty as to the presence or absence of adhesions. No doubt adhesions are usually present on both sides, and thus the double incision is usually safe because both lungs can be expanded by expansion of the chest-walls. But the free opening of both sides of a normal chest would be certainly fatal, and on one occasion it is stated that the accidental opening of the wrong, that is, the healthy side, in a case of empyema was followed by a fatal result. The wise course, in my opinion, therefore, is to open one side freely and to aspirate the other. As was pointed out above, aspiration sometimes leads to the cure of an empyema, especially if repeated on two or three occasions. I have several times obtained this result in double empyema in children, but if after a certain time, when the patient is accustomed to the altered respiratory conditions, the pus continues to accumulate in the unopened side, and the lung on the other side is obviously doing some work, it is best to open the second pleural cavity and drain it.

CHRONIC EMPYEMA

There are several reasons why empyema may become chronic, and which must modify opinion as to the advisability and nature of the treatment. Amongst them are to be noted:—

1. An opening badly situated or insufficient in size.
2. The large size of the cavity, which, though to some extent obliterated by adhesions, is not capable of further reduction because the limits of contraction of the walls and expansion of the lung have been reached.
3. The complete collapse of the lung before any pleural adhesions have formed, such as occurs after wounds of the thorax or from the sudden rupture of an abscess or a hydatid into a healthy pleura.
4. The presence of a bronchial or biliary fistula.
5. Tuberculous disease which is sometimes associated with the formation of larger or smaller calcareous masses or plates.
6. Malignant disease of the pleura, which is sometimes not suspected at the time of the operation.
7. The presence of foreign bodies.
8. Callus of the rib.
9. Lung abscess.
1. *If the opening be insufficient or badly placed,* pus will be retained

in the cavity, and in the latter case can be emptied out at the dressing. If the opening be well placed but too small it should be enlarged by removing part of another rib, probably that above the original opening. If it be badly placed a second opening must be made in a more favourable position, the proper place for which may usually be determined by introducing the finger and thus ascertaining the lowest part of the cavity both in the recumbent and the erect postures.

2 and 3. *If the cavity be too large to close by natural methods,* we have at our command various procedures. In all these cases it would seem desirable to use bismuth paste. Beck as well as others have had excellent results in the injection of bismuth paste into this type of cavity or in the type of empyema which refuses to close. Care should be taken when the bismuth paste is injected that if the empyema cavity communicates with the bronchus, the patient does not aspirate the bismuth paste into the opposite lung. The cavity is well filled with the paste, which can be injected with an ordinary blunt-pointed glass syringe, and closed. One injection at times suffices. At other times if the infection is very active, the bismuth paste will be eliminated from the cavity and a second or even a third injection is required. If this method fails, the cavity can only be obliterated along mechanical lines.

There are many modifications and types of operation for obliterating an empyema cavity. These all have for their basis the resection of the rigid chest wall to allow the soft tissues to collapse, thereby mechanically obliterating the cavity.

Thoracoplasty. It is neither necessary nor advisable to give precise instructions as to the performance of a thoracoplasty, because the procedure varies with the size and extent of the cavity, but some practical points may be set out. The shape and size of the cavity are first ascertained with the finger or the probe (see Fig. 43), and then the position of the incision is so planned as to afford easy access to the ribs it is desired to remove, and at the same time it should be devised so as to avoid dividing transversely muscles with the use of which it is not proposed to interfere. Thus it is often advisable to make it curved or angular; sometimes two incisions are preferable to one. The exposure of the ribs should be quickly carried out because the operation is often a severe one, and the hæmorrhage is sometimes considerable. It seems as if, owing to the fact that the intercostal trunks themselves are generally so far obliterated by the contraction of the surrounding fibrous tissue as not to require the application of a ligature if divided, the superficial circulation is abnormally free. The ribs should be removed in the usual way, *i.e.* after separating the periosteum, because the periosteum is more easily and rapidly taken away afterwards with the thickened pleura with which it

has become incorporated. The surgeon should not hesitate to remove six, seven, eight, or more inches of each rib, but he should recollect that it is not essential to finish the operation on one occasion. The attempt to do so has sometimes caused a fatal result. It is a good plan in bad

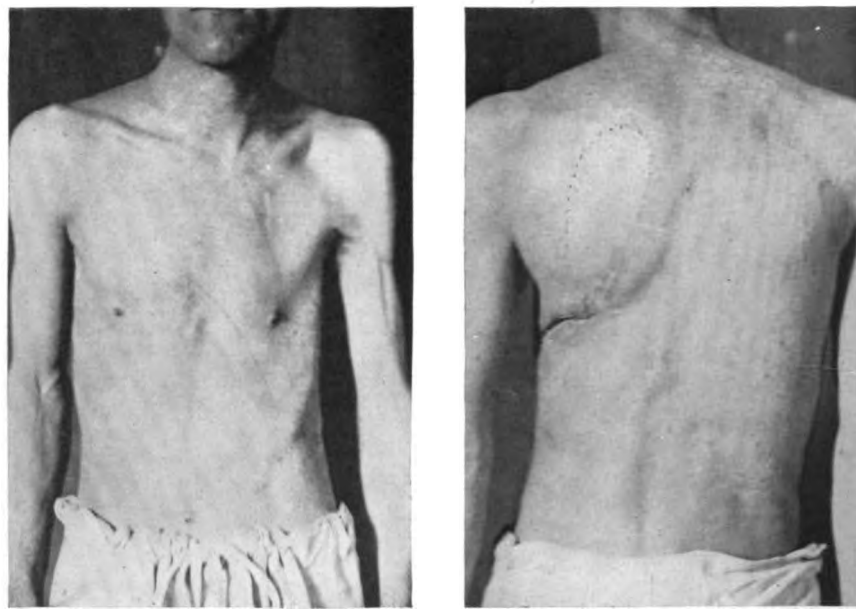

FIG. 43. FRONT AND BACK VIEW OF AN OLD EMPYEMA. From a photograph taken before the operation. The dotted line in the back view shows the extent of the cavity as ascertained during the operation.

cases to perform the operation in two or even more stages, allowing some weeks or months to elapse between them. I have indeed known what at the time was supposed to be an incomplete operation result in a cure. The appearance seen in the completed operation on the patient shown in Fig. 43 is shown at Fig 44, which is taken from a photograph. The most difficult part of the pleura to close is that included in the rigid circle of the upper two or three ribs. I would again point out how simple a matter it is to attack the first and second ribs from behind, and how difficult the first rib is to deal with from the front.

When the time comes for removal of the periosteum and pleura, this may usually be done freely with knife or scissors without fear of bleeding from the intercostal arteries, which, as has been said, are either obliterated or much smaller than normal.

I have never myself seen any harm come from applying strong lotions (say chloride of zinc 40 grs. to water $\bar{3}$i) to the pleura before closing the skin wound; but I have heard of a death apparently arising from a

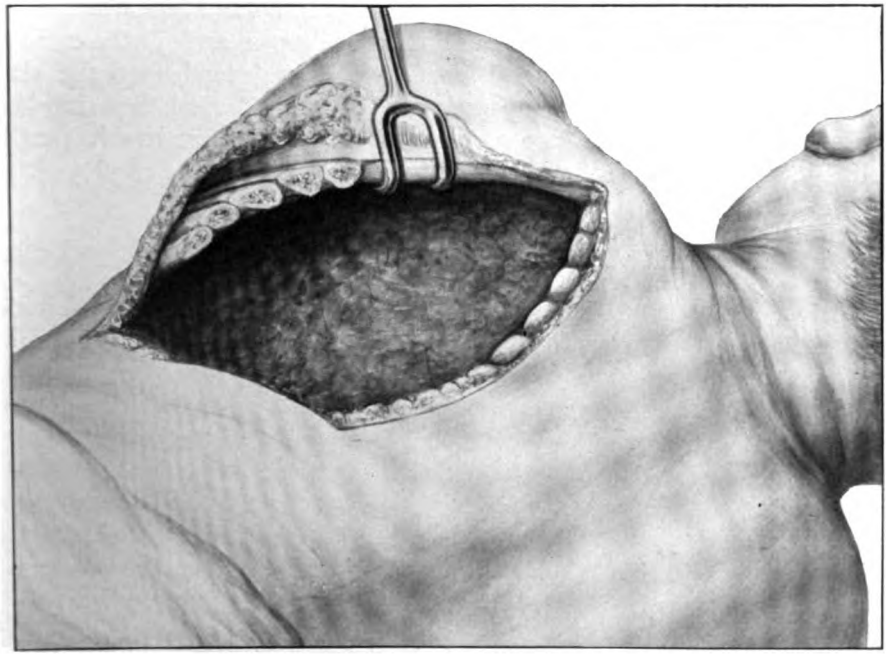

FIG. 44. COMPLETED THORACOPLASTY ON THE PATIENT SHOWN IN FIG. 43. From a photograph taken before inserting the stitches.

similar cause. Some caution should therefore be observed in irrigating the remains of the cavity.

I think it is important to keep a drainage tube of large size in the *upper* as well as the lower part of the incision.

It is seldom advisable to remove such ribs as are in contact with the pericardium. It can of course be done without killing the patient, but the obvious pulsations of the heart under the skin are a source of considerable discomfort, and it seems likely that the exposure of this organ to possible injury is not altogether free from danger.

ESTLANDER OPERATION

The size of the non-collapsible cavity is ascertained either by means of the X-ray with or without the injection of an opaque substance. The ribs overlying this cavity are resected subperiosteally and the soft tissues including the chest wall and pleura allowed to drop in and fill the cavity. The number of ribs resected and the type of flap depend upon the size of the cavity. In extensive operations a large U-shaped flap may be employed, resecting a variable number of ribs. If the cavity is small, a small U-shaped flap or simply a semilunar incision may be employed.

SCHEDE THORACOPLASTY

In those cases in which there is a large non-collapsible cavity Schede recommends a very extensive operation upon the chest wall. The skin incision starts from the upper part of the back between the spinal column and the scapula and descends to the lower border of the pleura and ascends again along the anterior axillary line, ending at the border of the pectoralis major muscle. The skin flap is dissected upwards and all the ribs from the second down are resected together with the costal cartilage. When the ribs are resected the thickened, infiltrated, and hardened parietal pleura with the intercostal muscles is removed. At times the visceral pleura can be scraped with a curette. The skin flap is then replaced and a drainage tube introduced. In this manner the entire cavity is filled by the collapsible soft tissues of the chest wall. Adhesions take place between the wall and the visceral pleura, thus obliterating the cavity.

The chief danger to this formidable operation is collapse, due to the fact that these patients are practically all in a much devitalized state and are not in condition to withstand such an extensive operation. The whole success depends upon rapid work and perfect hæmostasis with as little trauma as possible.

ROBINSON MUSCLE IMPLANTATION

Robinson combines the technique of the Schede operation with his own in order to obliterate the cavity in chronic empyema. A U-shaped incision is made, starting at about the inferior angle of the scapula, extending downward in a U-shape to about the lower end of the pleural cavity, coming anteriorly to end in the anterior axillary line at about the border of the pectoralis major muscle at the level of the nipple. This incision varies somewhat, depending upon the location of the empyema

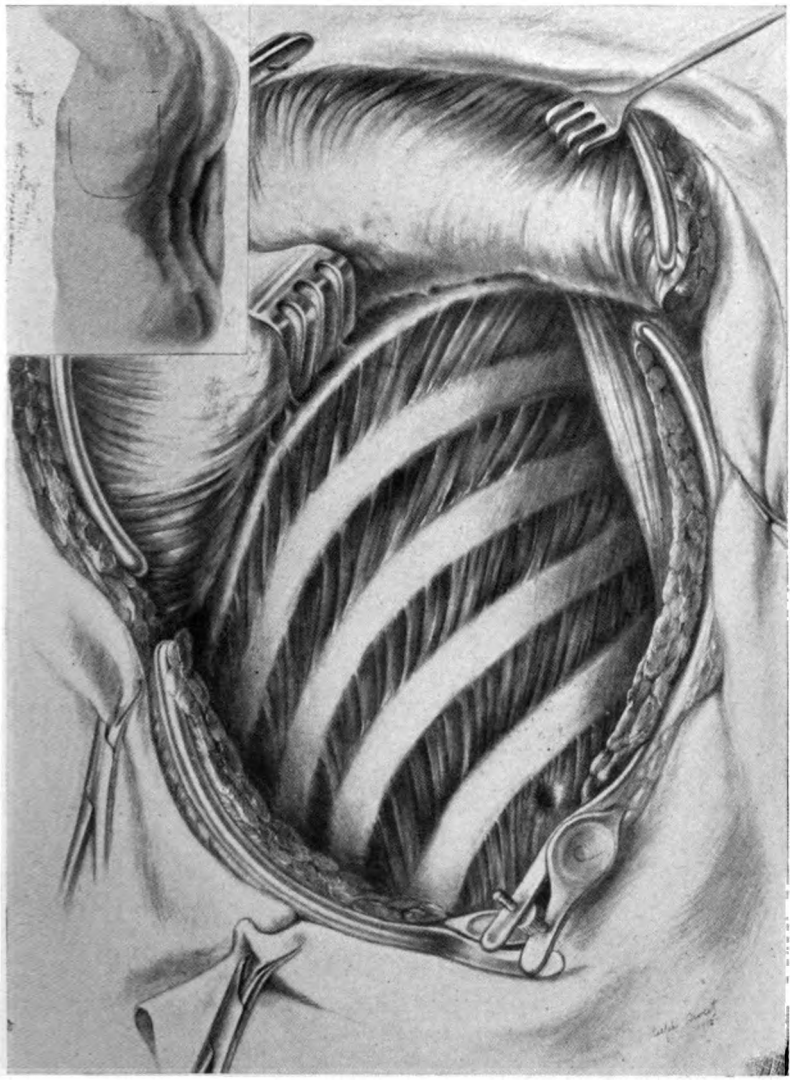

FIG. 44A. CHRONIC EMPYEMA. Cavity filling by muscle implantation combined with an operation of Schede type. First step: Reflection of skin and muscle flap. Note curved clamps (without handles) to check muscle bleeding. (*Robinson.*)

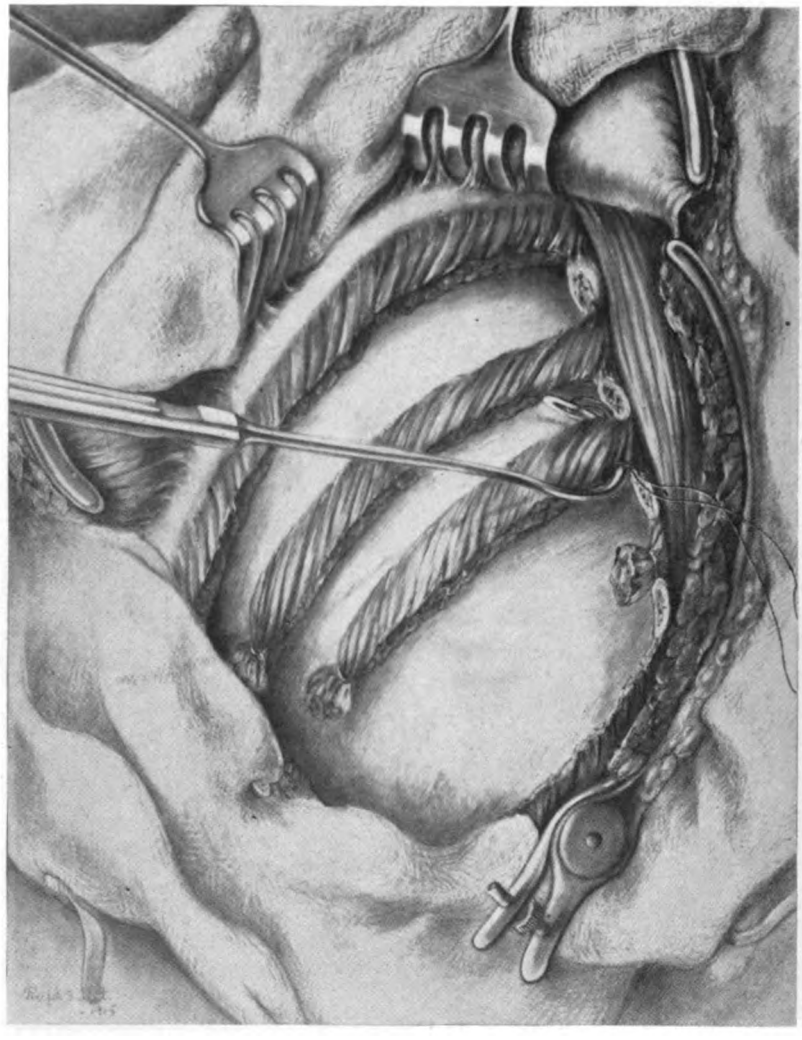

FIG. 44B. MUSCLE IMPLANTATION OPERATION. Second step: Ribs have been resected subperiosteally. Ligation of intercostal bundles. (*Robinson.*)

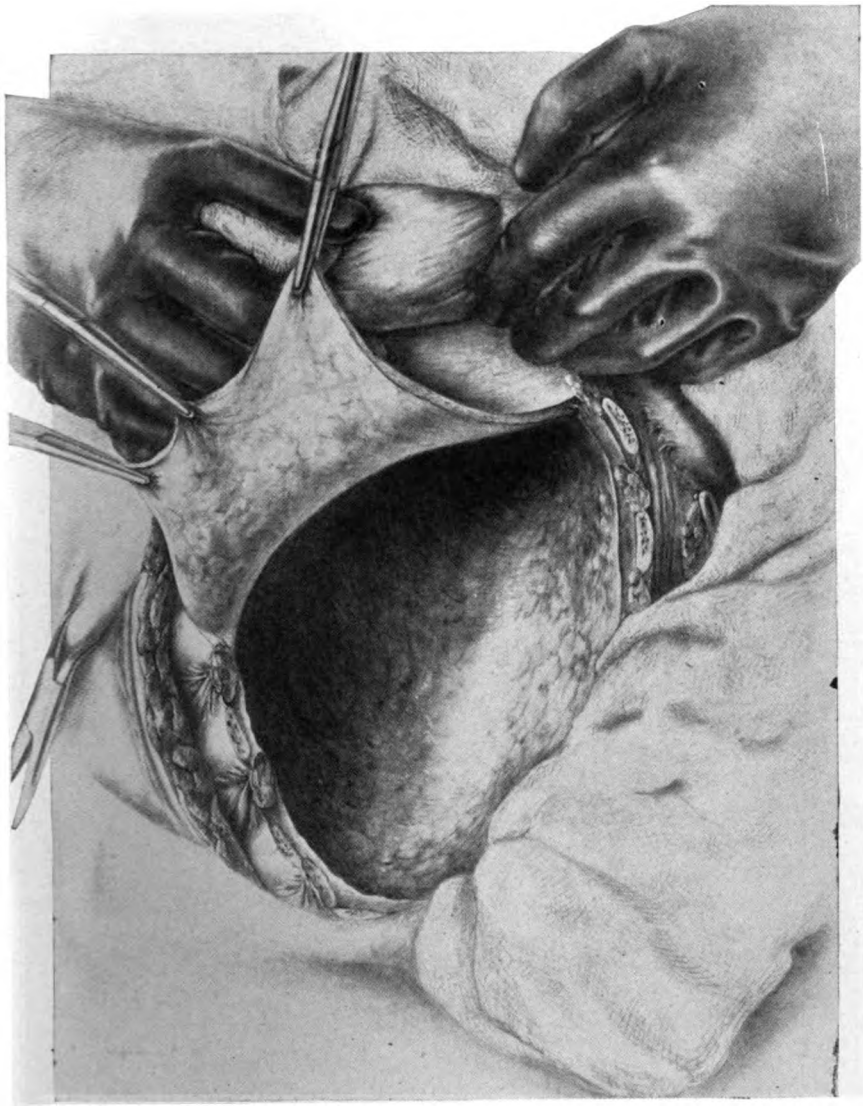

FIG. 44C. MUSCLE IMPLANTATION OPERATION. Third step: Thickened parietal pleura in process of removal. (*Robinson.*)

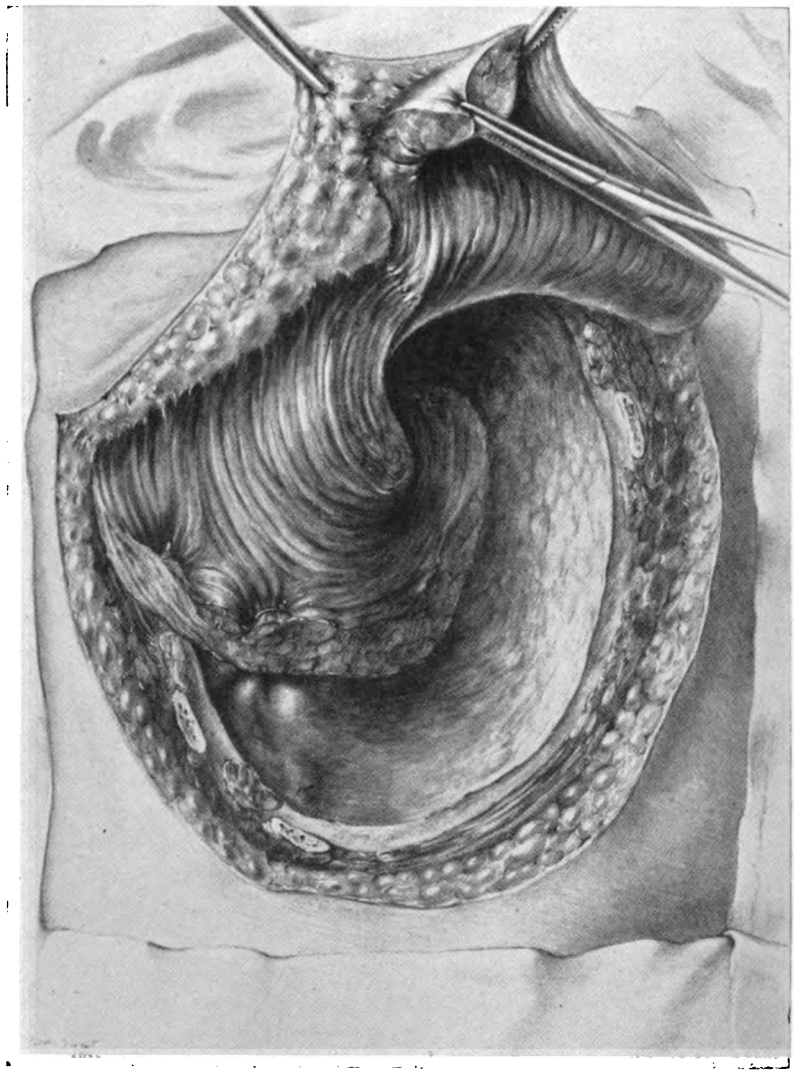

FIG. 44D. MUSCLE IMPLANTATION. Fourth step: Latissimus muscle has been split; one-half has been dissected from U-shaped flap and sutured into top of cavity; the remaining half is to be implanted likewise. Note important lateral sutures to muscle to relieve tension upon stitch at tip of flap. (*Robinson.*)

cavity. The skin and muscles are reflected upwards, the latissimus dorsi being cut between clamps (see Fig. 44A). The ribs are resected and the intercostal bundles ligated and removed (see Fig. 44B). The

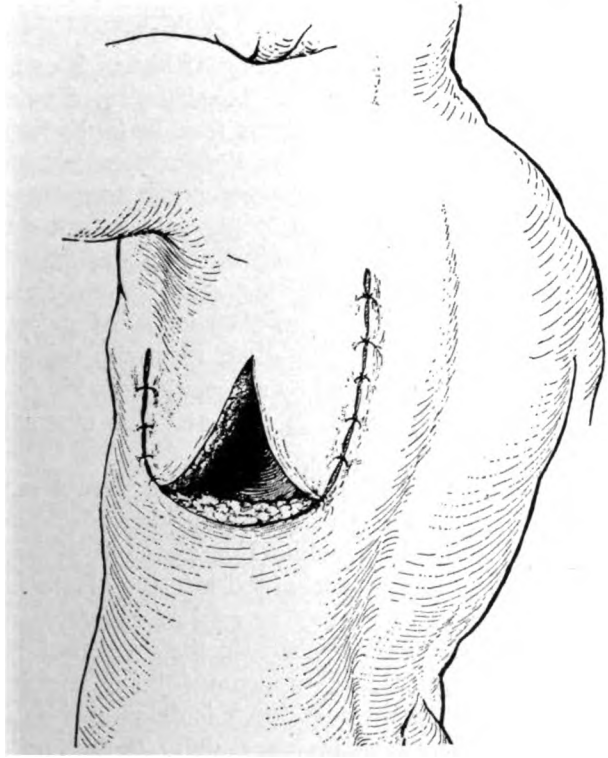

FIG. 44E. MUSCLE IMPLANTATION. Fifth step: U-shaped skin and fat flap has been restored. Triangular piece has been excised from border of flap to permit of free drainage, packing and stimulation of muscle granulations. (*Robinson.*)

thickened pleura is excised, thus opening the empyema cavity (see Fig. 44C). The latissimus dorsi muscle is split and displaced into the empyema cavity (see Fig. 44D) and the skin flap is replaced with a small portion incised for drainage (see Fig. 44E).

BECK'S SKIN IMPLANTATION

Following a technique very similar to the Robinson technique, Beck prepares skin flaps and after excision of the chest wall slides the skin flaps into the empyema cavities. He calls attention to the fact that the thickened visceral pleura should be scarified to enhance adhesions between

the skin and pleura. These flaps are held in position by tampons, no stitches being employed. The result to be obtained is a cavity lined by skin. Beck has proven that although the entire cavity is not covered with skin, there is a rather rapid proliferation of the epithelium and the denuded surfaces are soon covered.

4. *Biliary fistulæ* may follow the opening of hydatids or abscesses of the liver which have burst into the lung and been followed by empyemata. They are not very uncommon. As long as the bile is discharged freely, there is, as far as I have seen, no chance of the empyema closing, however much it be reduced in size, and no operation on the empyema is likely to be of use. Such cases, however, usually get well at last owing to the closure of the bile duct in the liver, though the bile may flow for months and the patient may be reduced to the last stage of emaciation. If *all* the bile escape by this channel owing to obstruction of the common bile duct, it may be necessary to unite the gall-bladder with the intestine. In cases of amœboid dysentery followed by abscess a sloughing process may cause the cavity actually to increase in size, and this ulcerating process may extend into the lung as well.

The presence of a *bronchial fistula* may also permanently prevent the closure of an empyema, though this I think depends to some extent upon the state of the lung or bronchi. For example, if bronchiectasis be present, the amount of mucus discharged into the pleura is enough to prevent its closing, and the same may be said of tubercle or malignant disease. If, however, the lung be healthy, in the great majority of cases the opening in it closes, and the empyema follows the usual course towards a cure. No special treatment for it is demanded or available.

5. *The presence of tuberculous disease* usually, though not invariably, prevents the closure of an empyema, even if the shape and size of the cavity are such as are favourable for a cure. If the patient be in good general condition and the cavity be of moderate size, thoracoplasty should be attempted after warning the patient that the result would probably though not certainly be unsuccessful. But if the tuberculous process be active or advanced, and the cavity be large, it is not right to diminish the patient's vitality by what is sure to be a useless procedure. If calcareous plates be met with, they should be removed if not too large, but not until the external opening is very free, because they are sometimes in contact with large vessels which may be torn during the process of extraction. An abscess originating in caries of the spine, sternum, or rib, or a tuberculous mediastinal gland, may, by bursting into the pleura, give rise to an empyema which can only close after the cure of the primary disease by natural or artificial means.

Whenever tuberculous disease is present every effort should be made to improve or cure it before undertaking any serious operation.

6. No treatment is likely to do any good if *malignant disease* be present.

7. *Foreign bodies,* such as drainage tubes, bullets, pieces of wood, portions of necrosed rib, ears of corn, &c., will effectually prevent the closure of an empyema and call for immediate removal. I have known a lead pencil to be driven through an intercostal space into the lung and remain unsuspected until an incision revealed its presence.

Actinomycosis and dermoid cysts will be dealt with separately.

OPERATIONS FOR CHYLOTHORAX

Chylothorax may be caused by wounds of the thoracic duct or by rupture of this vessel owing to obstruction in filarial disease or in connexion with malignant disease. The traumatic cases may be those of wounds, or of fracture of the vertebræ. True chylothorax must not be confused with the milky pleural effusions met with in some cases of malignant disease. In cases of traumatic rupture of a previously normal thoracic duct healing may be expected to occur after a longer or shorter period of time, as happens almost always if the duct is injured in the neck. If the rupture be complete it is probable that the establishment of anastomosing channels favours this result. In all cases of milky effusion into the chest, therefore, no surgical interference is indicated except it be removal of the fluid by aspiration, and that only if the accumulation is large and leads to interference with the respiration. It may have to be repeated several times. In malignant cases the reaccumulation sometimes occurs very quickly, and under these circumstances little or nothing is gained by aspiration.

CHAPTER V

OPERATIONS UPON THE LUNGS

OPERATION FOR ABSCESS OF THE LUNG

THE method of operating upon, that is of opening, all cases of abscess of the lung is the same, but as the chance of doing good varies very much with the nature of the abscess, it is necessary shortly to discuss the conditions that may give rise to a pulmonary abscess.

Abscess of the lung may be acute or chronic, circumscribed or diffuse.

Indications. Amongst acute abscesses are those resulting from acute pneumonia, septic emboli, the presence of rough foreign bodies, the rupture into the lung of abscesses from neighbouring parts, and some tuberculous abscesses. In all of these except those that occur as a part of a general embolic pyæmia, there is a possibility of affording relief by evacuating the contents.

Chronic or subacute abscesses may result from pneumonia, tubercle, tumour, from the presence of smooth foreign bodies, from the gradual extension of chronic abscesses from surrounding parts, and from bronchiectasis. It is always doubtful if any good will come of opening cavities resulting from tubercle or tumour. Those resulting from tumour are not usually diagnosed before operation, sometimes, indeed, not till long afterwards. Chronic tubercular abscesses, if occurring at the base of the lung, are often much benefited by incision, but they seldom heal. The question of bronchiectasis must be dealt with separately.

Diffuse suppuration of the lung, whether resulting from acute pneumonia, pressure on a bronchus, or tubercle, does not form a favourable field for surgery, though I have known much benefit, it might be said cure, result from incision of acute diffuse suppuration of the base of the lung in a patient supposed to be tuberculous.

Operation. If it be decided to operate, the first thing is to ascertain the position of the abscess by means of the aspirator or preferably by means of the fluoroscope or stereoscopic roentgenograms. It is seldom wise to open the chest until this has been done, and it must be remembered that all the signs of abscess may exist though no localized collection of pus be present. Under no circumstances should an exploration be made by a simple exploring trochar, as it is impossible to diagnose with certainty the presence of adhesions, and if air be admitted to the pleura, the position of the abscess is likely to be altered.

ving ascertained the presence of an abscess the trochar may be
l as a guide, though it impedes the subsequent steps of the
on, or the surgeon may withdraw the trochar and trust to his
r for finding the abscess after dealing with the chest-wall.

y frequently the abscess will be found lying beneath the visceral
and, due to the localized pleuritis, adhesions have taken place
the visceral and parietal pleura. The adhesions, depending upon
of the process, may be of the fibrinous type or may have suf-
organized to have already walled off the remaining pleural
If such is the case, it is most desirable to resect one or two ribs
ately over the area of the adhesions. The abscess can be drained
this area where the lung is, as it may be plastered to the chest
thout fear of soiling the pleural cavity. A drain may be inserted.
umothorax is formed and the remainder of the lung remains active
overy is quite prompt. When there are no adhesions between the
and parietal pleura or when the adhesions are so situated due to
process that they cannot be utilized in the drainage of the abscess,
four inches of two or more ribs are then removed in the usual
ut much greater care must be taken in clearing the deep
of the ribs than in a case of empyema, as there is danger
ing the pleura and, by causing a pneumothorax, preventing the
ul completion of the operation. When a sufficiently wide area
ostal pleura is clearly exposed, a single or preferably double row
nuous catgut sutures is inserted by means of a rather large fully
Hagedorn's needle, which is passed deeply enough to attach the
the chest-wall, and, if any air is heard to suck into the pleura,
itches should be inserted until the union is definitely air-tight.
his result has been obtained, the pleura is to be incised, and then
ess is again sought for with an ordinary exploring trochar, or
riginal trochar has been retained in position, this will serve as
The actual opening of the abscess is conveniently done by
f sinus forceps or dressing forceps, or even by the knife. I do
ommend the use of Paquelin's cautery, as the hæmorrhage is
of much moment and usually stops after a few minutes' pressure,
as happens in some cases, it is at first rather severe. The finger
llows the instrument with which the opening has been made,
the cavity, breaks down obstructing bands, and then a drainage
suitable length to thoroughly drain the cavity, is inserted and
position to the skin as in a case of empyema. If bleeding be
e tube may be packed round with gauze, though this should, if
be avoided as it may cause unnecessary damage to the lung.

nopened, pulmonary abscesses may burst externally, sometimes

just above the clavicle or sternum, occasionally involving on their way the sterno-clavicular articulation, or through an intercostal space, or passing into the abdomen may reach unsuspected regions.

OPERATIONS FOR BRONCHIECTASIS

When giving an opinion about the treatment of a case of bronchiectasis it is necessary to inquire into the cause and history of the case. The most hopeless ones are those that come on insidiously as the result of, say, whooping-cough or pleurisy or chronic bronchitis, and already yield physical signs at both bases; the more promising are those that follow the inspiration of foreign bodies, or those that result from some localized pulmonary affection even if it be tuberculous.

The results of surgical interference have been so unsatisfactory that

FIG. 45. MUCH-BRANCHED BRONCHIECTASIS, UNFAVOURABLE FOR OPERATION.

one is often tempted to refuse operation. If there be extensive dilatation of bronchi on one or both sides (see Fig. 45) the mere opening and draining of one cavity, which is often a simple enough matter, can hardly give more than temporary relief. The most reasonable surgical procedure would be an extensive horizontal section of the lung which might open many of the cavities. It would have to be made with the actual cautery and might involve serious bleeding. The removal of many ribs in order to allow the chest to fall in, with the idea that any further contraction of the lung might involve a diminution in the size of the bronchi, has more theoretical than practical value.

it must be remembered that the process is not necessarily so ead as the physical signs suggest, and also that there may be one esulting from the fusion of several bronchiectases. In some of

46. LARGE CAVITY RESULTING ONCHIECTASIS, FAVOURABLE FOR ON.

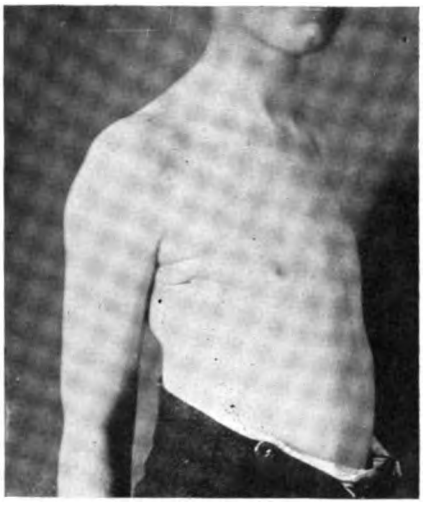

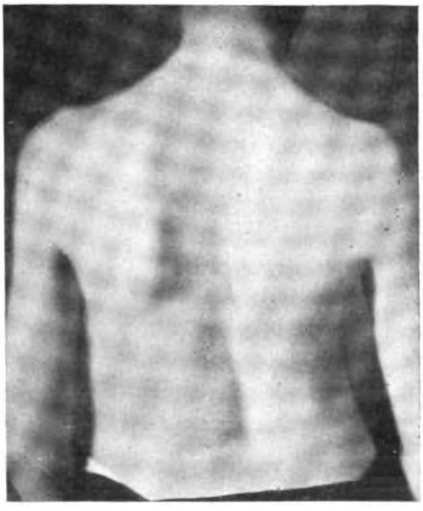

FIG. 47. LATERAL AND BACK VIEWS OF A BOY WHOSE BRONCHIECTATIC CAVITY WAS CURED BY OPERATION.

alized cases large portions ffected lung have been re- apparently with good ef- Occasionally, after giving no hope of benefit, I have uch a cavity (see Fig. 46) ed the patient by free in- to the lung (see Fig. 47); ave often seen operations l by temporary benefit and later on by a relapse, accompanied by severe hæmorrhage or cerebral abscess or some of the other zed sequelæ of bronchiectasis. The condition is, however, so

hopeless if untreated, and so extremely disagreeable, that patients often grasp at the slender hope of cure which operation offers, and then the surgeon is justified in undertaking it. I desire to emphasize the fact that even in advanced cases, and in spite of suggestive physical signs, it is common to meet with a completely non-adherent pleura.

The exploratory puncture of a lung riddled with dilated bronchi and yielding marked physical signs of a cavity and copious expectoration often fails to extract even a drop of pus. Should, however, a cavity be reached and opened its nature is at once recognized on introducing the finger by the smooth lining wall, which contrasts with the spongy wall of most other pulmonary cavities. Very copious and even dangerous hæmorrhage may occur if any attempt be made to dilate the neck of such a cavity; this may also occur apparently from ulceration caused by the drainage tube at a subsequent period, or from the puncture made before the operation for the sake of diagnosis. Such hæmorrhage can be stopped by plugging, as the walls of the cavity are firm, but is very apt to recur, and, as is known, is quite common if no surgical treatment has been adopted.

It is specially after opening a bronchiectasis, though it is observed in other cases of pulmonary abscess, that a loud whiffing sound is heard on inspiration and sometimes a louder sound on expiration. Respiration through the opening is indeed often so free that the patient can breathe with mouth and nose shut, and cannot speak above a whisper unless the wound be closed. This inconvenience may be overcome in cases where it is desirable to keep the opening patent as a matter of precaution, and when the discharge is little or nothing, by substituting a solid plug for the tube and removing it when required; or if a tube is still necessary, by keeping the dressing in place by strips of adhesive plaster. If the case is thought to be cured the opening should be closed by a plastic operation.

OPERATION FOR TUBERCULOUS ABSCESSES

Chronic tuberculous abscesses at the base should always be opened, and though in some cases a permanent fistula may result, a certain number will be cured. Cavities at the apex are usually only a part of extensive pulmonary infiltration and are probably in most cases better left alone. But I think there must be a certain number in which the disease is localized where an incision into a dependent part would, by relieving cough, make the patient more comfortable and possibly check the advance of the disease. This view has not, however, made much way with physicians, certainly not in this country, probably because the suitable cases are just those in which a spontaneous cure may be

ed, and also because a phthisical patient with a large apical not nearly so much troubled by the cough and expectoration ho has an imperfectly drained basic cavity or a bronchiectasis; h of a phthisical patient being comparatively speaking an easy the sputum never having the foul smell that is common in the other cavities referred to. But I still think, as I said , that this is a field of surgery which is capable of further ient.

ation on tuberculous cavities is usually rendered simple by the of adhesions. The surgeon will sometimes be disappointed by both in the more acute and the more chronic cases, that instead rge cavity which the physical signs have appeared to indicate, le of the affected part of the lung is riddled with small . Operation in such cases may, however, be followed by bene-ilts.

ngst the surgical treatment of tuberculous cavities must be d the *intrapulmonary injection* of various medicaments which time to time been suggested. The method of performing this ration does not call for a detailed description.

ifferent grounds it seems unnecessary to describe the suggested ns for *removal of the affected part of the lung.* It has been be possible both in the lower animals and in man; but as it is ent only applicable to early cases for which more rational and eful treatment is available I cannot believe that 'extirpation of ' for tuberculous disease will find a permanent place amongst ed surgical operations.

EMOVAL OF FOREIGN BODIES IN THE LUNG

removal of foreign bodies from the bronchi by means of the cope is dealt with in Vol. IV. The attempt to extract foreign om the lung itself may fall to the lot of the general surgeon.

oth bodies may remain for months or years in one of the bronchi, gradually setting up bronchiectasis, but not creating in their immediate neighbourhood. Rough ones may set up n at the points where they are lodged; such objects as pieces may travel to distant parts of the body and possibly escape e surface, while seeds may swell or germinate. Any of them se irreparable damage even after a short residence in the lung, efore, if possible, an attempt should be made to remove them delay. If they are opaque to X-rays a stereoscopic skiagram e taken and the precise distance from the surface of the body f possible be ascertained.

The present war has brought about many changes in thoraci
gery. This applies especially to the localization and removal of f
particles incident to warfare. The present status of lung surgery
concerns the removal of foreign bodies can well be described
words of Moynihan:

'We may say with confidence that a rifle bullet, or a small pi
shell casing, may be retained for months or years without causing d
and without affecting appreciably the normal functions of the l
which it lies buried. But with large or irregular pieces of shell th
is different. I have seen many patients suffering for 12 or 18 r
from cough, with hæmoptysis at intervals. In two cases the l
blood was serious. And in many patients there is an increasing
plaint of pain, dyspnœa on exertion, and of expectoration of mucu

'For these reasons I have recently given special attention to
patients and have submitted a number of them to operation. The
so far entitle me to say that it is probably a safer, as it is certa
speedier, procedure to submit all patients, in whose lungs a larg
jectile is retained, to operation rather than to leave them untreate
almost every case operated upon the projectile has been dropped a
into a culture medium: with one exception all missiles were in
the organisms most commonly found were staphylococci.

'The following are the details of the procedure adopted for t
traction of bullets from the lung. The new features in the meth
chiefly due to the initiative and the superb technical skill of Pierre
to whom I most gratefully acknowledge my indebtedness. The op
is performed in anæsthesia induced by ether and oxygen. A preli
injection of morphine and atropine is given about half an hour bef
operation.

'The patient lies flat on his back, with the arms to the side. A
incision about 5 or 6 inches in length is made exactly along the line
fourth rib. The fibres of the pectoralis major are split, and the pe
minor separated from the rib. There are many points of hæmo
requiring a clip or a ligature. All must be carefully secured
there is a perfectly dry field. The rib and the costal cartilage a
posed for a distance of not less than 5 inches. An incision is
through the periosteum midway between the upper and lower bord
this membrane is stripped from the rib on both surfaces. A l
curved raspatory is very useful for the purpose. In my earlier
tions I cut through the costal cartilage and then divided the ri
forceps so that a length of 4 to 5 inches of the rib could be remove
later operations I have freed the inner end of the rib after c
of the cartilage, have passed a strip of gauze beneath it, and

ard and outward. In this way the rib may be saved, and
d at the end of the operation. This, however, is not a point
t importance, for when the periosteum is left, a new rib is formed
pidly, and the chest wall soon becomes as firm as ever. Care is
n excising the rib and in lifting it away not to wound the pleura,
must be separated widely from the ribs above and below, to the
nd the outer side of the wound. Unless this is done, accurate
of the pleura later on, always difficult, will be impossible. A re-
is now placed in the wound to widen the interval between the ribs
nd below. Any abdominal retractor will do: but the best instru-
have used is that invented for this special purpose by Tuffier. As
gap as possible is made, so that the whole hand can easily be passed
e chest.

he pleura is now incised along the line of the rib and air enters
nd at once into the pleural cavity. As a rule this causes no dis-
e and does not alter the rate of the respirations or of the pulse.

he hand is now passed into the chest cavity. Adhesions of the lung
parietal pleura may be encountered. These are sometimes very
and easily broken through. At times they are tough and strong
e with great difficulty severed. If they are numerous or thick and
bleeding may occur quite freely for a minute or two. With a gentle
e from a hot moist swab, the oozing is soon checked. In a case
a projectile was in the base of the right lung posteriorly, the whole
lower lobe and a great part of the upper lobe were most intimately
nt to the parietal pleura. The adhesions, however, separated in
e same way as adhesions within the abdomen separate, by gentle
e and stripping. Thoracic adhesions bleed, I think, far more freely
ose encountered in the abdomen. When all are loosened, the col-
lung lies free within the pleural cavity. It may now be seized
e fingers or with a special light form of clip and drawn up to the
r wound, and, little by little, be coaxed out of the wound. It is
nded as it appears by warm cloths soaked in normal saline solu-
When a lobe of the lung is freely delivered it is palpated from top
om. Any projectile embedded in it is felt as a rule at once. Even
equestra blown in from a rib may be recognized without any
ty. These foreign bodies are as easily recognized as the par-
f gritty sand in a new sponge. When the projectile is felt, the
the lung containing it is made prominent, the lung tissue lying
is incised, the metal removed, and the wound sutured. Deep
s of catgut are passed through the lung substance, and with gentle
act as a hæmostatic.

f necessary very fine catgut sutures may be used to secure the

accurate apposition of the pleural edges. If there is any bleedin
the collapsed lung, it is slight and easily controlled, but precision in
is most desirable, for expansion of the lung will rapidly be secure
the operation is completed. If there are two or more parti
shrapnel or shell casing in the lung, they are all dealt with in th
way. I have once incised the hilum of the lung and stitched it u
out difficulty. When the sutures are completed the lung is replac
cavity of the pleura most carefully dried and emptied and a gauz
wet with ether wiped over the visceral pleura, and over any ad
which may have been separated. The retractor is removed a
parietal pleura now stitched up. This is quite the most difficult
the operation; indeed I have not been able to close the pleura acc
unless this membrane has been stripped up freely from the chest w
fore being incised. The rib, if it has been turned back, is replac
fixed in position by a suture through the costal cartilage. The
are carefully sutured and the wound edges accurately approximate
out drainage. The closure of the wound should be so carefully
to seal the chest hermetically. When the dressing is applied, a t
needle may be plunged into the chest, and the ether and air ex
therefrom. The lung then rapidly expands and faint breath sou
heard at once. No shock follows this operation.'

OPERATION FOR ACTINOMYCOSIS OF THE LU

Numerous fungi may attack the lungs, amongst which actino
is the one most generally recognized. It appears that more or less
cases of the disease may result from the attacks of different org
The surgical treatment adopted for actinomycosis is suitable for a
of pulmonary mycosis.

The organism may enter the chest by the air-passages or by ex
from the liver. In time its ravages extend to the pleura and t
in which it quickly invades the cancellous structure far and wi
ultimately it points on the skin. Vigorous internal treatmen
iodide of potassium having been started at the earliest opportun
external parts, including the ribs, should be freely dealt with, the s
tissues being cut out or scraped and treated with pure carbol
It must be seldom that the infiltrated lung can be attacked w
safety, as is shown by studying museum specimens; but the tr
here recommended, accompanied by the administration of 90
grains of iodide of potassium a day, may effect a cure even altho
lung is considerably involved. If an attempt be made to scrape th
very free hæmorrhage must be anticipated and the unsatisfactory
of packing the wound in the lung will probably have to be reso

igh speaking from a rather large experience of actinomycosis, never met with a case of infection by an aspergillus or any fungus.

ERATION FOR HYDATID DISEASE OF THE LUNG AND THORAX

inococcus cysts may occur in the bones of the chest. Such cases treatment on general principles. They may also be met with mediastinum, the lung, and the pleura, which may be the primary the disease or may have been invaded from the liver or some bdominal viscus. They may be living, or dead and suppurating. tter must be treated like abscesses of the mediastinum, or lung, empyemata, as the case may be, the only difference being that the st and all daughter cysts should be removed. The chance of ng the ectocyst is very small, but if it can be effected the cure more rapid.

peration. In the case of a living hydatid, supposing the diag- o have been made, the surgeon should on no account explore st even with an aspirator, because of the risk of rupture into chus occurring at the same time, which may result in suffocation. pening the chest very freely the cyst should be exposed, whether mediastinum, pleura, or lung, and after evacuating the contents, mpt may be made to isolate it from surrounding structures. If ould prove successful the hole in the chest-wall may be closed; ccessful, the cyst must be fixed to the opening and the tedious of 'healing from the bottom' embarked upon. During this the patient should be kept in good hygienic surroundings. I have ore than one case become tuberculous. The expectoration of l material does not prove the existence of an intrathoracic cyst, ould suggest a careful examination of the liver, as hydatids of this not infrequently burst upwards. Such cases are usually best ith by making an abdominal, or at all events a subdiaphragmatic, as a thoracic opening. Multiple hydatids of the chest, though not n, are by no means unknown.

RATION FOR DERMOIDS OF THE INTERIOR OF THE THORAX

rmoid cysts of larger or smaller size are occasionally met with in est; they sometimes involve the pleura and usually the lung, s does not prove that they do not always originate in the media- . They resemble ovarian dermoids in being lined by real skin having large finger-like processes springing from the inner

wall, from which as well as from other parts long hairs, so
like those of the patient's head, sometimes of a different colou
Occasionally bones and other fœtal débris are met with, su
the idea that they are included fœtuses. They need cause no sy
until they burst into a bronchus, which seems sooner or later
to occur, or into the pleura, which is less common. In th
case an empyema results, on opening which the diagnosis is r
finding free felted masses of hair in the interior. In such a c

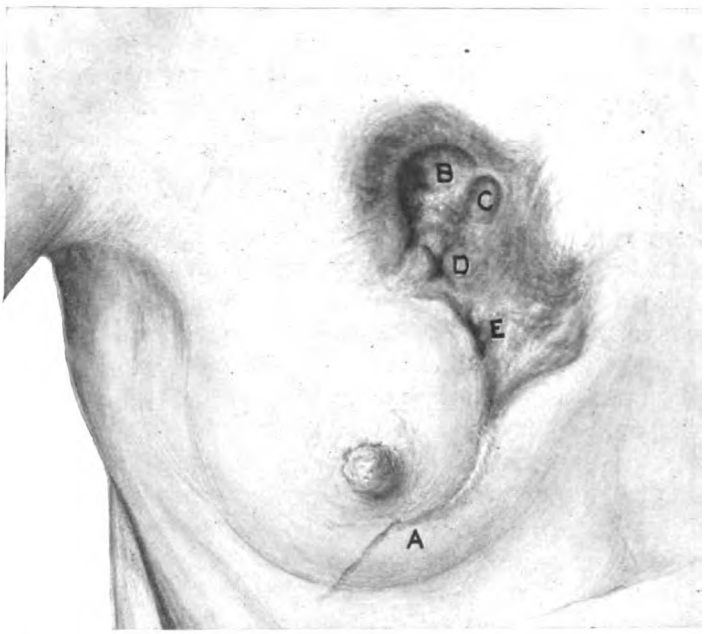

FIG. 48. DERMOID CYST OF THE MEDIASTINUM AFTER ELEVEN OPE
A, Lower limit of original incision; B, C, D, E, Pouches still remaining,
skin. That indicated by B communicates with a large bronchus.

necessary to make a very free opening and remove as m
possible of the finger-like processes and skin, but the complete
of the cyst is impossible as it actually involves the lung. The
unsatisfactory because the interior does not dry up, however l
opening, and the offensive smell of decomposing epithelial st
is a great annoyance to the patient. Moreover, as a bronchial f
usually present, the disagreeable consequences of a discharge of
more or less cough, and the chance of strange noises occurrin
external opening add to the patient's troubles. All that can

r permanently a large vulcanite, or silver, or rubber tube, and cavity as clean as possible.

ame must be said about those cases, usually situated near the ne, which have ruptured into a bronchus, but in which the is escaped. One or two small ones have been successfully and an attempt should be made to enucleate such a one if it o be circumscribed; but numerous autopsies have shown that r parts are usually so intimately related to the large vessels in stinum that complete extirpation is quite out of the question. y be added that by free drainage the general health may be amyloid degeneration counteracted, and life prolonged; and nt is probably glad to substitute the discomfort of a rather external wound for that of a racking cough with foul expec- I think the risk of hæmorrhage is rather increased by the opera- case under my care at the present time has greatly benefited by This has been repeated on many occasions. Each time more iry skin has been removed or cauterized, until at last there is e than a large bronchial fistula, the outer part of which is lined see Fig. 48). Considerable portions of the upper rib cartilages have been removed on the right side and the pulsation trans- this unprotected area has a somewhat alarming appearance.

MOVAL OF TUMOURS OF THE LUNG AND MEDIASTINUM

are primary simple tumours of the lung, such as fibromas, and others, about which little is known and no surgical treat- present likely to be suggested.

rto the available methods of diagnosis have seldom been y exact to warrant an exploratory incision while such growths enough to justify attempts at removal. Should radiography al signs render the presence of such a growth probable no should be felt in opening the chest, even without the means ting pneumothorax mentioned at p. 129, because the disease ne is hopeless, and the possibility of removing even large por- he lung without fatal results has been fully demonstrated both d in the lower animals.

dealing with a malignant tumour of the chest-wall it be found te the lung, the extent of the growth in this direction and if he state of the bronchial glands should be ascertained by and if it appears sufficiently circumscribed the whole mass removed together, either after constricting the lung beyond

it with ligatures or, if this be not done, by cutting it away with th
cautery. Flaps of pleura may be fashioned to cover over the stu

The mortality after these operations is likely to be high
prognosis, even if they are successfully completed, unfavourabl

The method of opening the chest widely by making a lar
including the superficial soft parts together with the ribs and
might be found useful in exploring or dealing with primary t
After the removal of the portion of lung, or after deciding tha
not possible, the thoracic walls would be sutured carefully in
Supposing the 'high-pressure' or 'low-pressure' methods were
the difference between the intrapleural and the extrapleural
should be maintained until not only the muscular and osseous
also the skin flap have been accurately sutured. If the opera
done under ordinary atmospheric conditions the air may be,
at least, extracted by the aspirator at the end of the operatio
this is of doubtful value and might well result in the displace
a pleural flap or the sucking in of air through divided bronchi
monary parenchyma. Moreover, if the case be aseptic the air
absorbed.

The position of the opening into the chest must vary with
posed position of the tumour, but for the purpose of exploration,
be no certain guide from physical signs, the lower axilla is likely
the most satisfactory results.

REMOVAL OF TUMOURS OF THE MEDIASTIN

I have not yet met with a tumour of the mediastinum, eithe
or malignant, which seemed to me capable of removal, though
endeavoured to do so after trephining the sternum. It has been
mended to trephine or resect parts of the sternum or to freely
posterior mediastinum, but the prospect of dealing satisfactor
malignant growths in this region seems to me very slight. Sti
reading of an operation by Dr. Marwedel,[1] for sarcoma of the
stinum in a woman of twenty-two, in which, after removal of th
brium and parts of the first and second right ribs and wound
pleura, the tumour was successfully taken away, and not only
patient recover but at the end of two years was alive and well,
married and borne a child in the meantime, it does not do to sp
disparagingly of this new field of surgical advance. The record
show a high mortality and a high percentage of early recurr
might have been expected. Secondary tumours are beyond th
of operation.

[1] Recorded by Amburger in *Beiträge zur klin. Chir.*, 1901.

CHAPTER VI

ATIONS UPON THE PERICARDIUM, THE HEART, AND THE PULMONARY ARTERY

EPAIR OF WOUNDS OF THE PERICARDIUM AND HEART

NDS of the pericardium and heart may be produced by stabs, or ounds, or in- the chest-wall ithout fracture or sternum, or quite unlikely The substance he wound may ered from the the back, or the from above or A sword-swal- ured his heart directed effort, heart may be by a blow on strium. A man shot in the re- position, and et has been enter the heart one of the great ithout passing he pericardium. soft chests of or women the ay be almost from its at- without any fracture or external wound (see Figs. 49–52).

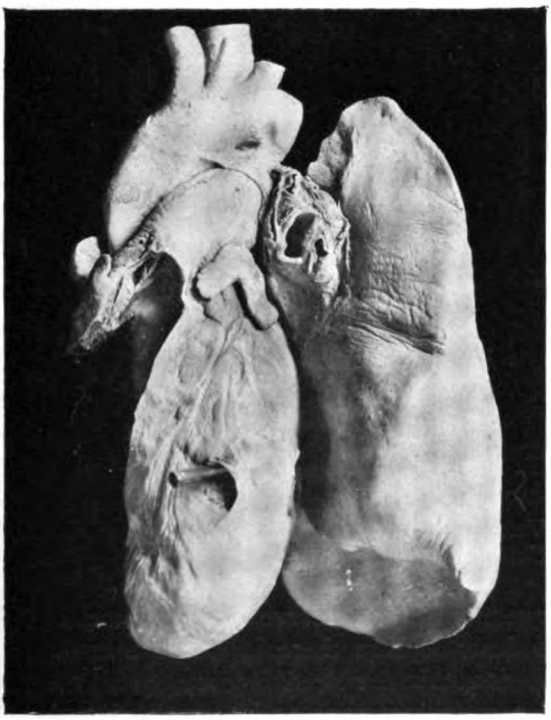

FIG. 49. A WOUND OF THE HEART WHICH PASSED THROUGH THE VENTRICULAR WALL WITHOUT ENTERING THE VENTRICLE. (*University College Hospital Museum.*)

cations. When it is remembered that the injury may vary mere prick of a needle to the grave injuries just mentioned, it

will be recognized that the advisability of active surgical treatme vary enormously with the nature of the case; in some the ch recovery without interference being great, and in others the ch doing good being nil. There are various other consideration modify the prognosis and treatment; for example, wounds of tricles need not ne penetrate the those of the auric tically always do

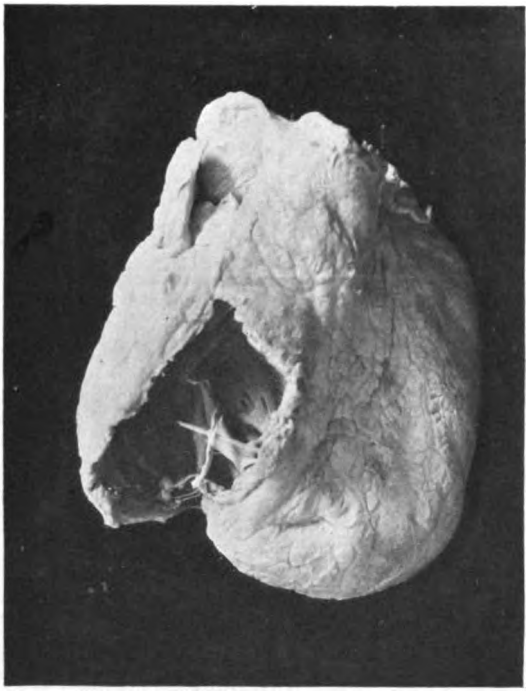

FIG. 50. AN EXTENSIVE RENT IN THE RIGHT VENTRICLE CAUSED BY A CRUSH. (*University College Hospital Museum.*)

Wounds of th need cause no rhage; injury of nary artery is a v ous complication that of the peri while a less seri more common on involvement of both pleuræ; but lung or a bronchu jured, air may e pericardium and to strange physic and symptoms. be an external there can be no against sepsis, many promising have died of per and pleurisy, this borne in mind w question of the closure of the wound is being considered. It follow, because there is free hæmorrhage from a stab in the region, that the bleeding comes from the heart, as it may come internal mammary or intercostal vessel. The blood coming f right side of the heart is of course dark, that from the left bright

Until about 1896 no attempts were made to deal surgica wounds of the heart. They were all treated by absolute rest, l and sometimes by blood-letting: and a certain number of cases re as is shown by the records of many in which the diagnosis wa above suspicion, and others in which foreign bodies have actua found in the substance of the heart long after they have been k

have entered it, such as bullets or needles which have penetrated from outside or which have been swallowed.

As this is the case, it may be right to pause in any given case of suspected heart injury before proceeding to an operation; but against waiting too long it may be urged that bleeding which has stopped not unfrequently recurs, that the patient's condition may be rendered so much worse by delay that surgical interference becomes hopeless, and that while, as has been said, foreign bodies in the heart sometimes do no harm, they may give rise to fatal consequences at a remote period after their introduction. It may be said that the operation in itself is a dangerous one, and this cannot be denied; but, on the other hand, the dangers of septic pericarditis ought with our present methods to be materially diminished by its performance. On the whole, therefore, modern opinion seems to be in favour of early interference in cases of suspected or undoubted injury to the heart.

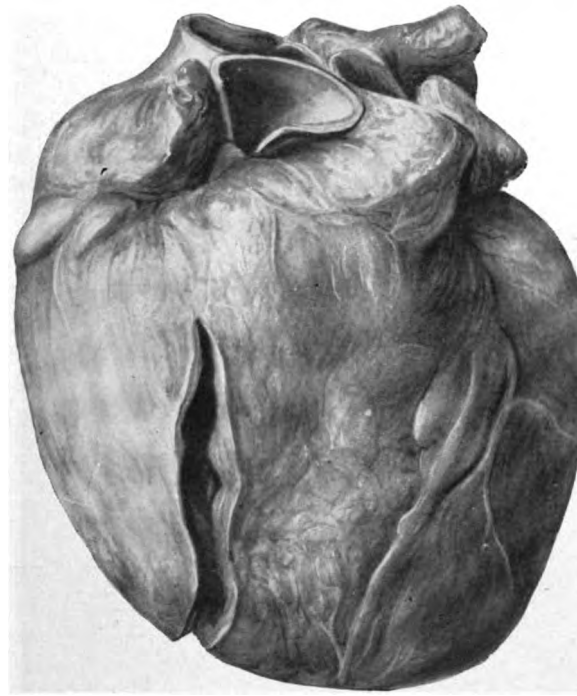

FIG. 51. A WOUND OF THE HEART CAUSED BY A BLOW FROM THE FIST. (*St. Thomas's Hospital Museum.*)

Operation. As is common in new fields of surgery, a number of different methods of operating have been recommended, and in the lack of personal experience it becomes necessary to mention the general principles, and to select from more detailed description those which seem most wise.

The earlier operations appear to have been done through an opening obtained by the removal of one rib. I do not think this will generally give enough room for the subsequent procedures.

The other plans recommended consist either in (1) the removal of parts of two or more ribs and rib cartilages subperiosteally, or (2) the formation of a hinged flap consisting of skin, ribs, and muscles, or (3)

in the combination with either of these methods of the section moval, of a portion of the sternum. To these I may add what c appear to have been practised, (4) the reflection of a skin flap a of a hinged flap of muscle and bone, and, lastly, (5) the exposur heart through an abdominal incision.

The exposure of the heart through an abdominal wound d appear to be a practical procedure, and would probably only itself in cases where such a wound is already present. It seems that a free view of diac wound could tained in this way.

FIG. 52. WOUND OF THE HEART FOLLOWING A FALL. A needle has passed through an intercostal space and penetrated the apex of the right ventricle. (*St. Thomas's Hospital Museum.*)

The subperioste moval of the ribs is sa unobjectionable beca ribs are regenerated. great a portion of removed is cartilage if this can be trusted I do not think it is leave the heart unpr Moreover, this is not t expeditious way of op

The division of t num seems a needle vere procedure, and were divided in two is difficult to see h bone could be drawn

It appears theref a hinged flap of ribs tercostal muscles is be recommended.

scriptions of these operations the skin is usually left attached to but I cannot help thinking that it would be more easily done if of skin and pectoralis major were first reflected, and then the flap and muscles; and that the suturing of the wound would also b easily performed if this course were followed.

A horseshoe-shaped or rectangular flap is probably preferab triangular one. The base may be internal or external, or, if it ferred, superior or inferior; but the most practical plan seems to be the flap outwards. It should be at least 3 inches from side to si should extend almost or quite half-way across the sternum. It sh

ıgh from above down to expose the fourth, fifth, and sixth ribs
53, 54). Supposing the flap of skin and pectoralis major be
d aside, the flap of rib and muscle may be turned either inwards
ds. The latter seems to be the better plan, as it admits of re-
part of the sternum, if necessary. The knife is carried along
border of the fourth rib and a short distance below the lower
the sixth rib, the cartilages and muscles are then divided close

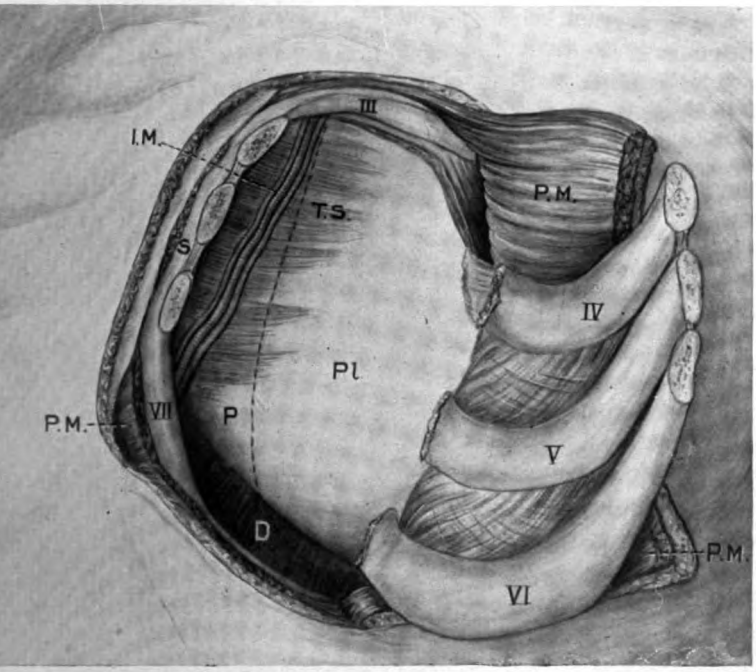

. DISSECTION TO ILLUSTRATE THE OPERATION FOR DEALING WITH
THE HEART. P.M., Pectoralis major; S., Sternum; III, IV, V, VI, VII,
cartilages; I.M., Internal mammary vessels; T.S., Triangularis sterni;
gm; PL., Pleura, the edge shown by dotted line; P., Pericardium.

ıum, and the ribs are cut through with cutting pliers 3 inches or
ı the sternum. The flap is then raised and pulled forcibly out-
he pleura, if not already wounded by the injury, is, if possible,
intact; but if it be opened, the margin of the lung must, either
riod or later, be sutured to the intercostal spaces. Should a
orax occur, the consequent diminution of the blood pressure
tate the subsequent placing of the sutures in the heart, con-
f which will be rendered less forcible. It has indeed been ac-
ımmended to make a pneumothorax with this object by opening

the pleura. At this period of the operation it will probably be n to ligature the internal mammary vessels in two places, and mo to tie one or more intercostal vessels. The incision into the peri is best made in a vertical direction, but lateral incision may be necessary (see Fig. 54.)

The real difficulties of the operation now begin. The blood or the mixture of blood and air, must be rapidly but gently remov

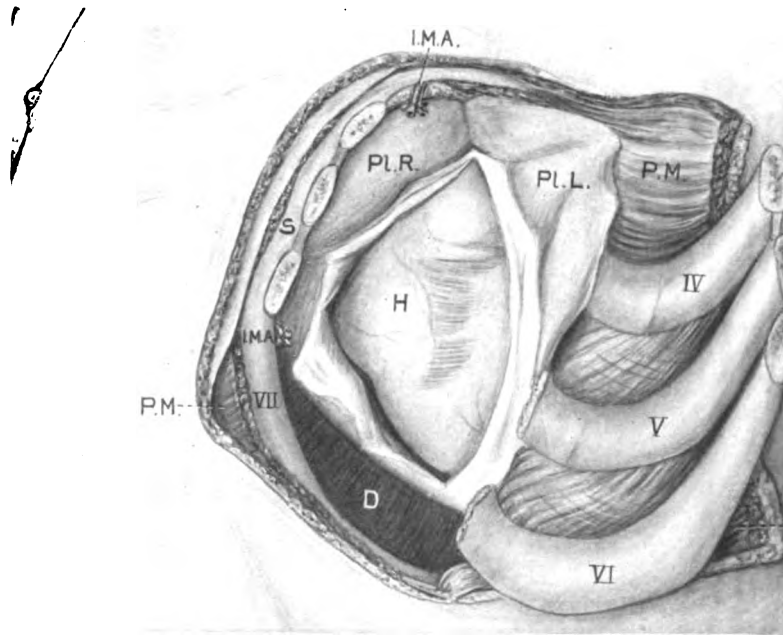

FIG. 54. DISSECTION SHOWN IN FIG. 53 COMPLETED. P.M., Pectorali S., Sternum; III, IV, V, VI, VII, Ribs and rib cartilages; I.M.A., Internal n artery; PL.R., Right pleura; PL.L., Left pleura; H., Heart.

the pericardium, and a search made for the wound. This is for usually on the anterior surface. But it may be behind, or there more than one. It may involve either ventricle or auricle, or on large vessels, and it may be complicated by a wound of a coronary The wound in the heart must be temporarily gently plugged, whi easier matter in the case of a ventricle than in that of an auri either case it may necessitate the gentle grasping of the heart surgeon's left hand. Great care should be taken to prevent the of air into the heart. The stitches are then to be inserted. I worthy catgut be at hand, it is preferable to silk or linen thre

ay be used. Intercepted sutures are probably better than con-
ones; they may be introduced with a fully curved needle held
lle-holder, and must be much closer together in the case of a
f an auricle or large vessel than in that of a wound of a ven-
ome surgeons recommend a purse-string suture.

ng the insertion of the stitches the heart must be steadied, either
rgeon's left hand or by the insertion of a silk thread through
of the heart. It has been recommended to pass stitches into the
icle during systole and into the right during diastole, but the
ical correctness of this advice has been called in question, and
cability of carrying it out appears very doubtful.

it is clear that the wound or wounds are completely closed, all
age from the coronary arteries or their branches is to be at-
, and then the incision in the pleura is to be sutured. It appears
st to leave a drainage tube in the pericardium, because pericar-
quently follows the operation. Some have also methodically
ne pleura if that cavity has been opened, but this may be left to
casion, as necessity for it may never arise. The accumulation
in amount of fluid in the pleura is not so serious a matter for a
ho is passing through this ordeal as is the presence of a serous
nt collection in the pericardium. After suturing the pericardial
e flap of ribs and muscle is to be replaced and fixed by a few
nd then the edges of the skin are to be brought into accurate
n. In the course of the operation it may have been necessary to
y a part of the sternum by means of gouge forceps or other
nstruments, in which case the flap of ribs and muscles can only
d in place at the upper and lower borders.

eedless to say that during the performance of the operation the
condition is likely to be a very critical one, and that cases of
the table must occasionally occur. The question of the adminis-
a general anæsthetic will have to be considered, and no doubt
in number of cases it can be dispensed with. If the pulse be-
remely feeble, it may be advisable to give an injection of saline
ither into a vein or into the right side of the heart. But this
done cautiously, lest the resulting increase in the force of the
ulsations should interfere with the insertion of the stitches.

apparatus were at hand and time allowed, the use of the 'high-
or the 'low-pressure' methods of operating might conceivably
great service.

iting this section I am much indebted to Professor Riedinger's
chapter in the *Handbuch der praktischen Chirurgie,* 1907,

PARACENTESIS AND OPENING OF THE PERICAR

Paracentesis. In pericardial effusion where there are n sions, the heart occupies the outer, anterior, and upper part pericardium; the fluid collecting chiefly at the posterior and low of the cavity. This is the case when the body is recumbent as when it is erect. It is thus possible to aspirate the pericardium t an intercostal space near the lower part of the sternum without i the heart. But owing to the variation in the extent forwards a by the pleura, there is no certainty that this sac will be avoided, the spot chosen be the fifth interspace on the left side close to t num. On the other hand, if a similar spot on the right side be s it is just possible that the pleura will escape. Some authorities st a distended pericardium separates the two pleuræ, but I doubt if generally the case. Fig. 55 gives the arrangement of pleura, perica and vessels as determined by the average of several dissections not, however, usually a matter of much importance in performing aspiration, though, if the fluid be actively septic, the pleura may infected.

The only way to be sure of escaping the pleura is to punctur below with or without preliminary abdominal incision. The latt would probably avoid injury to the peritoneum. Another su route for entering the pericardium is by trephining the sternum seldom followed, for it complicates the operation and does not nec secure the avoidance of the pleura, because, in the first place, t pleuræ are often in contact much lower down than is considered n and, secondly, the line of attachment of the anterior mediasti the back of the sternum, which forms here a sort of mesopericard easily moved for a considerable distance to one side or the other, a displacement may well occur in a case of pericardial effusion. In ing the spot for the puncture, the position of the internal ma artery must be borne in mind. Though subject to a certain amo variation it usually approaches closely to the border of the sternu is here almost never more than ½ inch from its outer border. T therefore to be recommended is the fifth left interspace, ¾ inch fr sternum. The trochar should be passed backwards and to the rig the right fifth intercostal space be selected, the trochar should be backwards and to the left. A bottle aspirator with very slight n pressure in the bottle, a siphon arrangement by means of a long rubber tube fixed to a trochar (see Fig. 37), or even a simple ex trochar may be employed for the purpose. The ordinary per needle is not recommended.

on. If a free opening is to be made, it will probably be o remove rather more than 1 inch of the fifth rib cartilage, s a small portion of the sternum. This depends upon the age, he size of the patient. It is convenient but not essential to rnal mam- els. After rough the s sterni, a k out for must be if it be should be ide. The displace- the pleura follow on nd chronic ses is quite e, one lung hing con- beyond the border of num. If is best to he opening pleura at e drainage uld reach ior part of The op- convenie- e through l or an cision. ricardium y be mis- empyema.

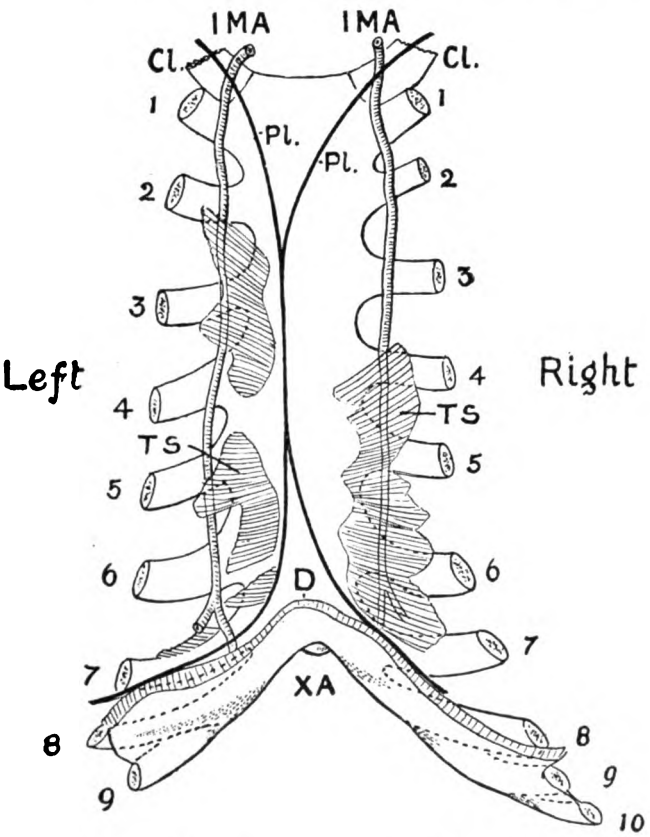

FIG. 55. PARTS IN CONTACT WITH THE STERNUM AND COSTAL CARTILAGES VIEWED FROM BEHIND. 1 to 10, Rib cartilages; CL., Clavicle; X.A., Xiphoid appendix; T.S., Triangularis sterni; D., Diaphragm; I.M.A., Internal mammary artery; PL., Pleura.

It may coexist either causally or accidentally y other conditions, such as subdiaphragmatic abscess, liver r empyema. If the association be with empyema, the peri- elling may well escape notice until it is felt by the finger into the pleura. Even then the condition has remained zed, the swelling being mistaken for a consolidated lobe of

the lung. If a correct diagnosis be made, the proper thing is to the pericardium through the pleura. Cases have been recorded in this course has been followed by cure. It must be remembered pyopericardium, like empyema, may burst into a bronchus.

CARDIOLYSIS

Cardiolysis is the name given to an operation first suggested Brauer in 1902 (*Archiv für klin. Chirurgie*, von Langenbeck p. 258), intended to counteract the mischief which results from a mediastino-pericarditis, that is, pericardial adhesions accompan adhesion of the pericardium to the chest-wall. The object is to the extra work entailed on the heart owing to its inability to retr rigid chest-walls, as it can the soft parts under normal conditions

It consists in the removal of 3 or 4 inches of the fourth and fi and rib cartilages, and, if necessary, also of portions of the thi sixth ribs or rib cartilages and a piece of the left border of the st

The operation is a simple one. A horseshoe-shaped flap of width, hinged upwards and with the inner side over the left border sternum, has been recommended. It should contain all the str superficial to the ribs. I think it would be better, as involvi injury to muscle, if the flap were hinged outwards; or if the skin were reflected in any direction preferred and the muscles subse turned outwards.

The ribs and cartilages are then removed with the superficial teum and perichondrium; but it is safest to strip these membrane the deep aspect of the ribs and cartilages before dividing them, as wise the pleura is likely to be opened, and this would, under cumstances, be an undesirable complication.

The object of removing as much of the periosteum as possib prevent the re-formation of the ribs and a consequent recurrence mischief. If there be time the attempt might be made carefully sect away the deep layer of the periosteum after the removal ribs; but it is not easy in so doing not to injure the pleura. No should be made to do this with the perichondrium, as it is no that either bone or cartilage would be formed from it if it were

The operation is completed by replacing and suturing the fla

It is thus seen that the name implies more than the operation as no attempt is usually made to deal with any adhesions excep of the pericardium to the chest-wall. To try to separate the in cardial adhesions would be dangerous and probably ineffectual, moreover unnecessary.

eedless removal of bone should be avoided, as it is not desirable
r the heart unnecessarily.
recovery a suitable shield or protection must be worn.

AL OF CLOTS FROM THE PULMONARY ARTERY

elenburg has shown (*Zentralblatt für Chirurgie*, January 25,
experiments on animals that an operation with this object can
sfully carried out, and at the meeting of the Deutsche Gesell-
r Chirurgie, 1908 (*Zentralblatt für Chirurgie*, No. 35, 1908),
rations on the human subject were reported, and though all
ally, one during the operation, one fifteen hours after the opera-
heart failure, and one thirty-seven hours after the operation
norrhage from the internal mammary artery, it is evident that
r is one for serious consideration. In support of this statement
burg points out that sudden death after the occurrence of the
is the exception, that at least half the cases survive for fifteen
and that some live for an hour.
commends in the later of the two publications the formation of
gular flaps (see Fig. 56) beneath the left clavicle by means of
ons: one carried vertically along the left border of the sternum
lower border of the first rib to the upper border of the third,
ond transversely along the second rib for 10–12 centimetres.
of the second rib about 10–12 centimetres long is then either
or divided at the outer part of the wound and raised and bent
o the right over the sternum. If more room be required, a
f the third rib must be taken away. The pleura is then opened,
ericardium is cautiously incised, after picking it up with two
forceps, to the inner side of the phrenic nerve, which must be
avoided. The incision must be enlarged upwards and back-
til the upper half of the pericardium is opened; the lower half
erfered with, and the heart itself is not displaced. The two
ericardium are then drawn apart against the sides of the wound
est-wall either with hooks or by means of sutures. The pul-
rtery and the aorta, which is closely adherent to it, are now
a hook-shaped (*hakenförmig*) olive-pointed sound of about
nd length of a middle-sized catheter is passed with a rotatory
t into the sinus pericardii transversus, behind both the aorta
onary artery, until its point appears near the edge of the
This, with proper management, is said to be an easy per-
The sinus readily admits the index-finger, which may be
to assist the passage of the sound if it does not pass easily.

The sound is then pressed somewhat forwards in order to draw th
sels forward and to steady them, and later on it is pressed more fo
forwards, while the artery is compressed against it by means
finger. The sound will lie opposite the pulmonary valves.

Before making pressure the visceral pericardium and the unde
fat should be stripped off the pulmonary artery with two pairs of fo
in order to ensure a good view of the spot (not too near the v

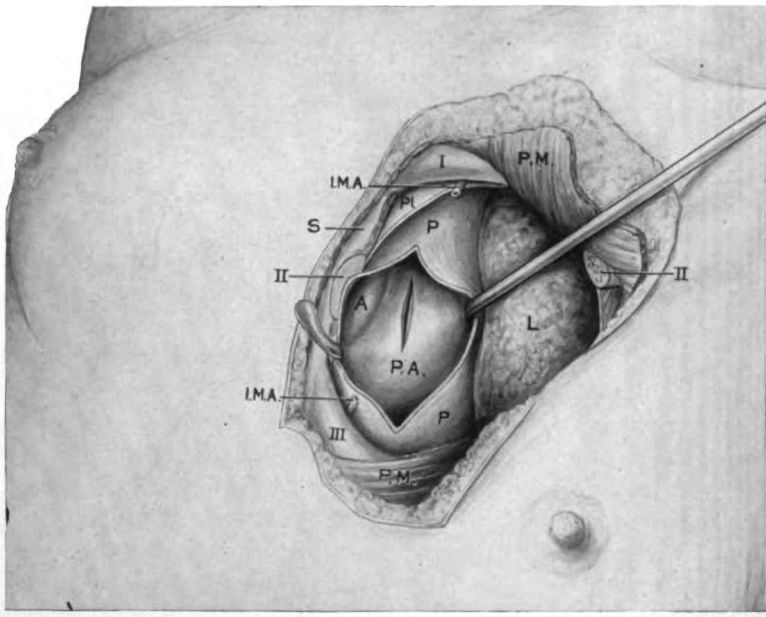

FIG. 56. DISSECTION TO EXPLAIN TRENDELENBURG'S OPERATION FOR
ING CLOTS FROM THE PULMONARY ARTERY. P.M., Pectoralis major; S., Ste
I, II, III, Rib cartilages (and divided second rib); I.M.A., Internal ma
artery; P., Pericardium; A., Aorta; P.A., Pulmonary artery; PL., Pleura; L.,

where the artery is to be incised and to facilitate the subsequent
tion of the sutures.

Compression is now made, the artery is incised, a pair of bent p
forceps is inserted and passed into the main trunks, or, if necessar
the branches of the vessel, and the clot, if it can be seized, is extr
The forceps may be introduced to a depth of 6 to 8 centimetres.
out loss of time the wound in the artery is closed by means of a
clamp placed parallel to the long axis of the artery, so that the ed
the wound project a few millimetres beyond its blades. The compr
finger is raised and the sound is removed; the blood flows again th

the pulmonary artery, and is prevented from escaping by the clamp. The stitches can now be introduced at leisure. The application of the clamp is facilitated by the use of a pair of weak-springed forceps with the points turned outwards into hooks. The forceps are introduced closed into the wound in the artery, the hooks catch under the two ends of the incision, stretch it, and pull the edges of the wound forwards into the grasp of the clamp.

A few stitches placed in the pericardium and the closure of the opening in the chest-wall complete the operation. Experience will show whether polypus forceps or some other instrument is more efficacious for removing the clots.

It is needless to say that such an operation is not likely to be available in many cases. It must in fact be almost necessarily confined to hospital practice, and indeed to the practice of hospitals possessing a resident surgeon of sufficient responsibility to entrust with such a serious diagnosis and operation. Experiments on animals showed that complete compression of the artery could only be maintained with safety from 45 seconds to 2 minutes. Trendelenburg considers 45 seconds sufficient time for two such 'simple proceedings as incising the artery and extracting the clots,' but he points out that, if more time is required, it may be obtained by temporarily clamping the wound in the artery. Fifteen minutes, he thinks, allows time enough for the completion of the operation in a hospital, or, at all events, for reaching the critical stage of it.

CHAPTER VII

OPERATIONS UPON THE DIAPHRAGM AND FOR S DIAPHRAGMATIC AND HEPATIC ABSCESS

REPAIR OF INJURIES OF THE DIAPHRAGM

THESE may result from simple compression of the body v external wound, or from penetrating wounds of the thorax or ab or conceivably from objects passed down the œsophagus. They ar accompanied by the formation of a diaphragmatic hernia in whicl portions of one or more viscera or large quantities of the abd viscera may find their way into one or other pleural cavity or i pericardium. The right half of the diaphragm has been ruptured often than the left. More or less definite and typical physical sig symptoms may result, but the nature of the injury may escape If the rent be small and occupied by a portion of intestine, stra tion with its characteristic symptoms may set in.

Indications. Healing has in some cases undoubtedly oc in others the aperture has remained permanently open, with cons inconvenience and perhaps risk to the patient. It is better, the to endeavour to close it.

Operation. If there be already an abdominal wound or a t wound the surgeon will probably be inclined to make use of it, en it if necessary for applying his sutures; but it is at least questi whether he should not always supplement an abdominal wound thoracic, or a thoracic by an abdominal wound. It appears to experience of those who have had such cases to deal with that sertion of the sutures is thereby much facilitated. In making th plementary thoracic wound some have simply made an opening t an intercostal space, but I should think it would generally be make a hinged flap of ribs and muscles of fair size, and at the the operation to secure it in position. The question of the proc of a pneumothorax does not enter into consideration; it must be produced, unless the rupture has taken place at a part where adhesions exist, in which case the diagnosis will probably not be and the thought of an operation will, therefore, not occur. Th tion of the openings will be determined by the seat of the ruptu

ases without external wound, if there be localizing signs point-
er side, the linea semilunaris of that side may be sutured; but,
no such signs, a median incision is to be recommended.

RATION FOR SUBDIAPHRAGMATIC ABSCESS

has been written upon this subject. It may even be feared
refinement of classification and description may lead to con-
thought and make the question appear more complicated than

general observations are called for before describing the com-
simple operative procedures that may be required.
agnosis is often difficult. If the abscess be small and situated
er part of the dome of the diaphragm, it may produce no per-
ysical signs. If it be nearer the origin of the muscle, a sub-
atic abscess is likely to be mistaken for some intrapleural
And even supposing there be no doubt of the situation of
, it is easy to mistake a new growth or an enlarged or displaced
an abscess. A recognition of these difficulties and of the fact
is often very harmful should prevent the surgeon from post-
investigations in cases of reasonable suspicion.
are certain anatomical structures which may limit the extent of
gmatic abscesses. They are the right and left lateral liga-
the falciform ligament of the liver, the small omentum, and
er of speaking, it may be said, the boundaries of the lesser sac
ntum. But besides these normal barriers, abscesses beneath the
, being always associated with peritonitis, are usually sur-
more or less firm peritoneal adhesions. It is in my experience
mon to find these adhesions limited by the margin of the
The practical bearing of this observation is that, supposing
f doubt—say, in one of an abscess resulting from the gradual
an ulcer on the anterior surface of the stomach near the
ature—it be found that adhesions exist as far as the costal
e safest plan is to close the laparotomy wound and to attack
s through the attachment of the diaphragm, but of course
limits of the pleura. A clear appreciation of these natural and
is limitations is of the utmost importance in the search for
ainage of subdiaphragmatic abscesses.
fficulties of diagnosis being recognized, it is essential to re-
at a subdiaphragmatic abscess may result from many different
l that the nature of the contents and the gravity of the case,
nger of delay in operating, are also subject to very considerable

variation. It must not be forgotten that, while strictly localized a are most commonly associated with diseases of the viscera whi contact with the under surface of the diaphragm, that is to stomach or duodenum, liver or kidneys, there is no abdomina disease of which may not give rise to one; and that general sep tonitis, if it does not prove rapidly fatal, is more often than not by more or less limited collections of pus round the back of on the right side or round the spleen on the left. It is quite c for example, if an inflamed appendix lies on the outer side of the for the resulting abscess to track up along the ascending colon a a collection far back between the liver and the diaphragm. known such an abscess burst into the lung. It should be a practice, therefore, if an appendix abscess occupies this situa explore its upper limits carefully and probably to drain it a counter-opening in the loin. I have seen recently an abscess the front of the liver and the diaphragm reaching up to the fo starting from a long gangrenous appendix that reached up bel ascending colon as far as the hepatic flexure. In cases of gener peritonitis it should also be as much a routine practice to expl sponge out both the post-hepatic and the splenic regions, as it vestigate the pelvis; and if some time after the primary opera case should not progress favourably, particular attention shoul voted to these regions; and should there be any suspicious symp signs, I would almost say even if they be not present, an exp which if it does no good is not likely to do harm is more than ju for during the period of doubt and delay the patient's strength ably being reduced by septic absorption and fever. I have know be continued until the shock produced by the operation, when it place, was too great for the patient's enfeebled powers of resist

It has been hinted that the pus from a subdiaphragmatic is at least as variable as the viscus from which it has originated while it may be simple odourless pus, it may be pus mixed with or intestinal contents, bile, urine, hydatid cysts, and so forth, o be the chocolate-coloured pus derived from an abscess of th But from the present point of view the important point to rem that these abscesses often contain gas. If this be the case, a in diagnosis may easily be made, and if it be discovered at th tion the suggestion is obvious that the abscess has originated i ture of one of the hollow viscera. This conclusion is, howe absolutely a certain one, as bacterium coli and other organisms m the development of gas. Such abscesses as these may reach an e size and hardly merit the name of subdiaphragmatic abscesses.

uptured duodenal ulcer result in an enormous cavity, yield-
itic resonance and a typical bell sound from the third rib on
ide to Poupart's ligament when the patient was recumbent.
nce and dullness of course change places on assuming a dif-
ure. It is to these abscesses that the rather ridiculous though
name of subdiaphragmatic pneumothorax has been applied.
ially, though not exclusively, in these cases that displace-
e heart (mediastinum) either laterally or vertically may take

tion. With regard to treatment there are certain main rules
dance. The objects are to open the abscess safely, to drain
, and, if it involves no extra risk to the patient, to deal at
me with the source of the mischief. It is useless to say that
ragmatic abscess should be opened behind close to the lower
the ribs, which is the most favourable position for drainage
ases, because a considerable number could not be safely
m this position. Each case must be considered from its own
nt of view. My meaning can be best illustrated by a few
nples.

g woman with signs suggesting left empyema, but a history
ulcer of the stomach, was explored with the aspirator through
ea in the back. Stinking pus was reached, but it was found
leura contained a small quantity of clear odourless fluid.
tory opening below the costal margin revealed the presence
ns between the liver and stomach and the stomach and
reaching as far as the costal margin. The opening was
losed and a spot was selected in the mid-axillary line below
limit of the pleura. Through this incision a portion of rib
ed; the origin of the diaphragm was then cut through and
assed through the adhesions along the anterior border of the
l the abscess was reached. This was a safe and successful
Any attempt to deal with the ulcer would have been useless
fiable. But supposing the first incision had led into adhesions,
ess itself and the ulcer had been on the lower instead of the
of the anterior surface of the stomach, it would have been
eal with them at once. Supposing, on the other hand, it had
that the front of the stomach was normal, it would probably
necessary to go further back and make a transpleural opera-
ving the rules laid down at p. 190.

with a ruptured duodenal ulcer—at all events this was the
-was the subject of such an enormous collection of pus and gas
nal contents as has been referred to at p. 186. On opening

it in front below the costal margin the posterior wall of the abs seen to consist of the intestines matted together by thick lymp simple insertion of a drainage tube was sufficient to cure this cas happened many years ago. At the present time, no doubt, at le incisions would be used, one in front, one below, and one behi the successful result in this case should remind us that it is not to disturb the adherent viscera in order to make a stab woun loin, though no doubt it is a good thing to make one if possib fact that no attempt was made to deal with the duodenal ulcer i importance. I am confident that any thought of a gastro-ent should in such cases be postponed till after convalescence.

A young woman, previously in perfect health, suddenly bega hydatid cysts from the bowel, and later on to expectorate stin containing similar material. An exploratory laparotomy sho the parent cyst was at the upper part of the right lobe and c firmly adherent. The laparotomy wound was closed and a transpleural opening was made into the abscess, which ultimate after a secondary pulmonary abscess had been opened. Suppo parent cyst had been low down on the anterior surface of the would have been necessary to fix it to the margins of the lap wound and drain it in that way. I have not referred to the att of the colon to the under surface of the liver, which in this cas it would have been perilous to disturb.

The liver of a man with a tropical hepatic abscess reached b umbilicus; but on opening the abscess in what I consider the mos able position (see p. 190) it was found that three pints of present between the diaphragm and the liver, which indeed materially enlarged. A careful search was made with the fing probe over the upper surface of the organ, but the opening original abscess could not be found. So no more was done and was rapid. If the opening had been met with, it would h enlarged and the tube would have been passed into it; but know quickly some hepatic abscesses shrink, it would, I think, have practice to explore the liver further at the time.

The risks involved in delay may be illustrated by the case o who had a right anterior subdiaphragmatic abscess, as well a peritonitis resulting from a long gangrenous appendix which la the ascending colon. The operation consisted in removing the a which involved pulling almost all the small intestines out of incision in the right linea semilunaris. The abscess was then through a stab wound in the loin and a tube was left in the lo of the anterior incision. After some days of favourable pro

e became hectic and indefinite physical signs appeared at the These were watched from day to day, and at last a copious on of stinking pus occurred which put the patient's life in rdy. I think the right practice would have been to make tory incision far back on the left side as soon as suspicion l as to the existence of what is a common sequence of general onitis. It is at least possible that the damaged lung will equire surgical treatment.

up, it is advisable in a case of subdiaphragmatic abscess to and if possible to avoid breaking down the adhesions that from the general peritoneal cavity. It is best to make the hind; but this is not essential, and it must not be forgotten the after-treatment it is not essential to keep the patient on his that by sitting him up or otherwise changing his position ake even an anterior opening the most dependent possible. the primary cause of the mischief be not dealt with at the often heal spontaneously, and in most cases is most safely at a subsequent period.

PERATION FOR ABSCESS OF THE LIVER

tions. Multiple abscesses and pylephlebitis and some other bscesses are unsuited for operation; but if it be decided to e methods of procedure are the same whatever may be the he abscess. One point must, however, be dwelt upon, *viz.* e may occur into any of the viscera or the spaces or cavities n near relation to the liver, *e.g.* the peritoneum, forming either subdiaphragmatic abscess (right or left), or into the general the peritoneum, or into the stomach, duodenum, colon or into the pleura (right or left) or the pericardium, the lung left), or the mediastinum. Although many cases have re- thout operation which have thus ruptured into lung, stomach, t is bad practice to wait for such an event, the serious com- which may occur far outweighing the slight and problematical of a spontaneous cure. Should rupture into lung, stomach, ave occurred, it is right to wait a few days, but not longer, in e whether the exit for the pus seems to be sufficient; but, if ms do not rapidly subside, an external opening should be ithout delay.

tion. Sometimes the pointing of the abscess determines which the external opening is to be made, and in this case othing more to be said about the operation except that the

abscess must be opened, and the further remark which applies t
incisions into liver abscesses, *viz.* that the finger should be ir
and pockets and imperfectly opened diverticula should be expl
freely opened. The very thick pus usually met with demand
large drainage tube.

If there be no sign of pointing, the seat of election for the in
in my opinion, at the side, midway between two lines prolongi
wards the anterior and posterior folds of the axilla, and this is
for making the exploratory punctures with pretty large aspirato
6 inches long, which, if the pus be not hit off at first, must
passed in all safe directions, the surgeon being guided by his a
knowledge. This position is selected because in this situation th
possible opening can be made which does not involve interfer
the pleura. The higher the opening, the better the drainag
liver always contracts upwards in the course of cicatrization.
situation the interval between the margin of the ribs and the low
of the pleura is, as a rule, at least 2 inches. A transverse
about 2 inches from the costal margin is made on to the subj
a portion of which, 2 inches long, is then cleared from the p
and removed at the anterior part, the section probably passing
the cartilage. If the pleura be seen it is turned upwards out of
The diaphragm is then divided vertically, *i.e.* in the directi
fibres, and the liver is exposed. If adhesions be present it only
to open the abscess, which may conveniently be done by means
ing forceps instead of a knife, especially if the pus be far
surface. If bleeding be, as is sometimes the case, severe, the
a plug should be kept for a minute or two in the wound, aft
time it will probably cease.

If there be no adhesions two courses are open to the
one the difficult one of stitching the liver to the diaphragm,
other the simple one of packing off the peritoneal cavity with
or antiseptic gauze before making the incision. I used for
practise the former method, but in recent years have adopted t
which appears to afford a satisfactory protection against p
It is of course not possible to be sure that the pus will no
virulent septic organisms, but this is not usually the case.

Sometimes the abscess is at the back and can only be reac
factorily by a posterior incision. In this case the operation r
through the pleura. I have read accounts of cases where no
taken to occlude this opening in the pleura and where no ha
of it; but I have myself seen most disastrous results. I ther
strongly of opinion that the pleural opening should be close

e abscess. This may be done by making a rather free trans-
ion into the diaphragm and by passing a strong catgut con-
itch right through its substance and through the structures
the intercostal space, *viz.* the intercostal muscles and pleura.
o possess the means of operating with the 'Überdruck or
k' apparatus (see p. 129) would no doubt find the operation
lified by the avoidance of pneumothorax. No special instruc-
equired for the treatment of abscesses of the left lobe, except
inary exploration with an aspirator needle is not admissible
rts of the liver.

s the most important point to bear in mind in treating abscess
r is to have sufficiently large and long tubes at first, not to
em too soon or to remove them until the discharge is prac-
I believe many cases in which a second abscess is supposed
n opened are really examples of refilling of the original abscess
ne rapid shortenings and removal of the tubes.

methods of opening and draining the abscesses of the liver
devised and are highly spoken of. One of the best is that sug-
Sir Patrick Manson. After puncturing the skin a large trocar
is thrust through all intervening structures into the abscess.
drawing the trocar a drainage tube of considerable size,
ghtly stretched on a strong probe, is then passed through the
the abscess; the canula is then withdrawn and the probe
The tube then becomes shorter but of wider bore, and tightly
ck made by the canula and trocar. In this way it is stated
k of extravasation of pus into the pleura or peritoneum is
avoided. It must be owned that the device is simple and
and the objections that the tube can only be of a moderate
is impossible to explore and break down septa in the cavity,
has been called a somewhat unsurgical procedure may be
ent than real.

hers, I have met with many cases in which the symptoms
ared to point almost unmistakably to abscess of the liver,
ch recovery has taken place after exploratory puncture. This
t be a result and not a coincidence, has been supposed to
on local phlebotomy of the organ. In this connexion refer-
be made to the remarkable results obtained by Leonard Rogers
Medical Gazette, April, 1908, and preceding numbers) from
stration of large doses of ipecacuanha in the pre-abscess
senteric (amœbic?) hepatitis, and to observe that, as far as
are concerned, it is impossible to say when this stage is passed.
destly says that this is only the revival of an old treatment.

He also has employed 'aspiration and injection of quinine to amœbæ without drainage (which has proved a rapid means o some cases of small deep-seated abscess which are most difficul and drain).' I have had no opportunity of trying this method ment with quinine, but I have seen the internal administr ipecacuanha rapidly change the appearance of a sloughing abscess. I have tried the local application of ipecacuanha wit apparent result, and am therefore rather surprised to hear injection of quinine is sufficient in destroying the amœbæ, se they must exist in the liver outside the abscess cavity, where the not possibly reach them. After perusing Rogers's observations certainly combine the two treatments, or at all events should r the quinine without at the same time administering the ipecacu

SECTION III

OPHTHALMIC OPERATIONS

BY

M. S. MAYOU, F.R.C.S. (Eng.)

Surgeon, Central London Ophthalmic Hospital;
Ophthalmic Surgeon, Bolingbroke Hospital

CHAPTER I

GENERAL CONSIDERATIONS APPLICABLE TO OPERATIONS UPON THE EYE

RATIONS upon the eye differ so widely from general surgical
ns that it is necessary to say something of the preparations for
fore passing on to their actual performance. Although not
ple in themselves, they require great accuracy and presence of
ght mistakes, such as too small an incision, may cost the patient
which sometimes may be almost more important than life itself.
intra-ocular operations are performed without general anæs-
t is therefore important that the patient should be given con-
y talking to him during the operation, so that he may follow the
ons of the surgeon during its performance; loss of self-control
art of the patient, movement of the head, screwing up of the
., may lead to disastrous results, however well performed the
n itself may be.

GENERAL PRELIMINARIES TO AN OPERATION

of the utmost importance for the success of intra-ocular opera-
pecially in old people, that they should be thoroughly examined
nd. One of the chief dangers of cataract extraction is irido-
which is frequently brought on by auto-infection as the result of
l toxæmia. As a routine the teeth should always be removed if
a alveolaris is present. Examination of the urine for indican
lso be undertaken. Examination of the urine is also important in
cataract, as not infrequently this disease is associated with
and it is often advisable to treat the general condition before
n.

bowels should be opened by an aperient the night before the
n, as it is desirable to keep them confined for the first two days
ds, so as to avoid straining. During the first week after a major
n, when the patient is confined to bed, they should be evacuated
pine position.

best time for operating, if possible, is the morning, as the patient
a night's rest and is less likely to lose self-control. Usually there
ain after the cocaine has gone off, and the patient is better able
it during the daytime. In old people the spring or autumn is

the best time for operating, as they are then less liable to suffer chest mischief as the result of confinement to bed.

Anæsthetics. *General* anæsthesia should be induced in all p with congested eyes, in small children, patients who are deaf, and who show a want of self-control. Chloroform should be used

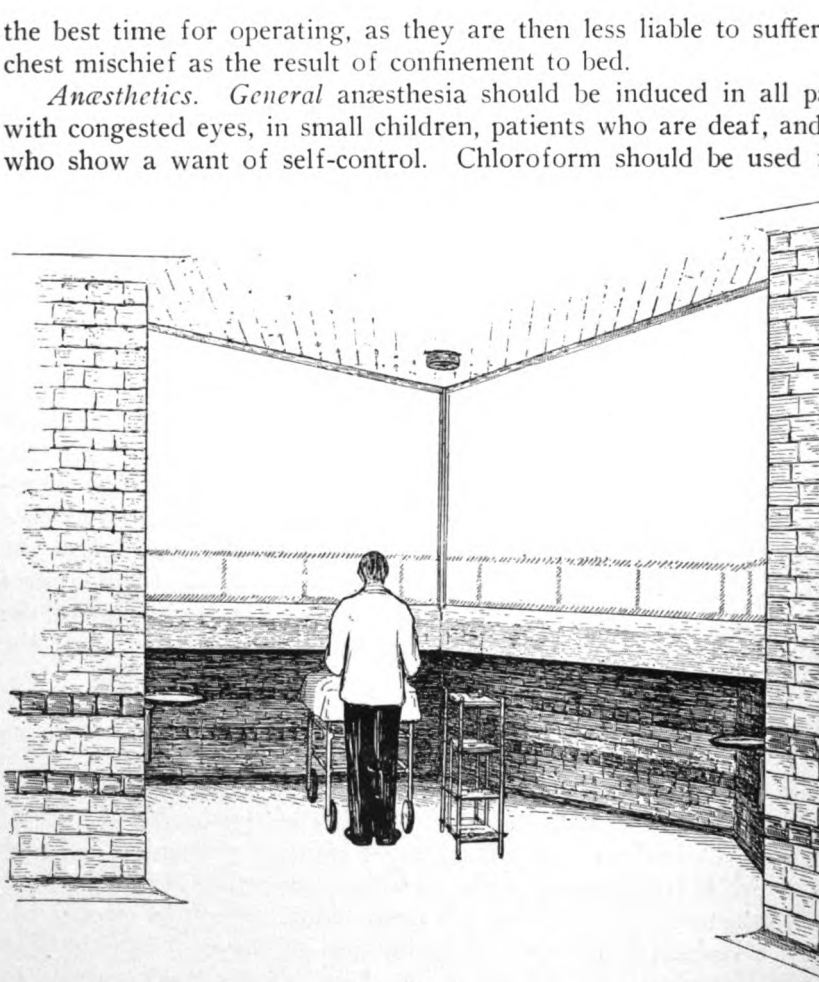

FIG. 57. WINDOW OF THE OPERATING THEATRE, KING'S COLLEGE HO The windows are fitted with outside blinds so that either can be used sep or the surgeon may stand in the angle and operate with his back to th A recess beneath the window allows the patient's face to be brought clos light on dark days. The ceiling should be blackened so as to avoid reflection.

intra-ocular operations, and should be given to the full surgical It should be given on a towel or an inverted mask specially ma the purpose, a Junker's inhaler being used during the time the operation is being performed. As the surgeon usually stands head of the patient, the anæsthetist should stand on the side away the eye being operated on. The local use of cocaine in addition to

ı is indicated when operating on patients to whom it is ad-
give as little anæsthetic as possible.
anæsthesia is obtained by the use of a 4% solution of cocaine
our or five times before the operation at intervals of three
a drop of the solution should also be instilled into the eye

Fig. 58. A Nernst Projection Lamp.

not being operated on, to prevent an accidental reflex stimulation
njunctiva and screwing up of the eyes. Adrenalin (1–1,000)
ısed in conjunction with the cocaine; it is especially useful in
erations, as it lessens the hæmorrhage. For hypodermic in-
novocaine and adrenalin are the most satisfactory. Under
circumstances the only pain felt during an intra-ocular opera-
uring removal of the iris; this is obviated to a great extent by

instilling the cocaine at least 15 minutes before the operation formed, so as to allow time for its diffusion into the anterior c The patient should be warned when to expect the pain, so that he move; his self-control may be tested beforehand by pricking t with a pin.

The theatre. The theatre should possess, as far as possible modern improvements found in an up-to-date general surgical o room. The light should proceed from a single large window, v possible, should face the north. *The window* should consist of pane of glass or of two panes forming the angle of the theatre; i begin about 5 feet from the floor and should extend to the (Fig. 57). The advantage of an angular window is that it all operator to stand with his back to the light in the angle, and so onlookers to see. No top light should be allowed, as it produces a reflection which may prevent the operator from seeing the pos his knife in the anterior chamber. Beneath the window there sh a recess for the end of the operating table, so that the patient's be brought close to the window if necessary (Fig. 57). This formed by building the main wall of the theatre further out t window, which has to be supported by a transverse girder.

The window should be fitted with outside blinds so that the can be easily darkened for the operations, such as capsulotomy require the use of artificial light. The best artificial light is a projection lamp fitted to a standard, which is fixed to a solid base which stands on the floor of the operating theatre. Faili a single powerful lamp with a ground-glass globe, placed in fron patient, will serve, the rays of light being brought to a focus on by means of a large convex lens of about + 10 D.

For *squint operations* it is desirable to have a light fixed to the directly over the head of the operating table, for testing the of the eyes either by the reflection of the light from the surfac cornea or by the Maddox rod test.

The operating table should be provided with a means of a its height and the position of the head-piece, so that the patien can be brought to about the level of the operator's elbows when th is standing upright with his arms at his side.

After operation the patient should be warned to lie still and strain in any way; he should be carried to bed and should lie back if possible. If a patient cannot sleep on his back it is bet he should lie on the sound side than be without rest. A length o age should be fastened round the wrists of each hand which is behind the back, so as to prevent the hand being put up to the eye

After major operations, such as those for cataract, the patient ed to bed for one week, during the first four days of which the uld not be raised from the pillow; but old patients with a tend- bronchitis or hypostatic pneumonia must be propped up in bed ved to get up earlier: in these patients it is better to perform the in the summer if possible. In old people and patients with a to melancholia the mental condition must be carefully watched, ently they cannot stand the confinement to bed and darkness. operations both eyes should be tied up for at least a week and simultaneously liberated.

LOCAL PREPARATION OF THE PATIENT

operating upon the eye, a surgeon has to face the great diffi- he is operating in an area which is not always aseptic, since it ally impossible to render the conjunctival sac sterile. At the e, the conjunctiva has been shown to be sterile in health in ses, pyogenic organisms (principally the staphylococcus albus) nd only in 15%; but, although these are usually not of a very character, they are by far the most frequent cause of sepsis; of suppuration after operation which the author has examined due to this organism. After the methods of purification given is percentage is considerably reduced, so that, if due pre- are taken, the risk of sepsis is comparatively small. On the d, if conjunctivitis or lacrimal obstruction be present, the risks mously increased, especially in the latter condition owing to ent presence of the pneumococcus in the discharge, unless recautions are taken. It is, therefore, of the utmost impor- t every case should be examined for lacrimal obstruction before . Care should be taken also to see that there is no purulent from the nose or any septic sores about the face, or pyorrhœa present.

s after intra-ocular operations manifests itself in one of two ither by suppuration, which usually ends in a rapid and com- truction of the eye (panophthalmitis), or more rarely in less cases by recurrent attacks of hypopyon associated with acute itis; or by a plastic irido-cyclitis, which may lead to slow dis- ion of the eye, with always the possibility of destruction of the by sympathetic cyclitis (sympathetic ophthalmia). Although ditions are comparatively rare, owing to the improvement in septic and antiseptic methods, every surgeon of experience will these disastrous complications. Immunization with vaccine carried out before major intra-ocular operations are performed

in cases where it is doubtful whether the conjunctiva can be moderately aseptic. In all cases of cataract extraction a care teriological examination by smear preparations and cultures s made.

The methods of purifying the eye before operation. Four n fore the operation the eye should be bandaged, and examine morning for conjunctival discharge. If this be absent, cultivation be made from the conjunctival sac, and if any organism more than a staphylococcus albus be found the operation should be p until the conjunctival condition has improved. The conjunc three days prior to the operation should be washed out six tim twenty-four hours with boric lotion or 1–6,000 perchloride of It will then be found practically sterile. In needling operations,



FIG. 59. LANG'S EYE SPECULUM. Designed to hold the lashes from the field of operation.

of entry of the needle through the conjunctiva should be touc a probe which has been dipped in 'pure carbolic,' so as to ens no organisms are carried in with the needle. In the event of being extremely urgent, the conjunctiva should be swabbed o nitrate of silver (10 gr. to the oz.) immediately before the op some surgeons prefer 1–2,000 perchloride of mercury. If obstruction be present, the sac should be thoroughly washed boric lotion and protargol (10%) injected. The canaliculi may porarily occluded by ligature. If the lashes be very long they s cut short. Epilation is performed by some Continental surge is not practised in this country. Various forms of specula are keep the lashes out of the field of operation; of these, a mod of Lang's is perhaps the best (Fig. 59).

An hour previous to the operation the lids should be th cleansed with soap and water, followed by 1–2,000 solution of per

ry, special attention being paid to the lid margins and lashes. unctival sac should be washed out with boric lotion and a pad e gauze applied over the closed lid.

AL CONSIDERATIONS AS TO MAKING AND HEALING OF WOUNDS IN THE GLOBE

already been pointed out that the great danger in intra-ocular s is sepsis. It is the aim and object of every ophthalmic sur- nake such wounds into the globe as will apidly shut off from the conjunctival ay in the healing tends to the forma- fistulous opening into the globe. This in the continuity of the globe may lead ectly on to the surface or beneath the va, subsequent inflammation in which ad to the interior of the eye.

FIG. 60. UNDINE FOR WASHING OUT THE CONJUNCTIVAL SAC.

ne and other solutions used at the time quently to operation should be sterilized. e this, the solutions should either be mediately before use, or put up in drop- ade in one piece with a long tapering ich is sealed off, and can be broken ely before use. These bottles can be n aseptic solution so as not to soil the hands of the surgeon.

ands of the surgeon are purified. Thin rubber gloves should be ere sutures are to be tied, as in an advancement. Sterilized nd a mouth mask should be worn. The latter is important, rgeon should talk to the patient to give him confidence during tion. After the dressings have been removed, the patient's the area surrounding the operation are covered with sterilized In operations such as advancement, where sutures are used, it le that the face should be covered with sterile muslin, with a n it for the eye, so as to prevent the sutures being contaminated skin of the face. The eyelids are again washed in 1–2,000 le of mercury lotion, and the conjunctival sac is washed out with tream of boric lotion or normal saline by means of a sterilized or an undine (Fig. 60), which has been kept in a bowl of lotion.

ments. Non-cutting instruments are boiled for 15 minutes in ater, placed in a tray without lotion or on sterile lint, as this nfection from the surgeon's hands due to the lotion running on to the instrument. Failing distilled water, a small quantity nay be added to the water used for boiling, but this has the

disadvantage that a deposit is liable to form on the instrumer may be obviated to a certain extent by not placing them in th until it is boiling. Cutting instruments should be sterilized b them in liquefied carbolic acid (crystals dissolved by heating of water) for half a minute immediately prior to use and absolute alcohol to remove the acid; they are then placed in The greatest care should be taken to see that cutting instrun needles do not touch the side of the dish. The edges and poir always be carefully tested immediately before sterilization o

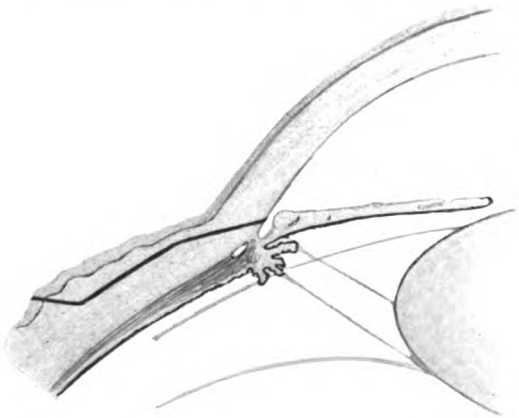

FIG. 61. CATARACT EXTRACTION. The drawing shows the line of incision. Note the conjunctival flap.

covered with fin cially made for pose. The poin pass through the the weight of t ment held flat or palm; the cutt should also b Scissors are best cutting wet cig per, special ca taken to see that are good near t Immediately aft tion the in should be boi dried whilst hot to prevent rust.

The direction of an incision into the globe should be as obl consistent with the object of the operation, so as to allow large surfaces to come into apposition. With this object in view it is that a conjunctival flap should be formed to all wounds wher sible (Fig. 61). Further, owing to the extreme vascularity of junctiva, as has been shown elsewhere,[1] wounds in it become firm after 48 hours. As a rule sutures are best avoided and ar required.

Position of the incisions. Corneal incisions are to be av possible, for the following reasons: firstly, the cornea being f blood-vessels heals comparatively slowly; secondly, the wound to become fistulous owing to the rapidity with which the e grows down the side of the wound. On the other hand, incision from 3 to 6 millimetres behind the limbus are liable to injure t

[1] Mayou, *Hunterian Lectures,* 1905.

in addition to irido-cyclitis being set up by the trauma, the ry body will pro- the wound and e union of its n the result that spread into the g the prolapsed the uveal tract an irido-cyclitis not only ruin the d, but may also ympathetic irido- the other eye

e of election of an nto the anterior globe is therefore nillimetre behind that is to say, as rnea as is consist- obtaining a good l flap to cover the the globe (Fig. n possible it is ad- make all incisions ard direction for ng reasons: They easily performed; nities, such as an are hidden by lid; more perfect btained, as the ot exposed in the perture, the eye ed upwards when closed. Further, portion of the l sac is more n the lower. mediate danger of of a knife into the anterior chamber of the eye is the wound- lens. To avoid this the point of the knife should be always

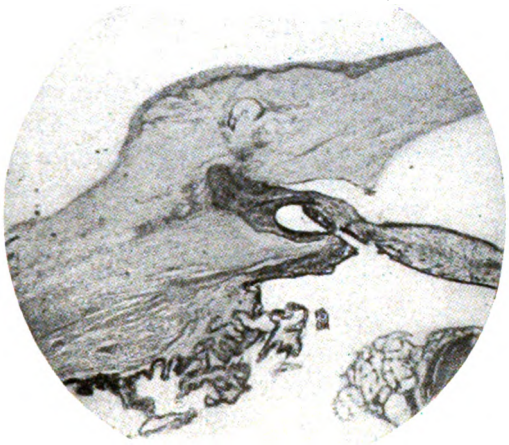

FIG. 62. SYMPATHETIC OPHTHALMIA. The exciting eye of a case following cataract extraction. The section shows the incarceration of the iris in the wound.

FIG. 63. CYSTOID SCAR AFTER IRIDECTOMY FOR GLAUCOMA.

kept superficial to the iris if a clear lens be present in the ey operation the chief danger is prolapse of the iris into the wou is best avoided at the time of operation by carefully replacin with the spatula at the end of the operation, but unfortunately not infrequently occurs during the first few days owing to the re lation of the aqueous in the anterior chamber and its sudd through the imperfectly healed wound, as the result of strain some movement on the part of the patient; the iris may be ca the wound with the escaping aqueous, and a fistulous opening may form subsequently (Fig. 63).

The less manipulation used consistent with the object of t

FIG. 64. AN EYE BANDAGE. The first turn, A, encircles the head and is fixed with a pin. This portion of the bandage can be put on before the operation and obviates movement of the head. The turn B is then brought up below the ear and fixed with pins.

FIG. 65. A PRESSURE BAN first turn of a 1½-inch band cles the head. It is then carri the ear and over the head in a eight. The final turn goes head and is fixed by a pin at of crossing of the previous tu

tion the less likelihood is there of cyclitis following it. All ins should be held lightly in the fingers, which should be as far a responsible for the fine manipulation required. The part of not actually holding the instrument should be steadied on before the instrument is brought in contact with the eye.

When more than one operation has to be performed on eye it is desirable that all ciliary injection after the first operati have disappeared before the second is undertaken.

Dressings. A pad of sterilized wool or gamgee next the cl lid, held in position by a bandage, is all that is necessary.

Bandaging. The bandage is started on the forehead over th

eye and is carried in a direction away from the eye to be covered. A complete turn is made to encircle the head and is fixed with a pin. The bandage is then brought up beneath the ear and over the eye and fixed with pins on the forehead (Fig. 64). When absolute rest is desired, it is necessary to bandage both eyes. After intra-ocular operations this is desirable for the first three days. When pressure is desired, a figure-of-eight bandage should be used (Fig. 65). A useful bandage (Moorfields bandage) for occlusion of both eyes is made from stockinette, which fits closely over the eyes and nose and is fastened with tapes.

The dressings should not be disturbed for at least 24 hours. The lids are then cleansed with 1–6,000 perchloride of mercury lotion, and the lower one is pulled down so as to allow the escape of tears and to see if any discharge be present. The upper lid should not be touched. If no discharge be present the eye is re-dressed. If discharge be present the conjunctival sac should be washed out carefully with boric lotion. Most wounds with conjunctival flaps are shut off in 48 hours, after which time it is advisable to wash out the conjunctival sac twice a day with boric lotion. Great care should be taken to see that no undue pressure is made on the globe. The patient should be warned not to screw up the eyes or strain whilst the dressing is being performed.

CHAPTER II

OPERATIONS UPON THE LENS

Surgical anatomy. The lens consists of fibres whic veloped from cells originating in an inclusion of the fœtal A normal lens is surrounded by a capsule, the anterior half o lined with a single layer of epithelial cells on its inner surface. life the cells which line the posterior half of the capsule go tc lens fibres, so that after birth the lens capsule is lined by cells anterior surface. The lens capsule, which is deposited from th cells lining it, consists of a highly elastic membrane; small its continuity, therefore, gape widely. Throughout life the

FIG. 66. A LENS THREE WEEKS AFTER NEEDLING. The section shows the swelling and breaking up of the lens in the anterior chamber. The iris has become adherent to the needle puncture.

the capsule c become new l but at the sam bulk of the len increase marke is due to the fa lens fibres bec closely packed and lose som watery c (sclerosis). central part of the first to un process, with that a definite hard nucleus is found in the lenses of people age of thirty to thirty-five and upwards.

Chemically the lens fibres are composed of crystallin, which allied to a serum globulin and is therefore soluble in salt solutio the lens capsule has been opened, by operation or accident, aqueous is admitted to the lens, which becomes opaque, swel is gradually absorbed (Fig. 66). In those under the age of thi fore, a simple incision into the capsule is all that is required it to be absorbed. But, as has already been pointed out develops a hard nucleus after that age and will not then be

rily by simply opening its capsule; to remove it, as is done cataract, the hard nucleus must be extracted from the eye.
ens is held in position by the suspensory ligament, which con- nterlacing fibres attached on the one hand to the ciliary process

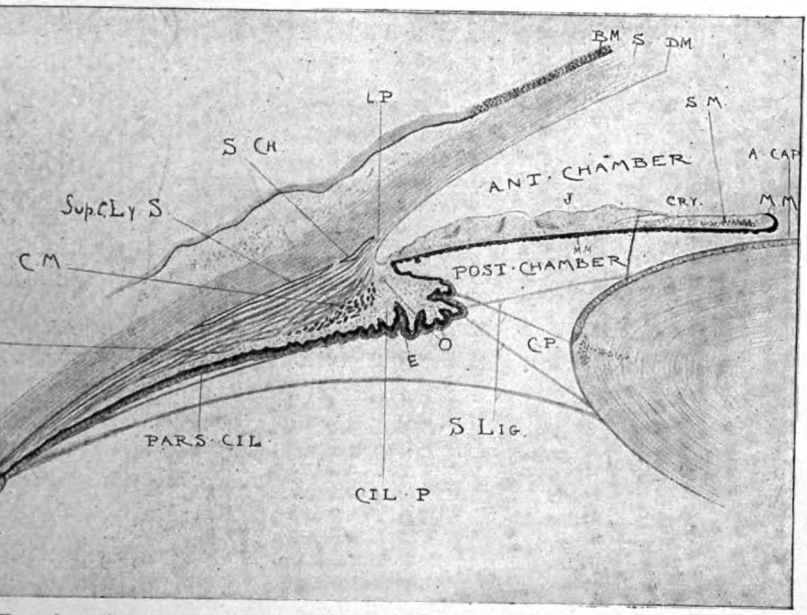

FIG. 67. ANATOMY OF THE ANTERIOR SEGMENT OF THE EYE.

Ciliary process. S. CH. Venous sinus of the sclera.
Lig. pectinatum, between the fibres of which are the spaces of the ne iris.
. LY. S. Suprachorioidal lymph-space which extends backwards be- chorioid and sclera.
idional portion } of the ciliary muscle.
ircular portion }
ulus arteriosus. S. LIG. Suspensory ligament of the lens.
helium covering the ciliary process.
IL. Pars ciliaris retinæ. Pars plana of the ciliary body.
retina. } The junction of these with the pars plana is known as the
chorioid. } ora serrata.
S.M. Sphincter muscle. CRY. Crypt.
nent epithelium. S. Cornea. Substantia propria.
rior elastic lamina of the cornea. D.M. Posterior elastic lamina.
nterior capsule of the lens. C.P. Spatia zonularia (Canal of Petit).

e other to the capsule at the lenticular margins (Fig. 67). Pro- the vitreous after cataract extraction is prevented by the in- this ligament and the posterior capsule of the lens, together

with the hyaloid membrane of the vitreous. The tension on t
of the suspensory ligament, in addition to keeping the lens in
also exercises traction on the lens capsule. In dislocated len
is a gap in the suspensory ligament either as the result of inju
congenital malformation; when such cases require operation
some difficulty in producing a sufficient gap in the capsule to
their absorption, owing to the mobility of the lens and the
traction on the incision in the capsule.

DISCISSION OR NEEDLING

Discission of the lens has for its object the tearing open of the
capsule, so that the lens substance may be broken up and abso

Indications. This operation will be required:

(i) **For cataract in patients under the age of about thir**
forms of cataract for which these operations are usually perfo
(i) *complete congenital cataract*, in which the whole lens is op
consists of little more than a shrunken capsule which may ha
extracted if discission is unsuccessful; (ii) *lamellar cataract*, of
density to interfere seriously with vision; (iii) *posterior polar*
in rare instances; (iv) *traumatic cataract*, to complete the al
of the lens by breaking up its fibres.

Before operating on any form of cataract the following fa
be ascertained as far as possible:

(*a*) *Vision.* It must be remembered that in children a
eye, retaining the power of accommodation, is often more usefu
eye which sees better but has to wear different glasses for
distances. Vision must be reduced to less than $\frac{6}{18}$ in both e
correction with glasses before the operation should be underta
rare cases, in children, and in traumatic cataract where the
is very dense and confined to one eye, it may be removed
improve the personal appearance and partly to enable the patie
large objects.

An eye without a lens (aphakia) will not work with an ey
lens even if the former be corrected with glasses.

If the patient be unable to see letters, he should have a re
quick perception of light, no cataract, however dense, being
to prevent this.

(*b*) A patient should have a good *projection of light;* that
he should be able to locate the light when thrown into the ey
mirror whatever direction it comes from. Children generally

ds the light, provided that they can see it and that the eye is ve from other causes.

ote whether *the pupils* are equal and active. In children most rmation can often be obtained as to the condition of the means of the pupil, which often will not react when the pa- ble to appreciate light.

e condition of the fundus of the other eye, if observable, aken into account, as many diseases of the fundus, such as and myopia, are bilateral, and would influence the prognosis y.

e lacrimal sac and conjunctiva should be free from all signs ation.

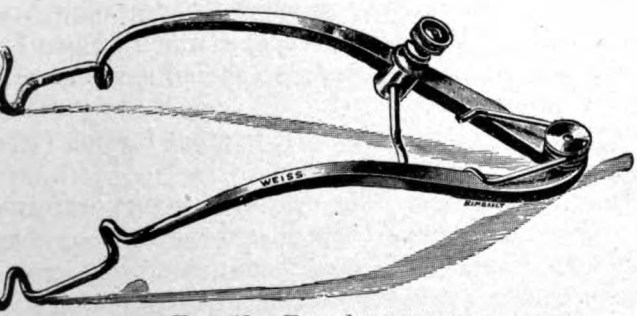

FIG. 68. EYE SPECULUM.



FIG. 69. FIXATION FORCEPS.

or the removal of a lens for high myopia. In selected cases, gives very satisfactory results with great improvement of leed, full normal distance vision has been obtained without The operation, however, is only justifiable under certain cir- s, the chief of which are:

he amount of myopia should exceed 18 D.

istance vision should be defective—less than $\frac{6}{18}$ with glasses.

phthalmoscopically the macular region should be sound.

inocular vision should be absent.

he patients should be children or young adults.

there is some serious reason why the patient is unable to wear glasses.

netropia, if the lens be removed, a glass of + 11 D. has to be

placed before the eye for distance vision and + 14 D. for ne
It is impossible to predict the exact amount of correction c
which will be produced by the removal of the lens, owing to the
inability to estimate the refractive power of the lens associate
distortion of the posterior pole of the globe. Usually a pa
about 22 D. of myopia is rendered emmetropic by the operatic

There are two main objections which have been raised to
tion: first, that there is a slight risk of septic infection, sy
ophthalmia even having been known to occur; secondly, th
detachment seems rather more common after operation than in
myopia of the same degree. As a rule it is only advisable t
the operation on one eye, the patient using the other for reading
but under certain circumstances, as when the operation has
cessful for a considerable period of time, it would be justifiab
form it on the other eye. The operation should never be perf
patients having only one eye.

Instruments. Speculum (Fig. 68), fixation forceps (Fig.
cission needle.

Operation. *First step.* The operation is best performe
ficial light. The pupil having been dilated with atropine an
anæsthetized with cocaine (a general anæsthetic being necess
ever, for young children), the speculum is inserted by first d
the upper lid, making the patient look down, and insertin
blade, and then drawing down the lower lid, making the pa
up, and inserting the lower blade. The speculum is opened
width without undue strain on the canthus and is kept in p
tightening the screw. The eye is steadied by fixation forceps h
left hand, which grasp the conjunctiva as close to the cornea a
directly opposite to the spot at which the puncture is to be
puncture is made directly behind the limbus and the needle
into the anterior chamber.

Second step. Using the shaft of the needle lying in the co
fulcrum on which to rotate the needle, an incision is made in th
capsule of the lens, and the lens fibres are broken up by a stirr
ment. The needle is then rapidly withdrawn in the same plane
it was inserted so as to avoid making a cruciform incision in t
with the spear-like end and thereby losing the aqueous. The
to make sure of this is to mark one side of the handle so th
be inserted and withdrawn in the same position. A pad and
are then applied.

After-treatment. The pupil should be kept dilated sub
by the use of atropine twice a day until the lens has become

age may be removed about the fourth day and dark glasses

ffect of the operation on the lens varies considerably. It may so rapidly that the tension of the eye becomes increased, in **se an** evacuation may have to be performed; in other cases, **in** the case of a patient with high myopia, several needlings **equire**d before absorption is complete.

CAPSULOTOMY

lotomy is the division of the opaque capsular membrane left **taract** has been removed.

cations. After a cataract has been removed, either by dis- extraction, an opaque membrane is usually left. This is e proliferation of the cells in the anterior capsule of the lens **empt**ing to lay lens fibres. Al- the posterior s clear and free s, those from the capsule may it and so render e. A fibrinous may also organ- help to thicken **brane** (Fig. 70). **se** reasons and

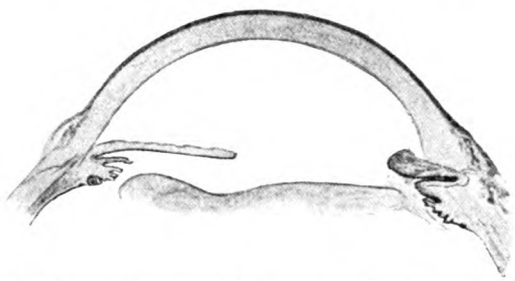

FIG. 70. SECONDARY CATARACT. Opaque capsule after cataract extraction.

use the soft matter may not have absorbed entirely, it is not to operate too soon after a cataract has been removed. There at least six weeks' interval after an extraction has been per- A few surgeons operate earlier than this, the idea being that **brane** is then softer and more easily divided.

ugh the operation of discission for after-cataract (capsulot- **imple**, it is not to be undertaken lightly. The patient's vision less than $\frac{6}{18}$. In former days the operation was looked upon **ed** with as much risk as the extraction, owing to the frequency **ch** it was followed by inflammation. The reasons for this **have** been want of proper antiseptic precautions, the passage **edle** through the non-vascular corneal tissue instead of through **nctiva**, and also the use of a badly made needle, often resulting **e** of the vitreous into the wound. A proper discission needle **ve** sufficient width in its spear-like point to cut a hole large

enough to admit the shaft freely; hence needles which ha sharpened several times should be discarded. It need hardly that there should be no signs of cyclitis (keratitis punctata) when the operation is undertaken.

Instruments. These are the same as for discission, with t tion of a needle with a long cutting edge.

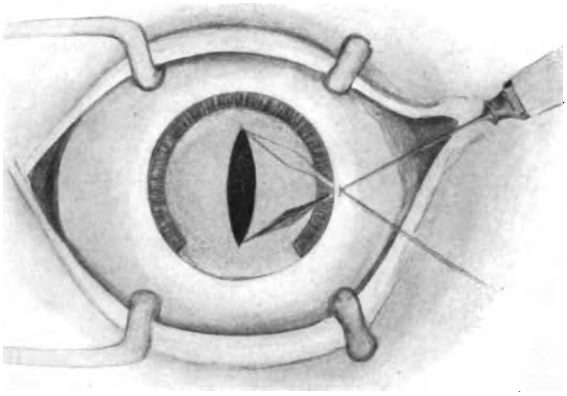

FIG. 71. CAPSULOTOMY. *The method of incising the capsule.* The fu movement of the needle is where the shaft lies in the sclera.

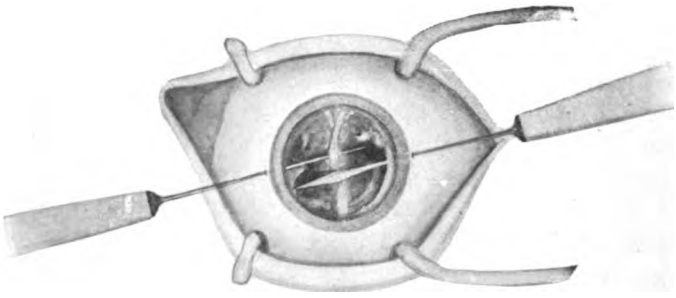

FIG. 72. CAPSULOTOMY. *The method of dividing a dense band* This is done with two needles.

Operation. Capsulotomy is best performed by artifici under cocaine. The cutting needle is inserted into the anterior as in the previous operation. The point is then thrust thro membrane below (but it should not penetrate deeply, other vitreous will be torn) and an incision is made in an upward d This incision usually gapes sufficiently to give a clear pupil (F

urgeons who operate early try to cut out a triangular portion membrane. When a dense band is present which gives before le and cannot be divided, a second or ordinary discission needle be passed into the anterior chamber from the limbus opposite utting needle. The discission needle is made to pass behind the ilst the cutting needle lies in front of it. By a rotary movement liscission needle around the cutting needle, the band is carried the edge of the latter and so divided. The needles are then wn (Fig. 72).

ults. These are good as a rule, but the operation may have to rmed again owing to an insufficient or non-central opening being in the membrane, or to a fresh membrane forming; this is take place if any irido-cyclitis follow the operation.

er-treatment. This should be carried out as described for .

EVACUATION

ications. (i) In cases of increased tension associated with s substance in the anterior chamber.

To accelerate the absorption of soft lens matter from the an- amber. As a rule it is only undertaken for the former condition.

ruments. Speculum, fixation forceps, bent broad needle, curette.

eration. Under cocaine.

step. An incision is made behind the limbus, usually in an egment of the cornea by means of a bent broad needle. The the instrument is passed into the anterior chamber immediately he limbus with the handle at right angles to the cornea; directly rior chamber has been entered the handle is depressed so that t of the instrument shall turn forwards and avoid injuring the ne blade is passed on into the anterior chamber until the point about the centre of the pupil. It is then either withdrawn or, if a larger incision be desired, lateral pressure is made so withdrawing the blade the wound is enlarged.

nd step. Evacuation. With the rush of aqueous which follows ion some soft matter is usually evacuated; then a curette may duced, if necessary, and the lens fragments removed by gentle ation. Occasionally the iris may prolapse into the wound; if this it should be replaced, but if it occur more than once the pro- ortion should be removed. Suction apparatus has been used for g the soft lens matter, but it is not to be recommended in most wing to the difficulty of sterilization and the trauma which it se. After-treatment as for needling should be carried out.

EVULSION OF THE CAPSULE

Indications. (i) In congenital cataract when the lens of little more than a dense capsular mass.

(ii) In dense capsular membranes following removal of a discission in which a cutting needle cannot make a hole.

Instruments. Speculum, fixation forceps, keratome, capsule discission needle.

Operation. A general anæsthetic is usually desirable.

First step. The pupil is previously dilated with atropine. case of congenital cataract a discission needle is first passed mass to estimate its consistency. If it consists of little more than an incision is made at the limbus with the keratome as descr evacuation.

Second step. The blades of the capsule forceps are then closed, opened, and the opaque capsule grasped and withdraw the eye. The speculum is then removed and a pad and bandage The pupil should be kept dilated with atropine subsequently, as a amount of irido-cyclitis following the operation is not infrequent sionally the iris may become entangled in the wound, and it sho be removed.

EXTRACTION OF THE LENS

Indications. (i) For all forms of cataract in patients ov years of age.

(ii) For cases of high myopia over the same age.

(iii) For lenses containing foreign bodies.

(iv) For displacement of the lens causing irritation.

Probably no operation in surgery has so many modification of which possess advantages and disadvantages which counte each other so nearly that the individual surgeon must decide for which is the most satisfactory to carry out. The opinion of ma geons, including the author, is that the ideal operation is one wh obtain sight for the patient at one sitting. The operation d below is carried out with this object in view, the various modi and the indications for their use being subsequently discussed.

Instruments. Speculum, two pairs of fixation forceps, a knife, iris forceps (Fig. 73), iris scissors (Fig. 74), capsule cystotome, curette or spoon, iris spatula, vectis (Fig. 75), or len (Fig. 76).

ration. The operation is performed under cocaine and is nto five steps:

cision.
dectomy.
ening the lens capsule.
4. Delivery of the lens.
5. Toilet of the wound.

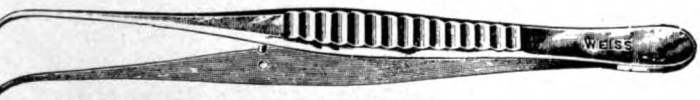

. 73. IRIS FORCEPS. Care should be taken to see that the teeth dovetail properly.

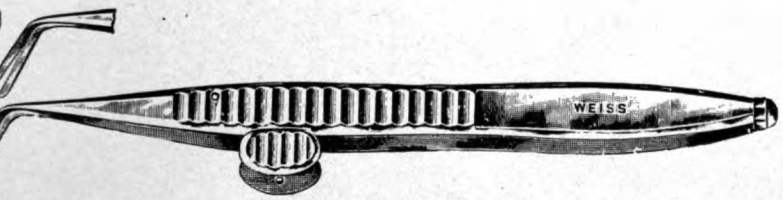

74. IRIS SCISSORS. Their cutting power should be tested on wet cigarette paper before use.

FIG. 75. A VECTIS. It should be made of stiff steel.



PAGENSTECHER'S SPOON. It is an advantage to bend the shaft near the spoon to a right angle.

step. *The incision.* The surgeon, standing behind the patient's holding the knife with the edge directed upwards, in the right the right eye, and in the left hand for the left, fixes the eye with forceps held in the other hand, by grasping the conjunctiva d to the inner side as close to the limbus as possible (Fig. 77). ntinental surgeons stand in front of the patient and cut upwards. t of the knife is then passed on the flat into the anterior chamber outer side, 1.5 millimetres behind the corneo-scleral junction.

It is first directed downwards and inwards until the chamber is penetrated (Fig. 78). The knife-point is then directed horizontally and passed across the anterior chamber in a line parallel with an imaginary tangential line across the top of the cornea. The counter-puncture is then made, the knife emerging 1 millimetre behind the corneo-scleral junction (Fig. 79). In making the counter-puncture, the beginner is apt to go too far back in the sclera owing to the angle of the chamber being

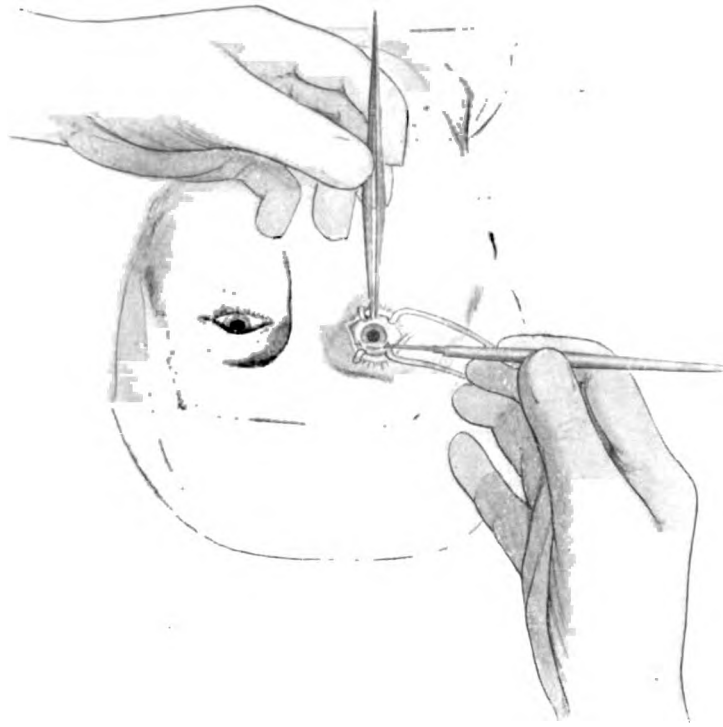

FIG. 77. LENS EXTRACTION. Showing the position of the hands when making a section upwards with a Graefe's knife.

placed behind the limbus; he should therefore aim for a point about 1 millimetre inwards from the limbus. The knife is next made to cut upwards by a sawing movement so that a flap is formed of corneal tissue about 3 millimetres in breadth (a breadth and a half of a new Graefe's knife), the upper margin being at the corneo-scleral junction. When the corneal flap has been made, the knife should lie beneath the conjunctiva, from which a flap about 3 or 4 millimetres in length should be formed. The knife-edge is then turned forward and made to cut its way out. In

making the section, care must be taken not to prick the patient's nose or eyelid with the point of the knife, as it may cause him to move his head with disastrous results. This is more likely to happen with patients who have sunken eyes.

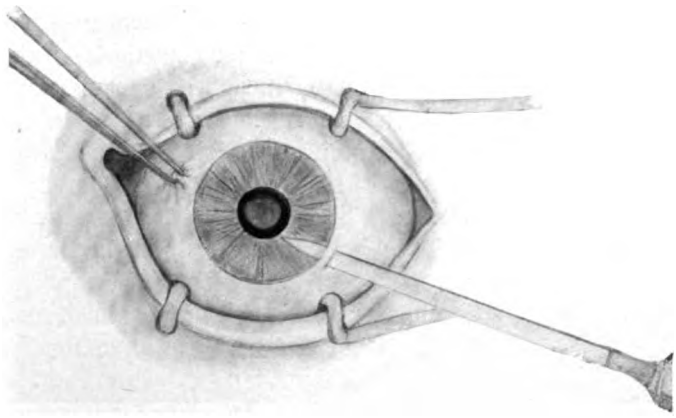

FIG. 78. THE KNIFE ENTERING THE ANTERIOR CHAMBER IN CATARACT EXTRACTION. The point of the knife is directed downwards and inwards.

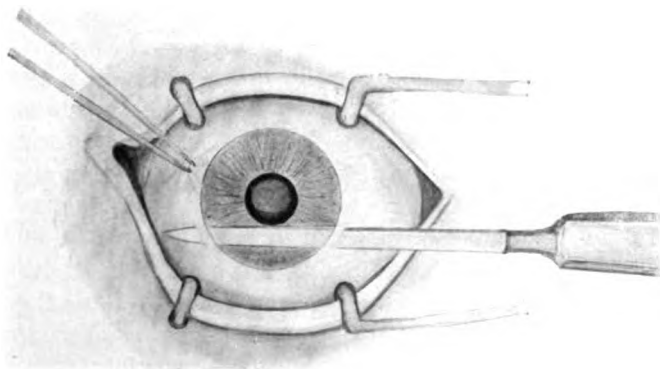

FIG. 79. MAKING THE COUNTER-PUNCTURE IN CATARACT EXTRACTION. The counter-puncture is shown completed.

Second step. *Iridectomy.* The patient is made to look downwards. A pair of iris forceps are inserted, closed, into the anterior chamber, opened, and the iris grasped near its root, and withdrawn. The piece of iris is then removed with the iris scissors, dividing it parallel with the incision as close to the eye as possible (Fig. 80). If the conjunctival

flap hinders the insertion of the iris forceps into the anterior
it may be turned forward over the cornea with the point of
forceps.

Third step. *The capsule of the lens is opened.* This is don
to allow the lens nucleus and soft matter to escape. Since th
capsule becomes opaque after the removal of the lens, owi
multiplication of the cells in their attempt to lay down new len
is desirable to remove a portion of the anterior capsule from th
area. This may be performed (*a*) by means of capsule forc
are inserted closed, and when in position in front of capsule a
as widely as possible without entangling the iris, then pressed
closed; in this manner the portion of the capsule thus included i
by a slight lateral movement. Care should be taken that t
is removed by the points of the forceps rather than the base,
means the central portion of the capsule
the pupillary area is thereby removed
(*b*) by means of a cystotome, the le
being opened by a triangular or T-shap
over the pupillary area; (*c*) by the po
knife as it passes across the anterior
(*d*) by a discission needle before the
made. When the capsule of the lens
opened properly, the lens nucleus is us
to come forward. The advantage of t
forceps over the other methods is tha
move a larger portion of the capsule an
tags which may become incarcerated in the wound. On the o
they are somewhat more difficult to use; more pressure on the
quired, and therefore dislocation of the lens in its capsule may
is, therefore, not advisable to use them in cases in which a flu
is suspected. If the teeth of the forceps are not well made th
grasp the capsule; it is therefore always advisable to have the
in readiness. The cystotome also should be used when th
chamber becomes filled with blood so that the margin of the
be seen and there is a risk of the iris being grasped by the forc

FIG. 80. INCISION AND IRIDECTOMY IN CATARACT EXTRACTION.

The method of opening the capsule with the point of th
needle is useful in cases of extraction without iridectomy;
should be dilated before the operation.

Fourth step. *Delivery of the lens* is performed by a gentl
combined with massage, on the extreme lower margin of t
with a curette or spoon, until the upper margin of the len
in the wound, when the pressure is gradually made upw

the cornea until the lens is delivered. Delivery of the lens may be prevented by—

(*a*) Imperfect opening of the capsule, which is usually the result of using a blunt cystotome; if capsule forceps are used this difficulty hardly ever arises.

(*b*) Too small an incision. The margin of the nucleus may present and not be able to pass the wound. The wound must then be enlarged with the iris scissors and the lens delivered in the ordinary way. Only

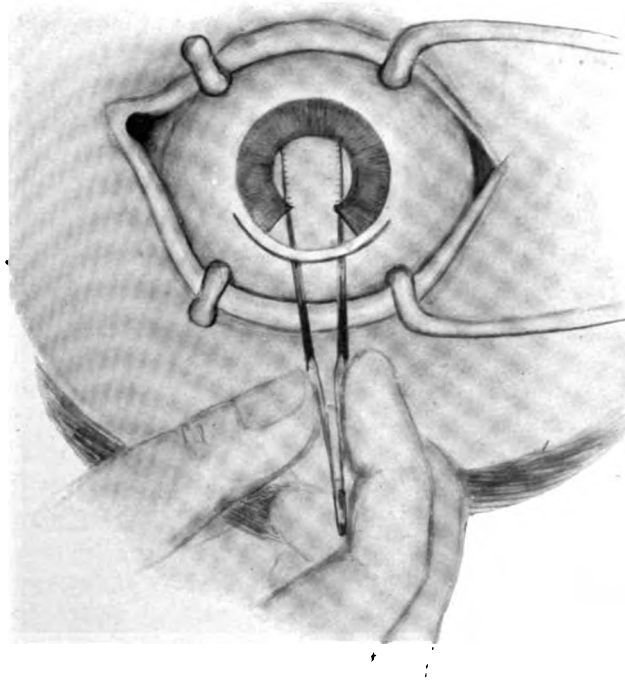

FIG. 81. OPENING THE CAPSULE WITH FORCEPS IN CATARACT EXTRACTION. The forceps are inserted closed, brought in contact with the lens, opened, and the capsule grasped between the blades and withdrawn by a gentle side-to-side movement.

by experience can the amount of pressure required for the delivery of the lens be gauged.

(*c*) A sticky consistency of the cortex is not infrequently found in cases of immature cataract. When the lens presents and cannot be delivered readily it may be helped out by means of the cystotome plunged into its substance, pressure being used on the cornea at the same time.

If from these or any other causes the suspensory ligament rupture and the vitreous present in the wound, the lens should be removed with the vectis. The vectis, which should be made of stiff steel, is passed vertically into the incision and behind the lens nucleus by depressing the handle; with a steady gentle pressure forwards it is then withdrawn together with the nucleus. The forward pressure should be such as to prevent the instrument slipping on the nucleus, for if it does so, the accident is nearly always followed by a rush of vitreous. A Pagenstecher's spoon may be used instead of the vectis, and is to be preferred in cases where a small nucleus is suspected, since the latter may slip through the loop of the vectis and fail to be delivered.

Fifth step. *Toilet of the wound.* After the nucleus has been extracted, all the soft matter should be removed as far as possible by gentle expression with the spoon. The angles of the coloboma in the iris should be replaced by stroking it inwards on its anterior surface with the iris spatula, paying particular attention to the angles of the wound (Fig. 82). The spatula should also be passed throughout the extent of the wound so as to free it from any capsule which may have prolapsed into it. The conjunctival flap is then placed in position by stroking it upwards with the iris spatula.

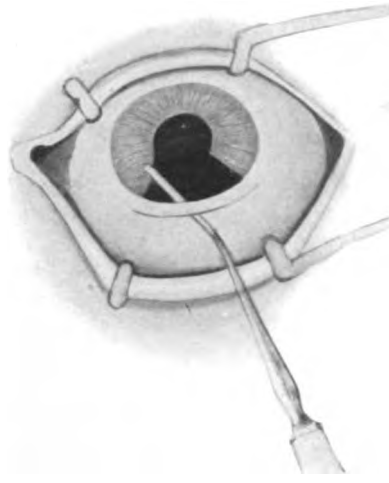

FIG. 82. CATARACT EXTRACTION. Replacing the iris, and any tags of capsule which may be in the wound, with an iris spatula.

After-treatment. Atropine is instilled either at the time of operation or at the first dressing, and continued until all signs of redness of the eye have disappeared. The patient should remain in bed for one week, both eyes being bandaged during the first four days. The eye that has been operated on should be covered for at least two weeks; subsequently a shade or dark glasses should be worn.

Modifications. The operation may be modified in various ways.

The incision. *The position* of the incision has undergone many modifications. The one described above is now in general use.

The size of the incision should be increased when (*a*) a large nucleus is expected, as in old people; (*b*) an immature cataract is to be extracted;

uid vitreous is suspected, so that the lens may be delivered
e pressure as possible.

lectomy may be omitted. *Extraction without iridectomy* is
the ideal operation; it leaves the pupil unbroken and the
normal to external appearance. Further, the pupil reacts
gly to light than if an iridectomy has been performed. The
the iris further prevents the prolapse of any capsule into
At the same time it is attended with considerable risk of
hich, as has been pointed out, is a very great danger to the
proper care this probably only occurs in about 5% of the
erated upon, but is so serious that the opinion of most sur-
favour of the combined method (iridectomy and extraction);

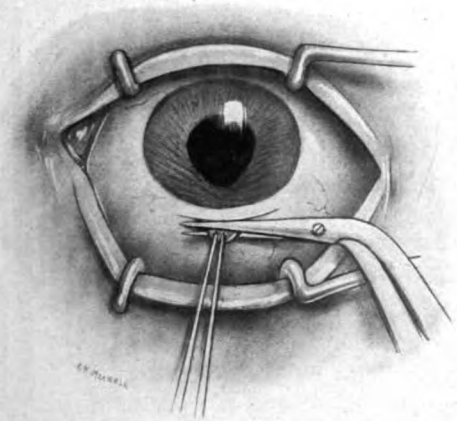

G. 83. CATARACT EXTRACTION. Showing the method of button-holing the iris.

same time it is the practice of many surgeons to omit the
under the following circumstances: first, if the patient be
the deformity will interfere with his getting employment;
extraction of the lens in its capsule be performed the un-
e of the iris will help to prevent the prolapse of the vitreous
erwise so liable to take place. A useful modification of simple
nas been recently introduced. After removal of the lens, the
ced in position, and is then seized by a pair of iris forceps
a small hold of it in its periphery and withdraws it slightly
e wound so that it can be cut off with scissors (Fig. 83).
ces a small button-hole in the iris, and leaves the sphincter
tton-holing of the iris minimizes the risk of subsequent pro-

lapse of the iris, while at the same time all the benefits of a
traction are obtained.

Eserine (gr. ii ad ℥i) should be used to prevent prolapse
after the extraction has been performed, and should be con
a day until a good anterior chamber is present, which is usua
twelve to twenty-four hours, when atropine should be subs
much soft matter be left, or the iris betray any liability to pr
the operation, as shown by the drawing upwards of the pupil
tomy should be performed before the patient leaves the tab

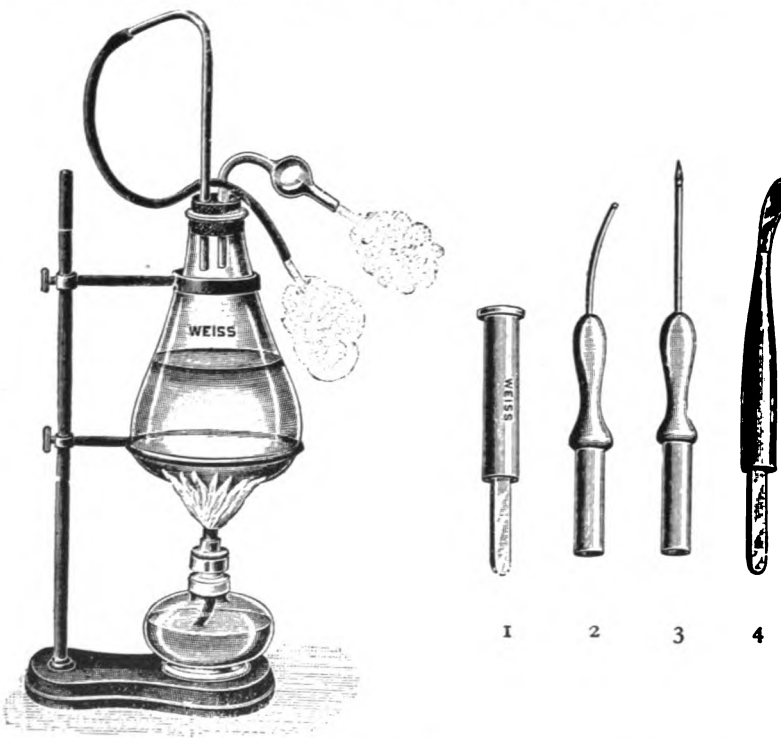

FIG. 84. MCKEOWN'S IRRIGATION APPARATUS FOR WASHING OUT TH
CHAMBER. The second and third terminals are the most u

case the eye should be examined on the evening of the operat
prolapse has occurred, that portion of the iris should be re
a prolapse of the iris occurs, and is not discovered until the
healed, the conjunctiva should be dissected off the surface i
of a flap and the iris tissue drawn out of the wound and re
angles caught in the scar being freed if possible. The ope
globe is subsequently closed by replacing the conjunctival fl

it has not been possible to preserve the conjunctiva over the raising a flap from the ocular conjunctiva in the neighbour- itching it down over the opening in the globe. Not infre- operation is followed by an attack of acute iritis, which sides under treatment.

ary iridectomy. The iridectomy may be performed at a eration. It has the advantages that the surgeon learns how will behave under operation, and how the eye will react to ration. There is an absence of bleeding at the second opera- makes it easier, and there is less liability for the iris to be- ent to the capsule. The disadvantages, which seem to out- dvantages, are that there is a double chance of sepsis, and that has to submit to two operations when one is sufficient. performed by the author in cases in which there is a increased tension in the eye due to swelling of the lens stages of the cataract. When a preliminary iridectomy d a keratome may be substituted for the Graefe's knife the incision for the iridectomy, a much smaller one being

of the lens by irrigation. McKeown removes the soft lens process of irrigation into the anterior chamber, a practice h adopted, but of considerable service in removing the soft the extraction of the nucleus, especially in immature cataract. obable that the thorough removal of the soft lens matter by reduces the number of cases of cyclitis following the opera- he soft matter forms a suitable medium for the growth of The apparatus used is shown in Fig. 84, nozzle No. 2 being eful; it is inserted into one angle of the wound and a stream normal saline solution at 39° C. (in the flask) is allowed the anterior chamber; this stream is obtained by raising the fficient pressure is obtained. An undine may be substituted . Care should be taken that there is a free return of fluid terior chamber; irrigation should be continued until as much of the soft matter has been removed.

on of the lens in its capsule. This operation is frequently n India, where patients will often not return for needling of ataract (capsulotomy). Although the method undoubtedly results, the percentage of eyes damaged by loss of the vitreous ner than when the posterior capsule of the lens is left intact. ng operation is the one usually performed, and is known as ration.

SMITH'S OPERATION FOR THE EXTRACTION OF A CATA ITS CAPSULE

Instruments. Speculum without a stop, Graefe's knife w blade, fixation forceps, two strabismus hooks, iris forceps an lens scoop, iris spatula.

Operation under adrenalin and cocaine.

First step. The speculum is inserted and the eye washed conjunctiva is grasped below with the fixation forceps and corneal section is made by means of the Graefe's knife; one, most two, strokes are enough to complete the section.

Second step. The eye is now rotated downwards by the and the iridectomy is performed.

Third step. The speculum is removed and the lids held the assistant, the upper lid being retracted by means of the hook, thus relieving all pressure on the globe. With the kn strabismus hook pressure is made at the junction of the m lower thirds of the cornea directly backwards, the pressure tinued until the wound in the cornea bulges, and the lens presen

The pressure is still continued backwards and more upwa lens in its capsule presents until it is completely delivered th incision. As a rule the upper border presents in the wound, sionally the lower does so instead, this latter form being kn 'tumbler'; the edge which presents depends on which porti suspensory ligament gives way first.

If the lens will not present, or presents together with the it is delivered by means of a spoon which is passed behind rim of the lens which is held tightly against it by means of bismus hook pressed on the cornea.

If the capsule of the lens is ruptured in the process of i after the nucleus has been extracted the capsule may be pull means of iris forceps.

Fourth step. The iris is then replaced in its position and age applied.

Extraction of the lens in its capsule is also performed whe is dislocated and causing irritation. If the lens be in the ante ber immediate extraction is called for, as glaucoma is a usual tion. Eserine is first instilled in order to contract the pupil a the lens passing back into the posterior chamber; an incisi made as for a cataract extraction and the lens removed by me vectis. Complete dislocation of the lens into the vitreous rare operation, as the patient is able to see. Partial dislocation

occasionally calls for extraction, the vectis usually being employed for delivering the lens, but before undertaking the operation an attempt should be made to get the lens into the anterior chamber by dilating the pupil and making the patient lie face downwards; if this is successful eserine should be instilled to contract the pupil behind the lens and so retain it in the anterior chamber, from whence it can more easily be extracted. Some surgeons prefer to fix the lens with a needle passed through the sclera behind the ciliary body before making the incision.

Subconjunctival extraction. In order to diminish the risks of sepsis, more especially in cases in which the conjunctiva is affected with

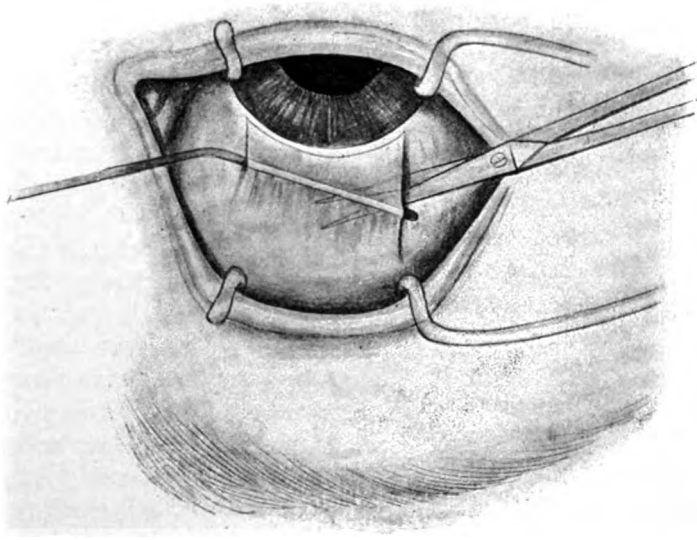

FIG. 85. SUBCONJUNCTIVAL EXTRACTION. The section in the sclera being completed with a Graefe's knife, the figure shows the method of undermining the conjunctiva to form a pocket into which the lens is delivered and from which it is subsequently removed.

trachoma, some Continental surgeons deliver the lens into a pocket beneath the conjunctiva, whence it is subsequently removed. The operation has the additional advantage of a better blood-supply to the corneal flap, which is also held in better position after the operation.

Operation. A section upwards is made with a Graefe's knife as in the ordinary method of extraction previously described, the lens capsule being opened with the point of the knife as it is passed across the anterior chamber. When the section through the sclera has been completed and the knife lies entirely beneath the conjunctiva it is withdrawn.

The wound in the conjunctiva on the outer side is the upwards with scissors, and an iris spatula is passed beneat junctiva from the small wound on the inner side and the poi appear in the wound on the outer side; by this means the cor raised on the spatula, and by means of sharp-pointed scissors, made in an upward direction by undermining the conjunctiva Delivery of the lens is then performed into this pocket, fro is subsequently removed, the conjunctival wound on the outer closed with a stitch. The advantage of this form of subc extraction over other forms which have been devised is that is met with in delivering the lens, &c., the operation can converted into an ordinary extraction by completing the the conjunctival flap.

Complications. These may be immediate or remote.

Immediate. 1. If the knife-point become entangled in th is passed across the anterior chamber it should be slightly if this can be done without loss of aqueous, the iris being t engaged.[1]

2. *Loss of the aqueous before the section is complete* ma the entanglement of the iris as before described, or the iris, o presence of the aqueous in the posterior chamber, may bulge front of the knife-blade. The latter complication is mor occur if the section be made too rapidly. The iris may so disengaged by depressing the handle of the knife towards th chin and raising the blade towards the cornea so as to allow t in the posterior chamber to escape. If this cannot be ac the section should be completed and the iris, which may by the knife, removed subsequently when doing the iridectom

3. *Avulsion of the iris* due to movement of the patient's h is more liable to take place if the eye has not been properly some time before the operation. The grasping of the iris by is always felt by the patient to a certain extent, and he should not to move. Avulsion is usually not complete and only a larger iridectomy than was intended.

4. *Dislocation of the lens.* (*a*) When opening the cap from too great pressure of the capsule forceps, or from moving his head. The lens must then be delivered by the v If, in delivering the nucleus, the upper edge is not made to pressure on the lower part of the cornea, the nucleus, especia small, is liable to be dislocated upwards beyond the incisio

[1] For the other complications which may arise in passing a G across the anterior chamber, see Glaucoma Iridectomy, p. 242.

then be removed with the vectis. In cases where a small nucleus is suspected, pressure should be made on the sclera above the incision with a curette, as well as on the lower part of the cornea, so as to make the nucleus present in the wound.

The lens may be dislocated backwards into the vitreous; if this should happen and the lens cannot be delivered, the flap must be replaced in position and the eye bandaged. Unfortunately this complication is usually followed by irido-cyclitis and loss of the eye.

5. *Loss of the vitreous.* There are two chief phenomena which may indicate that loss of vitreous is about to take place after the extraction of the lens.

(*a*) The wound gapes unnaturally after the expulsion of the lens, and the clear vitreous may be seen presenting in the wound in the still unruptured hyaloid membrane.

(*b*) There may be an apparent deepening of the anterior chamber owing to the fluid vitreous making its way forward through the ruptured hyaloid into that cavity.

If the vitreous presents in the wound before the lens has been removed, the latter should be delivered as rapidly as possible by the vectis, as has previously been described.

If the vitreous be lost or one of the phenomena, previously mentioned, occurs after the delivery of the lens, the speculum should be removed from the eye and the conjunctival flap replaced in position as quickly as possible. The eyelid is then carefully raised from the surface of the eyeball by means of the lashes held in the finger and thumb and carried downwards over the globe until it is in the closed position, and a bandage is then applied.

As little manipulation as possible should be carried out when once the vitreous has shown itself about to present, and unless the iris be obviously in the wound no attempt should be made to replace it.

Loss of vitreous may be the result of subchorioidal hæmorrhage, which may only make itself manifest after the patient has been put back to bed.

Loss of vitreous is frequently accompanied by hæmorrhage into the vitreous, as is seen subsequently by the floating opacities therein. As a rule these clear, and useful vision is obtained.

Detachment of the retina may follow loss of vitreous even months after operation. This complication seems more liable to occur if the vitreous which is lost in the first instance be normal and not of the fluid type.

6. *Intra-ocular hæmorrhage* (see Glaucoma Iridectomy, p. 245).

Remote. 1. *Panophthalmitis* is a result of infection of the wound.

It usually makes its appearance about the third day and must
by evisceration. Occasionally the purulent material is limit
line of the incision or even to the anterior chamber; in the latte
the wound should be opened up and the anterior chamber w
with peroxide of hydrogen solution (10 vols. ⅓). Microscopic
tion of the pus should be made and a vaccine prepared and adm
in two cases so treated by the author a good recovery resulted.

2. *Escape of the aqueous beneath the conjunctiva* usua
about the third day, owing to the conjunctival wound havi
without the opening into the globe being properly shut off.
accompanied by considerable pain, with chemosis and some œde
upper lid. It is usually distinguishable from acute iritis by the p
evenly dilated and discoloration of the iris being absent. The
usually subsides in three or four days, when the wound in the
become shut off.

3. *Acute iritis* not infrequently occurs after extraction.
comes on about the third day and may be accompanied by
It may settle down under atropine, leeching, and dry heat,
also pass on into the more chronic form; adhesion of the i
capsule, however, frequently results. More rarely the disease
make its appearance till two or three weeks after the operati
sepsis), the patient suffering from recurring attacks of hypo
those cases in which the hypopyon persists, washing out th
chamber with peroxide of hydrogen (10 vols. ⅓) and the admi
of a vaccine is of service.

4. *Chronic irido-cyclitis* is usually primary, but may oc
follow an acute attack of iritis. Of all the disastrous complica
is by far the worst. It may not only destroy the sight of t
which the operation has been performed, but may set up sy
ophthalmia in the other eye. The eye does not settle down well
operation, there being usually some prolapse of the iris or capsu
wound. It remains injected or flushes up on exposure to light.
time (usually about the end of the third week) keratitis punct
its appearance, and the tension of the eye may become dec
occasionally increased. The disease may resolve or go on to
of the globe. Energetic treatment with atropine and hot fon
locally, with the internal administration of iron, is indicat
administration of staphylococcus vaccine causes only temporary
ment in most instances. In six cases so treated by the a
improvement was only temporary, in spite of the fact that
a definite local reaction to the vaccine and in two cases the
coccus albus was isolated from the fluid in the anterior chamb

two months the eye be red and well-marked keratitis punctata and if the pupil be beginning to be drawn up and the eye tendency to improve, enucleation should be seriously con- is is especially advisable if the projection of light has become showing that the retina is probably detached. If any signs netic irritation, such as mistiness of vision, ciliary flush, or a, appear in the eye which has not been operated on, the e should be enucleated. On the other hand, if well-marked on has developed in the sympathizing eye, which may also be , and the other eye has a fair amount of vision, it becomes questionable whether it is advisable to enucleate the exciting y case must be judged on its own merits according to the severity of the disease. In a few cases in which the incar- the capsule in the wound leads to a very chronic cyclitis, with a cutting needle will sometimes lead to subsidence of mation. It is most important that every eye that has been n should be examined for the presence of keratitis punctata, before allowing the patient to use the eye or before another s performed on it.

ucoma following extraction occurs as a result of (*a*) soft lens cking the angle of the anterior chamber. As a rule the ten- sually subside under eserine, but evacuation of the anterior see p. 257) may have to be performed; on the whole the results tory. (*b*) The incarceration of the capsule in the wound pull- d the iris and blocking the angle of the anterior chamber. the lens capsule is usually sufficient to make the tension sub- ing this, trephining of the sclera should be performed; the s not nearly so good when the increased tension is due to this

ute keratitis usually makes its appearance on the second or fter operation. The cornea near the line of incision presents ped appearance with the striæ arranged at right angles to the athologically the condition is due to an infiltration of the ers of the cornea, the striped appearance being caused by of the posterior elastic lamina of the cornea; the condition ises from septic infection. The affection may subside without to further trouble, but is frequently followed by irido-cyclitis nally local suppuration and even panophthalmitis may follow. horizontal line about the centre of the cornea is sometimes an eye has been too tightly bandaged; this always disappears andage is removed.

hropsia (red vision) occasionally follows the extraction of the

lens, and is probably due to bleaching of the visual purple the admission to the eye of an unusual amount of light; it u appears in a few weeks.

8. *Defective vision.* Glasses have to be worn after remo lens. Usually patients who were previously emmetropic req + 11 to see clearly for distance and + 15 for near vision.

The section produces some flattening of the corneal cu right angles to the line of the incision; this usually amount two diopters.

COUCHING

Couching is the removal of the lens from the pupillar depressing it backwards into the vitreous. It is rather a r past than a present-day operation, although it is extensively p quacks in India. Under certain circumstances the operation justifiable; it is very simple, and is followed by immediate of vision, but the subsequent risks of irido-cyclitis, retinal d and glaucoma are so great, that, according to some authorities should only be undertaken in preference to extraction when operation has only a chance of one in three of giving satisfact

Indications. The chief indications for its performanc

(i) The presence of a fluid vitreous, the patient having h of the other eye extracted with bad results.

(ii) In the insane, where it would be impossible to car after-treatment of extraction satisfactorily.

Operation. The operation is usually done under cocai case of the insane a general anæsthetic is usually necessary. performed by a simple depression of the lens backwards into t with a needle passed through the cornea (anterior route). This yields unsatisfactory results owing to the lens being liable to the pupil; this can be partly overcome by sweeping the needle periphery of the lens so as to divide the suspensory ligamen operation is not so satisfactory as when the needle is passe behind the ciliary body and the lens pressed down from behind route), to which the following description applies. The caps lens should be torn freely, so that some absorption may subseq place and diminish the risk of complications.

Instruments. Speculum, fixation forceps, needle.

First step. The pupil should be dilated with atropine. Th head should be well raised on the table. The needle is passe the sclerotic about 5 millimetres behind the limbus to the

ior capsule of the lens is then freely divided by a sweeping

step. The needle is next made to appear in the lower part
l by carrying it round the lower and outer border of the lens.
or capsule is then freely divided.
tep. The shaft of the needle is laid flat on the surface of the
ls its upper part, and by raising the handle of the needle the
laced backwards into the vitreous. The tearing of the sus-
ament on the inner side may be assisted by the cutting edge
lle during depression.
lications. *Immediate.* Difficulty may be experienced in
lens lie at the bottom of the vitreous, and it is only by fre-
ession of the lens backwards and downwards, with a sweeping
of the needle to divide the suspensory ligament, that the
ect can be obtained.
. The lens nucleus may prolapse through the pupil into
or chamber. If this should happen, the patient should be
his back and the pupil dilated with atropine; if the nucleus
o back into the vitreous chamber it should be depressed by
needle passed through the cornea.
na may result from the dislocation of the nucleus into the
amber and should be treated as described above. It may also
with a lens which is dislocated backwards. This condition is
to end in loss of sight. Probably the only hope of relieving
is by the use of eserine or trephining the sclera.
and retinal detachment may also follow, and usually end
s.

Digitized by Google

CHAPTER III

OPERATIONS UPON THE IRIS

IRIDOTOMY

Indications. Iridotomy is an operation which is performed when the iris has become drawn up after a cataract extraction, so that there is no pupil, or the pupillary area is covered by the upper lid. A long interval should elapse between the extraction and the iridotomy, since these cases have usually suffered from cyclitis following the operation. Iridotomy should not be performed for at least six months after all signs of cyclitis have disappeared, for the frequent failure of the operation is due to the fact that the opening made in the iris and underlying capsule becomes filled with fibrous exudation as the result of cyclitis, which is frequently set up again by the operation if undertaken before a sufficient time has elapsed for the eye to settle down after the inflammation. The ideal operation, therefore, is to make an artificial pupil with the least amount of trauma to the ciliary body.

Instruments. Speculum, fixation forceps, a long, narrow, bent 'broad needle,' Tyrrell's hook, iris scissors, iris forceps, and spatula.

Operation. Many operations have been devised for this most troublesome condition, but the following is the one that the author has found to be successful.

The operation is usually performed under a general anæsthetic, but this is not essential.

First step. The surgeon stands facing the patient on the same side as the eye to be operated on. The long, bent, broad cutting needle is passed into the anterior chamber from the limbus downwards and inwards, and is driven directly through the iris and underlying capsule. The needle is then made to pass in an upward and outward direction behind the iris into the pupillary area above, or if no pupil be present, again through the iris (Fig. 86). The bent broad needle is made to cut laterally by slightly deflecting the handle so as to produce a band of iris and capsule; the cutting needle is then withdrawn.

Second step. A Tyrrell's hook, bent to the correct angle, is passed beneath the band (Fig. 87), which is drawn into the wound and removed with iris scissors. A large opening is thus obtained with a minimum

of trauma. If the hook should slip, the band may be seized forceps, withdrawn from the wound, and removed.

rnative methods. The following methods have been practised:

le incision across the fibres of the iris by means of Graefe's or knife.

ion with scissors through a wound in the limbus.

hese two methods the opening produced is small, and is very be closed by the subsequent cyclitis. The following operation ore satisfactory results.

86. IRIDOTOMY. Showing on with a long, bent, broad

FIG. 87. IRIDOTOMY. Showing the method of withdrawing the band of iris and capsule with a Tyrrell's hook.

nt's operation.

ments. Speculum, fixation forceps, Graefe's knife, iris for- scissors.

step. The surgeon, standing facing the patient, enters the chamber about 2 millimetres inwards from the limbus at the of the middle and lower third of the cornea with a Graefe's e cutting edge directed downwards. The knife is then made to e the iris and underlying capsule, and to travel beneath this to a oint on the other side, where it is made to come back again anterior chamber by again penetrating the iris, and finally out rough the cornea. The knife is then made to cut out in a down- rection.

Second step. Iris forceps are inserted and the flap of iris a is withdrawn and as much of it removed as possible. A mo triangular opening usually results.

Ziegler's operation.

Instruments. Ziegler's knife, speculum, fixation forceps.

The object of the operation is to cut a V-shaped flap in th underlying capsule, folding the flap backwards on its base so a a triangular opening in the iris membrane to serve as a pupil.

First step. The knife-needle is entered at the corneo-sclera with the blade turned on the flat and is passed completely anterior chamber 3 mm. of the ap periphery. The kn turned edge downw carried 3 mm. to the vertical plane

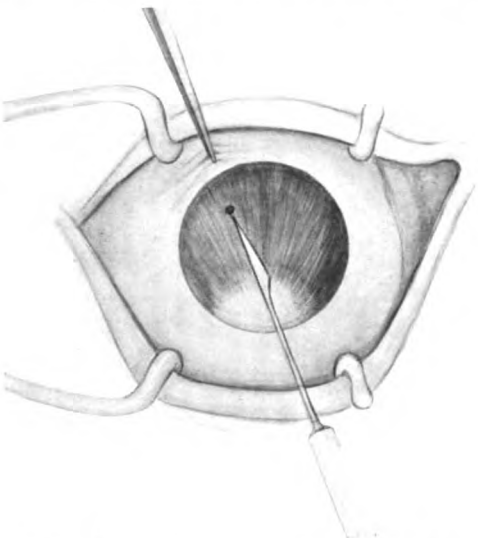

FIG. 88. IRIDOTOMY BY ZIEGLER'S METHOD. Showing the shape of the knife and the position of the first puncture in the iris; the cutting is performed by a sawing movement.

Second step. is now allowed to iris membrane, a dart-like thrust brane is pierced. knife is drawn gen down with a saw tion, without mak pressure on the ti cut, until the in been carried thr iris tissue from ture in the membra beneath the corn ture. This mov made wholly in a line with the long axis of the knife, the sha to and fro through the corneal puncture, loss of the aque avoided in the manipulation (Fig. 89).

Third step. The pressure of the vitreous will now cause of the incision to bulge open immediately into a long oval. blade is raised until it is above the iris membrane, and is th across the anterior chamber to a corresponding point on th the vertical plane. Owing to the disturbance in the relation o made by the first cut, this point is somewhat displaced and puncture must be made 1 mm. further over.

Fourth step. With the knife-point again resting on the

a second puncture is made and the incision is carried rapidly forward by the sawing movement to meet the extremity of the first incision at the apex of the triangle, thus making a V-shaped cut. Care must be taken that the pressure of the knife-edge on the tissue shall be most gentle, and that the second incision shall terminate a trifle inside the extremity of the first, in order that the last fibres may be severed, and thus allow the apex of the flap to fall down behind the lower part of the iris membrane (Fig. 90). When the operation has been completed the knife is turned on the flat and withdrawn.

IRIDECTOMY

The operation of iridectomy differs widely in its performance, according to the different conditions for which it is used. Hence it is

FIG. 89. IRIDOTOMY BY ZIEGLER'S METHOD. Showing the first incision and the position of the second.

FIG. 90. IRIDOTOMY BY ZIEGLER'S METHOD. Final step; the triangular flap of iris attached at its base is turned downwards.

better to prefix the condition for which it is employed, thus: preliminary iridectomy, optical iridectomy, glaucoma iridectomy.

Apart from being one of the stages of removal of a cataract, already described, it is performed as an independent operation in the following conditions:

1. For optical purposes (optical iridectomy).
2. For the relief of glaucoma, primary and secondary (glaucoma iridectomy).
3. For small growths at the free margin of the iris.
4. For prolapse of the iris through a wound.

OPTICAL IRIDECTOMY

Indications. Iridectomy for optical purposes is performed for a centrally situated nebula of the cornea and in some very rare cases of small central opacities in the lens. In the latter condition it is rarely of much value, as nearly all the rays which enter the eye pass through the central portion of the lens. Further, in this condition the lens may

be removed and better sight obtained with glasses. Optical
should always be performed opposite a clear portion of t
the lower segment of the eye being chosen, otherwise the
may be subsequently covered by the upper lid. The site
for the operation is downwards and inwards, but in all cases
should be carefully examined in the following ways: (1)
is tested, any refraction being corrected without a mydriati
pupil i
lated, a
situatio
iridecto
mined
of a ste
The v
be def
proved
of the
operati
advised
advanta
iridecto
it allo
light to
eye, a
periphe
lens be
spherica
tion m
For b
reasons,
it is ac
make t
tomy a
possible
ing of
scar in
will of

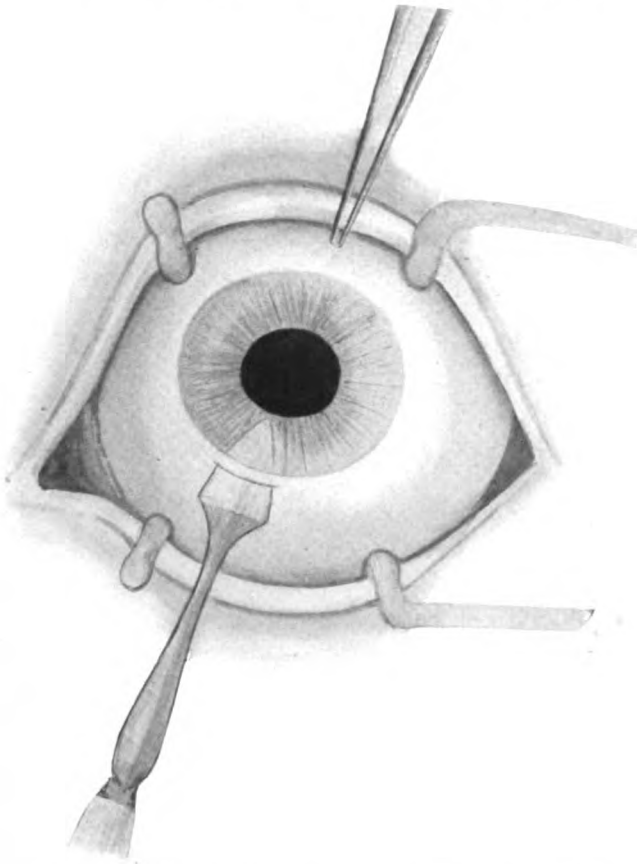

FIG. 91. OPTICAL IRIDECTOMY. The incision being made with a keratome.

ish the amount of light entering the eye, but before undertaking
operation the eye should be cocainized, and the area covered w
of black paper to see if the vision is improved thereby.

Instruments. Speculum, fixation forceps, bent broad need
keratome, Tyrrell's hook, iris forceps, scissors, and spatula.

tion. The operation is usually performed under cocaine.
tep. The eye is fixed by grasping the conjunctiva directly
e spot at which the incision is to be made. The incision
de by means of a keratome or bent broad needle directly
limbus, and enlarged laterally if desired (Fig. 91.).
step. A Tyrrell's hook, bent at the correct angle, is passed
into the anterior chamber. When the margin of the iris is

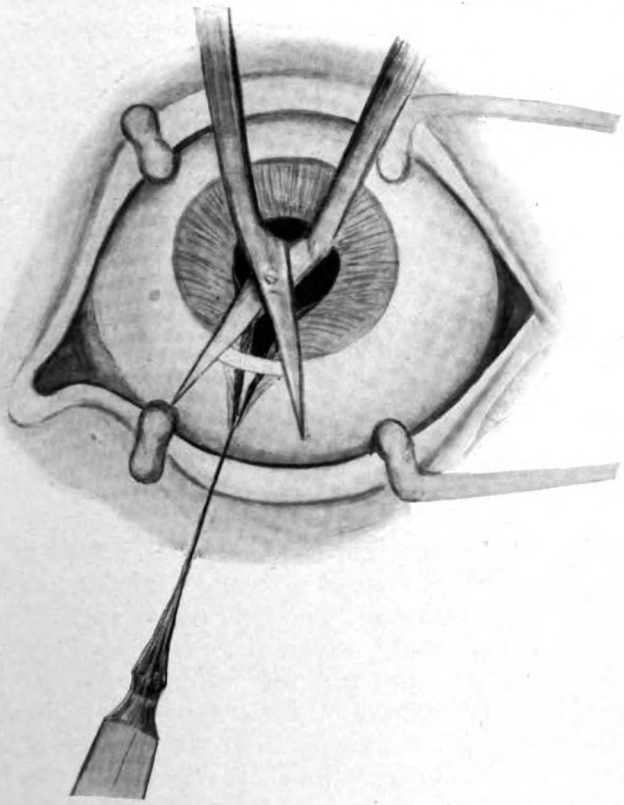

Optical Iridectomy. Method of removing the iris to produce a small coloboma.

handle is rotated and the hook is made to engage the free
he iris, which is then withdrawn from the wound; a small
emoved with scissors, which should be held at right angles
d when dividing the iris (Fig. 92).
tep. The iris should be carefully replaced and the pupil kept
nfluence of eserine until the anterior chamber has re-formed,
ine should be substituted.

Care must be taken to see that the Tyrrell's hook presents no sharp angle, and great care is required in its manipulation, otherwise the lens capsule may be damaged, and traumatic cataract will result. If the iris slips from the grasp of the Tyrrell's hook, iris forceps should be used, the iris being grasped near its free margin and as small a portion as possible withdrawn.

Brudenell Carter's method. The ordinary optical iridectomy divides the sphincter iridis and so inhibits the activity of the pupil. With the idea of obviating this, Brudenell Carter removed a small portion of the iris (button-hole), leaving the pupillary margin intact. On the whole the results of the latter operation are no more satisfactory, and the operation is more dangerous to perform owing to the likelihood of wounding the lens, and to the fact that monocular diplopia occasionally results.

FIG. 93. OPTICAL IRIDECTOMY. Showing the coloboma.

The pupil should be under the influence of eserine. The incision is made as in the previous operation. De Wecker's iris scissors are inserted open into the anterior chamber, closed, and the piece of iris which bulges up between the blades cut off; this can usually be withdrawn with the scissors; or if not, it should be removed subsequently by forceps.

GLAUCOMA IRIDECTOMY

Surgical and pathological anatomy. The fluid in the anterior and posterior chambers of the eye is secreted from the ciliary body by a process of modified filtration. The fluid passes partly direct into the posterior chamber and partly behind the suspensory ligament of the lens, making its way forward into the posterior chamber through the fibres of the suspensory ligament. From the posterior chamber it passes into the anterior through the pupil; from the anterior it filters at the angle of the anterior chamber through the spaces of the angle of the iris into the venous sinus of the sclera (canal of Schlemm); thence it is carried into the blood-stream by the venous anastomosis in that region (Fig. 94).

The essential change found in all cases of primary glaucoma is the blocking of the angle of the anterior chamber owing to the root of the iris being applied to the back of the cornea, and thus preventing the filtration of the fluid into the venous sinus of the sclera, as a result of which the tension of the eye is raised, either acutely (acute glaucoma) or slowly from time to time (chronic glaucoma) (Fig. 95). The aim of every operation for the permanent relief of glaucoma is the opening up of

sinus of the sclera at the angle of the anterior chamber, or the a new lymph channel between the anterior chamber and the tival tissue (filtrating cicatrix). Although this latter condi- unattended by the risk of the spread of inflammation from ctiva to the interior of the globe, it is not an inadvisable con- otain if the scar be small and free from iris tissue.

tions. Until the last few years, iridectomy has held the n the treatment of glaucoma, but now in the practice of most surgeons it is superseded other forms of sclerectomy, the best, in the opinion of , is by trephining; both for chronic cases. The indica- below are applicable to this as well as iridectomy, under ling they are here placed.

primary glaucoma. Iridec- ld be undertaken as early e in the disease. *In acute* ess the tension is relieved, e ends in rapid destruction t. Operation should always ken as quickly as possible, he patient has not lost his of light for longer than ays.

waiting for the operation, should be put under the f eserine (2 to 4 grains to ith the idea of reducing the contraction of the pupil. geons, in addition to using erform a posterior scleral ith the idea of temporarily he tension and allowing ymptoms to subside, and do the iridectomy some twenty-four ht hours later. This method is extremely useful (*a*) in cases neral anæsthetic is inadvisable, since the reduction of tension ine to diffuse into the eye; (*b*) in cases liable to subsequent hæmorrhage, a more gradual reduction of tension being upture of a chorioidal vessel is less likely to occur; (*c*) a rior chamber is often obtained, and hence there is less risk of

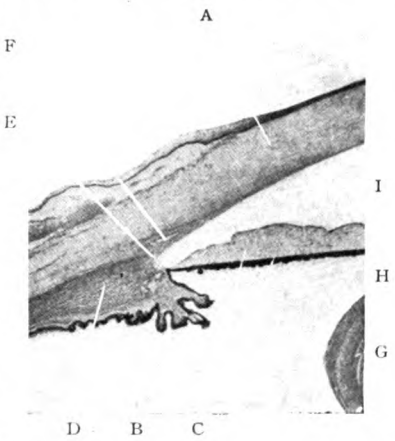

FIG. 94. THE NORMAL ANGLE OF THE ANTERIOR CHAMBER.

A. Cornea.
B. Ciliary processes.
C. Iris.
D. Ciliary muscle.
E. Pectinate ligament, to the right of which is the angle of the chamber.
F. Sinus venosus scleræ (Canal of Schlemm).
G. Lens.
H. Posterior chamber.
I. Anterior chamber.

wounding the lens, during the operation; (*d*) in cases where the operation has been performed in one eye and the lens has been subsequently extruded on the dressings.

In chronic cases early iridectomy is desirable, since the root of the iris applied to the posterior surface of the cornea becomes atrophic, so that when an iridectomy is performed the iris tears off at the anterior part of the atrophic portion, leaving the angle of the chamber still occluded by its root (Figs. 96 and 97).

Operation is only contra-indicated in a few very rare cases in which the tension is controlled by the use of eserine.

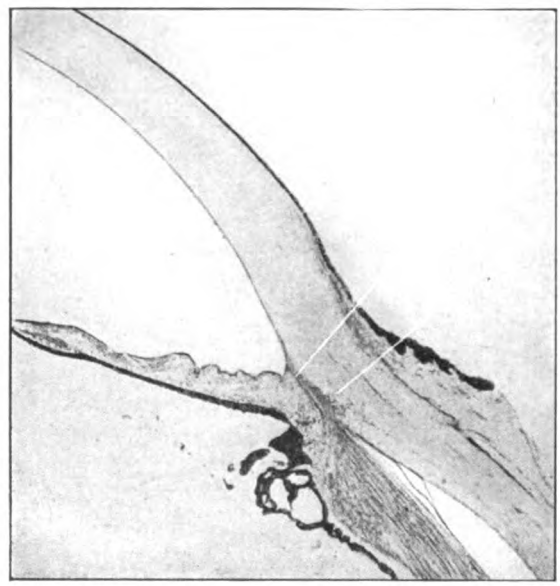

FIG. 95. THE ANGLE OF THE ANTERIOR CHAMBER FROM A CASE OF RECENT GLAUCOMA. Showing its occlusion by the base of the iris, A, being adherent to the posterior surface of the cornea, so preventing filtration of the aqueous into the venous sinus of the sclera, B.

(ii) **In congenital glaucoma (buphthalmos).** In this affection the results of iridectomy vary. Without doubt, the tension has been relieved by iridectomy in some cases, and either this operation or trephining of the sclera should be tried if the disease be not too far advanced.

(iii) **In secondary glaucoma.** For obvious reasons the predisposing causes should always be taken into consideration. Thus it would be of no use to perform an iridectomy in the case of a growth in the chorioid. On the other hand, an iridectomy would be unjustifiable for soft lens matter in the anterior chamber, which merely requires evacuation. An early iridectomy in cyclitis is not likely to influence the course of the disease favourably: at the most a paracentesis is required. As the early stages of cyclitis may give rise to tension, it is essential that every case of glaucoma should be examined for keratitis punctata before operation.

In iris bombé and total posterior synechiæ an iridectomy is indicated

more to re-establish the communication between the anterior and posterior chambers than to clear the angle, and therefore it need not be so extensive. In cases of iris bombé where iritis is still present, and in cases of cysts of the iris, transfixion is all that is necessary.

It is very doubtful if iridectomy in glaucoma following thrombosis of the central vein is justifiable, for as a rule the tension is not permanently relieved thereby and intra-ocular hæmorrhage is liable to take place. In secondary glaucoma following cataract extraction or anterior synechiæ, division of the capsule or the anterior synechiæ will often relieve the tension.

Instruments. Speculum, fixation forceps, Graefe's knife (with a short, stiff, narrow blade), iris forceps, scissors, and spatula.

Operation. With the idea of opening up the angle of the anterior chamber by removing the iris as near its root as possible, the incision should be made somewhat further back behind the corneo-scleral junction than in cataract extraction. At the same time, if the incision be placed too far back the ciliary body is liable to prolapse into the wound. The old idea of opening up the venous sinus of the sclera by dividing it has been abandoned, as to do so would certainly result in prolapse of the ciliary body; and even if this did not happen, no good would result, since the sinus would become closed subsequently by cicatricial tissue.

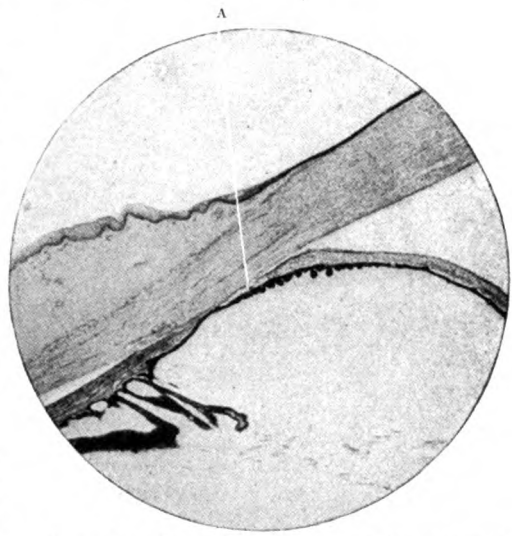

FIG. 96. THE ANGLE OF THE CHAMBER IN A CASE OF CHRONIC GLAUCOMA. The iris, A, has become atrophic at its root. An iridectomy in this case would not free the angle of the chamber, as the iris would separate at the point A.

Although von Graefe used a keratome for making the incision, most British surgeons of the present day use a Graefe's knife, as it gives an incision that is less shelving and more irregular, thus predisposing to the formation of a filtrating scar; a good conjunctival flap is obtained with it and there is less risk of wounding the lens.

When performing the iridectomy it is practically impossible to cut the iris with scissors at its attachment to the ciliary body, and

it is better to rely on tearing it off from the ciliary bo
in this situation that the iris is thinnest and most likely t
provided it has not become atrophic by prolonged conta
cornea.

In acute cases, and in cases of secondary glaucoma whe
many adhesions, a general anæsthetic is desirable.

First step. The incision. The position of the surgeo
cataract extraction. The eye is fixed by grasping the conju
to the limbus downwards and inwards. If the patient l
anæsthetic, two pairs of fixation forceps should be used, on
by an assistant. Occasionally in glaucoma the conjunctiva
easily, and in these cases scleral forceps are of use, or, if
already in the eye, grasping the insertion of the superior
rectus. Th
knife should
downwards
towards th
fixation, the
passed throu
1.5 mm. beh
bus to the
Directly th
chamber is
handle is d
wards the pa
The knife-p
superficial to
is passed
across the an
ber, close to
until the
the counter

FIG. 97. IRIDECTOMY FOR GLAUCOMA. Failure to relieve the tension owing to the iris not tearing off at its junction with the ciliary body, due to atrophy from prolonged contact with the cornea.

reached. The counter-puncture should be situated about
hind the limbus in a direct line with the original puncture.
be taken in making the counter-puncture that the knife-po
slip back on the sclera and so emerge further back in the
desired. The knife is then made to cut out upwards and
junctival flap is obtained. The incision should be carried
so that the aqueous escapes gradually, as sudden reduction
ocular tension is liable to lead to intra-ocular hæmorrhage

Second step. The iridectomy. The iris forceps are ins
into the anterior chamber, opened, and made to grasp the

ig. 98) towards the side of the wound on which the iris is ivided; then with a slight side-to-side movement of the is is withdrawn from the wound until its peripheral attach- ciliary body, near where it is held by the forceps, is felt e way (irido-dialysis) (Fig. 99). The iris is then drawn a out from the wound, and one side of the dialysis is divided sors as near the scleral wound as possible. The iris held s is then pulled over to the other angle of the wound, and t as possible is pulled out and divided close to the scleral . 100). The angles of the incision are freed from iris by spatula and the conjunctival flap is replaced in position. then bandaged.

eatment. The patient should be kept in bed for a week, ne first four days should not be allowed to raise the head

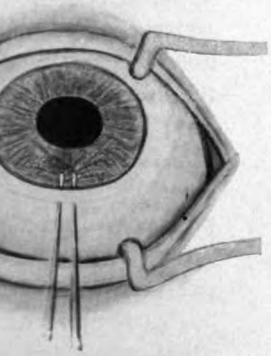

IDECTOMY FOR GLAUCOMA. position in which the iris ped with forceps.

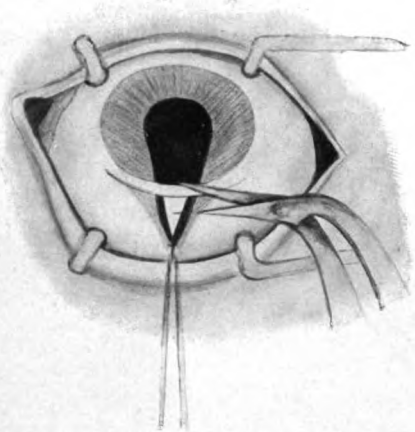

FIG. 99. IRIDECTOMY FOR GLAUCOMA. Showing the irido-dialysis produced before division.

ow. After that time the eye not operated upon may be serine should have been instilled into it before the opera- bsequent dressings to prevent the possible onset of glaucoma dilatation of the pupil which follows the application of the ne eye. It is not necessary to use any mydriatic or myotic hich has been operated upon.

ations. These may be immediate or remote.

e. 1. In passing a Graefe's knife into the anterior chamber ection, care must be taken that the cutting edge is directed by accident it should be inserted with the cutting edge

directed downwards the knife should be withdrawn and
postponed for a day or two until the anterior chamber has

Care must be taken that the cutting edge is kept on th
as the upper edge of the back of the knife, otherwise the inc
to pass further back than is intended.

2. *Splitting the cornea.* The anterior chamber ofte
more than a potential space, the knife may be passed betwee
of the cornea and may not enter the anterior chamber at al
cation that the knife-point is not in the anterior chamber is
no diminished resistance, such as is usually felt when the kn
chamber; if its point be slightly depressed, the cornea wi
dimple in over the position of it, showing that the point i
the anterior chamber.

3. *Locking of the knife.* This is due to the fact that the
counter-puncture
in the same plane,
ing twisted. It i
liable to occur i
chosen with a bl
not sufficiently sti
the blade can be
out, but failing t
should be with
ciently to allow a
puncture to be
withdrawn altoge
operation postpon

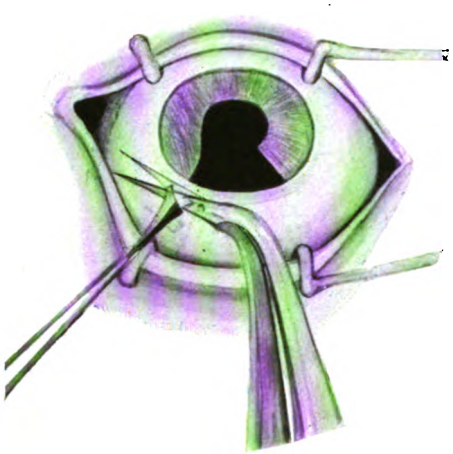

FIG. 100. IRIDECTOMY FOR GLAUCOMA. Division of the iris to form the inner angle of the coloboma. The iris is pulled out as far as possible before removal.

4. *Wound of*
great safeguard ag
ing the lens is to
of the knife alwa
to the iris and in
of the anterior
the lens be definitely wounded at the time of the operatio
extracted immediately after the iridectomy. If the wound
sequently discovered (usually about the third or fourth da
the lens be not presenting in the wound, the eye should
settle down and the traumatic cataract extracted some ti
tenth day.

5. *Presentation of the lens in its capsule.* The lens m
its capsule at the time of the operation or be found subseq
dressings. In the latter instance it is very liable to carry

d a cystoid cicatrix results. This accident is usually due to ension in the vitreous chamber; a large incision, especially if ier far back in the sclera, will also favour its occurrence. If it should happen to one eye, and acute glaucoma be present r, it is advisable to do a posterior scleral puncture before the is performed. Partial dislocation of the lens forward may r the wound has healed, leaving the tension of the eye not This is a condition extremely difficult to recognize, and it is y discovered pathologically; if recognized clinically, extraction should be performed (Fig. 101).

a-ocular hæmorrhage. *Hæmorrhage into the anterior cham-* at the time of the operation and is readily absorbed; occasion- persist for a considerable time in cases of glaucoma of long

he operation hæmorrhage may also occur from the cut margin , which never heals, *viz.* never becomes covered with endo- The hæmorrhage may occur as late as two weeks after the nd may recur from time to time; it is especially liable to occur ople with arterio- It is usually ab- hout giving rise to le beyond delay in escence.

l hæmorrhages are nd usually small, nsiderable hæmor- y take place into ous. As a rule r up satisfactorily macular region be

FIG. 101. IRIDECTOMY FOR GLAUCOMA. Failure to relieve the tension owing to displacement of the lens.

rioidal hæmorrhage. Of all the immediate complications which intra-ocular operation this is by far the worst. The hæmor- ue to the giving way of a large chorioidal vessel following the luction of tension, with the result that the chorioid and retina d up from the sclera, and, with the lens, may be partially ex- m the wound in the globe, from which the hæmorrhage then It may occur whilst the patient is still on the operating table, be discovered only after he has been put back to bed, the g seen coming through the dressings. Patients who have this complain of pain in the 'corner of the eye' at the time of ion. The treatment consists in evisceration or enucleation.

It is probable that limited extravasation of blood may also o
need not end in disintegration of the eye, but may cause vitre
and defective vision for some weeks after the operation.

Remote. 1. *The tension is not reduced by the iridectom*
cases the prognosis with regard to the reduction of the tens
improvement of vision is very satisfactory. The same can
of chronic cases, especially those which have been operate
late in the disease. If iridectomy, which may be repeated do
extended from the previous coloboma, fail to reduce the ten
more of the following measures should be adopted:

(*a*) The use of eserine.

(*b*) Trephining the sclera.

It is probably in this order that they should be tried.

2. *Failure of formation of the anterior chamber.*

After iridectomy or sclerectomy in some cases the vitr
forward the lens and iris against the back of the cornea, and
chamber never re-forms, although the aqueous may leak out
the conjunctiva and the tension be relieved: but in some case
ing of the vitreous is so great that the tension is not relieved
becomes hard and painful. These cases are known as mali
coma. In the cases in which the tension is relieved, the pati
tain good vision for the time, but subsequently the lens becom

3. *Prolapse of the iris and irido-cyclitis* should be treate
indicated under cataract extraction (see p. 226).

4. *The onset of glaucoma in the other eye* may be ind
dilatation of the pupil caused by bandaging, and is best avo
use of eserine. If it should occur, an iridectomy should be

5. *Astigmatism* produced by the incision is corrected w
This astigmatism is very marked, often amounting to s
diopters or more.

IRIDECTOMY FOR SMALL GROWTHS OF THE I

Indications. This is performed—

(i) As a diagnostic measure.

(ii) As a curative measure.

In the latter instance it is obvious that the growth must b
and situated at the free margin of the iris to yield a satisfa
especially if it be of a malignant character.

Operation. The operation is performed under coca
having been previously instilled in order to contract the pupil

First step. An incision should be made with a narrow Gr
in the limbus in a position most suitable for removing the gr

ould be as large as possible so as to avoid wiping off any por-
e growth into the anterior chamber.

step. The iris should be seized well in the periphery so as to
king up the growth; it is then withdrawn with the growth,
ter removed.

IRIDECTOMY FOR PROLAPSE OF THE IRIS

eration is usually performed for prolapse of the iris following
f the cornea or limbus, and may be attempted up to about the
fter the original injury.

tion. A general anæsthetic is usually desirable. The pro-
should be seized with the forceps and withdrawn from the

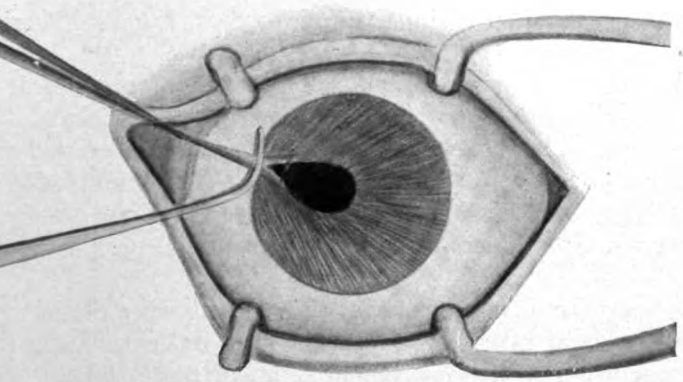

ROLAPSE OF THE IRIS THROUGH A PUNCTURED WOUND OF THE CORNEA.
f withdrawing the iris by two pairs of iris forceps before removal.

A second pair of forceps is used to take a fresh hold on the
can usually be drawn out further (Fig. 102). It is then
close to the corneal wound as possible. The iris usually flies
he anterior chamber clear of the corneal wound by its own
ut if it does not do so, it should be freed with a spatula.
should be kept subsequently under atropine.

TRANSFIXION OF THE IRIS

tions. This operation is undertaken in cases of iris bombé
is still present and when an iridectomy would subsequently
rawn-up pupil. It is also of service to evacuate the contents
the iris (local iris bombé).

ents. Speculum, fixation forceps, Graefe's knife (narrow).

Operation. The knife is entered at the limbus from th directly opposite the occluded pupil. The apex of the iri transfixed and the point of the knife made to appear above t area; the iris bombé on the other side of the pupil is then tra the knife is withdrawn.

THE DIVISION OF ANTERIOR SYNECH

Indications. Anterior synechiæ rarely require division are likely to cause tension, or the adherent iris is considered danger to the eye on account of its liability to septic infecti synechiæ are causing tension, the method of division desc sclerotomy is probably the most satisfactory; otherwise th method devised by Lang can be used.

Instruments. Speculum, fixation forceps, Lang's knives a sharp point, and one blunt.

Operation. Under cocaine. The incision is made at in a favourable situation for the division of the synechia. pointed knife is introduced into the anterior chamber and t withdrawn so as not to lose the aqueous. The blunt knife serted through the incision and, partly by cutting and partly the synechia is divided in a direction from the periphery t pupil.

The operation is not at all easy to perform, since the iris the knife. Great care should be taken to avoid evacuating t as the operation is thereby rendered much more difficult c possible.

CHAPTER IV

OPERATIONS UPON THE SCLERA

ANTERIOR SCLEROTOMY

ications. Sclerotomy is an operation undertaken for the relief ased intra-ocular tension. It is performed—

Usually as a secondary operation when iridectomy has failed.

As a primary operation for the division of anterior synechiæ tension.

ew surgeons prefer the operation to iridectomy, especially in cases thalmos. When practised after an iridectomy which has been wards, the sclerotomy is sometimes performed in a downward n; otherwise the section is usually made upwards. The intra-tension is probably relieved by the formation of a filtration and it is therefore probable that it will be largely superseded by ration of trephining the sclera.

en performed for the division of anterior synechiæ the position incision should be planned according to the situation of the to be divided.

ruments. Speculum, fixation forceps, Graefe's knife with a nar-de.

eration. The operation is done under cocaine. Eserine should en previously instilled in order to contract the pupil and prevent of the iris.

efe's knife should be passed across the anterior chamber in the anner and position as for a glaucoma iridectomy (see p. 242). *omplete* method the knife is made to cut out through the sclera, a band of conjunctiva to hold the flap in position. In the *ete* method a band of sclera is left in the periphery. If the n is done in a downward direction, it is better for the surgeon l on the opposite side of the patient to the eye on which the n is to be performed, operating across the patient.

nplications. Any of the complications which follow an iridec-r glaucoma may occur (see p. 226). Prolapse of the iris is prob-most frequent.

SCLERECTOMY

The object of the operation is the production of a filtratio
free from iris tissue for the relief of intra-ocular tension in gla
removal of a portion of the sclera in the neighbourhood of the

ELLIOTT-FERGUS OPERATION, TREPHINING THE SCI

The operation has not yet been introduced sufficiently lon
stood the test of time, but, in the author's opinion and that
other ophthalmic surgeons, it is the operation which should be
first place in the treatment of primary glaucoma both acute an
and also in that of many forms of secondary glaucoma. It
advantages over the old operation of iridectomy in that (1) it i
by far less risk to the eye; (2) it is easier to perform; (3)
done without an anæsthetic, even in acute cases; (4) it gives ri
little or no astigmatism;
much more certain of reli
tension, especially in chro
It should always be accom
a peripheral buttonhole o
which should be placed im
under the opening of the scl



FIG. 103. ELLIOTT'S TREPHINE.

Instruments. Speculu
pointed scissors, Graefe'
straight iris forceps, trephi
phine with a serrated edge cuts better than a smooth one), iri
iris scissors, stitch and needle holder.

Operation. Under adrenalin and cocaine.

First step. A large conjunctival flap is dissected up over
segment of the sclera with a pair of sharp pointed scissors, an
iris forceps. This is turned forward over the cornea (see F
By means of a Graefe's knife the flap is dissected forwards
limbus has been exposed. Great care should be taken not to l
the flap.

Second step. After all the bleeding has been arrested by
and cocaine, a 2 mm. trephine is applied to the sclera as ne
cornea as possible (Figs. 104 and 105). With a rotary move
trephine is made to penetrate the sclera, the depth of the incis
gauged from time to time with the point of an iris spatula.
when the sclera is penetrated there is a sense of loss of resista
operator, and the patient usually complains of some pain owi
trephine coming down on the iris or ciliary body; the disc of

then held in forceps and removed. If it is still adherent, it can be divided by scissors.

Third step. An iris spatula is inserted into the trephine opening, passed forward into the anterior chamber, and swept round so as to free the peripheral adhesion between the iris and the posterior surface of the cornea. The iris will then bulge into the wound. This manœuvre

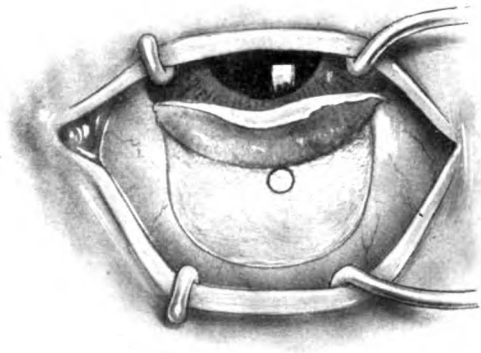

FIG. 104. TREPHINING THE SCLERA. Showing the position of the trephine opening.

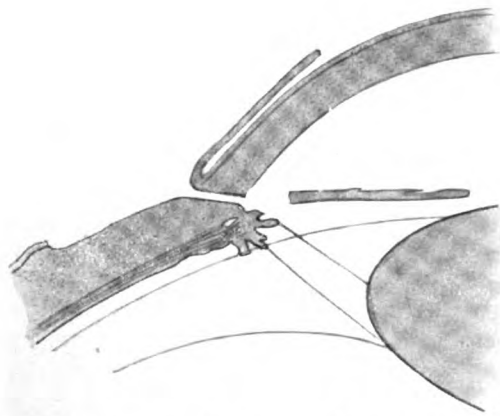

FIG. 105. TREPHINING THE SCLERA. Showing the tissue removed.

renders it unnecessary to place the trephine hole so far forward in the cornea as to produce prolapse of the iris, as would be the case if this method were not adopted.

Fourth step. The protruding iris is seized with a pair of straight iris forceps and a small piece is removed with iris scissors. The remainder

of the iris is then returned into the anterior chamber by m
iris spatula.

Fifth step. The conjunctival flap is replaced in position
by means of a stitch which should be removed about the f
A drop of eserine (1 gr. to ℥i) is put into both eyes and dr
applied.

For the first ten days or so after the operation the conj
the neighbourhood of the wound is swollen and œdematous
aqueous humour leaking beneath it. After a time the œdem
more localised, giving the appearance of a clear vesicle over th
of the hole in the sclera. This operation is one practised
surgeons, including the author, but there are many modifica
employed; thus Bardsley and Holt have devised a punch.

There are also numbers of other various forms of trepl
103 shows one devised by Elliott.

Complications

Immediate. *Button-holing of the conjunctival flap* in
forward over the cornea should be avoided by not carrying t
too far forward into the cornea, as it is not necessary if the i
by the spatula as described in the third step in the operati
surgeons prefer to use a secondary cataract knife rather tha
to deepen the incision at the limbus. If a button-hole is mad
phine opening should so be placed as not to lie directly under it

Loss of vitreous is not an uncommon occurrence in cas
acute glaucoma and in cases of secondary glaucoma due to dis
the lens; a small loss does not seem to affect the prognosis.

Injury to the lens by the iris spatula in replacing the i
avoided with ordinary care.

*The piece of sclera removed by the trephine may drop in
terior chamber.* It should be left alone. The complicati
avoided by not placing the trephine hole too far forward in the

Subchorioidal hæmorrhage (see p. 245) is far less frequent
iridectomy.

Remote Complications. *Inflammatory complications* ar
are similar to those following any wound into the eye. The
spread of sepsis from the conjunctiva into the wound after the
healed is very slight, if it be entirely free from the tissues of
tract. Small iritic adhesions to the anterior capsule of the le
infrequent.

Failure to relieve the tension of the eye by the operation

the opening in the sclera not corresponding to the iridectomy, the opening in the sclera again becomes blocked by the iris.

formation of a very large œdematous mass of conjunctiva over ning in the sclera, due to the scar tissues blocking the lymph and the aqueous accumulating beneath, can be improved by plac- ıbconjunctival silk drain between it and the healthy conjunctiva This is done by passing a silk stitch beneath the healthy con- on one side of the bleb, across it, and out through the healthy tiva on the other side; both ends of the silk thread are cut off the conjunctiva and with a little manipulation are made to ar from the holes made by the needle.

ruments. As for glaucoma iridectomy, with the addition of curved pair of scissors.

LAGRANGE'S OPERATION FOR GLAUCOMA

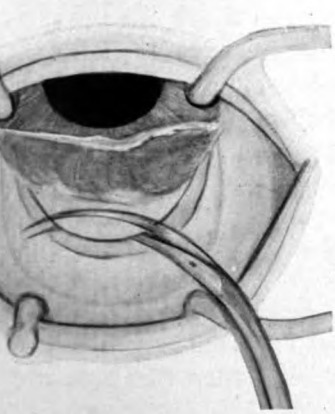

106. LAGRANGE'S OPERATION E PRODUCTION OF A CYSTOID CHRONIC GLAUCOMA. Showing ıod of removing a piece of the

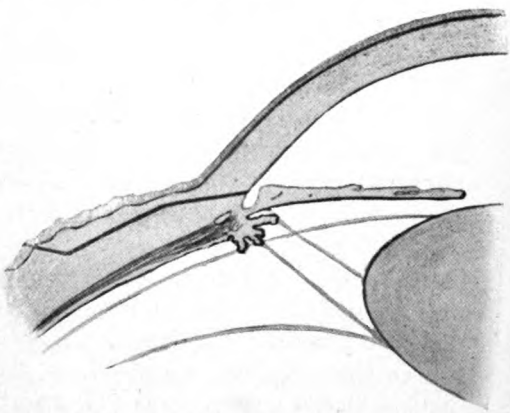

FIG. 107. LAGRANGE'S OPERATION FOR CHRONIC GLAUCOMA. Showing the piece of sclera removed by the scissors (black lines).

t step. (Under cocaine.) The incision is performed as for my (see p. 242), except that the incision should be rather smaller uld be carried more obliquely through the sclera, so that a long lap is obtained. A large conjunctival flap is very essential to e wound.

ond step. An iridectomy is usually performed as for glaucoma; y be omitted.

rd step: After all the bleeding has ceased, the conjunctival flap d forwards on to the cornea so as to expose the scleral flap; with

small curved scissors made for the purpose, an elliptical porti
moved from the sclera by a single snip (Figs. 106 and 107),
conjunctival flap is replaced in position. As a result, a hole is n
the anterior chamber, which thus communicates with the subcon
tissue, which is bulged forwards in the form of a clear vesicl
escaping aqueous when the wound has healed.

The immediate results of this operation are satisfactory
that enough sclera be removed to produce a filtration cicatr
operation is satisfactory but more difficult and dangerous to
than trephining.

POSTERIOR SCLEROTOMY

Indications. Posterior scleral puncture is performed—

(i) For the relief of tension, the indications for which hav
been described under the indications for iridectomy in glauc
p. 239).

(ii) For the evacuation of fluid behind a detached retina.

The operation in the latter instance, although not yield
satisfactory results with regard to the reattachment of the ret
be carried out with some hope of success in certain cases. Be
forming the operation the pathological cause of the detachmer
be carefully investigated, for it is obvious that it would b
to perform the operation in a case of detachment due to a c
tumour or if definite bands of fibrous tissue could be seen in the
pulling off the retina. Undoubtedly it should be undertaken as
possible after the detachment has occurred and the puncture sho
the space filled with subretinal fluid. Whether the punctur
penetrate the overlying retina is still a disputed point.

After the operation a pressure bandage should be applied
patient should be kept on his back and not allowed to raise
from the pillow for at least three weeks. This latter part of t
ment is most essential; indeed as good results may be obtai
complete rest as by performing scleral puncture. Unfortunatel
rence is very liable to take place whichever method be used, eve
tachment of the retina be obtained. For a modification of th
tion see p. 257.

Instruments. Speculum, fixation forceps, Graefe's knife.

Operation. Under cocaine. If no special position be
the puncture is best made upwards and inwards. The patient
to look outwards and downwards. The conjunctiva over th
well behind the ciliary body, is drawn down so that when re
shall form a valvular opening to the scleral wound. The Graef

n through the conjunctiva and sclera, the incision being made osteriorly in the direction of the fibres of the sclera to avoid ng the chorioidal vessels. It is probably better to enlarge the when withdrawing the knife than to turn the latter at right angles t is withdrawn, as has been recommended by some surgeons. A vitreous usually escapes under the conjunctiva. If the tension owered, gentle massage of the globe through the lid should be d.

ESTABLISHMENT OF NEW LYMPH PATHS BY MEANS OF SUBCUTICULAR SILK THREAD DRAINS

method was first introduced in surgery by Sampson Handley in lymph obstruction. It has been applied by the author and other s for the purpose of opening up new lymph channels both from rior of the eye and surrounding tissues. The following opera- ve been performed mostly with success, but the cases are as yet ciently numerous to give any definite results except perhaps in of glaucoma.

œdema of the eyelids. The condition for which this is most frequently used is persistent œdema of the eyelid follow- ipelas of the face. It generally affects principally the lower lid, upper may also be involved. The extent of the œdema on the uld be carefully observed, as sometimes it passes right down into k.

ration. A long surgical needle is armed with silk of medium s and is inserted beneath the skin well beyond the area of œdema, preferably well out over the eminence of the zygomal bone. dle is passed into the subcutaneous tissue of the lower eyelid ade to appear through the skin about the centre, 3 mm. below gin. The needle is again entered through the same hole and ownwards and inwards towards the nose and made to appear he area of œdema close to the inner side of the nose; the ends pulled downwards, which draws down the lower lid, and are lose to the skin and the lid pushed back into position, which e ends of the thread disappear beneath the skin. In bad cases al threads may be put in both on the lateral and medial side ain one. In some cases it may be necessary to unite the eyelids irst week after the operation. The upper lid may be drained in way, the silk thread being carried outwards over the temple Persistent chronic œdema of the conjunctiva from lymph ob- rarely gives rise to sufficient trouble to warrant this form of t.

For glaucoma. Mr. Zorab and the author independen applied the operation for the relief of tension in glaucoma, the ic to establish a silk drain between the anterior chamber and the junctival tissue.

The method of procedure is as follows:

Incision. After the instillation of adrenalin, cocaine, and a very large and thick conjunctival flap is turned forwards cornea and dissected up to the limbus. Great care must be t to button-hole the flap in the neighbourhood of the limbus. reason the flap should be dissected off the sclera as cleanly as and the limbus should not be approached too closely, as the co is thinner in that position. With a short Graefe's knife, an about 3 mm. long, is made from the outside into the anterior by gradually cutting through the fibres of the sclera with the kn The incision should start about 2 mm. behind the limbus, and forward, so that the anterior chamber is opened at its periphe easy to tell when the chamber has been opened, by the loss of r to the knife-point or by inserting an iris spatula, which will allo of aqueous to present.

Insertion of the silk drain. A piece of thick silk thread 5 m having a knot at one end, is carefully sterilized, and with a forceps is laid across the incision in the sclera. With a nar spatula, having a rounded notch in the end, the silk is tucked incision. As the silk is pushed forward into the anterior cha knot sticks in the lips of the wound, whilst the free end passes into the angle of the anterior chamber. The conjunctival fla replaced in position, a stitch being inserted if necessary. Th operation can be carried on without emptying the anterior cham is quite easy to perform. The wound in the conjunctiva aft eight hours is usually firmly healed, and the subconjunctival filled with fluid. At first, this usually extends beyond the are conjunctival flap, but after a time it becomes more localised. sion of the eye is usually subnormal for from four days to a we which time it regains its normal tension. In none of the cases been any iritis or undue reaction; the only contretemps was a sl lapse of the iris at the time of operation in one case; this was due to the fact that eserine had not been previously instilled the incision was made rather larger than usual.

The obvious danger in the operation is sepsis. The utmost c be used to avoid it. The conjunctival sac should be bacteric examined, and cleansed four or five times a day with boric lo three days before operation. After turning back the conjunct

instruments should not be used to touch the thread, and the uld not touch the conjunctiva. A thick and extensive covering ıctiva should be made, so that the knot is well buried.

plications. In none of the cases which have been performed uthor has sepsis occurred, nor has the stitch been removed in except one in which it worked out from the eye and lay free th the conjunctiva. In this case it was thought best to remove nsion of the eye still remaining normal after this had been n two of the author's cases the tension subsequently increased hine operations had to be d. On the whole the au- ks that the latter operation ble as a routine measure.

detachment of the This method has been the author with promising or draining the subretinal cases of detachment of the ig. 108). In one case the nt went back into position, w cases have been operated it is at present impos- ay whether a permanent re- accrue. The method of is somewhat similar to that oma. The area of detach- calised, and over the most t part of the detachment njunctival flap is dissected n oblique incision is made the sclera and chorioid. d is then inserted in a manner similar to that described under ion for glaucoma.

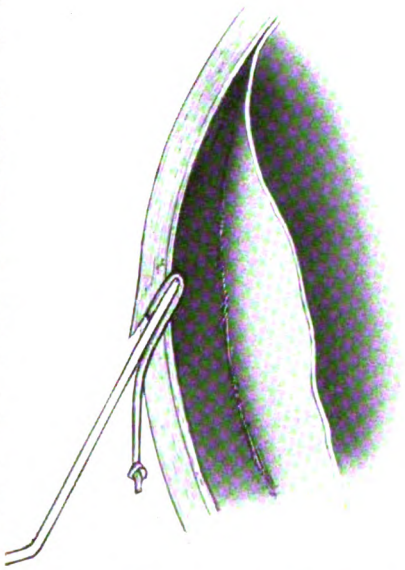

FIG. 108. INSERTION OF A SILK DRAIN INTO THE SUBRETINAL SPACE.

RACENTESIS OF THE ANTERIOR CHAMBER

ations. Evacuation of the contents of the anterior chamber ed for several conditions:

o reduce the tension of the eye when due to an altered con- f the aqueous, as for instance in cyclitis.

o evacuate pus from the anterior chamber following metastatic

To evacuate the anterior chamber in bad corneal ulceration,

especially when associated with hypopyon and tension, or t
the healing of a chronic ulcer such as a Mooren's ulcer.

(iv) To examine the aqueous for organisms in cases of c
lowing operation or of metastatic origin.

(*v*) To evacuate soft lens matter (see p. 213).

The operation is usually performed through an incision d
hind the limbus. In the case of corneal ulceration it is some
formed by dividing the base of the
a Graefe's knife (Sämisch's section
collecting the aqueous for bacterio
amination, a sterile hollow needle w
similar to a discission needle, atta
hypodermic syringe, should be pass
anterior chamber at the limbus an
withdrawn into the syringe by a
(Fig. 109). The spot through
needle is passed is first touched
electro-cautery to ensure asepsis.

FIG. 109. HOLLOW NEEDLE USED FOR PARACENTESIS OF THE ANTERIOR CHAMBER. This is used when it is desired to examine the aqueous humour bacteriologically. Care should be taken to see that the cutting blade is sufficiently wide to take the shaft of the needle.

Instruments. Speculum, fixatio
bent broad needle, iris spatula.

Operation. Under cocaine.
ture is usually made upwards and
unless there be some other special
for its position, such as a mass of
lower angle of the anterior cham
eye is fixed opposite the spot at
puncture is to be made, and the b
needle is passed into the anterior chamber through an incisio
behind the limbus. The needle is then withdrawn and is us
lowed by a rush of aqueous. The remainder of the aqueo
evacuated by pressing the lower margin of the wound wi
spatula. In some cases where a very tenacious hypopyon is
may be withdrawn with the iris forceps. The only complica
to occur is prolapse of the iris into the wound, which should b
with the spatula, or failing that, removed.

OPERATIONS FOR PENETRATING WOUNDS THE GLOBE

Indications. Of all the conditions which a surgeon is c
to see, penetrating wounds of the globe may present the mo
problems as to treatment. The most important factors in t
ment and prognosis are—

1. *The time at which the patient presents himself for trea*

n of the wound are all-important in the prognosis. Thus in
wound which is obviously septic and going to terminate in
itis the eye should be eviscerated.

position and extent of the wound. Formerly it was taught
iliary body were wounded the eye should be excised. The
his was that these injuries were so frequently followed by
ophthalmia, owing to prolapse of the iris and ciliary body.
nerally recognized that sympathetic ophthalmia only follows
d becomes septic, irido-cyclitis with keratitis punctata being
it is only after the latter symptom manifests itself that the
e excised, provided that the wound be not so extensive as
ll chance of recovery from the outset.

ds of the sclera all portions of the uveal tract and vitreous
se should be removed, and the wound closed with sutures
gh the superficial episcleral tissue. Unless the wound be
gnosis is not good, as it is liable to be followed by irido-
f this does not occur, detachment of the retina may ensue,
organization of the exudates in the vitreous.

of the cornea usually result in prolapse of the iris, which
noved in the manner described under iridectomy (see p. 247).

e lens be injured. Unless the wound amounts to little more
tured wound of the globe involving the lens, the prognosis
wound in the lens capsule and the breaking up of the lens
esence of soft matter in the anterior chamber—a condition
rs sepsis and is liable to produce increased tension from
angle of the chamber. In patients under thirty the pupil
ated with atropine and the lens allowed to absorb—assisted
te by needling, when the eye has entirely settled down after
injury. If the patient be over thirty it is often extremely
ecide whether extraction of the lens should be undertaken
of the injury or at a later date. The results of both pro-
very unsatisfactory, and the surgeon should be guided partly
on and extent of the wound. Given these in a fairly favour-
, it is probable that immediate extraction will give the best

e eye contain a foreign body. Usually these are pieces of
ss. The following points should be investigated to deter-
r the foreign body be in the eye:
history of these accidents is usually the same. The patient
with a hammer and chisel, and a piece flies off and strikes
n the case of glass it is usually a mineral-water bottle which

e position and nature of the wound in the cornea and sclera.

(iii) The condition of the anterior chamber—whether e
not.

(iv) The tension of the eye, which may be lowered.

(v) The presence of a hole in the iris.

(vi) The presence of traumatic cataract.

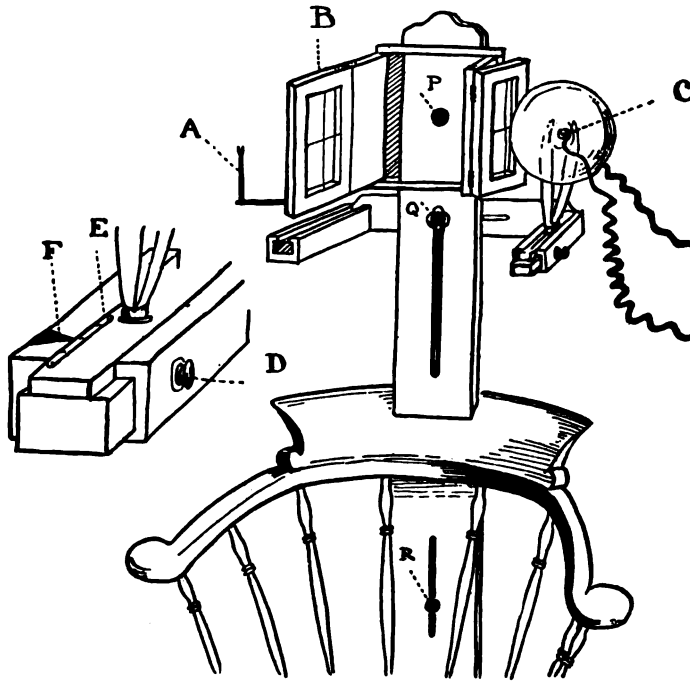

FIG. 110. AUTHOR'S CHAIR FOR THE LOCALISATION OF FOREIGN B
EYE BY THE X-RAYS. A is a rifle-sight for centring the anode, C,
wire, B, behind which the photographic plate is subsequently plac
screw clamping the head-piece on to the patient's head. Q is the scr
lating the height of the tube and the distance from the patient. R
for regulating the height of the head-piece. The inset shows the a
the tube more highly magnified. E is the sliding arm carrying
lateral displacement marked for stereoscopic photographs. F is the
marking the position of the anode. D is the screw for clamping whe

(vii) Whether the foreign body is visible with the ophthal
by focal illumination.

(viii) The localisation of the foreign body by the X-
latter is the most important factor of all, since the foreign bod
right through the globe and be embedded in the orbit.

Operative treatment. If the injury be a recent or
foreign body a metal of magnetizable properties, it is best rem
electro-magnet after localisation by the X-rays (Fig. 110

scopes have been used, but are not so satisfactory. If the foreign body be non-magnetizable, such as a piece of copper cap or manganese steel, an attempt may be made to remove it with forceps after localisation. If the foreign body be embedded in the lens it is often advisable to extract the lens together with it. If the foreign body be of glass, and it be only small, it is usually best left alone, unless capable of easy removal, *e. g.* if it be situated in the anterior chamber; the eye will often tolerate the presence of glass provided it be aseptic.

The eye should be removed—

(i) If the wound be obviously septic.

(ii) If the wound be very large, more especially if the lens be injured.

(iii) If the foreign body be a large piece of metal and cannot be extracted.

(iv) If the eye does not settle down after one of the operations described below, especially if irido-cyclitis with keratitis punctata should have supervened.

If the injury be of long standing. It is of little use as a rule attempting to extract a foreign body from the eye after three days, unless it be loose in the vitreous or embedded in the lens, as it becomes surrounded by lymph. Under these circumstances it is better to leave it alone, or, if it be causing signs of irritation, to enucleate the eye.

ELECTRO-MAGNET OPERATIONS

Magnets for the removal of magnetizable foreign bodies from the eye are of two types—(1) a small magnet, which is inserted into the globe, (2) a giant magnet, which is used to attract the foreign body in the eye from the outside.

Surgeons differ as to which is the best method to employ. The statistical results of both are about the same. Many surgeons in this country, and with them the author, prefer the small magnet, especially of the recent more powerful type (Hirschberg), which runs off the main electric current, for the following reasons; it is more accurate (after localisation by the X-rays), there is less trauma to the globe involved, it is more portable, and, when the foreign body is in the anterior or the posterior chamber, it is much easier to extract it with a small magnet than with a large one.

With the small magnet. Instruments. Beer's knife, fixation forceps, magnet (Fig. 111), and suture. The points of the magnet, which are detachable, are sterilized by boiling.

Operation. The foreign body is first localised accurately by means of the X-rays. If it lies near the wound of entrance the magnet-point is inserted, the electric circuit completed, and the foreign body with-

drawn, the wound of entrance being enlarged if necessary. eign body lies at some distance from the wound, as for inst vitreous, an antero-posterior incision is made in the sclera, a as possible, by plunging the knife through the conjunctiva and the former having previously been drawn to one side so as valvular opening. The size of the incision should be such tha mit the point of the magnet and allow the foreign body to co size of the foreign body being judged by the X-ray photogra the knife has been withdrawn, the point of the electro-ma serted and the circuit closed, the magnet drawn with the foreign body attached t conjunctival wound is closed by a suture sary. If the foreign body be situated in t or posterior chamber or the lens, an incisio made into the anterior chamber with a ke point of the n serted, and th body withdrawn in which the fo is deeply embed lens, more es patients over t

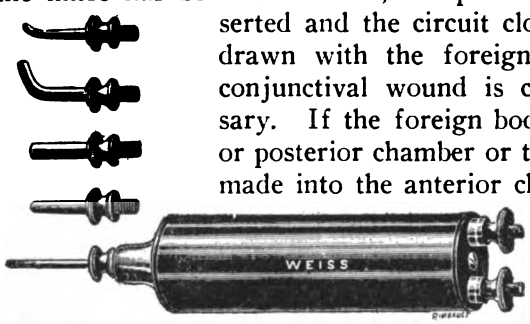

FIG. 111. SMALL ELECTRO-MAGNET FOR EXTRACTING PIECES OF STEEL FROM THE EYE. It is made to work direct off the electric main.

of age, extraction of the lens together with the foreign body performed.

Complications. *Immediate.* Failure to extract the fo may arise from—

1. The foreign body being embedded in lymph. It is t the utmost importance that the operation should be performed possible after the injury.

2. The foreign body being deeply embedded in the scler the magnet will not exert sufficient traction to withdraw it.

3. The foreign body being non-magnetic (all steel is not

4. Too small a wound being made for its extraction, being wiped off on the edges of the wound as the magn drawn.

5. Insufficient power in the magnet.

Remote. 1. Panophthalmitis, which must be treated b tion.

2. Irido-cyclitis; if this be prolonged, and keratitis punct enucleation should be performed.

3. Traumatic cataract; this may subsequently require n

4. Detached retina as the result of organisation in the vi may occur months after the original injury.

the giant magnet. The foreign body should have been ocalised by the X-rays, and its position and size determined, nay be removed by the shortest possible route and with the nt of injury to the

nents. Giant magnet 2), steel spatula. and magnetizable uld be removed from tient and the surgeon).

tion. Under atropine ne. The patient is at in a chair some three ont of the magnet, the ng held apart by the the electric circuit is he patient's head is ually advanced towards et. If a foreign body in the eye and be mag- the patient will usually his head or cry out with the foreign body may ulging forward the iris e posterior chamber. position it may be re- manipulating the head relation to the magnet withdraw it into the an- mber, from whence it is through the entrance an incision at the lim- by the giant magnet pplied to the wound or



FIG. 112. GIANT ELECTRO-MAGNET. The current is turned on by means of the foot pedal.

tizing a steel spatula which is inserted into the anterior cham- onnected with the magnet by a flexible steel cable. The small reviously described may be used, or the foreign body removed of iris forceps.

ce of steel in the vitreous always travels round the posterior f the lens and through the suspensory ligament, and does not lens capsule.

lications. These are similar to those described under the gnet operation.

CHAPTER V

OPERATIONS UPON THE CORNEA AND CONJU

OPERATIONS UPON THE CORNEA

REMOVAL OF A FOREIGN BODY FROM THE CORN

Removal of a foreign body from the cornea requires a (focal illumination). The use of a binocular lens is also Foreign bodies lodged on the surface of the cornea can be rem under cocaine with a spud. If the foreign body be deeply e the cornea, a fine sterile discission needle should be used. W eign body, such as a chip of iron, is deeply embedded, the ne be inserted slightly to one side of the entrance wound and pas the foreign body so as to lift it from its bed. When the foreig partially penetrated the anterior chamber but still lies in the incision should be made with a keratome at the limbus and body pushed back through the entrance wound with the aid spatula. If the foreign body be iron, the electro-magnet ma and in this case should be tried before resorting to an inci anterior chamber. A stain is left frequently after the remo eign bodies; this should be removed as far as possible. S the eye should be bandaged for a few days and bathed with b Atropine should be instilled if there be any signs of infiltrat the wound.

CAUTERIZATION OF THE CORNEA

Either a chemical or the actual cautery may be used.

Indications. *Corneal ulceration.* The cornea being dense, organisms do not penetrate very deeply into its substa destruction of the bacteria is effected by cauterization of th portion of an ulcer; the albumin is also coagulated and so presented to their advance.

Operation. The eye is thoroughly cocainized, and th portion of the ulcer is first defined by staining with fluoresci away the excess of stain with boric lotion.

By a chemical caustic. Liquefied carbolic (carbolic a liquefied in 10% of water) is applied upon a sharpened m

excess should be removed so as to prevent its running on to the cornea. A speculum is inserted and the cornea is dried by blotting with cigarette paper; the stained area is lightly touched with the point of the stick, particular attention being paid to the spreading margin. A dense white plaque is the result; this usually clears up in a few days. Atropine ointment is applied daily to the conjunctival sac.



FIG. 113. ELECTRO-CAUTERY.

By the actual cautery. The electro-cautery (Fig. 113) point should be extremely fine and only raised to a dull red heat. The stained area should be touched lightly with the point.

The actual cautery is best for serpiginous corneal ulcers, carbolic acid being more satisfactory for those of the vesicular type.

OPERATIONS FOR CONICAL CORNEA

Indications. Since the operation for conical cornea is not without serious risks, it should only be undertaken when the vision cannot be improved with glasses to $\frac{6}{18}$; high + or — cylinders will often yield satisfactory results. The object of all forms of operation is the flattening of the cone.

Operation. This may be carried out either by excision of the apex of the cone or by cauterization.

Excision of the apex of the cone is probably the more satisfactory method, although it is somewhat more difficult to perform. The object of the operation is to remove an elliptical portion of the whole thickness of the cornea from the apex of the cone, the long axis of the ellipse being placed horizontally. It leaves the eye with only a minute scar as compared with the nebula produced by the cautery, which is often so great as to require an optical iridectomy to restore vision.

Instruments. Speculum, fixation forceps, a narrow Graefe's knife, straight iris forceps, and scissors.

The operation is done under cocaine, atropine having been previously instilled.

First step. The apex of the cone is transfixed by the Graefe's knife with the blade directed slightly upwards and forwards, the knife being made to cut out. The cornea in this situation is extremely thin, being

often not more than 1 mm. in thickness. The length of
should not exceed 2 mm.

Second step. The flap of corneal tissue thus made is sei
straight iris forceps and removed with iris scissors, produ
elliptical opening. The chief difficulty of the operation is t
the corneal flap, which is most difficult to hold; care must
to injure the lens capsule with the iris forceps or scisso
cornea has collapsed as the result of the evacuation of
chamber. The eye should be firmly bandaged subsequen
patient kept in bed until the anterior chamber has re-formed

Complications. *Slow re-formation of the anterior cha*
anterior chamber will often take two or three weeks to re-
to the hole in the cornea not closing. During this time the
to septic infection and therefore the greatest care should
keep it aseptic when dressing it. For this reason and also
following complications are due to the same cause, it is
remove as little corneal tissue as possible in performing t
It is probable that conjunctivoplasty (see p. 269) would
facilitate the rapid closure of the wound.

Anterior polar cataract may result from prolonged co
lens with the wound in the cornea. As a rule this seldo
much with vision.

Anterior synechiæ from incarceration of the iris in the
sionally result and may require subsequent division.

Acute glaucoma is by no means an infrequent complicat
the author has seen four successive cases of conical cornea,
both by excision and by the cautery, followed by this
It is probably due to adhesion of the root of the iris to the
cornea during the time the anterior chamber is empty. It
be relieved by an iridectomy, or trephining the sclera.

The electro-cautery operation. The operation generall
known as the target operation. It consists in surrounding
the cone with two rings of cautery marks, the outer made
heat, the inner with the point slightly brighter, whilst the ap
ized at a red heat, so that rings of different depth are obtain
ization of the apex should stop just short of perforation, t
being deeper than the outer. With this method secondary g
anterior synechiæ are not so liable to occur. On the oth
optical iridectomy has to be performed more frequently.
geons still cauterize the apex of the cone until a perforation
This latter operation seems to have the disadvantages of b
and the advantages of neither.

REMOVAL OF TUMOURS INVOLVING THE CORNEA

ours which involve the cornea are usually secondary to tumours g at the limbus. The chief of these are: *simple*—dermoid moles of the limbus; *malignant*—sarcoma, endothelioma, epi-. Dermoid patches should be shaved off as close to the cornea ble; the white area left after their removal can be improved by .

gnant tumours in very early stages may be removed locally with and forceps, the cautery being applied to their base, since they end to invade the sclera deeply.

TATTOOING THE CORNEA

cations. (i) To do away with the blinding effects of light a scar after iridectomy has been performed (see p. 236).
To simulate a pupil on a white scarred cornea.



FIG. 114. TATTOOING NEEDLES.

peration is not without risks, as it may light up old inflamma- a previously quiet eye. Panophthalmitis and sympathetic ia have both been known to follow it. The pricking of the ay carry in epithelium and implantation dermoids may arise.

uments. A fine single needle is generally used, occasionally of needles (Fig. 114).

ration. Under cocaine. Chinese ink, sterilized and prepared ng up with 1–6,000 perchloride of mercury, is smeared over the e tattooed. Multiple punctures in an oblique direction are then o the cornea over the area desired. More paste is then rubbed is area. The cornea should be intensely black after the opera- certain amount of the ink is carried away by phagocytosis and of the epithelium. Subsequent reaction may be reduced by an iced compress. Atropine should be instilled.

SCRAPING CALCAREOUS FILMS

reous films, when not associated with active irido-cyclitis, may ed with advantage to the vision. Care should be taken to see eratitis punctata is present before the operation is undertaken.

uments. Speculum, fixation forceps, a spoon which should have blunt edge.

Operation. Under cocaine. The area is very lightly s
the spoon. The calcareous changes are in the deeper la
epithelium and the anterior elastic lamina, and hence are eas
The scraping should be carried well beyond the apparent m
film. The epithelium often takes some time to regenerate.
the results are satisfactory, although the film is apt to recur i
of years, but it may be removed again if necessary.

OPERATIONS UPON THE CONJUNCTIV

THE REMOVAL OF FOREIGN BODIES

Foreign bodies lodged in the conjunctival sac, unless e
the conjunctiva, are usually found by the surgeon under th
the subtarsal sulcus being a favourite situation. They are eas
with a spud or needle, after the instillation of a drop of
solution. Subsequently the eye should be bandaged for a
until the effect of the cocaine has passed off, as in wiping
patient may wipe off the epithelium of the cornea whilst it i
from the cocaine.

In order to evert the upper lid the patient is made to lo
down, the eyelashes are seized between the thumb and foref
left hand, the skin of the upper lid is pushed down abov
cartilage with the thumb of the right hand, and the lid is
pulling it upwards against the point of the thumb.

OPERATION FOR PTERYGIUM

Indications. A pterygium should be removed when
across the cornea, especially when the pupillary area is b
volved. The operation of ablation is the one now generally

Instruments. Speculum, straight iris forceps, small sh
scissors.

Operation. Under adrenalin and cocaine the neck of th
is seized with the forceps and the body and neck are carefu
from the conjunctiva. The body and neck should be ve
separated right up to the corneal margin by means of
scissors. The head is then stripped off the cornea with a
The wound in the conjunctiva should be subsequently close
sutures, otherwise the disease will certainly recur. In strippi
from the cornea some of the epithelium may be torn off wi
usually regenerates without impairing the vision.

EXPRESSION

n operation for the removal of follicular formations in the and is used more especially in trachoma.

nts. Graddy's forceps (Fig. 115), fixation forceps.

on. The operation may be performed under cocaine and ittle solid cocaine being rubbed into the area to be expressed. ses in which both eyes are affected, and in small children, æsthetic may be necessary.

a number of instruments are in use, perhaps the best, and least painful, is Graddy's forceps. In the case of the upper ted, one blade of the forceps being passed into the fornix, ing placed over the upper surface of the everted lid. A



FIG. 115. GRADDY'S FORCEPS.

ly pressure is applied, and the lid is drawn out between the this way as much of the conjunctiva is gone over as is neces- lower fornix is best expressed by picking up the loose fold of with ordinary forceps and then expressing with Graddy's. one or two follicles be present, they can be picked up with the ne dissecting forceps and expressed, but when situated on the follicles are best enucleated with a spud; a solution of 1 in 50 of mercury in glycerine is then rubbed into the conjunctiva. tion may have to be repeated several times as new follicles

CONJUNCTIVOPLASTY

nctivoplasty is an operation for the transplantation of a flap ctiva to cover some loss of substance or defect in the continuity be.

ations. The operation may be necessary—

To close large recent wounds of the cornea.

To close the wound made by the excision of a cystoid scar.

To facilitate the healing of a clean ulcer such as Mooren's ulcer, er the aperture made by an ulcer that has perforated.

(iv) In the treatment of conical cornea by excision o the cone, it might facilitate the rapid closure of the wound flattening of the cornea.

Operation. *First method.* Under cocaine. A flap o is raised from around the limbus, having its base as near t covered as possible; its breadth should be one and a half tin of the area to be covered. This flap is drawn across the cornea and stitched to the conjunctiva on the other side made in raising the flap should be allowed to heal by gran

The stitches holding the flap in position cut through in days, but by that time their purpose will have been served. be still adherent to the wound its base may be divided an fluous tissue removed; the remainder will disappear rapidly

Second method. The conjunctiva is dissected up a cornea as close to the limbus as possible, and backwards as sertion of the recti. A purse-string suture is then inserte margins and drawn tight so that the whole cornea is cov junctiva. The operation is suitable for cases in which larg to be covered.

REMOVAL OF TARSAL CYSTS

The tarsal glands being embedded in the tarsal plate, present both on the conjunctival surface and towards the contents are always evacuated from the former.

Instruments. Walton's iris knife, sharp spoon.

Operation. Under adrenalin and cocaine. The eye and a drop of the solution is injected into the cyst with syringe. A vertical stab is made into the cyst with the k contents are then evacuated with a sharp spoon.

Difficulty may arise in fixing the cyst whilst making this is best obviated by holding the everted lid between th thumb.

In some cases, when the cyst has persisted for a consi the sac-wall becomes so thickened that it has to be dissecte the mass in the lid will disappear.

CHAPTER VI

IONS UPON THE EXTRA-OCULAR MUSCLES

SQUINT OPERATIONS

ons. Operations upon eyes with concomitant squint are
or two purposes:
cosmetic reasons, to remedy a deformity due to a squinting
amblyopic.
rectify the muscular equilibrium in alternating or latent
nat binocular vision may be regained.
e operation is performed for the latter reason the adjustment
y have to be much more accurate than for the former, so as
it the superimposition of the images falling on each macula.
cular balance is interfered with by the administration of a
thetic, and therefore the results cannot be gauged accurately.
esirable that operations upon the ocular muscles should be
nder local anæsthesia. This is usually possible, except in
ery small children.
nd after the operation muscular equilibrium is tested by
electric light fixed to the ceiling immediately over the head
t (see Fig. 57). The room is darkened and the patient is
k at the light. In a case with an amblyopic eye the reflec-
ght should appear in the middle of each cornea if the eye be
usted. In cases where good vision is present in both eyes
rod test should be used, the rod being placed before the
g operated on; the bar of light produced by the rod should
n or within a few inches of the light if the adjustment has
ned accurately.
lons of the recti muscles are inserted into the globe at the
istances from the corneo-scleral junction: medial, 5 mm.;
nm.; lateral, 7 mm.; superior, 8 mm. Each muscle is held
expansions on either side of the tendon as well as by the
nsertions. Division of these expansions allows a greater
f the muscle and is, therefore, to be undertaken when a con-
gree of squint has to be overcome. On the other hand,
e a danger that the muscle may not regain a proper attach-

ment to the globe if division be too freely performed, and the opposite direction may result; proptosis also may be cau It is, therefore, better to combine tenotomy with advancem degrees of squint over twenty degrees convergent and in constant divergence. This is usually better than performing in the other eye, as there still remains the muscle of the reserve to tenotomize if necessary, if the advancement be in correct the squint. Further, it is much easier to rectify a mu by accurate tenotomy than by advancement. Division of th the medial rectus only, without its expansion, will usually of latent convergent strabismus with a deviation of about (Maddox test). Cases of latent divergent strabismus of abo (Maddox test) require complete division of the tendon of rectus, and, in some cases, of the expansion as well. Teno superior rectus for hyperphoria should only be undertaken i that is to say, of over 12° prism, any lateral deviation bei rected, as occasionally the correction of the lateral deviatio when this is due to the faulty insertion of a muscle, wil correct the hyperphoria present.

Partial tenotomies are performed by some surgeons for tion of latent muscular errors, but the experience of most in is that little benefit is gained unless the tendon be complet Tendon-lengthening by various methods has been performed, come into general use.

After all operations upon the ocular muscles both eye occluded to keep the eyes at rest whilst the muscle is gaini attachment to the globe; this usually takes about seven days, time both eyes should be uncovered, and if there is a tend vergence atropine should be used. Glasses correcting any fraction should be worn.

TENOTOMY

Tenotomy may be performed by (1) the open, or (2) junctival method.

Instruments. Speculum, straight blunt-pointed scissors hook, needle and silk, needle-holder.

Operation. The operation is performed under ad cocaine.

1. *By the open method.* The surgeon stands on the righ the patient when dividing the right lateral or the left m but at the head of the table when dividing the right media lateral rectus.

step. The speculum is inserted and the patient is made to look
m the muscle to be divided. The conjunctiva is freely divided
with scissors directly over the insertion of the tendon into the
ee Fig. 116) and dissected backwards.
d step. The tendon of the muscle is then seized with fixation
nd button-holed about its centre as close to the globe as possible
7). The lower blade of the scissors is then passed through the

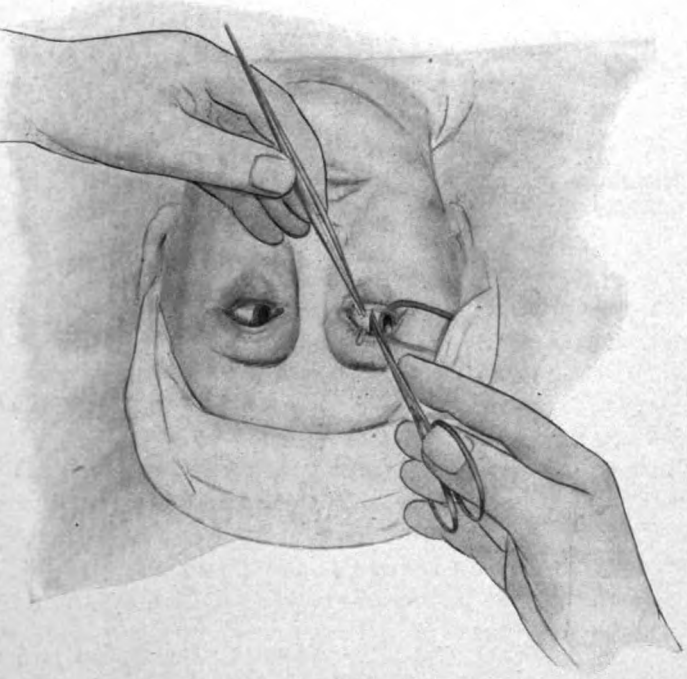

6. TENOTOMY. Showing the method of holding the scissors and the position of the hands.

he tendon, and the rest of the tendon and its expansions are
upwards and downwards to the extent required to bring the eye
as tested by its appearance or by the Maddox rod test. The
us hook may be inserted, both upwards and downwards, to see
tendon is properly divided, but all pulling on the muscle with
should be avoided, as it is painful and disturbs the muscular
um. The conjunctiva is then brought together with a fine silk
If the squint be over-corrected by the tenotomy, a deep hold
e taken with the stitch so as to draw the eye back into position.
y the subconjunctival method. This is unsatisfactory in that

accurate adjustment by division of the expansion of the
is not possible. It is painful, and is sometimes followed
some hæmorrhage into the bulbar fascia. Occasionally it
in some cases of amblyopic eyes where a small wound is d
conjunctiva is button-holed below the tendon, and separ
surface of the muscle. The bulbar fascia is then oper
tendon, a strabismus hook is passed through the opening

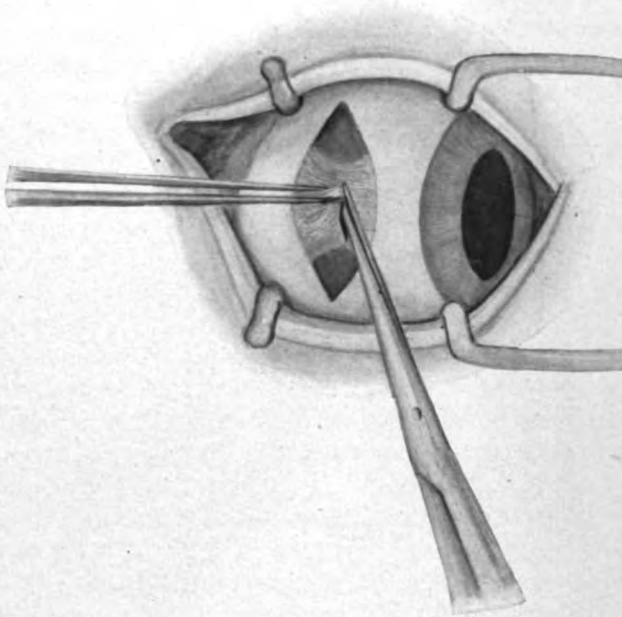

FIG. 117. TENOTOMY BY THE OPEN METHOD. The tendon
holed about its centre and the expansions are then divided upw
wards to the required extent.

cavity against the globe, and is then rotated upwards benea
which is subsequently divided between the hook and the gl

Complications. These may be immediate or remot

Immediate. 1. *Hæmorrhage into the bulbar fascia,* lea
proptosis, only occurs when the subconjunctival method is
a rule, the hæmorrhage ceases on the application of pres
sionally it may be necessary to open up the wound and
blood-clot.

2. *Perforation of the globe* has been known to occ
division of a tendon in an obstreperous patient. It should
a wound of the sclera (see p. 259).

flammation of the bulbar fascia very rarely occurs, but may lead
g down of all the extra-ocular muscles and defective movements
obe. Panophthalmitis has been known to follow this condition.

ote. 1. *Failure to correct the muscular error.* If the error be
nust be rectified by tenotomy of the corresponding muscle of the
or by the advancement of the opposing muscle of the same eye.
uld not be undertaken until five or six weeks have elapsed since
ous operation.

ver-correction of the muscular error at the time of the operation
remedied by stitching the tenotomized muscle forward to the
quired to bring the eye straight. Advancement of the tenot-
muscle should be performed if the over-correction be only
d after the operation. In cases with binocular vision lesser
of deviation may be corrected with prisms if they are causing
s, while small errors of over-correction of about 3° prism,
appear after the first few weeks.

efective movement in the tenotomized muscle is usually present
irst week or two after the operation, but recovery usually takes
er the muscle has regained its attachment to the globe; it may
however, to a slight extent; this is most liable to occur after
sion of the tendon and its expansion (more especially in the
he lateral rectus), or because the tendon has not been divided
ugh to the globe. In patients with previous binocular vision
is present after the operation on turning the eyes towards the
e as the tenotomized muscle, but this usually disappears.

granulation may form at the site of the tenotomy wound. It
ue to a tag hanging from the wound or to a portion of a stitch
been imperfectly removed. It should be snipped off with
nd the conjunctiva drawn together over its base.

roptosis may result from too free a division of a tendon.

etraction of the caruncle is best avoided by closing the con-
wound with a stitch, and thus pulling the caruncle forward.

ADVANCEMENT

ncement is an operation undertaken to rectify a squint by form-
sh attachment for one of the ocular muscles nearer the cornea,
e same time shortening it. There are three main types of oper-
formed:

he capsulo-muscular, in which the tendon, together with the
nt of the bulbar fascia to it, is advanced.

he tendon only is isolated, shortened, and advanced.

he tendon is shortened by folding it upon itself.

The first operation is by far the most satisfactory of to the fact that a broader new insertion of the muscle is obt is less likely to yield subsequently; it is the operation usuall in this country.

The chief cause of unsatisfactory results after advance tions is the cutting through of the sutures holding the tendor The various operations, which are some fourteen in numb mostly their respective surgeon's name attached, differ princ method of insertion of these sutures. Whichever method sutures be used, the main factors which aim at preventing from cutting out are (1) that the stitches should take a goo scleral tissue and stump of the divided tendon on the cornea wound, for the passing of which it is most essential that should be sharp; (2) that complete rest of the muscles shoul by bandaging both eyes for the first seven days after the op



FIG. 118. PRINCE'S FORCEPS FOR ADVANCEMENT. Care should see that the spring catch holds satisfactorily.

that the opposing muscle should be tenotomized so as to pre on the sutures.

Of the many operations that have been devised the capsu advancement or some modification of it is most frequently

Instruments. Speculum, straight scissors, fixation forc advancement forceps (Fig. 118), four sharp needles and needle-holder.

Operation. Under adrenalin and cocaine. *First ste* tient is made to look away from the side on which is the r advanced, and the conjunctiva over the muscle is freely c scissors, by a curved incision with the convexity towards the dissected back.

Second step. The bulbar fascia is button-holed by a sr well above or below the tendon. A tenotomy hook is pas the tendon and its expansion and brought out through a s the bulbar fascia on the opposite side of the tendon. The s of Prince's forceps is then inserted in place of the hook, an with its expansion is grasped between the blades. The force

ant, who should avoid all traction on the muscle. The eye ed in the direction of the muscle to be advanced, and tenot- opposing muscle is performed by the open method.

ep. The muscle to be advanced and its expansion, which between the blades of Prince's forceps, are separated from ith the scissors and given again to the assistant to hold. g silk sutures are passed in the following order, middle, ower, first through the conjunctival and episcleral tissue and e tendon on the corneal side of the wound and then as far ible through the muscle and out through the conjunctiva near gin on the other side of the wound (Fig. 119). Care should

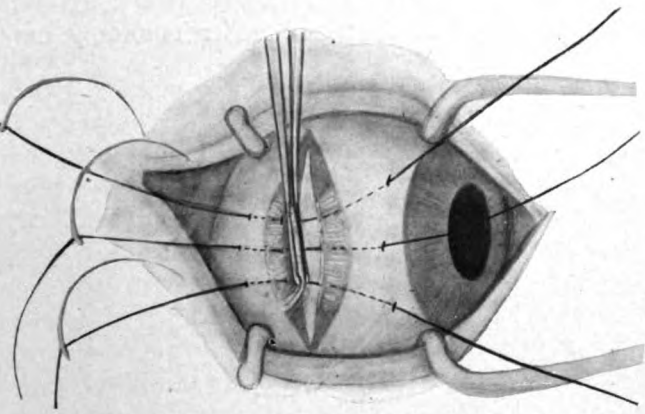

ADVANCEMENT BY THE THREE-STITCH METHOD. Showing the sition. A firm hold on the sclera to the corneal side of the wound o the success of the operation.

at the middle stitch is passed through the episcleral tissue osite the horizontal plane of the cornea and the central por- tendon. The portion of the tendon and capsule within the e forceps is then removed with scissors by cutting close to the he Prince's forceps, taking care not to cut the sutures.

step. The middle suture should be first tightened to the ired to bring the eye straight. The upper and lower sutures ed.

esting with the Maddox rod, the error be found to be slightly ted by the advancement, the eye can be drawn back by taking with the conjunctival stitch over the tenotomy wound. The l stitch may be removed on the fourth day, but the stitches advanced muscle in position should not be removed till after ay. Atropine in both eyes is desirable, especially when there

is any tendency to convergence. Glasses should be worn on
the eyes.

Complications. 1. *The eyes may not be straight after*
tion. No further operation for rectification should be undert
least two or three months. If there be a tendency to converge
should be worn and atropine used. Small latent errors may l
by prisms. *If the muscular error be insufficiently correcte*
may be performed on the other eye. *If the muscular error b*
rected it may also require tenotomy on the other eye, the adj
tenotomy being more accurate than that by advancement.

2. *Thickening over the site of the advanced muscle* usu
pears in a few months.

Other complications as described under tenotomy may
p. 274).

CHAPTER VII

LEATION OF THE GLOBE AND ALLIED OPERATIONS

principal substitutes for simple enucleation are evisceration, and Frost's operations.

ENUCLEATION

cleation is the removal of the globe from the bulbar fascia.

ications. Enucleation should be performed in preference to operation in—

Malignant tumours.

Injuries followed by cyclitis.

Painful blind eyes.

malignant tumours enucleation should only be performed when e no signs of extra-ocular extension. If extra-ocular extension nt, evisceration of the orbit should be performed, provided there vidence of general metastasis. In cases of glioma of the retina ecially desirable that the optic nerve should be cut as far back ible and the cross-section carefully examined for gliomatous ince the disease spreads to the brain along this structure.

njuries followed by non-suppurative cyclitis enucleation or Frost's on is preferable to Mules's operation, since cases have been re- of sympathetic ophthalmia following the latter operation, and it is ses of non-suppurative cyclitis which are especially prone to give hat disease.

d painful eyes, especially when affected with glaucoma, are best d, as occasionally the underlying cause, when not known, may be an intra-ocular growth.

ruments. Speculum, fixation forceps (two pairs), straight scis- rabismus hook, strong curved scissors.

eration. Before the anæsthetic is administered the forehead be marked over the eye to be enucleated, so as to guard against dent of removing the wrong eye. It is usual, at any rate in the hospital patients, to get their written consent for the operation.

t step. The speculum is inserted. In the case of the right eye junctiva is seized with the fixation forceps downwards and

laterally, or, in the case of the left eye, downwards and med straight scissors being held with the right thumb and ring conjunctiva is divided freely all the way round, as close as the cornea, and dissected back.

Second step. The bulbar fascia is opened below the lat by grasping it with forceps and button-holing it with the scis strabismus hook is passed through the opening made in the bu capsule with its concavity against the globe, turned upwards l tendon, and the latter is pulled well forward and freely di above downwards between the hook and the globe. The su inferior recti are treated in a similar manner. In dividing rectus, a small portion should be left attached to the glol subsequently grasped with rotate the glol when dividing nerve.

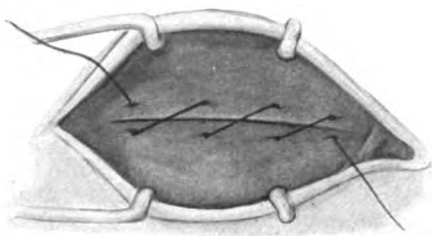

FIG. 120. ENUCLEATION. Method of suturing the conjunctiva; the suture requires no knot.

Third step. is dislocated b lids by opening lum widely and backwards. I will not dislo either because are imperfectl or the palpebral aperture is too small to allow of its delivery is liable to be the case in small children or in those with matous globe. In such cases the palpebral fissure should b by dividing the lateral canthus.

The fourth step is the division of the optic nerve. Th rotated strongly laterally, either by pulling on the tendon of rectus or by pulling the globe outwards with the finger; the is felt for by passing the strong curved scissors behind the glo the nerve is defined the blades are opened widely, pressed and the nerve divided. The globe is then pulled forwar finger, and the oblique muscles and remaining attachmen Hæmorrhage is easily controlled by pressure and the use of a

Fifth step. When the bleeding has ceased, the conjunct is united in a horizontal direction by means of a thick silk sut over and over; no knot is required and the ends are left lo it may subsequently be removed easily (Fig. 120). The usua are applied with a firm pressure bandage for the first six h

should be removed at the end of the seventh day. No artificial ould be worn for at least six weeks after the operation, and then or a few hours at a time until the conjunctiva becomes accustomed It should always be taken out at night.

omplications. These may be immediate or remote.

mediate. *Cutting into the globe.* This may occur during the on of the optic nerve, and is usually due to imperfect dislocation of obe. Although of little consequence as a rule, it may be extremely s, as for instance in the case of an intra-ocular growth, when it is vable that a portion of it might be left behind. If this accident l happen, the portion of the sclera and chorioid left behind should efully sought for and removed.

dhesion of the bulbar fascia. Eyes that have been the subject of inflammation are much more difficult to enucleate, owing to on of the surfaces of the bulbar fascia. In these cases the globe actically to be dissected out of that structure.

emote. *Hæmorrhage* into the stump may occur, leading to prop- of the conjunctiva and extravasation into the eyelids and beneath in of the face. The use of a firm pressure bandage and the omis- f the suture is usually sufficient to prevent this occurring, but the clot may have to be turned out and the bleeding-point sought for gatured.

anulations and polypi in the socket are usually the result of leaving tag of tissue between the margins of the wound, and are therefore likely to occur when no suture is used to close the wound. They l be removed with forceps and scissors.

olypoid masses sometimes form in a socket as the result of an fect artificial eye causing an œdematous condition of the conjunc- They should not be removed, owing to the contraction caused y, but the artificial eye should be left out, when they will often ear.

ontracted socket is usually the result of an imperfectly performed ation or loss of large portions of the conjunctiva; for the opera- for its relief, see p. 285.

EVISCERATION

isceration is the removal of the intra-ocular contents.

dications. It is the ideal operation for a suppurating globe; se cases enucleation is contra-indicated because the lymph-space the optic nerve is opened up by the division of the latter and the mation may spread directly to the meninges.

Instruments. Speculum, fixation forceps, Beer's knife scoop, and stitches.

Operation. A general anæsthetic is necessary.

First step. The eye is transfixed about 4 mm. behind t scleral junction with a Beer's knife, which is made to cut ou (Fig. 121). The flap of corneal and scleral tissue is then s forceps and the cornea removed entirely by completing the the sclera round it with scissors (Fig. 122).

Second step. The contents of the globe are then evis means of a spoon, and the cavity flushed out with 1 in 4,000

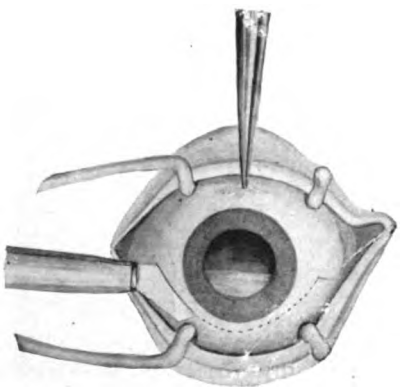

FIG. 121. MULES'S OPERATION. *First step.* Excision of the cornea.

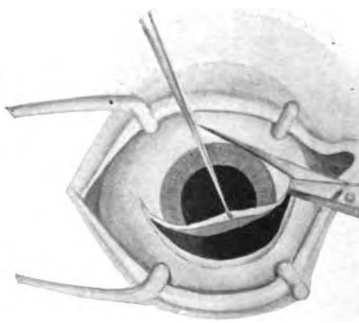

FIG. 122. MULES'S OPERA completion of the excision of with scissors.

of mercury lotion. Great care should be taken to remove all the uveal tract; this is best ensured by visual inspection after t rhage has ceased. The interior of the sclera should appea white.

Third step. Although not absolutely necessary, and ina the case of a septic globe, a single suture may be passed th centre of the wound in the conjunctiva and sclera.

Complications. As the operation is not infrequently for panophthalmitis, much swelling of the lids and discharge socket may take place after the operation; these symptoms u side in the course of a few weeks without further trouble. T which must elapse before an artificial eye can be worn is c longer than after enucleation.

MULES'S OPERATION

operation is the insertion of a celluloid globe into the sclera
ration, followed by closure of the scleral wound over it. In
nd Frost's operation a better stump is formed, so that more
may be obtained in the artificial eye which is subsequently
the inserted globe.

tions. (i) The operation is especially suitable for anterior
following ophthalmia neonatorum. In young children the
f the ball in the orbit assists the development of that

is also suitable for large, recently made, fairly aseptic wounds
e.

tion. The *first two steps* are the same as for evisceration.
tep. A glass or, better, a celluloid or gold-plated ball is in-
the sclera, which is closed over it by two rows of interrupted
e of catgut passing through the sclera, the other of silk closing
njunctival wound. To facilitate the closure of the conjunc-
l it is advisable to dissect the conjunctiva back from the limbus
sing the cornea. The ball inserted in the sclera should fit the
ly.

ications. In about 17 per cent. of the cases the ball is not
his is not infrequently due to too large a size being used, or
nd being imperfectly closed by the sutures. If two rows be
scribed above, extrusion of the ball is far less frequent than
be inserted. If the globe be extruded the patient is in the
on as if he had had evisceration performed.

FROST'S OPERATION

operation the eye is enucleated, a celluloid globe is inserted
lbar fascia, and the conjunctiva is closed over it by means of
sing through the bulbar fascia and the conjunctiva.

tion. The *first four steps* in the operation are similar to
ibed under enucleation.

tep. A small, loosely-fitting glass globe is inserted into the
ia. A purse-string suture of strong catgut is then inserted
t margin of the bulbar fascia, taking care to include in the
cut ends of the tendons of the recti muscles. The suture is
and tied so that the bulbar fascia and the muscles are thereby
the globe. The conjunctival wound is closed over this by a
ture of silk.

The advantage of this operation over the other substitute enucleation is that it can be used after any enucleation. Th advantages are that the globe is sometimes extruded unless be carefully closed by sutures, and occasionally it may becom from the bulbar fascia beneath the conjunctiva, thus pre artificial eye from being worn, and requiring removal. Thes tages are largely done away with if the method of sutur above be used.

OPERATIONS UPON THE SOCKET AFTER REMOVAL OF THE EYE

PARAFFIN INJECTION

Indications. Occasionally after an eye has been re movements in the socket are not communicated sufficiently t cial eye which is placed over it, so that the glass eye has a fi appearance. As a rule, this can be remedied by the use of improved eye, which has a rounded posterior surface and fits the stump. If this be not satisfactory, the injection of para stump will often improve the movements considerably. Th should be made by what is known as the 'cold method.'

The 'cold method' of paraffin injection is by far the factory, for the following reasons:

(*a*) The temperature need not be so high, and no dama fore done to the tissues.

(*b*) It is more easily regulated.

(*c*) Embolism is less likely to occur.

Instruments. Fixation forceps, tenotomy knife, speculu paraffin syringe, and a short needle having a big bore.

Operation. This may be performed under adrenalin a

First step. The stump is drawn forwards with forceps omy knife, inserted well to the lateral side of the stump, is freely round and a pocket is formed in the centre of the orbit the injection can be made. The tenotomy knife is then with

Second step. The sterile melted paraffin (melting-poin should be poured into the syringe, which should have been kept in a hot-water bath. The paraffin is then allowed to until it just becomes opalescent. The injection should be ma the hole made by the tenotomy knife, sufficient paraffin being obtain the desired result. The operation is usually follow siderable swelling of the tissues, which will subside in thr weeks.

OPERATIONS FOR THE RESTORATION OF A CONTRACTED SOCKET

result of wearing badly-formed artificial eyes or of subsequent ation in the conjunctival sac, the socket not infrequently becomes acted that the prosthesis cannot be retained. Enlargement of nay be obtained by two methods:

Skin-grafting (Thiersch's method).

Transplantation of skin from the surrounding structures (Max- eration).

SKIN-GRAFTING

cations. This procedure is especially suitable for cases in e base of the socket opposite the palpebral aperture has to be , and it is usually performed prior to Maxwell's operation for ration of the fornices in severe cases.

uments. Scalpel, speculum, skin-grafting razor, probes, and a thick style wire.

ration. *First step.* The base of the socket is freely divided zontal direction opposite the palpebral aperture so as to produce wound.

nd step. This gaping wound is put on the stretch in the follow- A thick piece of style wire is bent round to fit into the fornices cket, the ends being brought out over the lid at the inner canthus. le of wire is opened out as far as possible so as to put the wound ttom of the socket on the stretch to its fullest extent.

l step. Skin grafts are then cut from the medial surface of the plied by means of probes, and pressed down on to the raw No dressings should be applied directly to the grafts, atch-glass may be placed over the palpebral aperture and dress- lied over it. The style wire should be removed on the fourth

INCLUSION OF FLAPS. MAXWELL'S OPERATION

cations. It is especially useful for the enlargement of the the formation of new fornices. As a rule it is performed for oduction of the lower fornix, as it is frequently due to the ion of this cul-de-sac that the artificial eye cannot be retained. ration, however, may be modified and applied to the formation of upper and outer culs-de-sac.

uments. Scalpel, forceps, scissors, and sutures.

ration. A general anæsthetic is required.

step. An incision is made in the lower fornix throughout its

whole length and carried downwards for a distance of about
(Fig. 123).

Second step. A crescentic piece of skin is marked out
lid by two incisions which have their concavity directed up
upper one is parallel with the margin of the lower lid and a
metres below it. This crescentic flap is then dissected
deeper tissues all round, except for a small pedicle at its
123, B).

Third step. The incision forming the upper margin of t
piece of skin is deepened until it meets the incision made i

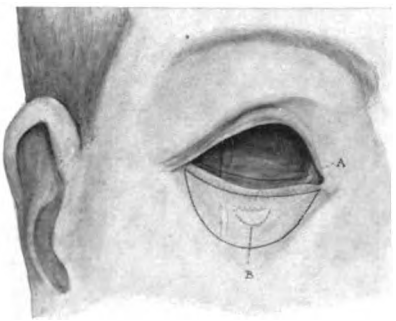

FIG. 123. MAXWELL'S OPERATION FOR CONTRACTED SOCKET. *First step.* A is the incision through the conjunctiva. The flap of skin from the outer surface of the lower lid is entirely raised from the subcutaneous tissue, except for the pedicle B, which holds the new fornix in position.

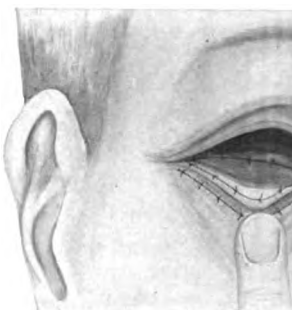

FIG. 124. MAXWELL *Final step.* Showing th from the outer surface lid turned in to form t fornix. The surface w closed by sutures.

so that the lower lid is converted into a band of tissue atta each end.

Fourth step. The upper margin of the incision in th stitched to the upper margin or concavity of the crescentic after the latter has been displaced upwards beneath the ba carrying the lashes, and the lower margin of the crescentic is stitched to the conjunctival edge of the band, so that th piece of skin is folded on itself and forms the new lower f held down in its position by the pedicle (Fig. 124). The su be of catgut, as their subsequent removal is somewhat diffic

Fifth step. The surface wound is closed by silkworm The socket should be packed with gauze, or else a piece should be inserted, as in the previous operation, so as to groove in the new lower fornix.

CHAPTER VIII

OPERATIONS UPON THE EYELIDS

SURGICAL ANATOMY

ε eyelids consist of well-marked planes of tissue, which are, from inwards—

Skin with very little subcutaneous fat.

Orbicularis oculi muscle.

The tarsi, which are attached to the orbital margins by the tarsal ts and which thereby form a barrier to the passage of infection rds into the orbit.

Subconjunctival tissue and conjunctiva.

s most important for successful results that flaps and incisions be made accurately down to and in the correct layer of the lid.

ng the lid margin, between the eyelashes and the posterior border eyelid, is a white line (intermarginal line) formed by the edge of us. In the many operations in which the lid is split the incision ed along this line.

blood-supply to the eyelids is derived from arterial arches—two op lid, and one in the lower—which run parallel to the margins. as possible, therefore, flaps should be planned with their bases at ngles to the course of the vessels. The extreme vascularity of the ether with the small amount of subcutaneous fat, allows of almost e detachment of flaps of skin without fear of necrosis, but at the me every care should be taken to avoid injuring these flaps when dating them. Hæmorrhage is controlled during the operation by of clamps or by direct pressure of the lid between the finger and As a rule a general anæsthetic is required for most of the ons.

SUTURE OF WOUNDS OF THE EYELIDS

unds which involve the skin only are brought together in the y way with a few fine sutures. In wounds of the upper lid care be taken to suture the levator palpebræ, if divided, as otherwise tic ptosis may result.

ure of wounds involving the lid margin.

In *simple division* the margins of the lids are brought together by

means of a fine suture; the conjunctival surface is first app
and then the skin by a deep suture which includes the tarsus.
apposition of the lid border is very essential. Unfortunatel
amount of ectropion frequently follows, which may require f
one of the operations given below (see p. 308).

(*b*) *Occasionally the lid margin carrying the lashes may*
As a rule, the strip remains attached to the lid. It shou
accurately sutured in position, taking care that the lashes
correct turn outwards. In cases where the strip is torn off e
skin and conjunctiva should be sutured together. When lar
of the lid are lost, some form of plastic operation, such as is
for making a new lid, is required (see p. 311).

(*c*) *When the canaliculus has been divided* the end atta
lacrimal sac should be sought for and divided for a sho
inwards from the wound (see p. 315), the entrance being kept
by a probe to prevent traumatic stricture.

OPERATIONS FOR ANKYLOBLEPHARO

Fusion of the eyelids together is either a congenital co
the result of injury, and may take the form of bands or fi
union. It is rarely complete and is often associated with sym
The union should be divided on a director, or by careful dissect
care not to wound the underlying globe. The raw surface
apart by daily dressing until they are covered by epitheliun
ternal dressing should be applied.

OPERATIONS FOR SYMBLEPHARON

Partial adhesion of the lid to the globe in which a few
from the lid to the globe are best treated by division followed b
the ocular conjunctiva over the raw surface; no external dres
be applied. Any tendency to fresh adhesion may be prevente
inspection.

In extensive adhesion of the lid to the globe, where the l
tirely adherent to the globe and the cornea is destroyed, inte
inadvisable. In less extensive adhesion, the lid is first sepa
the globe, reunion being prevented by covering the denuded a
globe with a flap of bulbar conjunctiva transplanted from an
does not come in contact with the raw surface on the eyeli
operation), or by Thiersch's grafts from a situation where th
hairs; or by grafting mucous membrane from the mouth of the

Teale's operation, or some modification, is by far the most ry, but unfortunately it cannot always be carried out when the njunctiva is large.

RATIONS UPON THE PALPEBRAL APERTURE

CANTHOPLASTY

cations. In contraction of the palpebral aperture, either due genital condition, or the result of a wound, trachoma, or other contraction.

uments. Speculum, forceps, scissors, and three sutures.

ration. The speculum is inserted and opened as widely as One blade of the scissors is passed into the cul-de-sac at the gle of the lid and the palpebral aperture enlarged by dividing canthus horizontally. The lateral tarsal ligament which is itudinally is then cut across with scissors passed into the upper r wound. The conjunctiva is drawn up into the wound and to the skin at the margin to prevent reunion. The stitches removed about the sixth day.

CANTHOTOMY

notomy is simple division of the lateral canthus without stitching nctiva into the wound. It is useful in some cases of blepharo- sociated with fissure at the lateral canthus.

CANTHORRHAPHY

n of the eyelids, usually at the lateral canthus.

cations. (i) When the eyelids do not cover the globe as of—

) Cicatricial contraction of wounds, burns, &c., about the lid.

) Long-standing facial paralysis.

) Exophthalmic goitre.

To help maintain the lid in position after ectropion operations.

uments. Beer's knife, fixation forceps, spatula, and sutures.

ration. *First step.* The position for the new lateral canthus nined by holding the lids together at the lateral canthus, and is on the upper and lower lids. From these points incisions are outwards to the lateral canthus along the intermarginal line in and bottom lids. These incisions are deepened to about 5 es.

nd step. From the medial end of the incision in the lower lid l one is made downwards for about 5 millimetres, and is then

carried out to the lateral canthus. The tissue thus marked the lashes, is then removed.

Third step. A corresponding, slightly larger, area is moved from the u junctival surface lid (Fig. 125).

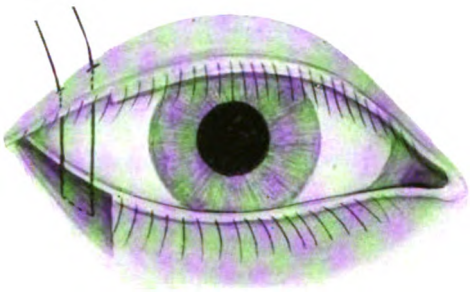

FIG. 125. CANTHORRHAPHY.

Fourth step. areas are brought tion by means suture passed th centre. The sut have a needle at and these should from the conjunc and brought out middle of the raw lower lid, about 2 millimetres apart, and then through the r raw area in the upper lid and out through the skin. The s so that the two raw areas are brought into accurate appo margins of the wounds may then be brought together by sut sary. The main suture should be left in for at least ten da

TARSORRHAPHY

Indications. (i) Complete union of the eyelids may when an eye has been removed and for some reason an cannot be worn.

(ii) Partial union is effected in cases of paralysis of the of the fifth nerve when corneal ulceration threatens. A sim also useful in keeping the lower lid in position during th cicatrization in many of the operations for ectropion desc The adhesions produced can be subsequently divided when has ceased.

Instruments. Knife, forceps, scissors, spatula.

Operation. *Complete.* As narrow a strip of tissue removed from the lid borders behind the eyelashes. This formed by everting the upper lid and shaving off the post with a sharp knife; the lower lid is then treated similarl areas are brought into apposition with fine sutures.

Partial. When only a temporary adhesion is requir ectropion operations, it is sufficient to make raw correspon about 2 millimetres on the posterior margins of the top an on either side of the central position of the cornea and uni sutures, which may be removed about the end of the first w

PTOSIS OPERATIONS

ollowing operations are usually only undertaken for congenital t they are occasionally required for the paralytic and traumatic All the operations are far from satisfactory, and should only aken when the lid covers the pupil completely or so nearly ead has to be thrown back to see objects directly in a line with The relative value of the various operations apart from their s is a matter of opinion amongst ophthalmic surgeons; there- arious types of operations which are performed are given below. are four types of operation, which respectively aim at—

ortening the eyelid by excision of a portion of the tarsus.
tachment of the lid to the epicranius muscle.
lvancement of the levator palpebræ muscle.
afting of part of the superior rectus muscle into the lid to take of the levator palpebræ superioris.

NING THE EYELID BY EXCISION OF A PORTION OF THE TARSUS

us's operation (modified). The object of this operation ten the eyelid by removing the superior portion of the tarsus, argin of which is subsequently sutured to the tendon of the lpebræ and the septum orbitale.

esults of the operation are satisfactory, especially in cases in ere is some movement in the eyelid. The author, who has l most of the ptosis operations on several occasions, has had form results by this method, the modification of which was ested to him by Mr. Treacher Collins.

the advantage that the amount of retraction required may be ily estimated, the corneal complications are of much rarer e, and the resulting scar forms a natural fold in the lid. It sly not applicable to cases in which the eyelid is already short, cases of 'Chinese eye' in which little can be done beyond the palpebral aperture.

ments. Spatula, scalpel, artery and dissecting forceps, scissors, es.

ation. *First step.* The spatula is inserted into the superior A curved incision is made directly below the orbital margin ut its whole length. The skin and orbicularis muscle are nd dissected downwards so as to expose the upper surface of . A suture is then passed through this flap so that it may be wn by an assistant.

d step. A narrow strip about 3 millimetres broad is excised

from the whole length of the tarsus; in doing this, care
not to button-hole the conjunctiva or flap of skin.

Third step. The cut margin of the tarsal plate is s
levator palpebræ and palpebral ligament by two sutures
following manner: A thick catgut suture armed with a
is passed through the upper cut margin of the orbicularis o
ligament, and levator palpebræ (if the latter be present)
junction of the middle and inner thirds of the wound, a fi
taken on these structures. The needle is then passed throu
parallel to the lid border for a distance of about 3 millim
again on to its anterior surface. The needle is then
through the levator palpebræ, palpebral ligament, and orb
upper part of the wound. A similar suture is passed abou
of the middle and outer thirds of the wound. When bot
in position they are tied sufficiently tight to produce the
the lid desired, slight over-correction being necessary. Th
is then closed with sutures.

ATTACHMENT OF THE LID TO THE EPICRANIUS

There are three chief methods of effecting this attachm

(*a*) By cicatricial bands (*e.g.* Hess's operation).

(*b*) By a suture left permanently in position (*e.g.* Ha
tion).

(*c*) By the attachment of the skin of the lid to the
Panas' operation).

Indications. In the majority of the cases of congen
levator palpebræ is completely absent, as shown by the wa
movement in the lid, and it is for this condition that one of
of this type is performed. In rare cases the epicranius
absent or imperfectly developed, and in these cases the
should not be undertaken.

Hess's operation. The object of this operation is
stitches between the eyelid and the epicranius muscle,
them in long enough for a fibrous band of union to fo
stitch tracks.

Instruments. Scalpel, dissecting forceps, needle and h
artery forceps.

Operation. *First step.* The eyebrow having been sh
cision 2 inches long is made about in the line of the brow,
is dissected down almost to the lid margin.

Second step. Three sutures are passed, one in the mi
at each end of the lid; each suture carries two needles.

ed in the intermarginal line of the lid about 3 millimetres brought out into the wound above, so that the lid margin is ıe loops. These threads are then carried deeply beneath the e of the wound into the substance of the epicranius muscle, ut through the skin well above the eyebrow, and tied over a rainage tube. The sutures should be drawn tight enough to ı undue amount of retraction of the lid, as this tends to drop r removal of the sutures. The skin wound is then closed and a ssing is applied to cover the drainage tube on the forehead. self should be covered with a celluloid shield, as it is usually im- or the patient to close the palpebral aperture, and the cornea is e injured by exposure. The deep sutures should be left in for ree or four weeks, so that they may bring about a fibrous band ıe muscle and the eyelid by their irritation. The immediate re- e operation is usually excellent, but the lid is very apt to drop ıe course of six months or a year after removal of the stitches.

ıan's operation. The aim of this operation is to insert tal chain between the epicranius and the lid, the chain being ınently in position. The operation has not yet been performed y often to allow any definite statement about the final results e.

esults have not been very satisfactory in three cases in which has performed this operation.

ments. A 4-inch straight surgical needle, to which is attached ire chain such as is used by spectacle-makers to attach glasses ess. It measures about 0.75 millimetre in diameter. It is o the needle by a soldered ring or by means of a piece of silk oped through the needle without a knot.

ation. Under a general anæsthetic. 'The method of implant- hain will be followed readily by reference to Fig. 126. The dle is inserted above the lateral angular process at A, is passed and with a slightly upward inclination deeply beneath the the forehead, to be withdrawn at B; as much of the chain is rough as desired. The needle is reinserted at B, passed beneath close to the orbital margin and through the tissues of the lid re it is withdrawn and the chain after it. In like manner it is om C to D through the substance of the tarsus and withdrawn. returned from D to E above the brow and withdrawn, and ngth embedded above the brow from E to F, which is just above al angular process. The chain should be buried completely ched evenly between the points A, B, C, D, E and F; and by he loop BCDE should be adjusted at B and E; when the lid is

at the desired height the slack at B and E is taken up b
A and F.

'The position of the points E and B is of importance;
situated in the region of the most effective elevation of
contraction of the frontalis muscle, as determined by expe
the commencement of the operation (and they should b
above the eyebrow).

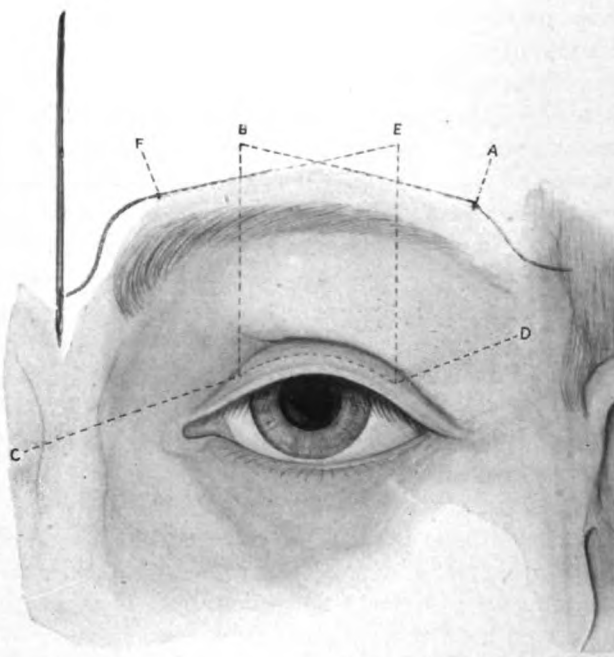

FIG. 126. HARMAN'S OPERATION FOR PTOSIS.

'The lengths of chain lying buried above the brows fr
E to F, and the angles A B C and D E F, are arranged so that
cient holding power to prevent the subsequent drop of th
not prevent adjustment to forcible traction on the lid until t
chain have become interwoven and surrounded by the gr
nective tissue. This growth should be sufficiently vigoro
of a week to securely fix the chain against all the force of t
orbicularis muscle. (In one case in which the author remo
after two weeks there was no connective tissue in the lin
easily withdrawn.) Until this time the free ends of the ch
turned towards each other over the skin of the brow and

by a cotton-wool and collodion dressing, after which time the s, A and F, are cut off and the free extremities pushed beneath

as' operation. In this operation a direct adhesion of the skin l to the epicranius muscle is aimed at.

uments. Lid spatula, scalpel, dissecting forceps, scissors, sutures.

ration. Under a general anæsthetic.

step. An incision, 2 inches long, is made in the line of the d an incision of a similar length is made into the skin of the ut half an inch . The tissue be- ese two incisions rmined so as to a band of skin ocutaneous tissue. e ends of the lower vertical incisions de into the lid, slightly laterally dially respectively the lateral and anthus (Fig. 127).

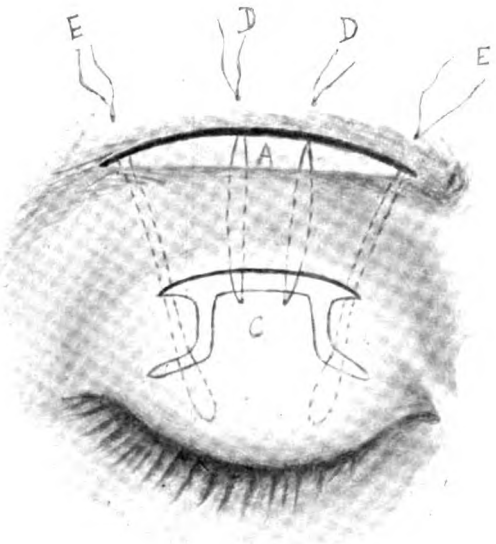

FIG. 127. PANAS' OPERATION FOR PTOSIS.

nd step. The flap, 127), thus pro- raised, and doubly sutures, DD, are hrough its upper nd are carried be- e band of skin and eous tissue. The re then carried deeply beneath the upper margin of the wound ne substance of the epicranius muscle and brought out on to nead. Outer and inner sutures, EE, are passed deeply into the e of the tarsus; both ends are then passed beneath the band and through into the upper wound, whence they are passed beneath r margin of the wound into the epicranius muscle and are tied iece of drainage tube. They hold the lid in position during ess of cicatrization. Considerable over-correction should be l as the lid tends to drop subsequently. No dressings should be over the open palpebral aperture. The stitches are removed on day. A small depression is usually seen where the skin of the s beneath the band.

ADVANCEMENT OF THE LEVATOR PALPEBRÆ MU

This is especially suitable for cases in which the levat has some power, that is to say, when there is some movemer present. It is also suitable for cases of traumatic and para The movement of the lid by the levator palpebræ is best e eliminating the action of the epicranius by holding down th asking the patient to raise the lid.

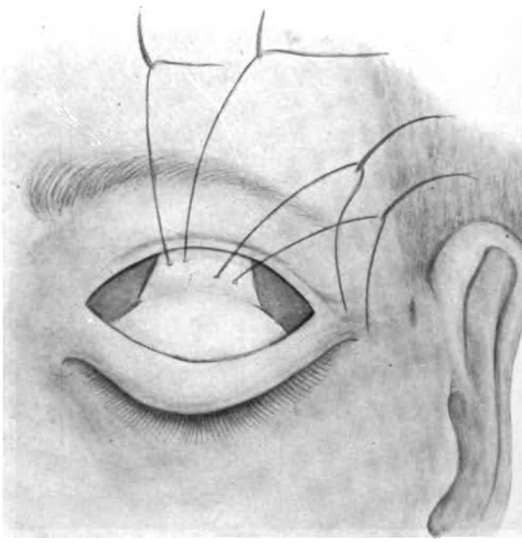

FIG. 128. PTOSIS OPERATION. ADVANCEMENT OF THE LEVATO Showing the suture passed through the tendon; the difficulty of the to find it. (*Diagrammatic.*)

Instruments. Lid spatula, knife, forceps, scissors, suture

Operation. Under a general anæsthetic.

First step. A spatula is inserted into the upper conjunct An incision is made just below the eyebrow over the up of the tarsus throughout its length. The skin, especially o margin of the wound, is dissected up and the orbicularis mus the tarsus with the superior palpebral ligament attached to orbital margin being exposed. The superior palpebral ligan divided carefully high up near the orbital margin, and directl a small quantity of fat, will be found the tendon of the levat

The tendon can usually be distinguished from the palpebral by the fact that it is en pulled on.

l step. The advance- the muscle is then l in one of the three ways: (*a*) by excis- rtion of the tendon ing the divided ends (*b*) detaching the rom the tarsus and it from behind for- rough a hole made pper margin of the and suturing it on ior surface towards margin; (*c*) by fold- endon on itself. The hod is the one most performed. Two su- h a needle at each passed through the of the muscle and . 128). The ends of tures are then car- vnwards between the and the orbicularis d out in the inter- line of the eyelid. ures are then tied o as to secure rather an the amount of re- required (Fig. 129). The palpebral ligament and orbicularis then united and the wound in the skin is closed.

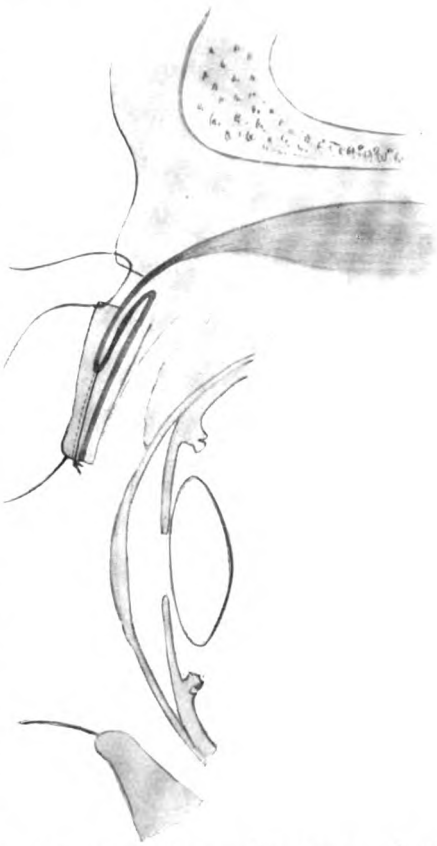

FIG. 129. PTOSIS OPERATION. ADVANCEMENT OF THE LEVATOR PALPEBRÆ. *Showing sutures in position.* The tendon is shortened by folding it on itself.

NG A PORTION OF THE SUPERIOR RECTUS INTO THE LID

ais' operation. Indications. This operation is performed for ptosis in which there is partial or complete loss of upward move- the lid. In cases of congenital ptosis the superior rectus is not ntly absent or imperfectly developed, as is shown by the defective movement of the eye. It need hardly be said that it is most t to see that the superior rectus is well developed before under-

taking the operation. Vertical diplopia always follows t
and therefore it is advisable only to undertake it when
bilateral, a similar operation being performed on both sid
somewhat hypothetical objection is that during sleep the
rolled upwards by the superior recti so that the lids are s
but this occurs in almost all successful ptosis operations.
there is some defective upward movement of the eye after t

Instruments. Speculum, straight strabismus scissors,
needle-holders, and stitches.

Operation. A general anæsthetic is desirable in all cas

First step. The superior rectus is exposed through
incision in the conjunctiva, as in the first stage for advanc
tendon is defined in the wound and a strabismus hook pa
it; its middle portion is isolated and two silk sutures, w
at each end, are passed through it and tied.

Second step. The speculum is removed and the eyelid
pulled upward by means of a retractor or two silk stitches pa
the substance of the lid. Starting from the middle of th
conjunctiva of the fornix is divided backwards and the u
of the tarsus is exposed.

Third step. An incision is carried above the tarsus pa
near its upper border well into the substance of the orbicula
the other side. The needles on each end of the doubly a
holding the isolated portion of the superior rectus muscl
through the hole and are carried downwards between th
muscle and the tarsus to near the lid margin, where they are
through the skin and tied over a piece of drainage tube
junctival wound is closed by sutures.

Complications. *Ulceration of the cornea* is more lik
after those operations in which the lid is much over-retrac
Hess's, Panas' operation, and the advancement of the levat
It usually affects the lower corneal margin and may be merel
and opacity of the epithelium or deep septic ulceration. If t
be severe, the sutures holding the lid in position should be t
the eye treated as for corneal ulceration; on the other
abrasion of the epithelium will often heal without taking out
As a prophylactic measure a stitch may be passed throug
lid and fastened to the brow, pulling the lower lid upwa
cornea and so affording it a protection.

Sepsis. The difficulty of keeping the wound aseptic afte
ations is considerable, and not infrequently inflammation ma
provided it does not go on to suppuration, the final result
thereby; should suppuration take place the sutures must be r

CHAPTER IX

ATIONS FOR ENTROPION, REPAIR OF THE EYELIDS, TRICHIASIS, AND ECTROPION

operations commonly performed for entropion and trichiasis are types:

Operations for the destruction of the individual hair follicles.
Rectification of a faulty curvature of the tarsus.
Transplantation of the lash-bearing area.

ELECTROLYSIS

ications. In cases of trichiasis where a few eyelashes turn e conjunctiva or cornea they may be removed by this method.

eration. A platinum electrolysis needle (negative pole) is alongside each lash into the follicle, and a constant current of milliamperes allowed to pass for a half to one minute. There ly some bubbling seen around the hair, which will fall out when if the operation has been properly performed. It is a compara- ainless operation and free from scarring if the hair follicle be not ted by the needle. This is best ensured by using a rather blunt nd not turning on the current until the needle is in position.

SKIN AND MUSCLE OPERATION

ications. This operation is especially suitable for the senile or forms of entropion of the lower lid, not infrequently seen after ndaging in old people, which has failed to yield to treatment by the lid outwards with strapping.

ruments. Straight scissors, fixation and entropion forceps.

eration. Adrenalin and novocaine solution is injected beneath of the lower lid. A horizontal strip of skin as near the lid mar- ossible is seized with the entropion forceps (Fig. 130) and re- by one snip of the scissors. The underlying orbicularis muscle is noved over the same area and the wound closed with sutures. If pronounced result is required, a vertical piece of skin is removed uter end of the previous wound and allowed to granulate.

RECTIFICATION OF A FAULTY CURVATURE OF THE TARSUS

DIVISION OF THE TARSUS FROM THE CONJUNCTIVAL SURFACE OF THE LID

Burow's operation. The object of this operation is to evert the inverted tarsal edge of the lid by dividing the tarsus from the conjunctival surface, and it is especially suitable for those cases in which the whole of the upper lid border is buckled inwards to a slight degree owing to cicatricial contraction such as is often seen in the late stages of trachoma and occasionally as a congenital deformity in the lower lid.

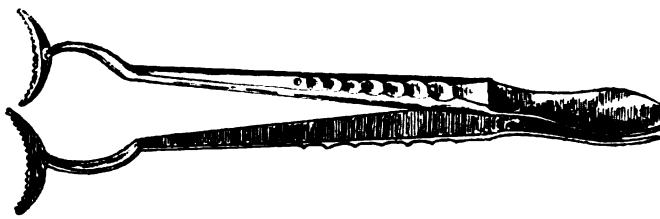

FIG. 130. TREACHER COLLINS'S ENTROPION FORCEPS.

Instruments. Lid spatula and Beer's knife.

Operation. The operation is performed under a general a

First step. The lid is everted over the lid spatula. An incision is then made along the white line, the result of cicatricial contraction, in the sulcus subtarsalis about 3 millimetres behind the upper lid margin; the incision should extend throughout the whole length of the lid, and completely divide the tarsus. Care should be taken that the cut is made at right angles to, and not obliquely through the tarsus. When the lid is replaced the lid margin will be found to lie in its proper position.

Second step. If the skin of the upper lid be very lax and a marked result be desired, an elliptical piece of skin may be removed from the upper lid above the site of the underlying incision, the wound stitched together so as to exaggerate the outward curve of the lashes; this is usually desirable in most cases, since there is a tendency for the lid to become inverted again owing to the contraction of the wound, which is allowed to heal by granulation.

DIVISION OF THE TARSUS FROM THE ANTERIOR SURFACE OF THE LID

Streatfeild's operation. The object of this operation is the removal of a wedge-shaped piece of the tarsus directly beneath the lashes throughout the length of the upper lid. The division

ıe outside, and the wound is subsequently sutured so that the of the lid is everted. It has the advantage over the previous ɔn that no granulating area is left to cicatrize; it is especially for cases in which there is much buckling inwards of the upper



FIG. 131. LID CLAMP.

and yields most satisfactory results even when the deformity is

ruments. Beer's knife, fixation forceps, lid clamp (Fig. 131), and sutures with a glass bead threaded on each.

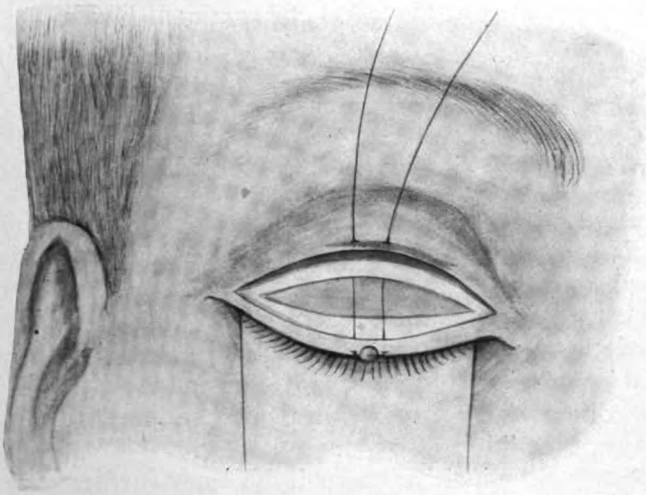

FIG. 132. STREATFEILD'S ENTROPION OPERATION.

eration. The operation is performed under a general anæsthetic. *t step.* The lid is fixed in a clamp. The surgeon makes an in the skin directly above the lash-bearing area throughout the ength of the lid and parallel to its margin. A second incision about 3 millimetres above this, and its extremities are curved

downwards to join the first. The piece of skin and orbi between them is removed and the tarsus is exposed.

Second step. A wedge-shaped strip is removed fro throughout the whole length of the lid, the apex of the w just through the ta the conjunctiva on i face.

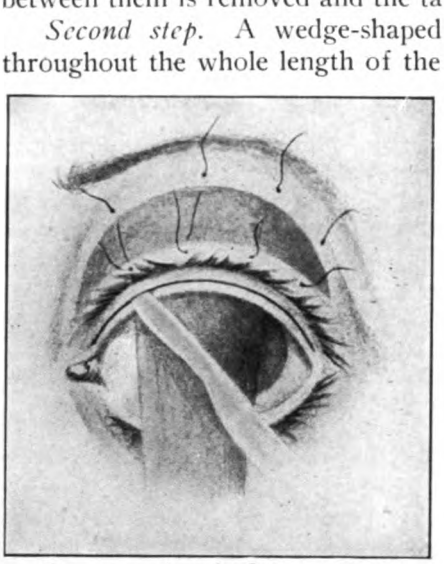

FIG. 133. ARLT'S OPERATION FOR TRICHIASIS.

Third step. Ma are then inserted. should have a needle A bead may be thr stitch to prevent it cu lid margin. The passed from the mar directly above the ey 3 millimetres apart, out through the low the wound. They a from within outward tarsus plate and the of the wound, being through the skin about half an inch above it and tied (few points of suture in the skin may be added if necessary

THE TRANSPLANTATION OF THE LASH-BEA

Arlt's operation. Indications. The operation is sui of trichiasis in which part or the whole of the lashes of turn inwards and rub on the surface of the cornea.

Instruments. Beer's knife, forceps, scissors, sutures,

Operation. *First step.* A lid clamp is applied to An incision is made in the intermarginal line and the tarsus the lash-bearing area for a depth of about 5 millimetres t whole extent of the lid (Fig. 133).

Second step. An incision through the outer surface o the lashes is made to meet the other at right angles, so t are carried on a band of tissue attached at each end.

Third step. A semilunar piece of skin is then remove incision above the last, joining it at the outer and inner band carrying the lashes is stitched to the upper margin o the line of the incision along the intermarginal zone behin allowed to heal by granulation. The subsequent contr

pulls down the band carrying the lashes to a certain extent. refore, desirable to pull the band of lashes upwards at the time tion to a greater extent than is required for the final result in overcome this tendency for the condition to re-form as a result icial contraction of the granulating area. In order to obviate ricial contraction some surgeons cover the area with a graft of membrane.

ECTROPION OPERATIONS

opion may affect the upper lid, but it occurs far more frequently wer. Operations undertaken for its relief vary very consider- the following reasons:

he cause of the ectropion. The active or cicatricial form re- ifferent and more extensive operations than the passive form, occurs after facial paralysis, senile ectropion, or that occurring pharitis.

he degree of ectropion, whether it is partial, affecting merely the in; or complete, affecting the whole lid.

opion of the lower lid is always accompanied by epiphora, owing ant of application of the canaliculus to the lacus lacrimalis. The us is also apt to become obliterated as the result of marginal is. Before undertaking any of the operations described below, dition must be remedied, either by dilating the canaliculus or g it inwards for a short distance (see p. 315), otherwise, even peration be successful in restoring the deformity, the overflow causes the patient to pull down the lower lid constantly in hem away, and this tends to reproduce the condition.

r many of the operations a temporary tarsorrhaphy is required to lid in position during the process of cicatrization. The tem- ands produced by this operation are so placed on either side of ea as not to interfere with vision altogether. Canthorrhaphy is rable in some cases, especially when the ectropion affects the d of the lid.

deformity to be overcome in ectropion is not only the turning s of the lid; in cases which have existed for any length of time order becomes permanently elongated and requires to be short- ore it will keep in position. The exposed conjunctiva, espe- cases secondary to blepharitis, becomes thickened near the lid and, though it may regain a more or less normal appearance lid has been replaced in position, the thickened margin pre- prevents the proper apposition of the canaliculus, and in these s often desirable to remove this tissue (see Fergus's operation).

OPERATIONS FOR PASSIVE ECTROPION

Snellen's suture method. The object of this op to pass sutures through the lower lid from rather above th eversion out on to the cheek, so that when tightened they up into position. The inflammation which occurs aroun leaves a permanent band of cicatricial tissue which contin of the sutures after they have been removed.

Indications. Snellen's sutures are useful in moderate senile form of ectropion in which there is not much thic lid margins. Although the results are satisfactory in car cases, the operation with considerable pai liable to be followed inflammation along tracks; indeed, the fi not very satisfactory inflammation does oc



A B

FIG. 134. SNELLEN'S SUTURES.
A. A suture in position.
B. The suture tightened.

Instruments. Tw sionally three, sutu silk, armed at eith 3-inch straight needle

Operation. A g thetic is desirable, alt solutely necessary. T longing to each stitch about 3 millimetres ap conjunctival surface a of the everted lid, and after passing deeply near the lower the posterior surface of the tarsus, they are brought out on down and tied over a piece of drainage-tube. The loops, tight, draw the lid margin inwards (Fig. 134). Two of are usually required at such a distance apart as to divide into thirds. They should be left in place some two or thre

Fergus's operation. This operation consists in ex apex of the everted lid.

Indications. It is a most satisfactory operation for c the lid margin has undergone thickening from blepharitis of slight senile ectropion.

Instruments. Beer's knife, fixation forceps, and scissors.

Operation. Under adrenalin and cocaine, a little solid rubbed into the conjunctiva. A strip of thickened conjunc

val tissue corresponding to the apex of the eversion is removed whole length of the lid (Fig. 135). The wound produced is th sutures. The pull of the conjunctiva, which is stitched to rgin, is sufficient to draw that structure inwards into position.

t's operation (modified). The object of this operation is val of a triangular piece of conjunctiva and tarsus from the the lower lid, the base of the triangle being placed towards nargin of the lid so as to produce sufficient shortening of the lid border to hold it in position. The he lid is also shortened by removal of a r portion at the lateral canthus.

ations. It is especially suitable for cases tic ectropion (lagophthalmos) and severe f senile ectropion of the lower lid.

uments. Lid spatula, Beer's knife, scissors, and sutures.

ation. A general anæsthetic is required.

step. The lower lid being held between the d thumb is split in the intermarginal line e lateral two-thirds of its length, and the leepened till the lower border of the tarsus d. For this purpose some surgeons use a ratome instead of a Beer's knife.

FIG. 135. FERGUS'S OPERATION FOR SLIGHT ECTROPION OF THE LOWER LID. Showing the lines of the incision.

d step. A triangular piece of conjunctiva whole thickness of the tarsus are removed centre of the lower lid, the base of the eing towards the free margin of the lid and sufficient length to produce the shortening o bring the lid up into position (Fig. 136); st estimated by making the incision forming the medial limb of l overlapping the lateral flap until the lid is pulled upwards into

step. A triangular piece of skin with its base upwards is ex- n the lateral canthus in the following manner (Fig. 136).* An s made outwards and slightly upwards from the canthus. A ncision, twice the length of the preceding one, is made directly ds from its lateral end to the lateral canthus, and the lower end then joined by an incision completing the triangle. The skin out by this triangle is then dissected up and removed. The ing of the flap formed by the skin and subcutaneous tissue of part of the lid is continued inwards until the flap, when pulled lace, restores the lid to its proper position.

Fourth step. The lid is sutured into position. The V-
in the conjunctiva and tarsus is sutured, the knots being
conjunctival surface with the exception of the suture at t
which is turned the other way, the ends being brought ou
skin of the outside flap, after the latter has been sutured in
the two ends tied over a bead. The outside flap of skin
into position by a suture at its upper angle. As the result
eyelashes project beyond the lateral canthus; these shoul
Additional sutures to hold the flap in position are then in
eyes should be bandaged after the operation, otherwise th
conjunctiva may rub on the cornea.

FIG. 136. MODIFIED KUHNT'S OPERATION FOR SEVERE ECTROPION. *Second step.* The lateral half of the lid is split and a V-shaped portion of the tarsus removed. The triangular piece of skin at the lateral canthus is entirely removed.

FIG. 137. MODIFIED
ERATION. *Fourth step.*
sutures in position. T
of the lid has been u
dissected up. The V-sh
tissues is sutured first.

Argyll Robertson's operation. The operation a
ening the border of the lower lid and at the same time pulli
into position by means of a strap of skin and subcutane
from the outer side, the attached end of the strap being f
outer portion of the skin of the lower lid.

Indications. It is especially useful for paralytic cas
subsequent measure to the V–Y operation described below
ectropion. The operation is likely to be successful if a mar
in the deformity is effected by pulling the skin at the side
canthus upwards.

Instruments. Scalpel, dissecting forceps, artery forc
sutures.

ration. *First step.* An incision, 2 millimetres below the lid and opposite its lateral third, is carried through the skin parallel order of the lower lid laterally to the canthus; having reached this e direction of the incision is changed and it is carried more up- nd outwards till the upper end is on a level with the upper orbital The incision is then carried outwards for about 6 millimetres in downwards, slightly diverging from the former incision, until posite the lower orbital margin. This flap of skin and sub- is tissue is dissected up from above downwards (Fig. 138).

nd step. A V-shaped portion is removed from the margin of the l near the lateral canthus, the base of the V being of sufficient

38. ARGYLL ROBERTSON'S OP- FOR ECTROPION. *Second step.* the method of shortening the e strap of skin reflected. The nvex line shows the piece of e removed so that the lid may upwards into position.

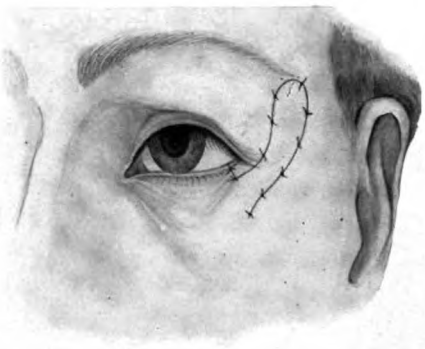

FIG. 139. ARGYLL ROBERTSON'S OPERATION FOR ECTROPION. *Final step.* The strap of skin has been sutured in position after pulling it upwards sufficiently to reduce the deformity and enlarging the raw area upwards to allow this to be done.

o produce the shortening of the lid required when the edges of ion are brought together.

d step. The strap of skin is pulled upwards to the extent re- o replace the lid in position, and sutured there. The raw area enlarged upwards so as to accommodate the upper end of the It is better to do this than to shorten the strap, since a firm hold btained (Fig. 139).

RATIONS FOR THE ACTIVE OR CICATRICIAL FORM OF ECTROPION

numerous operations which have been devised for this condition ded into two groups: (1) the transplantation of flaps in the

neighbourhood of the lesion, and (2) the grafting of ski other parts of the body. The latter method is usually onl when the employment of flaps from the neighbourhood of t is impossible, as the cicatricial contraction which follows th flaps from other parts of the body is usually attended by shrinkage and therefore does not yield such satisfactory res

BY THE TRANSPLANTATION OF FLAPS

V-Y operation (Wharton Jones). **Indications.** T is useful for cases of ectropion affecting the middle parts lid, generally due to a scar such as would result from a heal tuberculous periostitis of the lower orbital margin.

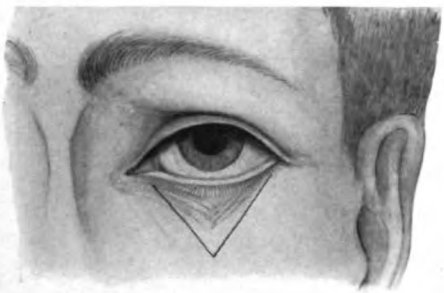

FIG. 140. V–Y OPERATION FOR ECTROPION OF THE LOWER LID DUE TO A SCAR. *First step.* Showing incision.

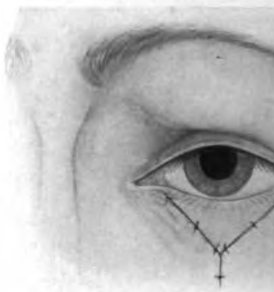

FIG. 141. V–Y O ECTROPION. *Final step.* lid in position.

Instruments. Dissecting forceps, scalpel, artery forceps

Operation. The operation is performed under a genera A V-shaped incision, with the apex downwards, is made to whole margin of the lower lid. The upper ends of the V the lateral and medial canthus and roughly lie over the l margin, enclosing the scar, the apex of the V falling rath orbit. The incision should include the skin and subcuta The V-shaped flap is dissected up and the lid liberated fro lying scar tissue. The incision is then sewn up in the form 141). Temporary tarsorrhaphy (see p. 290) is always des sequent shortening of the lid margin by the Argyll Roberts sometimes necessary.

Denonvillier's operation. This procedure is usefu an ectropion of the lateral portion of the lower lid by the of flaps at the lateral canthus.

ruments. Scalpel, dissecting and artery forceps, scissors, sutures.
ration. The operation is performed under a general anæs-

t step. An oblique incision (Fig. 142), starting from below
ial end of the deformity, A, is carried outwards and slightly up-
or 12 mm. to the point B. From the point B a curved incision, B
ried upwards to and along the orbital margin. This marks out
ular flap. From C the incision is carried outwards and down-
a curved direction to D, which is situated about 2 cm. from the
canthus, thus marking out another triangular flap, B C D.
nd step. Both flaps are dissected up, and then, when all bleeding
ed, the apices of the triangles are transposed and sutured in posi-
incision thus forming a Z-like figure (Fig. 143). A canthor-
s generally required.

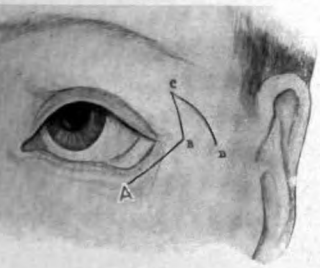

142. DENONVILLIER'S OPERA-
R ECTROPION OF THE LOWER
reversed flaps at the lateral
First step. The flap B C D is
down to form the lateral part
wer lid.

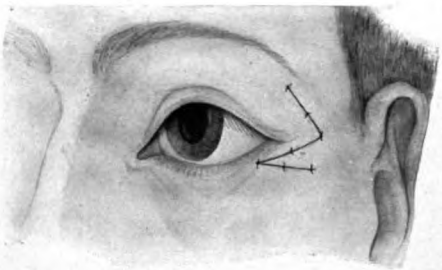

FIG. 143. DENONVILLIER'S OPERATION FOR ECTROPION. Showing the operation completed after transposition of the flaps.

ke's operation. This has for its object the transplantation
from the side of the forehead or face into the lid to remedy a
issue resulting from operation or cicatricial contraction.
cations. The operation is usually performed for cicatrices about
r lid, the flap being turned down from the side of the forehead.
nay be turned in from the inner side in addition if necessary.
ration may also be applied to ectropion of the lower lid.
ration. When planning the flaps the following points must be
to account:
The flap must be cut so that its base contains the main blood-
f the part made use of.
It should be at least one-third larger than the area to be covered.

This is estimated by cutting a piece of protective the size be covered and laying it on the skin before the flap is cu

(iii) The base of the flap should consist of a consider subcutaneous tissue as well as skin, but the apex may be the skin itself.

(iv) The direction of the subsequent contraction shou account so as to assist the final result.

First step. The lid is first freed by dividing all the ci or, if only a small cicatrix be present, by excising that.

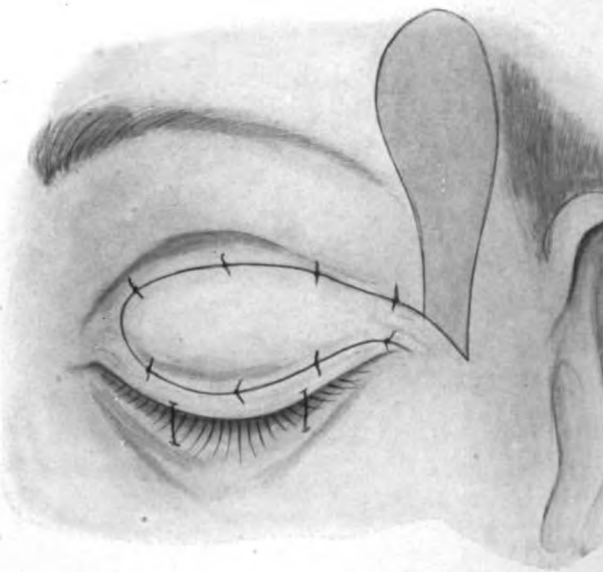

FIG. 144. FRICKE'S OPERATION. To replace the loss of porti of the upper lid.

pulled down into position and put fully on the stretch. T formed by stitching the margin of the lid to the cheek.

Second step. The flap is marked out at least one-th the size required to cover the raw area. The base of be placed a little below the raw area to be covered, so that the flap into position is easily performed without danger to the base (Fig. 144).

Third step. The flap having been raised and all ble it is rotated and sutured in its new position, the wound removal of the flap being brought together by sutures large for this, covered by skin grafts.

BY THIERSCH'S SKIN-GRAFTING METHOD

cations. As has already been pointed out, this method is not so ory as the method by flaps described above, but it is frequently one available when the surrounding skin has been destroyed, extensive lupus of the face.

uments. Scalpel, forceps, skin-grafting razor, probes.

ations. *First step.* As for the previous operation.

d step. Grafts are cut from a situation free from hairs, such edial side of the arm.

step. After all bleeding has been stopped, the grafts are traightened with probes, and pressed firmly down on to the raw The edges of each graft should slightly overlap the one next to t care should be taken in applying the dressings not to disturb s.

e whole thickness of the skin be used (Wolff's method), care e taken to see that the under surface is free from fat.

REPAIR OF LARGE LOSSES OF SUBSTANCE FROM THE EYELIDS

s of portions of the lid margins usually result from operations nant growths. When the loss is in the *upper lid*, some modified Fricke's operation is the best method of remedying the deformity. large area is to be covered, transplantation of a flap from the he Tagliacotian method has to be performed.

e's operation is also applicable to the lateral portion of the lower en the medial end of the *lower lid* is affected, De Vincentiis' yields satisfactory results. When the whole lower lid has been odified Dieffenbach's method with the use of the ear cartilage is

Vincentiis' operation. The operation aims at shifting the of the lid bodily inwards to cover the gap left by the removal of th.

uments. Scalpel, dissecting forceps, artery forceps, scissors,

ation. *First step.* The portion of the whole thickness of the lid with the growth is excised by a V-shaped incision (Fig. 145).

d step. The lateral canthus and orbito-tarsal ligament are di- h the scissors. The incision is then carried outwards and up- th a scalpel, in a line with the lower margin of the lid, the in- ng long enough to free the lower lid sufficiently to slide it in- d to enable the edges of the V-shaped wound to be united 5).

Dieffenbach's operation (modified with the use of ear c
This operation consists in shifting inwards a flap of skin a
taneous tissue derived from the outer side of the face to take th
the eyelid which has been removed, the conjunctiva and ta
being represented by a piece of skin and cartilage taken
posterior surface of the ear and stitched to the inner surface o

Operation. *First step.* The growth, together with the eyel
removed by a V-shaped incision, the base of the V being form
margin of the lower lid.

Second step. An incision is carried directly laterally from
canthus. The length of this incision should be 1¼ times the

FIG. 145. DE VINCENTIIS' OPERATION TO REPLACE THE LOSS OF THE MEDIAL PORTION OF THE LOWER LID. Showing the medial portion of the lid removed by a V-shaped incision and the relief incision made outwards from the lateral canthus.

FIG. 146. DE VINCENTI
TION COMPLETED. The low
been pulled medially and un
opposite side of the gap left
shaped incision. The incisio
from the lateral canthus,
diminished in length, is also

the lid margin. An incision is then carried downwards from
end parallel to the outer limb of the V by which the lower lid
excised. This flap is then raised freely (Fig. 147).

Third step. The ear is turned forward and a semilunar port
skin is marked out and deepened down to the cartilage. Th
this semilunar portion should be equal in length to the upper
the flap that is to form the new lid (Fig. 148). The skin is
sected up for about 3 millimetres from the crescentic part of th
back towards the straight one forming the base of the semilun
this part of the skin has been raised the cartilage is divided
a curved incision, 3 millimetres behind that through the skin,

the straight incision joining the ends of the curved one. It is ed from the skin on the anterior surface of the ear, and the semi- iece of skin and cartilage is thus removed. The portion of carti- moved with the skin is smaller than the latter; the two portions e in length along their straight margins, but the depth of the t of cartilage is considerably less than that of the skin (Fig. 148). rtilage is usually too thick to form the new tarsus and must be down until the right thickness is obtained. It is then applied to

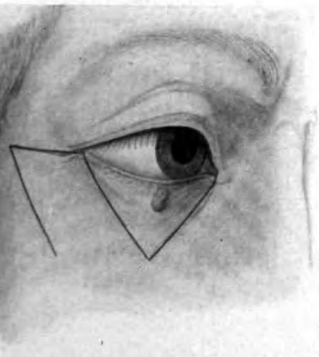

147. MODIFIED DIEFFEN- OPERATION TO REPLACE THE LOSS WHOLE LOWER LID. *First step.* ole lower lid, together with the is removed by the V-shaped and the flap to form the new ssected up from the lateral can- The diagram shows the incision g out the flap.

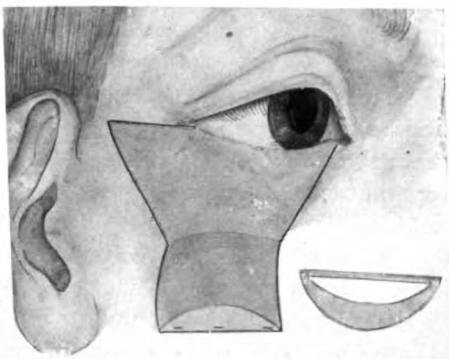

FIG. 148. MODIFIED DIEFFENBACH'S OPERATION. *Third step.* Showing the flap turned down, to the free border of which is attached the flap of skin and ear cartilage. The inset shows the proportion of skin and cartilage (light area) to be removed from the back of the ear.

er surface of the flap to form the new lid, the skin surface being d inwards to help to form the lower conjunctival sac. It is fixed by sutures at its margin, which are passed through the whole ace of both flaps, and tied on the lateral surface of the new lid.

urth step. The flap forming the new lower lid is sutured in posi- The surface from which the flap is taken is closed as far as pos- ith sutures after undermining the edges, any raw area being l by skin grafts taken from the arm.

CHAPTER X

OPERATIONS UPON THE LACRIMAL APPARAT

OPERATIONS upon the lacrimal apparatus are divided into—

I. Operations upon the lacrimal canals.

II. Operations upon the lacrimal gland.

The majority of operations are undertaken for the relief of
tion to some portion of the canal which leads from the con
sac to the nose, obstruction to which causes an overflow
(epiphora)—a condition which must be distinguished from hy
tion (lacrimation).

The obstruction may occur in any part of the canal, that i
in the puncta, canaliculi, lacrimal sac or duct; and it is most i
to determine the cause and position of the obstruction in ev
before undertaking an operation for its relief. Hence it need l
said that the nose should be carefully examined in every case u
cause is obvious. The operations are divided into two classes:

1. Those which are undertaken for the relief of the obstruc
2. Those which are undertaken for the obliteration of the

Except under exceptional circumstances, the latter operat
only undertaken when a cure cannot be brought about by the fo

The presence of a septic focus, such as a distended lacri
apart from the irritation and increased lacrimal secretion caused
is a source of grave danger to the eye if not relieved, as it is a
cause of serpiginous corneal ulceration.

OPERATIONS FOR THE RELIEF OF LACRIM OBSTRUCTION

DILATATION OF THE CANALICULUS

Indications. (i) Contraction of the puncta following
blepharitis, especially when associated with ectropion.

(ii) Preparatory to syringing or probing.

(iii) To dilate a stricture of the canaliculus.

Instruments. Nettleship's canaliculus dilator (Fig. 149).

eration. The operation is performed under adrenalin and a little solid cocaine being rubbed in over the canaliculus.
lid is slightly everted and put on the stretch by pulling it down- and outwards with the thumb. The depression caused by the n is seen on the top of a small elevation. The point of the dilator ed vertically into the punctum and then turned parallel with the gin and passed onwards with a steady pressure. At the same

FIG. 149. CANALICULUS DILATOR.

should be rotated between the finger and thumb, until the medial all of the lacrimal sac is felt. The only difficulty which may be nced is in entering the dilator into the punctum, owing to the ize of the latter. For this reason the fine point of Nettleship's is more suitable than the form modified by Lang. Even Nettle- ilator is too large in a few cases, and here a large sharp-pointed ometimes of use in defining the punctum before using Nettleship's

SLITTING THE CANALICULUS

ications. To enlarge the punctum and direct the entrance to the ulus inwards. This is especially desirable before ectropion opera- nd for the removal of concretions (leptothrix) from the duct. In days the canaliculus used to be slit with the idea of passing very robes down the lacrimal duct; this has now been abandoned,

FIG. 150. CANALICULUS KNIFE.

itting the canaliculus throughout its whole length, as is required treatment, does away with the capillary attraction.
ruments. Dilator, canaliculus knife (Fig. 150), straight iris for- arp-pointed scissors.
eration. It is usually performed on the lower canaliculus. The ocainized as in the previous operation and the patient is made to

t step. The canaliculus is first dilated. The knife is inserted ort distance with the handle parallel to the lid margin. The lower g held on the stretch by the thumb, the handle of the knife is

raised towards the brow, thus dividing the canaliculus. the knife should be directed upwards and slightly backwar

Second step. As the lips of the wound are liable t better to remove the posterior lip of the groove. This is seizing the latter with forceps and dividing it with sciss trance to the canaliculus should be kept open by means passed twice a week for a month.

SYRINGING THE LACRIMAL DUCT

Indications. (i) To test whether the lacrimal can

(ii) By constantly cleansing the sac and washing aw discharge the mucous membrane may regain a more hea and so an obstruction due to an alteration in the muco be relieved. In cases with a purulent discharge a sma protargol (10% solution) may be left in the sac after syri

FIG. 151. LACRIMAL SYRINGE.

(iii) The injection of adrenalin and cocaine into the excision.

Operation. The eye is cocainized and the patient m The punctum is everted by pulling down the lower lid. T is then dilated. The nozzle of the lacrimal syringe (Fig be passed until it is felt to impinge on the bony outer w Withdraw the syringe slightly and apply gentle pressure The fluid will either regurgitate through the upper canali duct be patent, pass down into the nose and so into the th

Complications. If too forcible syringing be used e the fluid may take place. This is accompanied by pain a the lacrimal region. It usually subsides under hot fom suppuration and even cellulitis of the orbit have been know

PROBING THE LACRIMAL DUCT

Indications. (i) In cases of congenital lacrimal o to débris blocking the duct.

(ii) When syringing has failed to bring about a cure, a passed once or twice to see if dilatation causes any impro especially useful in children.

i) As a preliminary to the insertion of styles.
arious forms of probes are employed, those of Bowman being in
l use. Too fine a probe should not be used, otherwise a false
e is liable to be made.
peration. This is performed under adrenalin and cocaine, which
be injected into the lacrimal sac.
e lower punctum is dilated and the probe passed parallel to the lid
n until it is felt to impinge upon the lacrimal bone. Keeping
int applied to the bone, the handle of the probe is rotated upwards
gh rather more than a quarter of a circle and passed by a gentle
re downwards and slightly outwards into the duct, keeping the
of the probe close to the bone the whole way. The direction of
obe after entering the duct should be downwards, outwards, and
ards in the direction of the first molar tooth on the same side.
ackward direction of the duct is much more marked in young
en than in adults.
mplications. A false passage may be made into the maxillary
n. If such an accident should occur, no further attempt should
de to pass a probe for a few days until the wound has healed.

THE INSERTION OF STYLES

few surgeons still insert styles into the lacrimal duct with the
f continuous dilatation. The hollow styles used by Bickerton are
es most frequently employed.
struments for dilating, slitting the canaliculus, probing, and styles.
Stilling's knife.
peration. A general anæsthetic is desirable.
rst step. The canaliculus is dilated and slit up, the posterior lip
removed (see p. 315).
cond step. The duct is dilated by probing (*vide supra*) or en-
by passing Stilling's knife down it.
ird step. A style is passed down the dilated duct. The lower
the style should rest upon the floor of the nose, otherwise there
endency for the style to slip into the duct and disappear. Care
be taken that the upper end does not rub on the globe. Styles
generally be left in position from three to six months. A style
at first be made of lead wire, and moulded until a suitable pattern
ined, from which a hollow gold style can be made subsequently.
dications. 1. *Dacryo-cystitis* may follow the insertion of a
which should then be removed until the inflammation has subsided.
The style may slip down the duct. If this should occur an at-

tempt should be made to grasp it through the slit canaliculus. T
end may present in the nose and the style can than be withdra
forceps. Occasionally styles lodge in the maxillary antrum,
case they must be removed after localisation by the X-rays th
opening from the mouth above the canine tooth.

OPERATIONS FOR THE OBLITERATION OF T CANALS

When syringing and probing have failed to relieve the
obstruction, one of the following operations for the obliteratio
lacrimal passages may be employed.

OBLITERATION OF THE CANALICULI

Indications. In cases of lacrimal obstruction in which a
diate operation upon the globe is required.

Operation. Under cocaine. Fine sutures armed with
curved needle are passed beneath both the upper and lower ca
and tied so as to include them in the ligature. Permanent ob
may be caused by the destruction of the lining membrane with t
cautery.

EXCISION OF THE LACRIMAL SAC

Indications. (i) For mucocele in cases of lacrimal ob
which have failed to yield to other treatment.

(ii) In all cases of tuberculous disease of the sac.

(iii) For a recurrent lacrimal abscess after subsidence of
inflammation.

(iv) For hypopyon ulcer associated with lacrimal obstruct

(v) Before operation on the globe in cases of lacrimal obst

(vi) For lacrimal fistula.

Instruments. Small scalpel, forceps, Muller's speculum (F
Axenfeld's retractor (Fig. 153), straight scissors, horsehair sut

Operation. Hæmorrhage is the most troublesome part
operation; it is best controlled by injecting adrenalin (made
dried gland, ʒj, and ℥j of water) and cocaine, 10%, into the sac
of an hour before operating. Swabs on the end of a glass rod
adrenalin and cocaine may also be used during the operation. A
anæsthetic is desirable, but many surgeons perform the operati
local anæsthesia, produced by injecting novocaine with 1
adrenalin into the tissue surrounding the sac.

First step. The medial tarsal ligament is first defined by
the lids on the stretch. An incision should be made, 15 millim

5 millimetres of which should fall above the tarsal ligament), ds and inwards directly over the lacrimal sac. Muller's re- s then inserted to retract the wound laterally, the hooks being engage the margins of the incision by means of forceps. The al fascia and the fibres of the orbicularis muscle are then divided. lial tarsal ligament in the upper part of the wound, together with ening deep fascia, is exposed and divided carefully so as not ire the lac- ac, which is directly be- (Fig. 154). *nd step.* With the sac-wall n separated ie deep fascia ncloses it, first and then , the cana- eing divided. ld's retractor inserted in gitudinal axis wound (Fig. The middle of c is grasped forceps and forward, and of the sac is and detached. is frequently owing to the ome hæmor- which often The sac is

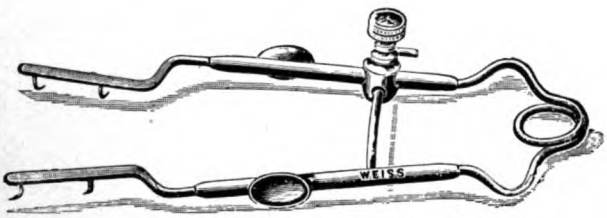

FIG. 152. MULLER'S RETRACTOR FOR EXCISION OF THE LACRIMAL SAC.

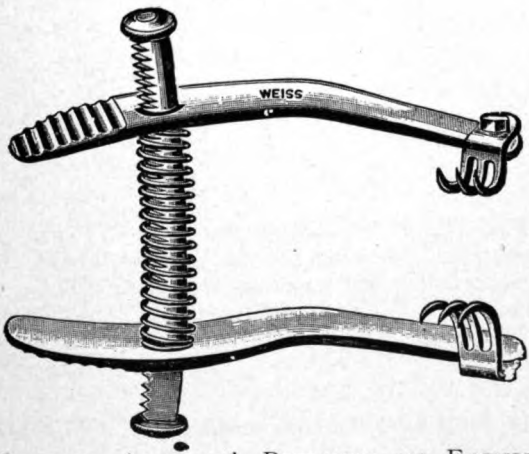

FIG. 153. AXENFELD'S RETRACTOR FOR EXCISION OF THE LACRIMAL SAC.

vell forward, and the posterior wall is separated, the neck of the g divided as far down the duct as possible by means of scissors. probe is passed down the duct into the nose. Some surgeons the periosteum of the lacrimal bone as well as the sac, which cessary. The wound is closed by three sutures, the middle one g the divided ends of the medial tarsal ligament. A firm dressing be applied so as to keep the walls of the cavity in contact. In lous cases it is desirable to curette the lower end of the

duct after removal of the sac. The stitches are re seventh day.

Complications. These may be immediate or remo

Immediate. 1. *Inability to find the sac.* This may ginner, and is generally due to the fact that the dissectio much medially towards the nose. It should not occur i the sac are carefully borne in mind, namely, the medial and, on the medial side, the crista lacrimalis posterior, w be felt with the finger or forceps in the wound.

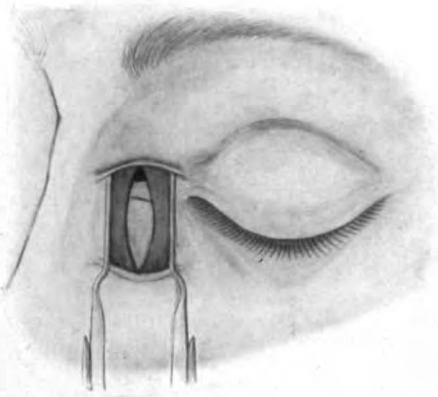

FIG. 154. EXCISION OF THE LACRIMAL SAC. Showing the medial tarsal ligament in the upper part of the wound with the sac lying beneath.

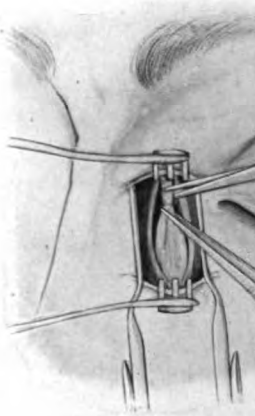

FIG. 155. EXCISI RIMAL SAC. Showin defining the upper enc medial tarsal ligament and the sac is well pu forceps.

2. *Opening the conjunctival sac.* This may take plac the canaliculi. It is more likely to occur if the deep imperfectly divided before carrying out the dissection to As a rule the opening heals readily.

3. *Opening of the orbit,* due to the division of the fa the posterior lip of the lacrimal groove. It is rec fact that orbital fat presents in the wound, and for this the operation more difficult. It is most likely to happen end of the sac is being divided. It lays the orbit open t of septic infection. The medial rectus has been divided, the fact that the fascia, which passes from the lateral muscle, is attached to the posterior lip of the lacrimal

as been thereby pulled up into the wound; with ordinary uch an accident is impossible.

njuries to the cornea. Corneal abrasions by the clumsy insertion tors may lead to severe corneal ulceration.

pte. 1. *Epiphora.* Normally the lacrimal secretion is largely from the conjunctival sac by a process of evaporation. It is n the hypersecretion of tears takes places that the lacrimal appa- alled much into use. As a rule, patients who have had the lac- excised do not complain of epiphora, except in a cold wind. ally this epiphora may be so troublesome that removal of the portion of the lacrimal gland is desirable for its relief. There of the conjunctival sac becoming dry after this operation, since numerous accessory lacrimal glands (glands of Waldeyer and opening on to the superior fornix.

sinus. The wound may break down and a sinus may form at of the incision. These cases are nearly always of tuberculous nd not infrequently have underlying bone trouble. They can e made to heal by the use of iodoform and scraping.

ecurrence of the mucocele or lacrimal abscess. Occasionally the may re-form, or an abscess result after removal of the sac. ue either to a piece of sac-wall being left behind, or to the re- the cavity with epithelium from the cut end of the duct. It is rly liable to occur in cases of a tuberculous nature. Firm pres- the dressings after the operation is the best method of prevent- cavity re-lining with epithelium. If the condition has arisen, lo-sac should be excised.

OPENING A LACRIMAL ABSCESS

cations. Lacrimal abscess is due to an inflammation around all through which infection of the cellular tissue has taken place. cess should not be opened until pus is present, as even con- swelling and œdema will often subside without suppuration; ually about the end of the third day. Further, if the opening too soon, the inflammation takes considerably longer to subside.

uments. Beer's knife, forceps, and probe.

ration. Usually performed under gas. An incision is made lacrimal sac and is carried downwards and inwards to the a single puncture of the knife. The pus is evacuated, and the uffed with gauze, which should be changed daily for the first s. Hot fomentations should be applied. As soon as the swell- subsided, the lacrimal obstruction should be treated by one of ods previously described.

OPERATIONS UPON THE LACRIMAL G

REMOVAL OF THE PALPEBRAL PORTIO

Indications. For obstinate epiphora after removal
sac.

Instruments. Fixation forceps (two pairs), two sha
bismus scissors, suture.

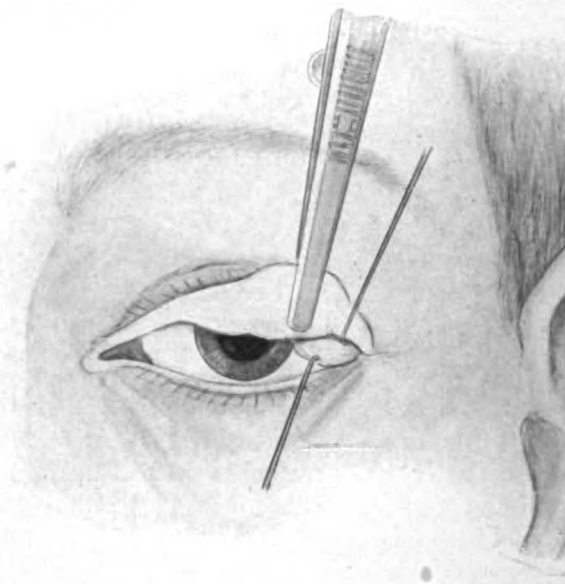

FIG. 156. EXCISION OF THE PALPEBRAL PORTION OF THE L
The lid is doubly everted and the gland is dissected out from w

Operation. Usually performed under adrenalin and

First step. The upper lid is doubly everted. The
carried out by holding the singly everted lid between fo
re-everting it; the forceps are then given to an assistant
a syringe a few drops of novocaine and adrenalin are injec
conjunctiva into the area to be operated upon.

Second step. The gland is seen beneath the conjuncti
part of the upper fornix, seized with forceps, and dr
A horizontal incision is made with scissors through t
which is dissected backwards. The edges of the wound
apart by means of sharp hooks (Fig. 156).

Third step. The gland, which is seen as a nodule, is

ceps. By means of the scissors the gland is separated from its nts along its whole length, starting on the medial side, the eing subsequently closed with a few points of catgut suture.

REMOVAL OF THE ORBITAL PORTION

cations. It is usually undertaken for tumours (endothelio-) and retention cysts.

uments. Knife, artery and dissecting forceps, retractors,

ation. Performed under a general anæsthetic.

step. An incision, three inches long, is made through the skin ely below the lateral third of the orbital margin. The under- bicularis oculi is divided, and the orbital fascia covering the defined and incised.

d step. The gland is first separated from the periosteum of the n in the bone in which it lies, and is drawn forward and care- ected out from the lid. The wound is then closed with sutures.

bscess in the lacrimal gland should be opened by an incision , but not so long as that in the above operation.

OPERATIONS UPON THE ORBIT

XPLORATION OF THE ORBIT (KRÖNLEIN'S METHOD)

is operation the bony lateral wall of the orbit is divided above w, and turned outwards so as to expose the orbital contents nterfering with the globe; the bony wall, being kept attached verlying tissue, can be replaced subsequently without fear of

cations. The operation is performed in cases of a suspected f the orbit, which, if small and non-malignant, can be removed, eing left *in situ.* If doubt exists as to the nature of the tumour an be removed and examined microscopically, either at the time peration or later. It is especially suitable for tumours of the ve and for orbital cysts behind the globe.

uments. Scalpel, dissecting forceps, artery forceps, scissors, elevator, chisel and hammer, or preferably, a motor rotary saw, ctors.

ation. Performed under a general anæsthetic.

step. A slightly curved incision with the convexity forwards o as to expose the lateral margin of the orbit and carried down

to the bone. The periosteum is separated from the medi lateral wall of the orbit by means of a periosteal eleva horizontally, the finger is inserted, and the orbit explo tumour or cyst be found it can sometimes be shelled incision without enlarging the wound further.

Second step. The eye and orbital contents are ca with a large flat retractor. The bone is first divided of either a chisel or a saw. The upper incision should base of the lateral angular process of the frontal bone wards and slightly downwards to the posterior end maxillary fissure. The lower incision should run dir from the lower orbital margin into the pterygo-maxilla triangular wedge of bone attached by its outer surface t in the temporal fossa is then forced outwards. In doin be taken not to fracture the orbital wall anteriorly, other work in will be much reduced.

Third step. Consists in the removal of the tumour taken to displace the lateral rectus to one side so as to it as much as possible. If the case should be one of tumour, for which the operation is most frequently perf nerve is divided close behind the globe. The tumour is surrounding ciliary nerves and the ophthalmic artery and the wound as much as possible. The optic nerve is the apex of the orbit and the tumour removed. The wound i of the outer wall of the orbit is closed with a catgut s together with the soft parts, replaced in position, and closed by sutures. A drainage-tube should be insert twenty-four hours.

Complications. 1. *Proptosis.* The operation is lowed by great proptosis as the result of hæmorrhage in the optic nerve has been removed, the globe may be disl between the lids and come in contact with the dressings.

2. *Corneal ulceration.* As the cornea is frequently division of the ciliary nerves, ulceration is very liable t therefore, desirable in many cases to stitch the lids togeth the skin wound.

3. *Defective lateral movement in the globe* is of freq owing either to injury of the lateral rectus or the abduc involvement of them in the scar tissue. Stitching the gether obviates the latter to a certain extent.

4. As the wound cicatrizes a certain amount of *enop* liable to result.

EVISCERATION OF THE ORBIT

ications. This operation is usually performed for some form growth originating either in the eye or the orbit.

eration. This may be modified (1) according to the *position* rowth. In severe cases of rodent ulcer and sarcomatous growths, nvolve the lids, it is desirable that the lids should be removed with our; but in cases of tumour of the optic nerve, or disease situated in the orbit, and not involving the lids or conjunctiva, these es may be retained, since a much better socket is thus obtained. e *nature* of the growth. In simple tumours, such as nævi and ses of arterio-venous aneurism which have failed to yield to other nt, the incomplete method, in which the lids are retained, is all ecessary, but in malignant cases they should be removed.

Complete Method. An incision down to the bone is first made, ely encircling the orbital margin and including any growth that involving the skin. The periosteum is then separated com- as near to the optic foramen as possible. Care must be taken in with the periosteum over the lacrimal bone, as the bone is liable ractured and an opening made into the nose if undue force be The apex of the cone formed by the periosteum is divided, as far possible, with curved scissors, and the whole orbital contents are l. The wound is packed with gauze, and skin-grafting is subse- performed when the bone has become covered with granulations; ally occurs about the end of the second week.

Incomplete Method. The globe is first enucleated and the lateral divided. The lids are well retracted and an incision is carried the bone along the orbital margins. The periosteum is then up from the walls of the orbit and the apex of the cone divided ack as possible, as in the previous operation. The conjunctiva ral canthus are then united with sutures. As a rule, skin-grafting ecessary after this operation.

OPENING AN ORBITAL ABSCESS

tal abscesses should be incised where they point. In the upper should be taken not to divide the levator palpebræ muscle; the should be placed well to one side. In making an incision over ial side of the orbit care should be taken not to detach the f the superior oblique. The cause of the abscess should be ed if possible. Suppuration in the ethmoidal sinuses coming from the nose is the commonest cause, and should be treated ately (see Section IV).

SECTION IV

OPERATIONS UPON THE EAR

BY

UNTER F. TOD, M.A., M.D. (Cantab.), F.R.C.S. (Eng.)
Aural Surgeon to the London Hospital



CHAPTER I

MINATION OF THE EAR: GENERAL CONSIDERATIONS WITH REGARD TO OPERATIONS

order to perform successfully the various operations upon the ear, ssential that the surgeon should be familiar with the technique of mination, which, for the sake of convenience, will first be briefly ed.

EXAMINATION OF THE EAR

r this purpose it is necessary to make use of certain instruments in to obtain a clear view of the deeper parts of the acoustic canal mpanic membrane. Most ant amongst these are the ing:

rror. A head-mirror, such e ordinary laryngological with a focus of eight is to be preferred to the nirror, as it leaves both free for manipulation.

urces of illumination. Al- the light reflected from y on a bright cloudless day llent, it can seldom be made , and so for practical pur- he source of light is usually al. It is wiser always to e same kind of light—for e, electric—as in this way a ccurate comparison can be made of the various pathological condi- seen on examination. In the consulting room, the lamp recom- d by Dr. Greville Macdonald, furnished either with a thirty-two -power frosted burner or with a Nernst light, is most suitable. As able lamp, it is useful to have an electric bull's-eye lamp, run off dry-celled battery: it can be held in the position of the ordinary he light being reflected into the ear by means of the head-mirror.

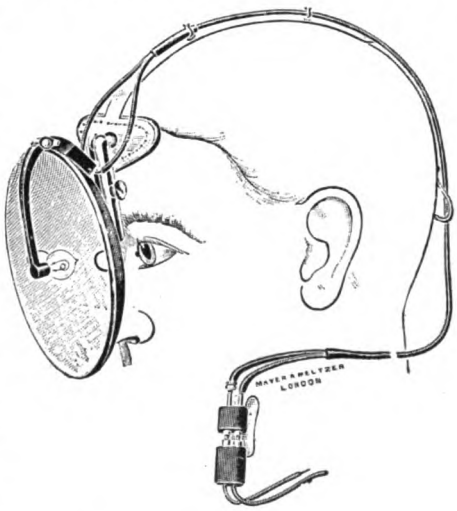

FIG. 157. CLAR'S LAMP.

The ordinary surgical head-lamp, although not well ada
tion of the deeper parts of the acoustic canal, is emin
obtaining good illumination during the performance of th
tions; or in its stead a head-mirror with lamp attached
recommended by Clar (Fig. 157).

Aural specula. Of the various aural specula emp
is very good (Fig. 158). A special speculum from whi
been removed from the narrow end is sometimes useful i
tate operative procedures within the external acoustic m

Forceps. The best are angular spring forceps with
(Fig. 158).

Position of the patient. The patient should sit up
with the side to be examined turned towards the surge

Fig. 158. Gruber's Aural Speculum.



Fig. 159. Angular Spri

movement, the head should be supported by an assistan
rest fixed to the back of the chair. The lamp is place
and to the left of the patient's head, on a level with
examiner.

Technique of examination. To convert the exter
a straight canal, the auricle has to be pulled backwards
in an infant, backwards in a child, and backwards and
adult. The speculum should be warmed and inserted
meatus by the thumb and index-finger of the left hand,
is held between, and pulled back by, the second and thi
160). This leaves the right hand free for manipulatio
possible speculum should be used, in order to give the m
of room and illumination. It should only be introduced
as far as the adaptable cartilaginous portion permits—ab
in the adult—and not forced into the bony portion. Th

s essential in order to obtain the confidence of the patient; this olutely necessary for the performance of the various small opera- upon the acoustic canal and tympanic cavity under local anæsthesia.

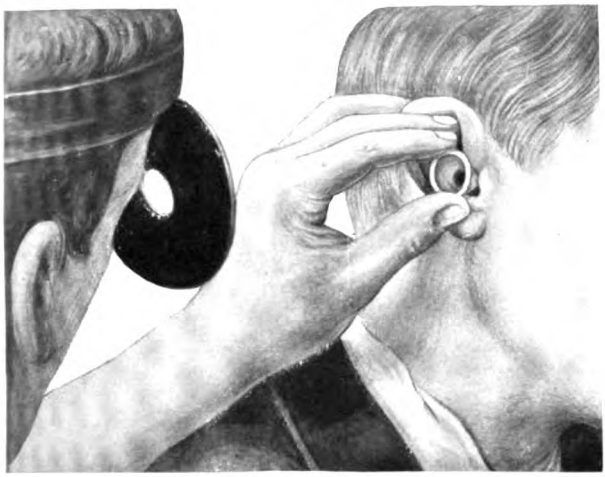

FIG. 160. EXAMINATION OF THE EAR.

ethod of cleansing the ear. Except when the acoustic canal is etely blocked by inspissated pus, cerumen, or epithelial débris, ufficient to mop out the ear with small pledgets of cotton-wool.

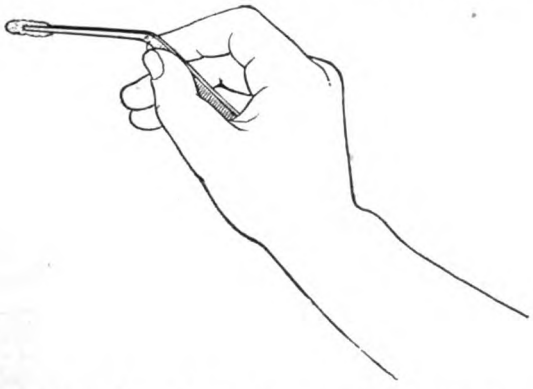

FIG. 161. AURAL FORCEPS HOLDING COTTON-WOOL.

event injury to the walls of the meatus and to the tympanic mem- the pledget is held between the blades of the forceps in such a n that it partially projects beyond its points (Fig. 161). The for- re passed through the lumen of the speculum along the acoustic

canal and then quickly withdrawn. This is repeated with fresh pl until the meatus is cleansed. If there is much purulent discharge, brief moment may be given (after the withdrawal of the force which to inspect the deeper parts. Such a view, however, should be obtained in order to form an accurate diagnosis. If this metho to cleanse the ear, syringing becomes necessary.

Technique of syringing. The patient should be sitting do syringing may cause giddiness. The fluid should be aseptic, an temperature of 100° F. The patient's head is inclined to the a side, and the auricle is pulled upwards and backwards. The syri inserted a short distance within the meatus, and applied t upper posterior wall so th stream of lotion flows along th of the canal to the drum, and r along the floor, thus washing contents. The best syringe with a metal plunger, as it easily sterilized. After syri the auditory canal should be and again inspected. If the sated pus or epithelial débris be removed by simple syringi ear-bath of warm hydroge oxide (10 vols. %) should be and the ear again syringed five minutes.

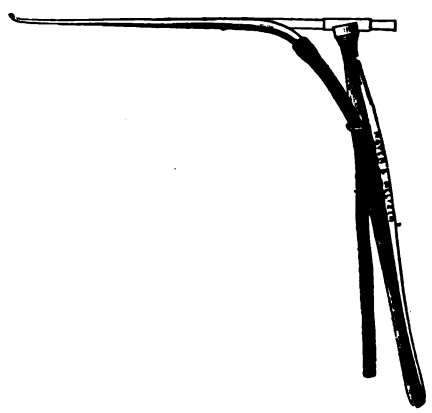

FIG. 162. MILLIGAN'S INTRATYMPANIC SYRINGE.

Syringing out of the attic. In certain cases of chroni suppuration, it is advisable to syringe out the attic. For this a syringe is necessary. It consists of a fine canula whose point is up almost at right angles to its shaft (known as Hartmann's ca to which is fitted a piece of india-rubber tubing and a ball s Milligan's modification of this instrument is now generally used permits of the canula being held in the hand, and, instead of a ball syringe, is connected by rubber-tubing to a small ir (Fig. 162).

The patient sits upright in a chair in the ordinary position for nation of the ear; a speculum is inserted into the meatus, and l position with the left hand; the canula, together with the ball s (if Hartmann's is used), is held in the right hand. Under good nation the canula is passed inwards along the acoustic canal, a point inserted through the perforation. By gently pressing syringe, the fluid is forced into the attic, which is thus washed out

ith Milligan's instrument, the irrigator is fixed about two feet above
el of the ear. While the canula is being inserted, the escape of
is prevented by compressing the tube against the shaft of the
nent by means of the thumb. After the canula has been inserted
e opening, relaxation of this pressure permits of flow of the lotion.
an's method is better than Hartmann's, as the surgeon has more
l over the instrument. Pain due to the introduction of the canula
e greatly minimized by previously inserting within the margins
perforation either a pledget of cotton-wool soaked in a saturated
n of cocaine, or a crystal of cocaine.
ter the cavity has been thoroughly washed out, the acoustic canal
fully dried; as a final step, gentle inflation by Politzer's method
e performed in order to expel any fluid still remaining within
ic.

GENERAL CONSIDERATIONS WITH REGARD TO OPERATIONS

this connexion two points must be borne in mind: (1) The sur-
nust have a good view of the part operated upon. For this reason
operating upon the acoustic canal, the tympanic membrane or the
num, he will usually require to work by reflected light.
) There must be no movement of the patient's head during the
ion. If the operation is performed under a local anæsthetic, it is
ore very important that the patient's head should be kept fixed
ans of an assistant.

eliminary surgical toilet. If there be no existing suppura-
ne ear should be cleansed, some twelve hours before the operation,
t giving an ear-bath of hydrogen peroxide lotion. This is done by
g the patient incline the head to the opposite side so that the
d ear is uppermost. The warm solution is then poured into the
s. After ten minutes the ear is syringed out with a 1 in 5,000
is solution of biniodide of mercury, and a strip of sterilized gauze
inserted into the auditory canal. The auricle and surrounding
should also be surgically cleansed, and afterwards protected by
le aseptic compress. If, as in furunculosis of the external meatus,
ng or cleansing of the ear is very painful, drops of a 10% solution
olic acid in glycerine may be instilled frequently into the meatus
. If there is otorrhœa the acoustic canal should not be plugged
auze, but before the actual operation takes place, if necessary after
æsthetic has been given, the ear and surrounding parts should be
ly cleansed, and the acoustic canal syringed out with biniodide of

mercury solution, dried, and painted over with a 2% alcoholic so of iodine. Failure of such precautions may lead to disaster; fo ample, perichondritis of the auricle as a sequel of the mastoid opera

In intrameatal operations the head should be wrapped in a ste towel, and a square of sterilized lint, having an aperture in the so as to expose only the auricle and meatus, should be placed over th of the head and face. In operations on the mastoid process, and in involving a post-auricular incision, the head should also be shave at least two or three inches beyond the region of the ear.

Anæsthesia. Both local and general anæsthesia are used. U contra-indicated for some special reason, and unless the ope is a very trivial one, it is wiser to give a *general anæsthetic* these, chloroform is the most suitable in adults and infants, an A. C. E. mixture in children. Ether, although it may be safer, i quently a source of annoyance to the operator, as it tends to increa hæmorrhage.

In order to produce *local anæsthesia* two methods may be empl (1) The instillation of fluids into the meatus; (2) subcutaneous tion of fluids beneath the lining membrane of the meatus and in surrounding parts of the auricle.

The solution usually employed is a sterilized aqueous soluti cocaine hydrochloride in varying strengths up to 20%, to which be added equal parts of 1 in 1,000 adrenalin chloride solution; the not only increases its analgesic properties, but also acts as a pow hæmostatic.

Instillation. As the auditory canal and the tympanic membran lined with epithelium which is very resistant to the absorption of complete anæsthesia is almost impossible to obtain. This m therefore, is practically limited to such trivial operations as the cur away or snaring off of granulations or polypi from the external or dle ear. To render anæsthesia more complete, the affected part m finally rubbed over with a crystal of solid cocaine hydrochloride before the operation is begun. On the other hand, if the raw su is large—for example, the wound left after a recently performed plete mastoid operation—the cocaine employed should not be str than a 5% solution in order to minimize the risk of poisoning. of Glasgow has suggested, as a more penetrating anodyne soluti mixture consisting of a 10% solution of cocaine hydrochloride in parts of aniline oil and absolute alcohol, a solution which he espe advocates in order to produce anæsthesia of the tympanic mem before doing paracentesis.

Subcutaneous injection. This is a modification of Schleich's me

first introduced by Neumann of Vienna. It consists in in- a very weak solution of cocaine and adrenalin chloride sub- sly beneath the periosteum lining the acoustic canal. By this even the complete mastoid operation has been performed, and n clinics it is used continually in the minor operations of para- of the tympanic membrane, division of intratympanic adhesions, n of polypi, and ossiculectomy. A solution of beta-eucaine caine may be used in preference to cocaine, as being less dan- According to Neumann, three solutions are necessary: (*a*) a oo solution of adrenalin chloride containing a 1% solution of aine; (*b*) a 1 in 3,000 solution of n chloride containing a 1% solution ne; (*c*) a 20% solution of cocaine.

FIG. 163. NEUMANN'S SYRINGE FOR SUBCUTANEOUS INJECTION.

syringe for injecting the solution has ty of 1 cubic centimetre, and for con- its needle is fixed at an obtuse angle ody of the syringe (Fig. 163). The e of the injection depends on whether ration is to be limited to the acoustic d tympanic cavity, or is to involve the process.

he complete mastoid operation is to ormed, the needle of the syringe, now vith the eucaine solution, is thrust the skin about the middle point of the process, and a few drops of the solu- injected. The needle is then forced s towards the temporal ridge, at the ne being thrust in deeply until it touches e, so that a syringeful of the solution ed beneath the periosteum. The needle is then withdrawn and ed at the same point, but in a backward direction, the solution jected along the posterior portion of the mastoid process; in r manner the solution is injected downwards towards the tip nastoid. The ear being now pulled well forward, the needle is pierce the fold between the auricle and the mastoid process, ve the posterior ligament, and is pushed inwards between the border of the mastoid process and the cartilage of the meatus, urther syringeful of the solution is injected. A large speculum inserted into the ear, so that by pressing it against the wall of tus the skin, at the termination of the cartilaginous portion, is project in folds. The needle of the syringe, filled with cocaine

Digitized by Google

solution, is pushed into this fold, and a few drops of the solu
jected. By degrees the needle is still further pushed inwards,
it in close contact with the bony wall so that the fluid is injected
the periosteum. If the injection has been successful, a white
of the superior wall of the auditory canal will be noticed. To
anæsthesia complete, further injections may be made into the
and anterior walls of the auditory canal. Finally, a pledget of
wool soaked in a 20% solution of cocaine is pushed into the tym

In the case of simple opening of the mastoid, subcutaneous in
into the acoustic canal are not necessary. On the other hand
operation is limited to the acoustic canal and tympanum, the in
into the mastoid process are not required, but a primary injec
a small quantity of eucaine solution into the auriculo-mastoid fo
siderably diminishes the pain produced during the act of injecti
the auditory canal. Fifteen minutes should be allowed to elapse
the operation is begun. The anæsthesia lasts about half an hou

Recently quinine and urea hydrochloride solution have been
the same manner as cocaine for subcutaneous injection. The ad
in their use is that anæsthesia may persist for a few days; the ch
advantages are that it takes half an hour to anæsthetise the par
as a result of the injection, œdema of the tissues may occur.

Difficulties. It is by no means easy to inject fluid beneath th
osteum of the acoustic canal, owing to its close adherence to th
The needle by mistake may repierce the skin at a point farther
that the fluid, instead of being injected beneath the periosteum
jected into the auditory canal itself. In these cases anæsthesia w
be obtained, and the operator may possibly blame the principle
cutaneous injection, rather than his own faulty technique.

In favour of subcutaneous injection it is urged that most
minor operations within the tympanum, including ossiculectomy
be performed with the patient sitting up in the chair in the con
room, and further, that the patient can afterwards go home; th
operation is rendered more easy owing to there being practica
bleeding; and that in the case of the more severe operations, s
opening of the tympanic antrum, the surgeon, in a case of emer
may make use of this method if he cannot possibly obtain the s
of an anæsthetist.

Against subcutaneous injection is the pain of the injection,
may be so great that the patient will not submit to it, and in conse
the proposed operation may have to be postponed.

In the case of the mastoid operation, it is difficult to believ
local anæsthesia, however efficient, will be looked upon with

y the surgeon or by the patient, except when a general anæs- absolutely contra-indicated. The discomfort produced by re- of the parts, the jarring caused by chiselling, and the conscious- what is taking place, is far more unpleasant and more of a shock atient than a general anæsthetic carefully given. Further, it is ays possible to foretell the extent of the operation, and if re- njections become necessary, there is danger of eucaine or cocaine ng being produced.

Position of the Patient and Surgeon

n the minor operations the patient may be operated on whilst in ng posture, whether a local anæsthetic or a general one of gas rgen is employed. The relative positions of the patient and the are then the same as for the ordinary routine examination of Special care, however, should be taken that the patient's head orted by the anæsthetist or assistant in order to prevent invol- movements.

f the patient is operated on in the recumbent position, the head t comfortably on an ordinary pillow, but if chiselling is going place, the best support is a loosely-filled sand-bag. The head be turned towards the opposite side so that the affected ear is ost, and the surgeon stands at the side to be operated on. The e source of reflected light, should be held about six inches above ent's shoulder on the opposite side.

CHAPTER II

OPERATIONS UPON THE EXTERNAL ACOUSTIC

OPERATIONS FOR FURUNCULOSIS

THE operative treatment consists in incising the furuncles necessary, curetting out their contents.

Indications. (1) If, in spite of palliative treatment, the so intense as to prevent sleep, and be accompanied by pyrexia.

(2) If there be accompanying œdema of the auricle and su ing parts.

(3) If the furuncles occur during the course of a middle- puration, and occlusion of the external meatus prevents free of the purulent secretion.

When possible, it is preferable to operate under a general an such as gas and oxygen. If, however, the patient objects to a anæsthetic, it should be explained that, in spite of the applic anodynes, the operation, although of momentary duration, wil cessively painful.

Operation. After the ear has been thoroughly cleansed, aural speculum is inserted within the meatus and the audito dried with pledgets of cotton-wool.

The instrument usually used for this operation is a small and sharp-pointed knife known as Hartmann's furunculotome (Fig. Equally suitable, however, is a fine bistoury; or, if necessary, tenotome or the ordinary paracentesis knife.

The surgeon holds the speculum in position within the mea the left hand, and with the right inserts the knife through the l the speculum along the meatus until its point passes the innerm of the furuncle. It is then quickly withdrawn, at the same time *the furuncle* freely down to its base. Another method is to *tra furuncle* by passing the knife through its base and making it cut through the skin. In a similar manner any other furuncles that present are incised or transfixed.

If the inflammatory process, instead of being localised as a extends to the subcutaneous tissues, and especially if it is acco

ch pain, pyrexia, and occlusion of the external meatus, *linear ation* may become necessary.

er incision, the contents of the furuncle are rapidly scooped out e curette (Fig. 164, A). Slight hæmorrhage may occur, but can sted at once by plugging the meatus for a minute with a strip of d gauze. The auditory canal is finally syringed out with a warm s 1 in 3,000 solution of biniodide of mercury, and firmly plugged uze soaked in a 10% solution of carbolic acid in glycerine; a hot ation being afterwards applied to the side of the head.

he operation has been performed under a local anæsthetic (and ould only be done if a solitary furuncle is present), the pain is too great to permit of firm packing of the auditory canal. This acking, however, should be carried out, if possible, for the follow-

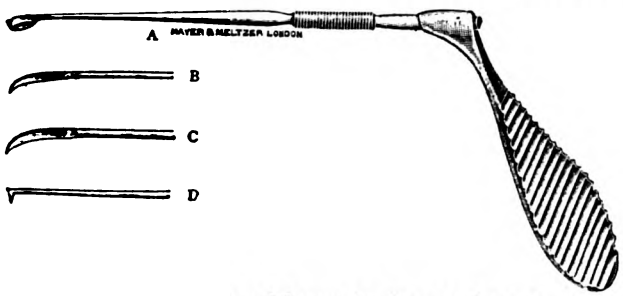

FIG. 164. BURKHARDT-MERIAN'S AURAL INSTRUMENT.
A. Curette. B. Myringotome. C. Furunculotome.
D. Hook for removal of foreign body.

sons: firstly, it presses out the contents of the furuncle; secondly, nts auto-infection from one hair follicle to another; and thirdly, to dilate the auditory canal.

er-treatment. If the furuncles have occurred during the of a middle-ear suppuration, the gauze plugging must be removed a few hours after the operation. The ear is then syringed out twice daily with a warm solution of lysol or carbolic acid, a ick of gauze soaked in a 10% solution of carbolic acid in glycerine fterwards inserted along the meatus.

here be no accompanying middle-ear suppuration, the packing not be removed for at least twenty-four hours. The pain pro- y the first dressing may be severe, but usually can be avoided by king the gauze with a 5% solution of cocaine in equal parts of a solution of hydrogen peroxide for a few minutes before removal, n gently withdrawing it whilst the ear is being syringed with a septic lotion. For the next two or three days it is sufficient to

insert a drain of gauze soaked in a 1 in 3,000 alcoholic solution chloride of mercury.

Results. Although cure may be expected, it is not uncom further furuncles to occur in crops at repeated intervals. This to auto-infection of the hair follicles, which to a large extent prevented by painting the surface of the acoustic canal daily least two or three weeks, with an oil containing a drachm of ni mercury to the ounce.

In addition a bacteriological examination should be made secretion; usually staphylococci are found. An autogenous may give good results, but the treatment at present may be co speculative.

In diffuse inflammation, although relapses are uncommon, su necrosis of a portion of the bony meatus may afterwards occur sult of involvement of its periosteal lining, and ultimately lead to of the acoustic canal from subsequent cicatrization.

Dangers. With ordinary precautions no accident should but the following may be mentioned: (1) if the furuncles are placed, the tympanic membrane may be incised inadvertently, middle-ear suppuration may result; (2) a too violent incision through the meatal cartilage posteriorly, and, as a result of se fection, may give rise to perichondritis of the auricle. This, fort is rare.

REMOVAL OF EXOSTOSES FROM THE EXTERN MEATUS

Indications. The indications vary, depending on whethe is a coexisting middle-ear suppuration or not.

If there be no middle-ear suppuration operation is not but is justifiable under the following conditions:

(i) *When one ear only is affected.* (*a*) If there be complet ness due to obstruction of the acoustic canal. The question of op however, should be decided by the patient, because it may be po indefinitely so long as no symptoms occur.

(*b*) If there be recurring attacks of discomfort or of pain in as a result of eczema, of otitis externa, or of actual pressure of the itself. The patient may desire operation to obtain permanent re

(*c*) If there be deafness of the opposite side from other cau the presence of the exostoses is causing deafness in the func good ear.

(ii) *When both ears are affected.* In addition to the indicat

en, operation is advisable on the worse side if there be almost
obstruction on both sides, accompanied by recurrent attacks of
owing to the narrowed passage of the acoustic canal becoming
blocked from accumulation of cerumen or epithelial débris.
tion is contra-indicated if previous examination indicates that
ess is due to a chronic middle-ear catarrh or internal-ear dis-
these cases restoration of hearing, which is the primary object
eration, will be impossible.
iddle-ear suppuration be present operation is generally

acute middle-ear suppuration operation is urgent if there are
retention of pus, *provided* it is impossible to dilate the lumen
ditory canal. Before resorting to operation an attempt should
rst be made to obtain free drainage, as the obstruction may
inflammatory swelling of the tissues lining the acoustic canal.
sation of the acute inflammation, this swelling may subside and
n of the acoustic canal again become patent; and if recovery
ing of the tympanic membrane takes place the hearing may
come normal, rendering the operation no longer necessary.
In chronic middle-ear suppuration operation is always indicated
are symptoms of retention of pus. It is also advisable as a
ctic measure, even when no acute symptoms are present.
ration. When there is no middle-ear suppuration.
operation may be performed either (*a*) through the external
or (*b*) by reflecting the auricle forward by a post-auricular

ugh the external meatus. This method is only indicated if the
is situated at the entrance of the meatus and is pedunculated.
neral anæsthetic is given, the patient being in the recumbent
The surgeon works by reflected light. After the ear has
roughly cleansed a large-sized aural speculum is inserted into
us and the outlines of the exostosis are defined with a probe.
gouge or chisel is used. It is inserted into the meatus in such
n that its point presses between the pedicle of the exostosis and
of the bony meatus. With successive sharp taps of the mallet,
e is made to cut through the pedicle, care being taken that the in-
t is not driven in too deeply, on to the tympanic membrane.
growth, which can now be felt to be movable within the meatus,
ally be removed by grasping it between the blades of forceps,
e expelled by syringing the ear. After its removal the acoustic
ould be plugged for a few minutes with a strip of gauze soaked in
n of cocaine and adrenalin chloride. This checks all hæmorrhage,

and at the same time enables the surgeon to get a good view of th parts to see if further growths are situated more deeply w meatus. Such growths, provided they are pedunculated and do on the tympanic membrane, can sometimes also be removed by method; much depends on their shape and situation. If sessi deeply placed, the operation may have to be completed by reflec ward the auricle. Before terminating the operation a clear vie tympanic membrane should always be obtained.

The meatus is finally syringed out with a 1 in 5,000 aqueous of biniodide of mercury and dried, a strip of sterilized gauze serted into the acoustic canal. A simple dressing is then appli side of the head.

Other methods of operation through the external meatus.

(*a*) Perforation of the exostosis, or enlargement of the smal existing between multiple exostoses, by means of the burr.

Although successful results have been recorded, this meth advised, as cicatricial tissue almost invariably causes closure of ing made. To keep the opening patent it is necessary to inser lead or silver canula, frequently a source of great discomfort.

(*b*) If the exostosis has a very fine pedicle, it may be possib through its base with a pair of forceps, but it is not so sure a as the employment of a gouge and mallet.

(*c*) Such methods as attempts to destroy the growth by r the galvano-cautery or by the pressure of laminaria tents sh avoided; they are useless and unsurgical.

By reflecting the auricle forward. This is indicated if the are multiple, have a broad base, and are deeply situated.

The position of the patient and the anæsthetic are the sa the previous operation. Reflected light may not be necessary.

The ear and the surrounding parts are carefully cleansed head is shaved for a short distance over and beyond the mastoid A curved incision is made *close behind* the auricle (Fig. 202), b at the upper level of its attachment and extending downwar the retro-auricular fold. The incision goes down to the bo auricle is reflected forward and the soft tissues are separated bone until Henle's spine and the posterior upper margin of the canal are brought into view. Any bleeding, chiefly from bra the posterior auricular artery, is at once arrested by pressure ligatures being afterwards applied. The assistant's duty is to auricle well forward and at the same time to keep the woun swabbing.

The fibrous portion of the canal is carefully separated from

n with the periosteal elevator, the growth, if possible, being ex-
without tearing through the thin layer of skin which covers it.
e method of procedure now depends on the character and number
exostoses present.
) If situated superficially, they are removed by chiselling through
ase with a gouge. They should be thoroughly removed, if neces-
utting through the normal bone well behind their base.
) If deeply placed, they are more easily removed by first chiselling
a part of the upper posterior wall of the external meatus. This
e in the same manner as in the early stage of the complete mastoid
ion (see p. 423). If possible the antrum should not be exposed.
re should be taken not to cut too deeply for fear of injuring the
nic membrane.
) If the exostoses spring from the anterior wall, it is necessary to
a T-shaped incision through the posterior membranous portion of
oustic canal in order to bring them into view clearly. This is
with a tenotomy knife, the flaps being held apart by means of
s. The growths can now be removed by means of the gouge and
.
) If the obstruction is due to multiple small exostoses forming an
r stricture within the bony canal, it is better to separate the mem-
us portion completely from the bony meatus. In doing so the
ver the exostoses tears through, so that the membranous portion
e reflected outwards as a finger-like process. To give greater
for the operation, the auricle and fibrous portion are pulled well
rd by means of a loop of gauze passed through the lumen of the
ginous meatus.
necessary, reflected light should now be used. To reach the
ses it may be necessary, as in the previous case, to remove part
posterior bony wall. With the gouge and mallet the exostoses are
lly chiselled away. They frequently abut on the tympanic mem-
so that their removal without injuring it may be well-nigh im-
le. It is of the utmost importance that the field of operation
be kept dry, if necessary by repeatedly mopping out the canal
ledgets of cotton-wool soaked in adrenalin solution. The chief
lty is to determine the situation of the tympanic membrane. A fine
is used to discover any existing chink between the growths; this
e a guide to show the direction in which to work. As soon as a
passage has been made, sufficient to allow of a view of the deeper
parts, the ear should be syringed out and dried, and a thorough
tion made. The tympanic membrane can usually be seen as a
h-blue membrane; at other times it can be recognized by touching

it with a probe. After making certain of the position of the mem
the rest of the operation is easy. A small seeker such
used in the mastoid operation is passed through the opening a
made, and with it the deeper limits of the exostoses can be felt.
opening is gradually enlarged by removing the growths piecemea
the chisel or gouge.

Although the burr is contra-indicated when operating throu
external meatus, it is frequently of great service in these cases in r
ing the walls of the canal smooth. The disadvantages of using
are, that it is less easy to control (unless the surgeon has had consid
experience in using it), and that it destroys all the epithelial lining
acoustic canal with which it comes in contact. It should, therefor
be used in those cases in which there is a complete ring of exostos
should be avoided if the exostoses are limited and if it is still p
to leave untouched a portion of the epithelial lining of the acoustic

When the surgeon considers he has successfully removed the ob
tion, he should verify this fact by syringing out and drying the ea
again obtaining a clear view of the tympanic membrane.

The fibrous portion is now replaced by inserting a finger in
cartilaginous meatus and pressing it back into the bony canal, the
being meanwhile pulled back into its normal position. The edges
posterior wound are sutured together and the auditory canal is
packed with gauze which should be inserted right down to the tym
membrane.

As a rule it is not necessary to make special meatal skin flaps, a
ful packing of the acoustic canal should be sufficient to keep the
in apposition.

With increasing experience I consider it wiser in cases of m
exostoses to perform the Schwartze-Kuster operation; that is, to
the antrum and remove the posterior wall of the acoustic canal wi
exception of its innermost part, the 'bridge.' This gives more
for removal of the growth from the anterior wall of the external m
and a better view of the tympanic membrane. After the operati
posterior fibrous portion of the meatus should be cut into a fla
p. 426), the posterior wound being then closed and the auditory
lightly packed with gauze.

In acute middle-ear suppuration, the tympanic antrum shou
opened; exostoses, if superficial and pedunculated, being removed
same time. If the exostoses are multiple and deeply placed, the
tion above described should be undertaken.

In chronic middle-ear suppuration, the complete mastoid ope
should always be performed.

er-treatment. The after-treatment is practically the same
r operation has been performed. The first dressing need not be
il the third day. The gauze plugging is then withdrawn and the
canal is syringed out and dried. If only a single exostosis has
noved the wound surface is small, and it is usually sufficient to
ome boracic powder and again insert a piece of gauze. This may
ted every second day, healing usually taking place within two
weeks. In the case of deeply situated multiple exostoses, espe-
removed from the anterior wall, considerable swelling of the
s lining the acoustic canal may occur as a result of the manipula-
n such cases, after syringing out any existing blood-clots, some
and adrenalin solution should be instilled into the meatus. An
eculum is then gradually worked into the auditory canal, which
mopped out with small pledgets of cotton-wool, and the deeper
e carefully inspected. Sometimes the torn ends of the fibrous
instead of covering the bony walls, are found to project into
stic canal and to cause considerable narrowing of its lumen.
ful manipulations with the probe or by stroking the edges with
lgets of cotton-wool, these rough surfaces may be smoothed
It is very important, in the early days of the after-treatment, to
any narrowing at the site of the operation. This is one of the
uses of subsequent failure. The gauze should always be rein-
ght down to the tympanic membrane, and if there is not much
it should be packed firmly against the posterior and outer por-
the canal in order to prevent subsequent stenosis from
ency of the cartilage to prolapse forward owing to the soft parts
een separated from the bony canal at the time of the operation.
wound behind the ear heals very quickly and the stitches can
be removed on the third or fourth day. Subsequent treatment
n preventing the formation of granulations over the wound area.
best accomplished by keeping the acoustic canal aseptic and dry.
lations occur they should be touched from time to time with
ted solution of trichloracetic acid. If healing has not taken
hin two weeks, it will frequently be advantageous to discontinue
e packing and, in its stead, to instil drops of pure rectified spirit.
middle-ear catarrh with secretion of fluid occurs, as a result
mpanic membrane having been injured, it may be impossible
ue the gauze packing. In these cases only a fine drain of gauze
e inserted into the meatus, the dressing being changed as fre-
as may be necessary.

ided asepsis is maintained, the middle-ear inflammation usually
rapidly with healing of the membrane. After healing has taken

place, inflation of the middle ear is recommended twice a week, fo or three weeks, in order to aid recovery and to prevent adhesions ing within the tympanic cavity.

Dangers. 1. If the exostoses be deeply situated, the tym membrane may be injured.

2. If much of the anterior wall of the acoustic canal be remove mandibular joint may be opened.

3. It is possible that the tympanic membrane may not be recog and, by working too deeply, the labyrinth or the facial nerve m injured.

Prognosis. Provided no accident has occurred during the tion, a successful result should be obtained. Stenosis, however, occur from cicatricial contraction if the operation has been incomp performed.

REMOVAL OF FOREIGN BODIES

Before considering the question of removal of foreign bodie following points cannot be emphasized too forcibly: (1) No at should be made to remove a foreign body until it is certain tha really exists. (2) Provided there is no middle-ear suppuration, a fo body left in the ear will very rarely cause any immediate harm. (3 most invariably the most serious complications are due to ill-ad haphazard attempts to remove the foreign body; as a rule from wo blindly in the dark without making use of reflected light.

If a foreign body be suspected, the surgeon should first car examine the auditory canal in order to determine its characte position. On this will depend the treatment to be employed.

If the object be a living insect it should be killed at once b instillation of warm oil, rectified spirit, or chloroform. This will immediate relief of the intense pain and tinnitus which may have set up by its movements against the sensitive tympanic membrane

The methods employed for the removal of a foreign body are s ing, extraction by instruments through the external meatus, a operation.

By syringing. In the vast majority of cases syringing is su ful, and therefore should always be tried except under the follo conditions: (*a*) If the foreign body be of such a nature that it m driven inwards; for example, a percussion cap for a toy pistol, with its concavity outwards.

(*b*) If there be much inflammation and swelling of the walls external meatus, unfortunately frequently due to previous unsucc

at extraction by instruments. In such cases forcible syringing se considerable pain, and, in addition, immediate removal of gn body may be impossible owing to the temporary occlusion eatus.

ss there are urgent symptoms of retention of pus behind the for-y, it is wiser to wait for a few days until the inflammation has in order that the canal may become more patent and permit e favourable opportunity for removal of the foreign body. The canal, in the meanwhile, may be mopped out two or three times ith pledgets of cotton-wool, and a 1 in 5,000 alcoholic solution lide of mercury afterwards instilled into the ear.

nethod of syringing has already been described (see p. 332). The hould be a large one, with its tip protected by some india-rubber The point is inserted within the meatus up against the foreign the stream of lotion is directed towards any chink which may veen it and the auditory canal. It may be necessary to use many ıls with considerable force before the foreign body can be ex-ıt the syringing should be stopped if pain or giddiness is caused. e foreign body cannot be removed at the first attempt, drops of spirit may be instilled into the ear several times a day, provided no urgent symptoms. This will tend to diminish any swelling ft tissues of the external meatus and of the foreign body if it is ole substance. The ear should again be syringed after two or rs. In many cases this will now be successful; if not, the for-y may be moved gently with a probe (using a speculum and light), great care being taken not to push it farther into the canal, and another attempt may be made to remove it by pro-yringing. If this fails it may be left *in situ* for a still longer provided there are still no symptoms requiring its immediate In some cases, instead of the instillation of alcohol, a 5% solu-arbolic acid in glycerine or olive oil proves more effectual.

e case of a hard substance, repeated attempts may be made to it before resorting to further measures; but in the case of a soft substance like a pea, it must not be forgotten that as a result ing swelling may occur which may eventually necessitate extrac-nstruments.

raction by instruments.

ations. (i) If inspection shows that the foreign body can be by a suitable instrument: for example a percussion cap, the vhich may be grasped by a pair of forceps (Figs. 165 and 179); ll boot-button whose shank, if it faces outwards, may be caught ll hook.

(ii) If repeated attempts have failed to remove the syringing.

(iii) If previous attempts by others have failed, and has been pushed in beyond the isthmus, and cannot b prolonged syringing.

(iv) If syringing produces violent giddiness, show presence of a perforation of the tympanic membrane.

(v) If there be symptoms of acute inflammation o or of pus being pent up behind the foreign body.

Operation. An anæsthetic may not be necessary foreign body is not too deeply placed within the ear, i pears to be a simple matter, and if the patient is of a pla

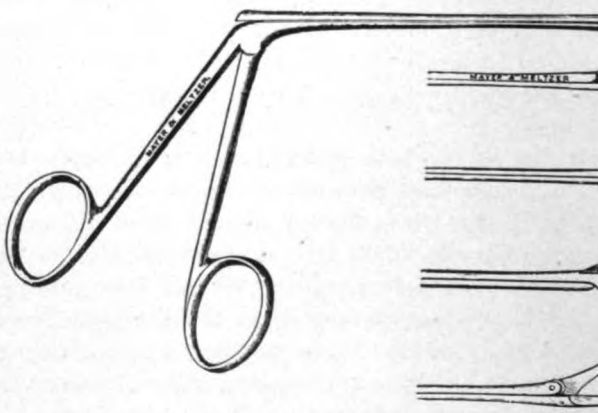

FIG. 165. CROCODILE FORCEPS. Two-thirds si
A, Points of crocodile forceps, full size. B and C, Aura
D, Aural scissors.

Otherwise, unless contra-indicated for some special r anæsthetic should always be given in children, and it i in adults for the following reasons: (1) Inability to re body after repeated attempts by syringing usually mean tion by instruments will be a somewhat difficult matte of injury to the meatal walls or tympanic membrane f movements of the patient during the operation is far risk of the anæsthetic. (3) If the foreign body ca through the meatus by means of instruments, the post- is indicated. This, if necessary, can be done at once under a general anæsthetic.

If no anæsthetic is given the patient may sit up in a the recumbent position is advised.

usually necessary to use an aural speculum, but if the foreign situated near the entrance of the meatus a sufficient view may ıed by pulling the tragus forward and the auricle backward. ımination is essential.

f the body be a soft substance, such as a pea, the core of an a fragment of wood, it is best removed by fixing into it some sharp hook (Fig. 164). These hooks vary in shape. They may d, or shaped like a crochet-hook, or have the sharp point placed angles to the shaft of the instrument.

e case of a round substance like a pea, especially if it is tightly within the meatus, its removal is sometimes facilitated by first into pieces by means of a small bistoury.

rule, the foreign body is impacted at the junction of the carti- and bony portion of the acoustic canal; sometimes, however,

FIG. 166. IMRAY'S SCOOP FOR EXTRACTING A FOREIGN BODY.

e deeply situated within the osseous meatus, usually the result ous attempts to extract it.

e former case, the instrument is passed along the upper posterior he canal between it and the foreign body, the point of the hook ot upwards or downwards so as not to project into the acoustic The instrument is first passed well beyond the foreign body, the shaft is twisted round so that the hook projects into the canal. With a quick movement it is drawn outwards a short so that the point of the hook pierces the impacted substance. action is now used and in the majority of cases the foreign body tracted.

is fails, an attempt should be made to pass a slightly curved ed scoop (Fig. 166) or curette between the foreign body and ior wall of the acoustic canal. The hook already fixed into gn body prevents it from being driven farther within the meatus, e scoop, if it can be got beyond the foreign body, can usually out.

e foreign body has been pushed in beyond the isthmus and lies ithin the osseous canal, it is better to pass the hook along the inferior wall of the meatus, because owing to the inclination mpanic membrane its anterior inferior margin is much more aced than its upper posterior part.

n the case of a hard substance, such as a piece of stone, coal, or

a bead, blunt hooks may be used instead of sharp ones. They passed into the meatus *beyond* the foreign body in the manner described.

(iii) *In other cases,* depending on its shape and position, the body is better removed by means of a snare, the loop of which nipulated round it and then drawn tight in the same manner extraction of a polypus.

The chief points to observe in these manipulations are (*a*) push the foreign body farther in and (*b*) not to injure the w meatus or the tympanic membrane.

Other methods of extraction are—(1) *Drilling through t body,* if it is a hard substance, and then inserting a fine hoo opening so made. (2) *The agglutinative method,* which cons ping a small paint-brush into a concentrated solution of seccot and then inserting it into the meatus until it comes in contact wi eign body. The brush is left in this position for several hours that it may become adherent to the foreign body; if so, on wi the brush from the ear, the foreign body should be extracte This method can only be used provided the ear is kept dry.

These procedures, although said to be successful in a few not recommended.

After-treatment. If the tympanic membrane and acou have not been injured, it is sufficient to dry the meatus and little boracic powder. If there be abrasions of the canal, a of gauze should be inserted and changed as frequently as moist with secretion, the meatus, if necessary, being also sy with an aseptic lotion. If there be acute inflammation of th the canal, accompanied by much swelling and purulent discha of glycerine of carbolic acid (1 in 10) may be instilled frequen the inflammation has subsided, an alcoholic solution of 1 in iodide of mercury may be employed. If the tympanic mem been injured, either from the presence of the foreign body itse the attempts at extracting it, the treatment is similar to th ordinary middle-ear suppuration.

Removal by operation. This may be done in the ways:

By means of a post-aural incision.

Indications. (i) If prolonged attempts to remove the fo by instruments have failed. This operation becomes imperati are signs of retention of pus within the middle ear.

(ii) If the foreign body has been pushed into the tympanic cannot be removed otherwise. In such cases, if the perforati

ıe foreign body is small, an attempt may first be made to dislodge bstance by injecting fluid into the middle ear through the auditory y means of the catheter and syringe (see p. 396). This method, er, is rarely successful.

peration. The procedure is the same as for the removal of exostoses . 341). After separating the fibrous from the bony portion of the an incision is made through it and the cut edges are held aside orceps. Usually the foreign body can now be seen lying within nal. It is best removed by passing a small fenestrated curette d it and levering it out. In some cases one of the hooks already oned will be found to be more suitable. Forceps should not be as they may inadvertently push the foreign body farther in. If reign body be very deeply placed, removal of the outer posterior n of the bony meatus may be necessary. The subsequent steps operation and its after-treatment are similar to those already ped in the case of an exostosis.

means of an operation upon the mastoid.

dications. (i) If the above measures fail to remove the foreign

) If there be symptoms of inflammation of the mastoid process, or ernal ear or of intracranial suppuration.

i) If there be facial nerve paralysis, the result of pressure from the n body.

peration. The operation performed depends on the condition Simple opening of the tympanic antrum may be sufficient in a f recent middle-ear suppuration, although it may be necessary also ıove a considerable portion of the posterior wall of the acoustic pefore the foreign body can be extracted. If these measures fail, empt may be made to dislodge the foreign body by forcibly syring- rough the aditus, or by the insertion of a probe through it, into the nic cavity. If this likewise ends in failure, it will then be neces- o perform the complete operation. These cases fortunately are

it be certain that chronic middle-ear suppuration already exists, mplete mastoid operation is indicated.

nerally speaking, if it becomes necessary to operate on the mastoid s, it is wiser to perform the complete operation at once, because, these circumstances, irreparable destruction within the tympanum most certainly already occurred.

e technique of these operations and their after-treatment are ped in the chapter on operations upon the mastoid process (see).

OPERATIONS FOR STENOSIS OF THE E MEATUS

Stenosis, or stricture of the auditory canal, is pract result of traumatism or inflammatory conditions; it is congenital.

Indications. (i) If there be deafness of the ot functionally good ear periodically becomes deaf from o narrow passage by cerumen or epithelial débris, and the of conservative treatment.

(ii) If there be recurrent attacks of otitis externa

(iii) If there be retention of pus, the result of infl external or middle ear, which is not relieved by conser

The operation is contra-indicated if there is accomp due to chronic middle-ear or to internal-ear disease, p no suppuration within the external or middle ear.

Operation. The method of operation depends stricture is membranous, fibrous, or bony in consisten is limited or is causing a general narrowing of the ac may take one of the following forms:

Dilatation. This method is not very satisfactory, recent cases of membranous or fibrous stricture of the After cleansing the meatus, a small laminaria tent is the stricture, and if the pain is not too severe it is left *i* twenty-four hours and then withdrawn. The ear is cleansed, and if possible a larger laminaria tent is su procedure is repeated until the maximum amount of di obtained.

Incision of the stricture. This also is limited to to fibrous strictures of the annular variety.

The operation, if necessary, may be performed und thetic, produced by subcutaneous injections, although u anæsthetic is preferable.

The ear and surrounding parts are surgically cleanse methods. The surgeon works by reflected light. The in either the sitting or the recumbent position, depen a local or general anæsthetic is given. In the latter c canal should be filled with cocaine and adrenalin solutio æsthetic is administered in order to diminish bleeding a

The ear having been dried, a conveniently large a inserted, and with a tenotome or a furunculotome ra

de through the stricture. One of the small flaps thus made is l with a fine pair of tenaculum forceps, and the surgeon cuts n its base, keeping the knife as close as possible to the wall of ustic canal. Each flap is treated in a similar fashion. Instead ing radiating incisions, the tissue forming the obstruction may sfixed through its base, the knife being made to cut in a circular right round the acoustic canal, keeping as close as possible to l.

completion of the operation, a piece of india-rubber tubing, of as size as possible, is inserted into the dilated canal. It should e removed for the purpose of cleansing and should be at once ed. A silver canula, if necessary, can afterwards replace the ubber tubing. This canula may have to be worn for months.

s operation is often most unsatisfactory, as the stricture, instead g annular as first supposed, may be found, on operation, to extend derable distance along the acoustic canal and, partially, to be a general thickening of the underlying bone.

ision of the stricture. The auricle is reflected forward and the nary steps of the operation are performed as already described noval of a deep-seated exostosis (see p. 343). The surgeon makes verse incision with a knife through the fibrous portion of the c canal, just external to the stricture, and carries it right round atus, thus separating the outer portion of the membranous from y canal. The fibrous portion is now pulled outwards by means ractor, and the thickened tissue, forming the stricture, is peeled m the surrounding bony meatus with a small periosteal elevator removed. If the stenosis is partially due to thickening of lls of the canal itself, it may also be necessary to chisel away derable portion of its upper posterior part. After completion operation a clear view of the tympanic membrane should be d.

his operation a considerable portion of the bony canal is denuded pithelial lining membrane, so that there is a special tendency to ormation of cicatricial tissue. To prevent this taking place, two s may be employed: (1) If much of the upper posterior wall bony meatus be removed, a post-meatal flap should be made and position by means of a catgut suture carried through the skin the auricle. The formation of such a flap is described as a step omplete mastoid operation (see p. 417).

If no bone be removed, the membranous portion is replaced *in* e posterior auricular wound closed, and as large an india-rubber possible is inserted into the meatus. A week or ten days later, as

soon as granulations begin to form, skin-grafting may be u
(see p. 430).

If grafting be not successful, the india-rubber tube or silv
must be kept constantly within the meatus (only being rem
cleansing purposes) until healing takes place.

The complete mastoid operation is indicated in the case o
occurring in chronic middle-ear suppuration if symptoms of
of pus occur.

In acute middle-ear suppuration, operation should be a
possible, as the lumen of the acoustic canal may again becon
after the acute inflammation has subsided.

OPERATIONS FOR ATRESIA

Atresia of the external meatus may be either congenital or a

Indications. (i) *In congenital cases* operation is only jus
the atresia is due to a *membranous web* situated in the outer pa
auditory canal, and if, as a result of tuning-fork tests and of
through the auditory tube, it is fairly certain that the midd
normal.

Operation is contra-indicated in cases of bony atresia.
attempts have been made to make an artificial canal in order t
the hearing power, a successful result has not yet been obtained
from the difficulty of retaining the patency of any canal so n
accompanying malformation of the middle ear renders a success
impossible.[1] Although the tympanic membrane is said to h
exposed by operation in a few cases, experience has shown
supposed tympanic membrane was really the capsule of the ma
joint.

(ii) *In acquired cases* operation is indicated (if the other ea
if the occlusion of the acoustic canal is in its outer part and
membranous or fibrous tissue, and if there is no previous h
middle-ear disease, and if the labyrinth is still intact.

Operation is not advised if the other ear is normal, unless th
particularly desires it.

Operation is contra-indicated if there is internal-ear deafne
affected side and if the other ear is normal; or if the closu
auditory canal is the result of a previous middle-ear suppura
healed. In the latter case the destructive changes within the
cavity will negative the chances of improving the hearing in spi
most successful operation.

[1] Hunter Tod, *Journal of Laryngology and Otology*, March 1901

ation. If the destruction be due to a fibrous band, an attempt nade to remove it by excising it by the intrameatal method. cases the post-auricular method is necessary.

hief point to remember is to make a large opening. For this e post-auricular method is to be preferred, as a considerable f the upper posterior wall can be removed and a large meatal oned (see p. 426).

lts. If the stricture or point of occlusion of the auditory canal l and composed of membranous and fibrous tissues, a good ually can be obtained, and there is no reason why complete of hearing should not take place if the labyrinth and tympanum al.

rtunately, as in all cases of stricture, there is a tendency for e to take place.

OPERATIONS FOR AURAL POLYPUS

is section only the aural polypi which project from the tympanic to the external acoustic meatus will be considered; whereas ment of granulations, and with them the minute polypi which limited to the tympanum, will be discussed in the chapter on s within the middle ear.

cations. An aural polypus should *always* be removed because, m the fact that it is a symptom of underlying disease, it may free drainage of the purulent discharge, and therefore become of danger.

ration. The simplest and the best method is *removal by the*

e case of small and soft polypi, the polypus is removed by traction rly called **avulsion**—after the snare has been tightened round its with a large, tough, fibrous polypus considerable force may be to tear through its pedicle. This procedure in the case of polypi from the region of the tegmen tympani has been known to to fatal meningitis. In such cases the pedicle of the polypus e cleanly cut through by the snare—so-called **excision.**

ural polypi are always associated with suppuration, it is espe- ecessary that the ear should be thoroughly cleansed before n.

cal anæsthetic (see p. 334) is sufficient in the case of smaller ut if the polypus be large and tough, it is wiser to give a general tic, such as gas and oxygen, or a 3% solution of cocaine may

be injected into the growth, which, according to Frey of Vienna removal absolutely painless; this, however, has not always experience.

The size of the polypus and the origin of its pedicle should mined before operating, if necessary by using a probe (Fig. 167 must be diagnosed from a bulging congested tympanic meml from the labyrinthine surface of the tympanum, which may be to view owing to complete destruction of the membrane having occurred.

A Wilde's snare is generally used. It is a fine angular sna with soft copper wire. Th the snare should be bent do and forwards and should b a size as just to surround th The snare is held between t and the first and second fing right hand (Fig. 168). Under good illumination, and using the and reflected light if necessary, the shaft of the snare is passed upper portion of the acoustic canal until the edge of the p reached. The loop is made to encircle the polypus (Fig. 169), being gr pushed inwa a gentle movement reaches the attachment growth. Th then tighter it firmly gr neck of the (Fig. 170) friable tissu through by traction and pus is withdrawn in the snare. Care must be taken not to injure panic membrane through which the polypus may be projecting; this reason that the loop is bent at an angle to the shaft of the that it may lie parallel to the tympanic membrane whilst in th grasping the polypus. If the polypus be very small, its pedicle clearly defined before operation, and the snare passed round it (Fig. 171).



FIG. 167. AURAL PROBE.

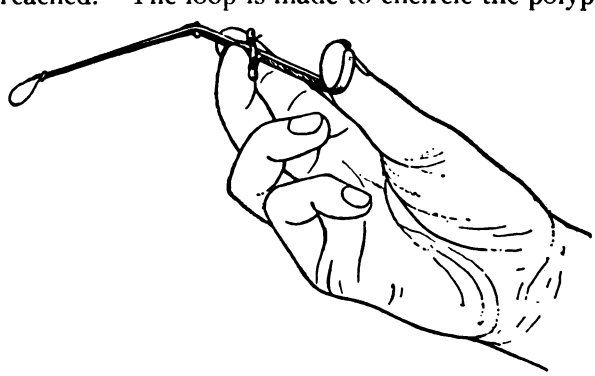

FIG. 168. WILDE'S AURAL SNARE. The snare is held in the usual position for extraction of a polypus.

If the polypus be very large and tough, the snare is made to

its pedicle as near to its attachment as possible, instead of emraction. The snare is then withdrawn, the polypus being afterasped and removed by means of forceps. In this latter case it necessary to use a stronger snare fitted with piano steel wire f the ordinary copper wire. On removal of the polypus there onsiderable hæmorrhage. After it has ceased, the ear is syringed dried. The acoustic canal is then inspected, and if it is found growth has not been removed completely, this can now be done lication of the snare.

final cleansing of the meatus, a strip of gauze is inserted, and protected with a pad n-wool and a bandage.

r-treatment. The should be removed wenty-four hours, and cleansed by syringing. opping it dry, drops of spirit should be in-

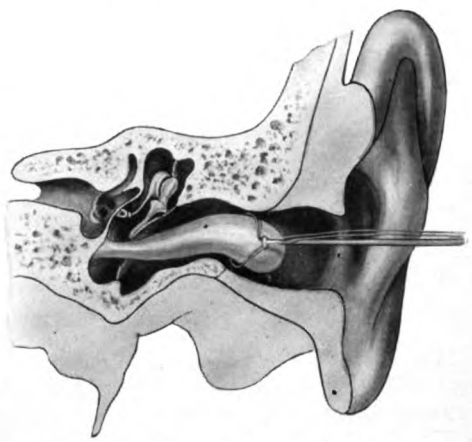

FIG. 169. WILDE'S SNARE BEING PASSED ROUND AN AURAL POLYPUS. (*Semi-diagrammatic.*)

removal of the first , any polypoid tissue emains may be cauterler cocaine anæsthesia ctual cautery, or by a chromic or trichlorid (see p. 372).

her treatment consists ng the ear clean and or the first few days it should be syringed daily, dried, and ops instilled. As the secretion becomes less, the syringing should nished. If the perforation be large, instead of instilling drops, ely powdered boric acid may be puffed in.

er methods of removal. These are not recommended, but are nentioned for the sake of completeness.

orceps. The rough-and-ready method of extracting a polypus from the ear by means of forceps, although formerly practised, been discarded as being unsurgical and dangerous.

ture. This operation consisted in passing a snare over the and grasping it tightly as near to its base as possible. The as then twisted round its axis in order to tighten the loop further obliterate the blood-supply of the growth, the wire of the snare fterwards cut through with pliers and the snare withdrawn.

After a few days the polypus became gangrenous from supply, and separated from its deep attachments.

Curetting. This method, which should only be ma case of small multiple polypi within the tympanum, w when discussing the treatment of granulations within the p. 421).

Dangers. Hæmorrhage is seldom profuse, but if be arrested by packing the meatus with gauze soaked adrenalin solution.

The chief dangers are injury to the contents of the as dislocation or removal of the ossicles; or subseq

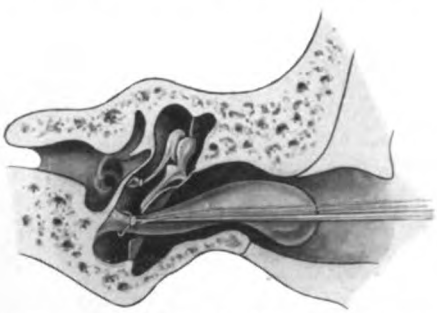

FIG. 170. WILDE'S SNARE GRIPPING THE NECK OF A POLYPUS. (*Semi-diagrammatic.*)

FIG. 171. POLYPU THE ATTIC REGION. position for the e polypus. (*Semi-diag*

These mishaps are usually the result of forcible extracti curetting the ear after this has been done. Meningitis, h known to occur, in spite of every precaution being tak caries of the tegmen tympani, the polypus has its origi mater of the middle fossa.

Prognosis. If the polypus be single and of recent probably of acute inflammation of the middle ear, its re complete recovery and cessation of the middle-ear suppu

In the case of multiple polypi associated with chr suppuration and usually signifying underlying bone dise may be frequent and further operations may become ne

It may here be emphasized that a polypus in itself but merely a symptom of disease.

After removal of a large polypus, the patient should under observation for a day or two in case of symptoms mation of the mastoid process arising and necessitating fu

CHAPTER III

RATIONS UPON THE TYMPANIC MEMBRANE AND WITHIN THE TYMPANUM

SURGICAL ANATOMY OF THE TYMPANUM

ıe tympanic membrane. The chief points to notice when ing on the tympanic membrane are its inclination and its relation labyrinthine wall of the tympanum.

e normal membrane is inclined obliquely downwards and forwards t it forms an obtuse angle of 140 degrees with the roof and an angle of 27 degrees with the floor of the external acoustic meatus. ants the inclination is even greater.

relation to the tympanum varies in its different parts. It lies t to the labyrinthine wall in the region of the umbo, being only imetres distant from the promontory, and is farthest from it in sterior quadrant.

unning backwards, just below the posterior fold, is the chorda ni nerve, which may be cut through in the act of paracentesis and ision of the posterior fold.

ıe tympanum. For the purpose of description, the portion of mpanum above the level of the tympanic membrane is known as the r *epitympanic cavity;* whilst the part below its level is called the or *hypotympanic cavity* (Fig. 172).

ıe **attic** contains the head of the malleus and the body and short s of the incus, and communicates posteriorly with the tympanic n by a variable sized opening—the aditus. Its roof, the tegmen ni, a plate of bone frequently of extreme thinness, separates the of the middle ear from the middle fossa of the cranium. The canal extends backwards along the medial and upper border of the num, passing superficial to the vestibule and above the fenestra to curve downwards posteriorly beneath the lateral semicircular which at this point forms the medial and inferior boundary of the

.

ıe **ossicles** form a movable chain fixed at three points: namely, tachment of the handle of the malleus to the tympanic membrane; sterior ligament of the incus, a feeble structure, binding its short

Digitized by Google

process to the entrance of the tympanic antrum; and the strong ligament connecting the foot-plate of the stapes to the margin fenestra ovalis.

In addition, the anterior, lateral, and superior ligaments of the also tend to keep it in position and limit its movements.

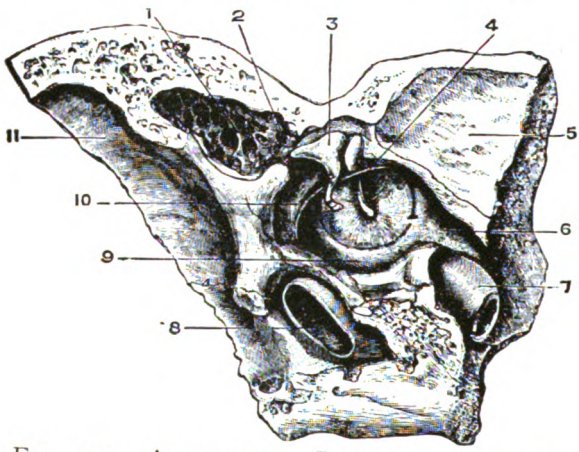

FIG. 172. ANATOMICAL PREPARATION OF THE MIDDLE EAR. 1½ nat. size. 1, Tympanic antrum; 2, Aditus; 3, Attic, containing head of malleus and body of incus; 4, Chorda tympani nerve; 5, Middle fossa of intracranial cavity; 6, Auditory tube; 7, Carotid canal; 8, Jugular vein in jugular fossa; 9, 'Cellar' or jugular surface of tympanum; 10, Canal of facial nerve; 11, Sigmoid groove for transverse sinus. (From the Author's *Diseases of the Ear.*)

The tensor muscle, extend the processus c formis, crosses panum to be into the media of the neck malleus; and pedius muscle e from the apex eminentia pyr is inserted into of the stapes.

These li and muscles divide the cav smaller compa such as the ou and Prussak's s that in some c flammation may ited to only a

the tympanum; a fact to be remembered in considering the ques operative procedures.

OPERATIONS UPON THE TYMPANIC MEMBRA

PARACENTESIS

Indications. The chief object of paracentesis (myringot simple incision) is to permit of escape of fluid from the tympanur

(i) *In acute inflammation of the middle ear*, if the acute sy continue in spite of palliative treatment, and the following conditi present: (*a*) An increasing congestion and bulging of the ty membrane, especially if accompanied by earache and pyrexia. (*b* obvious presence of pus within the tympanum, shown by a circums angry red or yellow protuberance on the tympanic membrane. (companying cerebral symptoms, such as drowsiness, vomiting, v

ulsions. (*d*) Tenderness over the mastoid process. (*e*) Par-
of pain acute enough to prevent sleep.
centesis should be done early in infants and in specific fevers.
rmer case even a slight middle-ear inflammation may give rise
e cardinal symptoms of meningitis, which frequently subside
s the result of simple paracentesis; in the latter, there may be
struction of the drum, which a timely incision may possibly

In middle-ear catarrh with exudation. Paracentesis is justifi-
rder to remove the secretion, if the hearing does not improve
nonth's treatment, owing to the existence of exudation within the
m.

As a preliminary to intratympanic operations.

ration. The auricle and surrounding parts are surgically
(see p. 309), the preliminary toilet, if possible, being carried out
alf an hour before the operation is performed.

ough apparently a trivial matter, it is of the utmost importance
r the acoustic canal as aseptic as possible in order to prevent
y infection of the tympanum from without.

wiser to give a general anæsthetic, such as gas and oxygen, as
of the operation may be intense. If this is refused, local
ia by Gray's solution (see p. 334) or by a subcutaneous injection
e and adrenalin may be employed. In infants an anæsthetic is
sary.

patient may be sitting up or lying down. If a general anæsthetic
een given, the patient's head must be held firmly by an assistant
to prevent sudden movement. The surgeon works by reflected
rder to obtain a clear view of the tympanic membrane.

point of election for the incision is through the posterior part
embrane, excepting when it is obvious from the bulging and
ce of the membrane that the incision must be made in the
inferior quadrant.

ncision is made by means of a paracentesis knife, which is shaped
y bistoury set at an angle to its handle (Fig. 173). The double-
ear-shaped knife is now seldom used, as with it there is a tend-
uncture rather than to incise the membrane.

tympanic membrane is pierced by the paracentesis knife at its
posterior margin. With a quick movement the drum is incised
e incision being carried in an upward direction midway between
eus and the circumference of the membrane posteriorly, until
s the pars flaccida (Fig. 174). In making this incision the
n of the membrane must not be forgotten. Owing to its lower

margin being more deeply placed than the upper, the
for those who have not had much practice in doing
begin their incision too high up, as they fail to realize
of the canal at this point. The soft tissues of the upp
of the external meatus close to the membrane, if muc
also be incised in the act of withdrawing the knife. I
chorda tympani nerve may perhaps also be cut, resultin
on the affected side for a time; this is a matter of no
a result of this free incision, drainage is given to the
tympanum, attic, and tympanic antrum.

In order to prevent rapid closure of the perfora
better drainage, some authorities advise making a flap
To do this,
incised upwa
upper border
carried back
wards before
from the wo

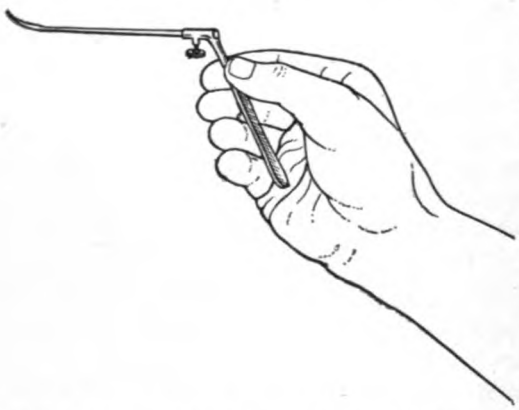

FIG. 173. PARACENTESIS KNIFE HELD IN POSITION IN THE HAND.

Occasion
flammation
attic, the par
ing deeply
bulging out
cover the
whilst the r
brane may
injected. In
sufficient to
area, beginning the incision just above the region
brevis and carrying it horizontally backwards to its po
(Fig. 175).

After-treatment. In acute middle-ear inflamm
first rush of blood and discharge has been mopped aw
of sterilized gauze should be inserted into the audito
ear protected with a pad of sterilized gauze. The dr
drain should be changed as often as may be necessa
the amount of discharge. The ear should not be syring
discharge becomes very profuse and thick.

In acute middle-ear catarrh with exudation, a Siegle
180) should be inserted into the meatus after free inci
brane, and as much fluid as possible extracted by sucti
gentle inflation by means of Politzer's method will help

e middle ear, which should then be mopped out of the external meatus. This should be repeated daily.

iculties and dangers. The usual fault is to mistake the con- osterior wall of the external meatus for the membrane.

ıe patient is not under an anæsthetic, the incision may be made dly, the membrane being only scratched. The pain thus inflicted se the patient to jerk away the head and probably prevent the ne from being incised freely. The incision, therefore, must be a bold and a rapid manner. It is better to make the incision too n too small.

must be taken not to plunge in the knife too deeply for fear

74. Tympanic Membrane showing in acute Suppuration of the Ear. Usual line of incision; dotted s continuation of incision to make a ing for drainage.

Fig. 175. Line of Incision in Acute Suppuration of the Attic.

ding the mucous membrane of the labyrinthine wall of the tym- This may result in adhesions between it and the membrane.

her, cases have been recorded in which a too violent incision red or dislodged the ossicles, or in which severe hæmorrhage rred, presumably from puncturing the bulb of the jugular vein, as projecting abnormally through the floor of the tympanum.

two chief causes of failure are insufficient drainage from too incision, which may necessitate a further operation, and sec- nfection from without.

ılts. In the majority of cases, provided free drainage is ed, the discharge ceases and healing of the membrane takes place thin a day or two to four weeks, depending on the character of If the symptoms continue it may become necessary to perform oid operation (see p. 418).

ARTIFICIAL PERFORATION OF THE TYMPANIC MEMB

The object of the operation is to equalize the pressure v tympanic cavity and external meatus so as to enable vibrations to be transmitted more readily by the membrane and chain c to the inner ear.

Indications. (i) In the case of an extremely calcified which apparently cannot vibrate.

(ii) To relieve tinnitus or vertigo which appears to be alteration of tension within the tympanum, the result of an im stricture of the auditory tube.

(iii) As a means of diagnosis. If the hearing be improv subjective symptoms relieved as a result of the artificial open if the perforation closes (as it probably will do), the surgeo position to suggest some more radical measure, such as ossi (see p. 375).

Operation. Two methods are employed: (i) the knife galvano-cautery. The perforation should be made in the poster quadrant.

In favour of the galvano-cautery is the fact that the perfor not tend to close so rapidly. On the other hand, considerabl may be done unless it is applied with extreme care. For this r wiser to operate under a general anæsthetic, such as gas and ox

If the *paracentesis knife* be used, it is not sufficient to mak incision; a small triangular flap must be excised. The operati be performed under good illumination. The paracentesis kn serted boldly through the membrane a little behind and above The membrane is incised in an upward and slightly backward towards its margin; then downwards parallel to its posteric then horizontally forward, meeting the original point of the The excised portion of the membrane is removed by seizing it v pair of crocodile forceps, or by means of a fine snare, if it has completely detached.

The *galvano-cautery* is applied cold; when it is in contact drum, the circuit is closed so that the point of the cautery bec hot. After the membrane has been burnt through it is v rapidly so as not to scorch the surrounding tissues. In using th care must be taken to push it only just through the membran of injuring the inner wall of the tympanic cavity.

After-treatment. The after-treatment consists in prot ear by a strip of gauze, which is changed as often as may be nec

DIVISION OF THE ANTERIOR LIGAMENT

lication. It is advised by Politzer in those cases of marked on of the drum in which inflation causes an immediate improve- n hearing, which, however, only lasts a short time. In several olitzer found the cause of this to be due to tension of the anterior nt causing retraction of the malleus.

eration. The anterior malleolar fold is divided with the para- knife just in front of the processus brevis of the malleus. The s then introduced 2 millimetres in- through the incision and made to cut upward direction as far as the pars (Fig. 176, c). This should divide ament.

he operation be successful, improve- n hearing and also diminution of the ive noises should take place.

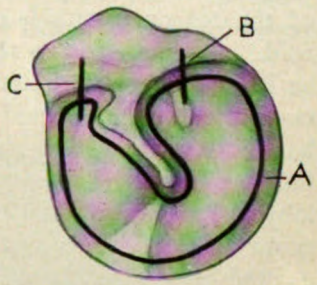

FIG. 176. LINES OF INCISIONS IN INTRATYMPANIC OPERATIONS. A, Removal of membrane in ossiculectomy; B, Division of posterior malleolar fold; C, Division of anterior ligament.

SION OF THE POSTERIOR FOLD

lication. The same as for the r ligament. Owing to the increased of the upper posterior quadrant of mpanic membrane, it is assumed that ovements of the malleus are dimin- nd with this the hearing power. Seeing, however, that the promi- f the posterior malleolar fold is due to the projection outwards of ocessus brevis as a result of the handle of the malleus having indrawn with the membrane, it is difficult to understand how its n can possibly be a means of restoring the retracted membrane to mal condition.

the few occasions on which I have performed this operation, rovement has followed. Others, however, maintain that it may d in certain cases. This, perhaps, may be possible if it is com- with other intratympanic operations, such as division of the r ligament or of the tensor tympani muscle.

eration. The paracentesis knife is inserted through the most ent part of the fold and is made to cut through it from above ards (Fig. 176, B). If this is successful, gaping of the cut edges lace and the membrane assumes a less retracted position, and ed hearing with diminution of the subjective symptoms should on inflation of the middle ear.

INTRATYMPANIC OPERATIONS

General considerations with regard to intratympanic o and their results. The chief difficulty, from a clinical point is to determine beforehand the exact pathological changes whic exist within the tympanum. For this reason the indicatio with regard to operation are somewhat empirical. For exa traction of the tympanic membrane may be due to closure of the tube; to adhesions between it and the promontory; to co of the tensor tympani, of the anterior ligament, or of the fold. An operation to remove only *one* of these causes may, be insufficient; the difficulty is to know what to do. Even i operations are performed, the result may be negative owing to having already taken place between the ossicles themselves, binding down of the incudo-stapedial joint or of the stap labyrinthine wall of the tympanum. And apart from this, eve porary benefit is obtained, the final result may be worse than th existed before the operation owing to the natural tendency for to re-form.

The prognosis is better in the case of post-suppurative th non-suppurative conditions.

Improvement by operation may be hoped for if a temporar in the hearing power, with diminution of the subjective sym obtained as a result of inflation; especially in those cases in malleus is only locally adherent to the promontory.

Generally speaking, these operations are not recommende to the impossibility of being able to give a good prognosis, and they can only be considered as experimental.

These operations are contra-indicated—(1) If there be in deafness.

(2) If the stapes (as shown by tuning-fork tests and Gellé' ankylosed within the fenestra vestibuli, especially in the case o rosis.

(3) If the membrane be completely adherent to the labyrin at its upper posterior quadrant, especially if this is of long sta the stapes will almost certainly also be fixed by adhesions.

DIVISION OF INTRATYMPANIC ADHESIONS

The position and extent of the intratympanic adhesions var ingly, and may be the result either of middle-ear catarrh or sup The following conditions may be found:

Adhesion of the handle of the malleus to the promontory, the e tympanic membrane being movable.

Adhesions between other parts of the tympanic membrane and nthine wall of the tympanum, either by bridles or bands of sue, or by the membrane itself being adherent over a large area.

Adhesion of the edge of a perforation to the labyrinthine wall.

Adhesions surrounding the articulation between the incus and d the stapes itself.

ations. Operation is justifiable in the case of adhesion of the the promontory if the rest of the membrane is freely movable; mbrane bulges outwards and there is temporary improvement

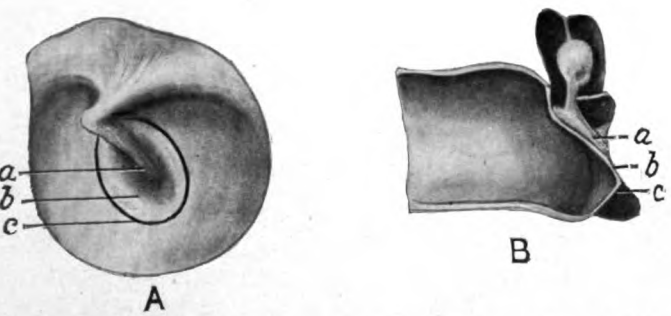

7. CUTTING THROUGH INTRATYMPANIC ADHESIONS. The malleus is o the promontory. A, Surface view; B, Vertical section. *a*, Handle of s; *b*, Membrane adherent to the promontory; *c*, Line of incision to cut ne membrane.

ng on inflation; and if examination shows that the labyrinth This operation is all the more indicated if there is marked on both sides: it should then be attempted on the worse side. ver, the intratympanic adhesions are extensive, it is very doubt- ner an attempt to separate the free part of the membrane from adherent to the labyrinthine wall is worthy of consideration.

ust also be remembered that adhesions in the region of the stapes e seen, unless a large perforation of the membrane already Operation is then only justifiable as a last resource if there is deafness accompanied by distressing subjective symptoms.

ration. Unless the patient is very sensitive or nervous, local ia is sufficient. It is more convenient for the patient to be p in a chair than to be in the recumbent position. The surgeon reflected light. Before the operation is begun, the ear must be y cleansed and carefully dried.

(i) *Adhesion of the handle of the malleus to the promontor* a paracentesis knife the membrane is incised round the hand malleus (Fig. 177). A small sickle-shaped knife, fixed at right its shaft, is then inserted through the incision (in front of or b malleus as may be most convenient to the operator) and is ma through the adhesions between the malleus and the promonto 178). In order to make sure that this has been accomplished ring-knife, such as is used in the operation of ossiculectomy, round the tip of the malleus, between it and the labyrinthine wa promontory, and slight traction is then exerted in order to pull th of the malleus outwards from the labyrinthine wall.

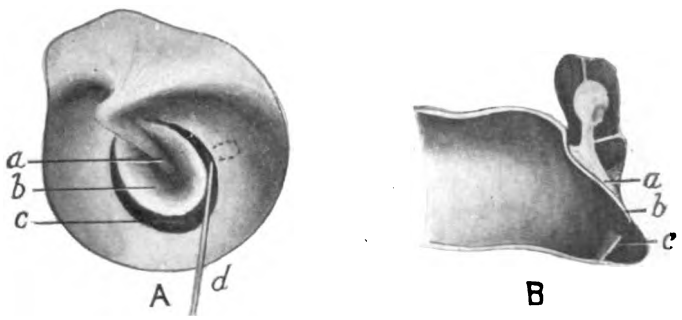

FIG. 178. FREE EDGE OF TYMPANIC MEMBRANE CUT THROUGH. A view; B, Vertical section. *a*, Malleus adherent; *b*, Membrane adheren edge of membrane; *d*, Spatula freeing membrane.

Provided asepsis has been maintained, this small operatio gives rise to any inflammatory reaction. The after-treatment in inserting a strip of gauze into the acoustic canal; if it becom with secretion, it should be changed.

Many methods have been devised to prevent recurrence of a but few are successful. Amongst these are daily inflation of by means of Politzer's method or the catheter; the injection o the middle ear; and the insertion of small pieces of celluloid the malleus and labyrinthine wall of the promontory accordin method of Gomperz. Another method is to *resect the handl malleus* (Fig. 181). After being freed from the promontory described, the manubrium is cut through with a pair of fine sciss 165, *d*) just below the processus brevis, and the lower fragme moved by means of Sexton's forceps (Fig. 179).

(ii) *Adhesion between the membrane and the labyrinthine w tympanic cavity.* Siegle's speculum should be used to deter position and extent of the adhesions (Fig. 180).

are two methods of operation:
n the case of bands forming a bridle between the tympanic
e and laby-
wall, an at-
ay be made
rough them.
one by incis-
membrane
paracentesis
front of or
he adherent
and then in-
through this
the sickle-
ife. By rotating it upwards or downwards, as the case may be,
s forming the adhesions are cut through. If this has been suc-

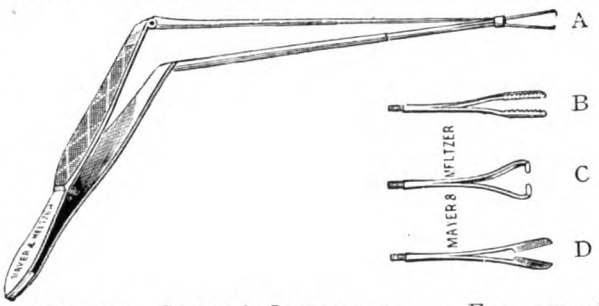

FIG. 179. SEXTON'S INSTRUMENT. A, For removal of a foreign body; B and C, For removal of the malleus; D, Scissors.

performed, and if the
n of the membrane was
ue to these bands, the
membrane will be
be freely movable on
ing the pressure of air
ne external meatus by
Siegle's speculum.
If the adhesions be
e, the only method
g a chance of success
arate the free portion
tympanic membrane
e part adherent to the
ine wall, leaving the
situ. To do this the
ne is incised with a
esis knife just beyond
in of the adherent por-
incision being carried
und the affected part.
spatula, bent at right
its shaft, is then inserted through the incision and passed round
the movable portion of the membrane so as to free it completely
8).

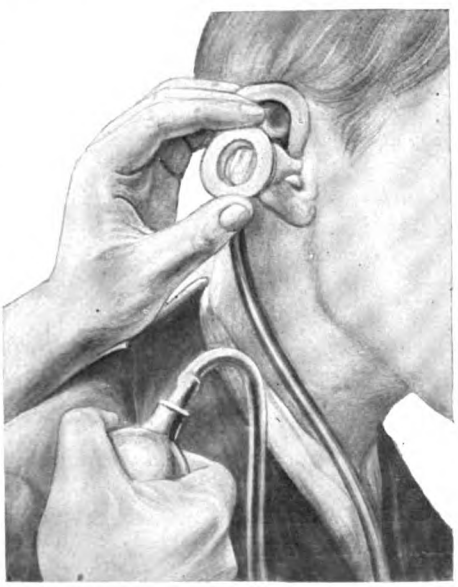

FIG. 180. METHOD OF USING SIEGLE'S SPECULUM.

Adhesion of the edge of a perforation to the labyrinthine wall.

If the middle-ear suppuration has only recently ceased, it may
ficient to divide the adhesion with a small knife curved on the
afterwards force the tympanic membrane outwards by means of i
through the auditory tube, and by rarefaction of the air within
ternal meatus. In the majority of cases, however, it is neces
excise the adhesion, especially in the more chronic conditions.
done by cutting through the movable part of the membrane just
the adherent portion (*vide supra*).

(iv) *Adhesions surrounding the articulation between the in
stapes, and the stapes itself.* These adhesions can only be obse
a large perforation involves the upper posterior quadrant. Ev

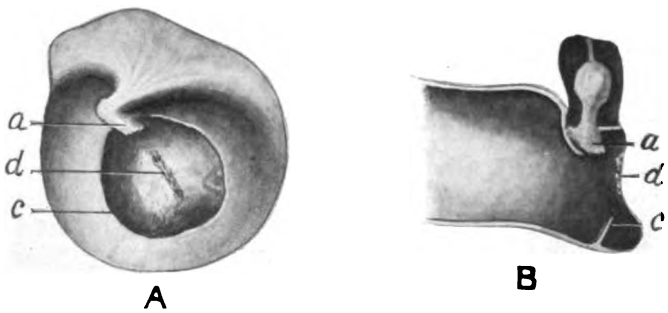

FIG. 181. DIVISION OF INTRATYMPANIC ADHESION WITH EXCISION OF
OF MALLEUS. A, Surface view; B, Vertical section. *a*, Remains of
(handle already excised); *c*, Free edge of membrane; *d*, Scar tissue
montory, at which point malleus and membrane were previously adhere

it may be anatomically impossible to see the stapes. The o
should only be performed if definite bands of adhesions can
Sometimes, although rarely, it happens that such adhesions are
If the incudo-stapedial joint be fixed to the labyrinthine wall
tympanum, the adhesions are separated from it by passing th
between the joint and the labyrinthine wall. In order to cut
adhesions surrounding the base of the stapes, a small horizontal
should be made along its upper margin, and also along the lower i
in view. This operation is seldom of any value.

TENOTOMY OF THE TENSOR TYMPANI

Indication. The chief indication for this operation is
retraction of the tympanic membrane, in a case of middle-ear d
in which there are no adhesions between the membrane and th
rinthine wall of the tympanum, and in which it is assumed t
retraction is due to shortening of the tensor tympani muscle.

peration. The first step of the operation is to incise the tym- membrane with a paracentesis knife in a vertical direction just the margin of the malleus. At the same time the posterior fold cut through, if required, by continuing the incision upwards. gh the incision thus made, Schwartze's tenotomy knife (a very fine pointed instrument curved on the flat (Fig. 182)) is inserted, its being directed upwards. The knife is pushed upwards until its s on a level with the processus brevis. The handle is then rotated rward direction so that the sharp edge of the knife, which is kept o the posterior border of the neck of the malleus, makes a circular ment forwards and downwards and thus cuts through the tendon muscle. If the knife has been too deeply inserted, the attempt te the shaft forwards will be resisted by the projecting processus ariformis. To overcome this difficulty the shaft of the instrument ted backwards so as to raise the point of the tenotomy knife and ree it; the instrument is then withdrawn slightly and the shaft

FIG. 182. SCHWARTZE'S TENOTOMY KNIFE.

rotated forwards. The division of the tendon can be felt distinctly, ay be accompanied by a slight crackling noise; after this has been d, the knife is rotated backwards and withdrawn through the in- in the tympanic membrane.

fter-treatment. There is usually a slight effusion of blood the tympanum, but no special treatment is required beyond keep- e ear aseptic. Absorption takes place rapidly.

e *result* of the operation is disappointing. There is seldom any vement with regard to hearing; a few cases, however, have been ed in which the attacks of vertigo have diminished in intensity.

TENOTOMY OF THE STAPEDIUS

dications. They are limited.

) As the result of middle-ear suppuration the malleus and incus ecome exfoliated. The theory has been advanced that the unop- action of the stapedius muscle prevents free movement of the stapes se cases, and for this reason tenotomy of its tendon is advocated. is operation, however, should only be performed provided that ge of the membrane is not adherent to the labyrinthine wall of mpanum, and there is no internal-ear deafness.

) The operation is also performed as a preliminary measure to al of the stapes (see p. 385).

Operation. The operation is simple, as the head of th and the tendon of the stapedius muscle are usually within view sequence of the destruction of the tympanic membrane. Th cleansed and dried, and the part rendered insensitive by the application of a pledget of cotton-wool soaked in cocaine solutio tiny tendon is severed with a snick of the paracentesis knife, through it from above downwards under good illumination.

Results. These vary; usually there is no improvement, bu times marked increase of hearing occurs. As the operation ca harm and can be done without any inconvenience to the patient be attempted subject to the restrictions given above.

REMOVAL OF GRANULATIONS FROM THE TYMP

Indications. Granulations should always be removed servative treatment fails.

Operations. (*a*) *Cauterizing;* (*b*) *Curetting.* The former is employed when the granulations are very small and localis latter when they are multiple and larger.

Cauterization. The tympanum is cleansed and rendered an (see p. 333). The acoustic canal and tympanum are then c dried. This is of importance in order to prevent scalding of rounding tissues during the act of cauterization. The ordinary cautery is used; only a weak current is necessary as the point cautery, of necessity, is very small. Under good illumination, the is inserted cold along the auditory canal until it just touches the tion. The circuit is then closed, and on the point of the cautery b white-hot, it is pressed against the granulation and then rapidl drawn from the ear. The current should not be shut off until the is withdrawn, otherwise it will adhere, on cooling, to the tissu which it is in contact, and on withdrawal will cause bleeding.

Instead of the electric cautery, the granulation may be touch a bead of chromic acid fused on to a probe, or with a saturated of trichloracetic acid. The galvano-cautery has the greatest Chromic acid has the disadvantage that unless it is very ac applied it tends to affect a larger area than was possibly intende chloracetic acid, although more localised in effect, is not so pot

After-treatment consists in blowing in a slight amount of bo powder and keeping the ear dry.

Curetting. This is performed by means of small ring (Fig. 164) or sharp spoons. They vary in size, and are either

nt in different directions to the shaft of the instrument. The in-
ient selected depends on the position and size of the granulation.
o minimize the hæmorrhage, adrenalin may be added to the cocaine
ion. The curette is made to encircle the granulation and cuts
gh its attachment with a firm movement, limited to the area of the
ılation. Curetting should not be done in a haphazard fashion, but
erately under good illumination. If bleeding occurs it must be
ted before further curetting takes place.

fter-treatment. The ear is syringed out to remove any fragments
anulation tissue or blood-clot. It is then dried and a strip of ster-
gauze inserted. After twenty-four hours this is removed and
of rectified spirit, if necessary containing ten grains of boric acid
drachm of perchloride of mercury lotion to the ounce, may be in-
l into the ear three or four times a day.

Dangers. With due care none should occur. The following
aps, however, have occurred from too violent curetting: (1) Injury
splacement of the ossicles; (2) internal-ear suppuration from dis-
ng of the stapes or injury to the promontory; (3) facial paralysis;
neningitis from injury to the tegmen tympani; (5) acute inflamma-
of the mastoid process.

Results. Provided that the granulations are localised and due to
mmation of the mucous membrane, a good result may be anticipated.
owever, there be underlying bone disease of the tympanic walls, or
e mastoid process be already affected, recurrences are usual, and
er operative treatment may become necessary.

OPERATIONS UPON THE OSSICLES

DIRECT MOBILIZATION OF THE OSSICLES

he object of the operation is to improve the hearing by breaking
the fibrous adhesions within the tympanum, which diminish the
ity of the ossicles.

Direct massage of the malleus. Indications. (i) As a
peutic measure. If the malleus be adherent to the promontory and
is no improvement on inflation, but only as a result of pneumatic
age.

ii) As a means of diagnosis. If temporary improvement takes
it may be assumed that the stapes is not absolutely fixed, and that
eafness is partly due to adhesions preventing movements of the
es, a condition which may point to the advisability of performing
ılectomy in suitable cases.

Operation. The ear is rendered insensitive by means of co
Gray's solution (see p. 310).

The manipulation is carried out with a Lucae's probe (Fi
Within its handle is a spring to render its movements resilient
its tip is a cup-like depression to embrace the point of the p
brevis of the malleus. The tip of the probe may be covered b
layer of cotton-wool or india-rubber.

The probe is inserted, under good illumination, into the
meatus and is applied to the processus brevis of the malleus. Th
tions are given by the rapid movements of the hand from the w
arm being kept fixed. This procedure, which may be painful
not last longer than one minute. Frequently there is consider
action, shown by congestion about the processus brevis and Sh
membrane. It is therefore wiser not to repeat the procedure at
intervals than one week.

FIG. 183. LUCAE'S PROBE.

Results. It is difficult to foretell what the result will be,
chiefly dependent on the extent of the adhesions already existing
the tympanum and on the mobility of the stapes within the
vestibuli. If the latter is already fixed, then improvement is im
If, however, the adhesions are limited, a better result may be
by this method than by pneumo-massage and inflation. The
must be guided by the extent and duration of the improvement as
long to continue the treatment. Unfortunately, relapses are not
mon, though temporary benefit may be obtained.

Massage of the stapes. This is only done as a last
in the hope of obtaining some improvement in hearing.

Indications. (i) In cases in which mobilization of the mal
caused no improvement, and it is hoped, from the history of t
that this is due to fibrous adhesions fixing the stapes within the
vestibuli. This condition must be carefully distinguished fr
sclerosis or bony ankylosis of the stapes, in which latter conditi
such procedure is absolutely contra-indicated.

(ii) Direct mobilization may be undertaken as a prelimin
previous to removal of the stapes itself. If the stapes is mova
slight improvement occurs, then its removal may be justifiabl
certain conditions. If, however, the stapes is fixed and no impr
occurs, then its removal will be attended with such difficulty as
to negative this being attempted.

peration. If a perforation of the upper posterior quadrant be
nt, a small pledget of cotton-wool soaked in a 20% solution of
ne is brought into contact with the labyrinthine wall of the tym-
n. After a few minutes Lucae's probe is placed in position against
ead of the stapes and the vibratory movements are carried out. If
rforation of the drum exists, then it is first necessary to excise
in the upper posterior quadrant of the membrane.

ifficulties. The chief difficulty is anatomical. Projection forward
e upper posterior part of the tympanic ring or a deeply placed
of the fenestra vestibuli may prevent a
of the stapes.
the membrane has to be incised, the slight
nt of bleeding may also prevent a good
being obtained.
here is no actual danger in the operation,
the stapes is fixed or if much force is
it is by no means difficult to fracture the
of the stapes.

FIG. 184. TO SHOW SITES OF PERFORATION IN ATTIC SUPPURATION AND CARIES OF THE OSSICLES. 1. Perforation in front of malleus. 2. Perforation behind malleus. 3. Perforation involving posterior attic region and upper posterior part of membrane. (From the Author's *Diseases of the Ear.*)

REMOVAL OF THE OSSICLES

xcept under the most rare conditions only
alleus and incus are removed; the stapes,
sible, being left undisturbed.
hese operations will therefore be consid-
separately.

emoval of the malleus and incus.
peration was first proposed by Schwartze
73, and later by Kessel, Ludewig, Sexton,
eroni.

dications. The indications for operation may be considered with
l to (1) chronic middle-ear suppuration and (2) non-suppurative
e-ear disease, whether the result of a previous middle-ear suppura-
r of a chronic middle-ear catarrh.
chronic middle-ear suppuration, the chief object of the operation
nsure drainage and if possible to remove the cause of the suppura-
in non-suppurative conditions, to improve the hearing.
may here be mentioned that the position of the perforation in the
egion is frequently of importance when considering the question
atment. If situated in front of the malleus, the disease is probably
l to the outer attic region and malleus; if just behind the malleus,
robably both the malleus and incus are affected; but if the perfora-
xtends farther back, involving the upper posterior quadrant of the

drum, especially its bony margin, it suggests disease not only ossicles together with the walls of the aditus and tympanic antr perhaps also of the mastoid process (Fig. 184).

(i) *In chronic middle-ear suppuration.* Before operation sidered, it is presumed that conservative measures, such as sy instillation of astringent and antiseptic drops, and washing ou attic by means of Hartmann's canula with various solutions, ha given a thorough trial and failed.

(*a*) If the suppuration be limited to the attic region (altho main portion of the tympanic membrane is intact), provided marked deafness and symptoms of inefficient drainage indic recurrent attacks of headache, a feeling of heaviness or giddi pain radiating up the head on the affected side.

(*b*) If there be caries of the malleus and incus, and the ou wall, with recurrence of granulations after repeated removal, e if accompanied by cholesteatomatous formation, provided ther evidence of disease of the mastoid process itself.

(*c*) Although the general symptoms and the condition fo examination justify the complete mastoid operation, yet if the refuses to have this operation performed, the simpler opera ossiculectomy may be undertaken if desired. This will permit drainage and diminish the risk of future intracranial complicati should, however, be clearly explained to the patient that no gu can be given with regard to effecting a permanent cure as a resul operation.

(ii) *In non-suppurative conditions.*

(*a*) If there be marked middle-ear deafness, the result of ad and the malleus is fixed to the promontory. Operation is ju if transient improvement of hearing is obtained after each infl the middle ear.

(*b*) If, as the result of artificial perforation, made under th tions already laid down, temporary improvement takes place, bu relapses owing to closure of the perforation (see p. 364).

(*c*) If tinnitus and attacks of vertigo, due to marked retra the membrane, are temporarily relieved by inflation. In suc operation should only be carried out as a last resource after a measures have failed to cure, and only if the symptoms are ver and distressing.

(*d*) If there be marked middle-ear deafness with extensive ad on both sides and the evidence points to the stapes being freely m The operation is justifiable, as an experiment, on the worse side

Operation. The only operation to be considered is the intr

Stacke originally suggested reflecting the auricle forward, and re- the ossicles, together with the lateral attic-wall. This method, er, has now been given up as being too radical, but will be men- later on in connexion with the mastoid operation (see p. 423).

less contra-indicated, a general anæsthetic should be given, as it always possible to foretell whether the operation will be difficult . In addition it may be necessary to curette out granulations so to remove the lateral wall of the attic. Unless the patient insensitive, this is almost impossible under local anæsthesia (see .

ore the anæsthetic is given, the ear should be filled with a 5% n of cocaine containing a 1 in 2,000 solution of adrenalin chloride r to diminish the bleeding during the operation.

e field of operation is isolated from the surrounding parts by cov- he head with a sterilized towel having an opening cut in it just nt to expose the auricle and meatus.

e following are the steps of the operation: (1) freeing the malleus s attachments to the tympanic membrane, and from the laby- e wall of the tympanum, if adherent to it; (2) cutting through don of the tensor tympani muscle; (3) removal of the malleus; noval of the incus; (5) removal of the lateral wall of the attic; retting out of granulations, if present. The method of operation according to the condition found.

noval of the malleus. In post-suppurative and non-suppurative ons the chief cause of failure is the recurrence of adhesions, so s reason it is wisest to remove the membrane as completely as .

h a paracentesis knife the membrane is incised below and behind lleus. The incision is then carried upwards along its posterior to the posterior malleolar fold, then round the complete margin ympanic membrane and along the anterior fold and border of the , so as to meet the original point of the incision. The knife is -inserted just in front of the processus brevis and cuts through erior ligament in an upward direction; in a similar fashion the or malleolar fold is also cut through (Fig. 176).

e next step is tenotomy of the tensor tympani muscle (see p. 371). e malleus thus freed can easily be removed by seizing its handle pair of Sexton's (Fig. 179) or crocodile forceps (Fig. 165). In ng the malleus it is necessary to remember that its head is situated the attic and that it cannot be pulled out directly, but must first vn downwards until it is seen within the tympanum. If this ion be not taken, the neck of the malleus may be broken, leaving

the head behind. If this takes place its extraction may be a
of difficulty.

Instead of using Sexton's forceps, the malleus may be remo
means of Wilde's snare. This is the method advocated by Sch

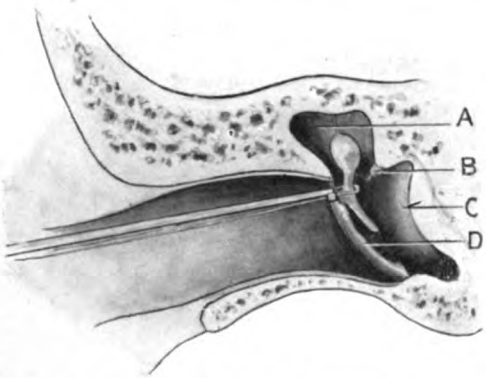

FIG. 185. REMOVAL OF THE MALLEUS BY WILDE'S SNARE. *First position.* After cutting through the tensor tympani muscle by Schwartze's method.

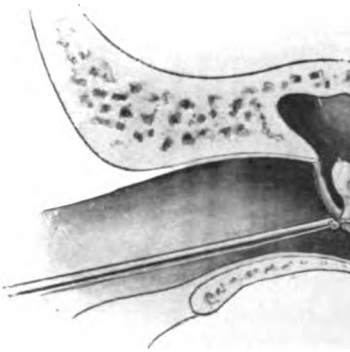

FIG. 186. REMOVAL OF THE M BY WILDE'S SNARE. *Second* Malleus pulled down from atti to be withdrawn from acousti

After cutting through the tensor tympani muscle, the loop of th is threaded over the head of the malleus and guided upwards embraces its neck. The loop is then drawn tight so as to hold the firmly in its grasp. The ossicle is extracted by first pulling it



FIG. 187. DELSTANCHE'S RING-KNIFE.

wards (Fig. 185), so as to dislodge it from the attic, and then l (Fig. 186).

Another method of extracting the malleus, and in my opin one to be preferred, is by Delstanche's ring-knife (Fig. 187). strument differs from the ordinary ring-knife in that the upper bo its anterior part is especially sharpened so as to form a fine surface. After the malleus has been freed from the membrane by of the paracentesis knife, Delstanche's ring-knife is made to enc

e. It is then pushed gradually upwards, keeping as close to the rior border of the malleus as possible, until it cuts through the ıment of the tensor tympani. In doing this the instrument will em- the neck of the malleus (Fig. 188). This permits of sufficient ıge to extract the malleus by gentle traction in a downward and out- direction without danger of fracturing its shaft. If much resist- ɔe felt, probably the tensor tympani muscle has not been cut through, nother attempt should be made to do this before trying further ex- on. The advantage of nstrument is, that once nife has encircled the us it should be possible nly to cut through the r tympani, but to ex- the ossicle itself with- he use of any other ıment. If Schwartze's omy knife be used, tenotomy knives are red, one for the right one for the left ear. anche's ring-knife is ly good for either ear.

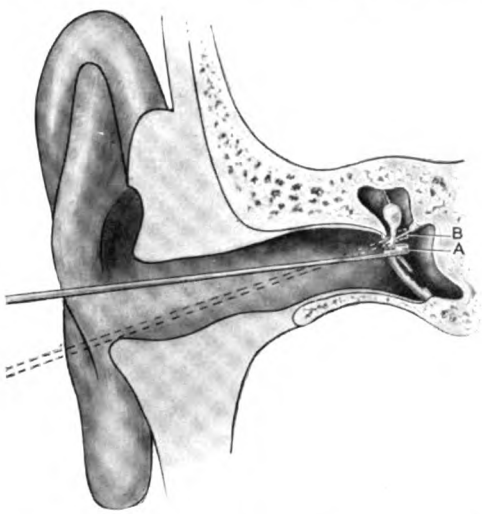

FIG. 188. REMOVAL OF MALLEUS BY DELSTANCHE'S RING-KNIFE. A, Curette inserted round handle of malleus; B, Curette pushed upwards, in act of cutting through tendon of tensor tympani muscle.

xtraction of the incus. ough it is frequently l that extraction of ncus is more difficult that of the malleus, ality it is the easier of the operation as, e the malleus, it has no firm attachments.

fter removal of the malleus all hæmorrhage must be arrested and w obtained of the labyrinthine wall of the tympanum. If it be ɔle to see the long process of the incus and its articulation with the of the stapes, this articulation should be cut through with a small -shaped knife. The knife is inserted just in front of the long ss of the incus and, keeping close to it posteriorly, is made to cut wards and backwards, thus separating its connexion with the stapes. ıently the long process cannot be seen, or it may indeed have already peared as a result of caries. Theoretically this delicate manœuvre rformed in order to prevent injury or dislodgement of the stapes g the act of removal of the incus. From a practical point of view,

however, it does not appear to make any difference whether the stapedial articulation is cut through or not.

FIG. 189. LUDEWIG'S INCUS HOOK. FIG. 190. ZERONI'S INCUS

A variety of instruments have been described for the pu removal of the incus. Ludewig's incus hook (named after Ludew was one of the first to draw attention to this operation) is stil mended by many as being the best. It consists of a solid hook, having of 5 millime a width of metres, bent angles to it (Fig. 189). of these are n one for each several sets o ent sizes ma quired owing variation in height, and the attic reg however, pre roni's (Fig. This hook, in being solid, of a steel eye ing a backwa similar to Ludewig's.

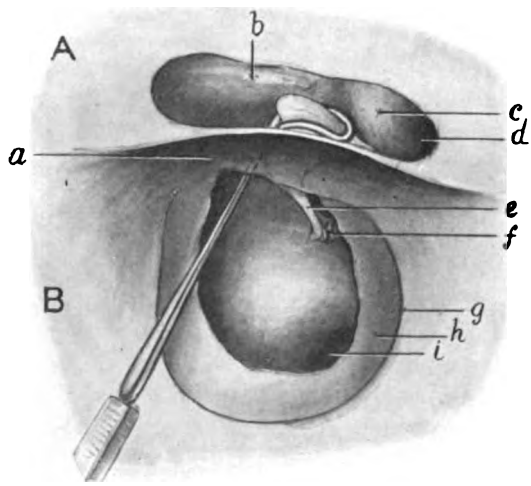

FIG. 191. REMOVAL OF INCUS BY ZERONI'S HOOK. A, Diagrammatic section showing opening in tegmen tympani: *b*, processus cochleariformis; *c*, lateral semicircular canal; *d*, aditus and tympanic antrum. B, Diagrammatic section, through the acoustic canal, just beyond the tympanic membrane: *c*, long process of incus; *f*, incudo-stapedial joint; *g*, tympanic ring; *h*, remains of the tympanic membrane; *i*, fenestra cochleæ; above it is the promontory.

The techn the same w pattern is employed. The instrument is inserted in such a fash the hook is directed upwards, having its concavity backwards passed into the attic at the point previously occupied by the hea malleus. The shaft of the instrument is then rotated backwards the hook passes over the body of the incus (Fig. 191). As the action is continued downwards and finally forwards, the incu lodged from its position and forced into the tympanum. It be seized by a pair of Sexton's or crocodile forceps and remo

o the floor of the tympanum, it can usually be dislodged by or else by means of a small hook passed in circular fashion floor of the cavity.

al of the lateral wall of the attic. In the majority of cases middle-ear suppuration, it is advisable to remove the lateral ne attic in addition to performing the simple operation of my. If granulations be present they should first be removed, o give a clear view of the labyrinthine wall of the tympanum, usually be obtained, the fact that a large n of the membrane is present. The malleus are then removed.

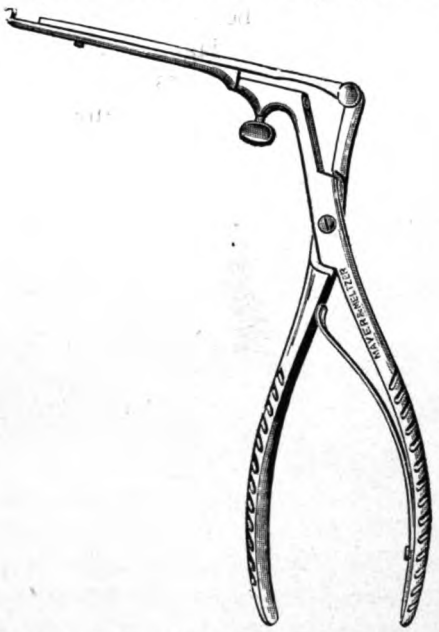

Fig. 192. Pfau's Attic Punch Forceps.

nove the lateral wall of small but strong pair forceps is required). The instrument is long the roof of the anal, its cutting edge rds and the blades kept pen, until the lateral felt to pass over the ll of the attic. The then depressed so that f the forceps is forced nd embraces the lateral ween its points (Fig. his is confirmed by at- to withdraw the for- h the lateral bony wall of the attic will now prevent. The f the forceps being assured, its blades are brought together by n the handle, and in this manner a small portion of the bone is ut. In this way the lateral wall of the attic is gradually cut nall fragments. Sometimes this is easy, owing to the acoustic g large and the outer wall of the attic being thin and easily cut In other cases, owing to the thickness of the bony walls or to vness of the canal, it is extremely difficult. If the lateral wall c has been completely removed, a fine probe, whose point is bent can be inserted into the attic and then withdrawn without en- any obstruction, owing to the roof of the attic and lateral wall ustic canal being now continuous. In some cases this part of

the operation may not be necessary, as the lateral wall of the
have already disappeared as the result of caries.

Into the larger opening thus made, small curettes are passed
and backwards and any granulations in the region of the a
entrance to the tympanic antrum are curetted away. Finally
is thoroughly swabbed out with pledgets of cotton-wool soa
1 in 2,000 alcoholic solution of biniodide of mercury. The
then dried, and a small drain of sterilized gauze inserted v
acoustic canal, the ear being afterwards covered with a pad
kept in position by a bandage.

After-treatment. In cases of non-suppuration there is r
pain, and if asepsis has been maintained, there is seldom much
beyond slight sanio
Unless there is co
discomfort the dres
not be changed fo
three days. If possil
should not be syri
merely mopped
pledgets of cotton-w
tened with boric l
then dried, the ga
being afterwards
This process may b
daily until healing is

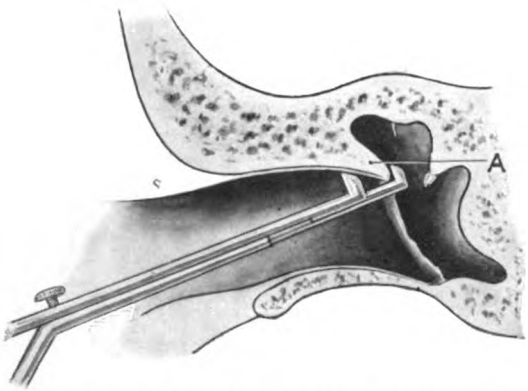

FIG. 193. REMOVAL OF LATERAL ATTIC WALL WITH FORCEPS. A, Lateral attic wall.

In middle-ear su
there may be co
pain, owing to forci
ing of the tissues of the inner part of the acoustic canal duri
of removal of the lateral wall of the attic. Sometimes, indee
much swelling of the lining membrane of the canal, with the
of furuncles as the result of septic infection.

If there be no pain, the after-treatment is the same as above
excepting that it may be necessary to syringe out the ear at e
ing owing to the discharge. If there be much pain, with swell
canal, the gauze drain should be removed and a 10% solution o
acid in glycerine frequently instilled into the meatus. Sul
drops of rectified spirit may be substituted.

Difficulties. 1. If the acoustic canal be very small there m
sufficient room to insert the instruments through the speculum.
cases, if there be no middle-ear suppuration, it is wiser to leav
dition alone. If, however, suppuration exists, either the co

ment must be continued or the complete mastoid operation recom-ed.

Hæmorrhage, especially on curetting away the granulations, may fficient to prevent a view of the deeper parts. It can, however, uickly arrested by plugging the acoustic canal with gauze soaked renalin and cocaine solution. Even if the surgeon has to wait v moments, this must be done, as it is very necessary to obtain r view of the field of operation.

Extensive adhesions between the membrane and labyrinthine wall render it difficult to separate the shaft of the malleus without frac-g its neck.

In old-standing cases in which there is a large perforation of the brane, the malleus may be so retracted as not only to be difficult to ut difficult to seize. In this particular case, division of the tensor ani with Schwartze's tenotome and then extraction of the malleus eans of Sexton's forceps is a better procedure than trying to en-its shaft with Delstanche's ring-knife.

Removal of the incus by the ordinary instruments may be rendered ssible owing to the narrowness of the attic posteriorly from chronic ening of its walls. In these cases a seeker, such as Schwartze uses e mastoid operation (Fig. 205), may be employed with advantage. passed over the incus in the same manner as an incus hook.

Accidents. 1. *Fracture of the handle of the malleus.* This is the of too forcible extraction. If a Delstanche's ring-knife has been this may be due to the tensor tympani not having been cut through; hould now be done. The head of the malleus is then removed, either eans of a small hook or some form of curette bent at right angles to aft, depending on what is most suitable for the case in question.

Failure to extract the incus. In the course of a chronic middle-ppuration, the incus may become exfoliated or gradually disappear result of caries. It does not therefore always follow that inability tract the incus means that the surgeon has failed in his manipula-although frequently this is the case, the instruments failing to ex-the incus, or perhaps dislodging it into the tympanic antrum, a fact is difficult to determine and may only be discovered if the subse-performance of the complete mastoid operation becomes necessary.

Facial paralysis. This accident is usually due to the incus hook eing inserted high enough up, so that, instead of entering the attic, sses on the labyrinthine and superior border of the tympanum, and ing rotated in a backward and downward direction, it follows the f the facial canal (Fig. 194). If much force be employed the frail of the facial canal will be fractured or pressed in on the underlying

facial nerve. It is very rarely, however, that the nerve is co crushed or torn through, and therefore recovery almost invariab place.

The facial nerve may also be injured whilst curetting away tions in the upper posterior part of the tympanic cavity.

4. *Injury to or removal of the stapes.* This very rarely occur the act of removal of the incus, but is generally the result of too curetting. If only the crura be broken off, it does not mat

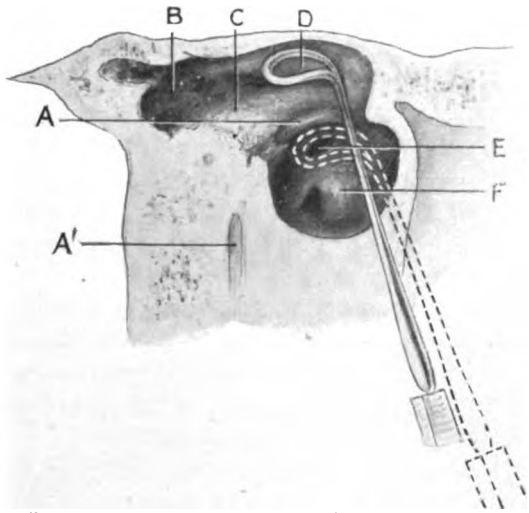

FIG. 194. DIAGRAMMATIC SECTION TO SHOW CORRECT AND WRONG POSITIONS OF INCUS HOOK. A, Facial nerve canal; A', Facial nerve, in section; B, Tympanic antrum; C, Lateral semicircular canal; D, Incus hook in its correct position in the attic, *above* facial canal; E, Incus hook in wrong position, about to press on facial canal; F, Promontory.

if the stapes itself lodged from the vestibuli, the sul symptoms may be at vertigo, nausea, and ing. As a rule thes toms subside. If, h the internal ear bec fected, complete dea even meningitis ma as the result of laby inflammation or tion.

Results. (*a*) *W gard to arrest of the* If the disease be li the ossicles themsel to the anterior an part of the attic, a able prognosis may b Complete cessation discharge and scarri of the affected pa take place within a month, or after a much longer period.

If, however, the disease be more extensive and involves the the attic posteriorly and the region of the aditus, as shown presence of a fistula or granulations, the prognosis is uncertain tinuance of the discharge and recurrence of the granulations ma tually necessitate the complete mastoid operation.

(*b*) *With regard to hearing.* In the case of chronic attic sup the hearing power may be increased to a distance of 12 feet conversation, provided the internal ear is not affected and the not fixed within the fenestra vestibuli; occasionally the result better. On the other hand, the hearing power may be made wor

post-suppurative conditions, the prognosis is not so favourable, as ntly the stapes is already bound down by adhesions; this is even robable in the case of chronic middle-ear catarrh. In both these ons the operation should never be performed without first explain- the patient that it is practically experimental. The chief cause ure is the recurrence of adhesions, which even the most complete reful operation cannot always prevent.

a series of fifty cases on which I had operated, the results of I published in 1910,[1] I found that in 52% a cure was obtained; there was a slight muco-purulent discharge, due to infection h the auditory tube; in 10% the condition was practically un- d, but free drainage had been secured; in only three cases was stoid operation eventually necessary.

th regard to the hearing: in 46% the hearing power remained restored to a degree sufficient for most practical purposes.

ce that date, I have had the opportunity of again seeing many e cases. Those in which complete cessation of the discharge had btained, have remained cured. In a certain proportion of the ere has been recurrence of granulations and evidence of bone after one or two years; this has been almost entirely confined se cases in which further conservative treatment has been com- neglected.

moval of the stapes. With increasing experience, the l opinion is that this operation is not to be recommended except arly stage in the operation of inferior vestibulotomy (see p. 452). r the sake of completion, the possible indications of this operation technique are described, but I do not personally advocate it.

e objects of the operation are: (1) to improve the hearing in f deafness presumably due to fixation of the stapes within the a ovalis, and (2) to relieve symptoms of tinnitus and vertigo the same cause.

fore this operation is advised careful examination must be made er to determine whether the labyrinth is intact, especially if the on is undertaken with the view of improving the hearing.

lications. (1) If there be ankylosis of the stapes on both sides, panied by marked deafness and distressing subjective symptoms, on is justifiable on the worse side.

) In a one-sided affection, provided the subjective symptoms of and giddiness are so oppressive as to render the patient's life able. The operation, of course, must not be attempted unless other form of treatment has failed.

[1] *Lancet*, September 3, 1910.

Operation. The operation may be performed either thro meatus, or by reflecting forward the auricle by means of the p incision, and then chiselling away the upper posterior part of t meatus in the manner suggested by Stacke (see p. 423).

The choice of the operation depends principally on the anatomical and pathological conditions.

If the meatus be very narrow the intrameatal method may bring the stapes into view. If, on the other hand, the meatus and there be a large perforation, the result of previous middle- puration, the incudo-stapedial joint or the head of the stapes its actually lie within the field of operation.

The intrameatal method. The patient should be fully anæs and the operation performed under good illumination. A portio tympanic membrane in its upper posterior quadrant is excised to bring into view the incudo-stapedial joint. The incision is be behind the handle of the malleus and is carried upwards and ba in a circular fashion through the tympanic membrane along the p fold, and then downwards for a little distance along its margi flap so made either falls downwards, or can be pressed downwar to expose to view the labyrinthine wall of the tympanum. With knife, curved on the flat, the incudo-stapedial joint is cut through a fine hook the long leg of the incus is dislocated forwards or ba from the stapes. The head of the stapes will now be seen with the of the stapedius muscle running horizontally backwards. With centesis knife, the tendon is cut through close to its attachmen stapes.

A fine, blunt-pointed hook is now inserted between the crura stapes. If the stapes be not firmly ankylosed it can usually be r by slight traction. If, however, it be firmly fixed, its crura will p be broken. To determine whether the stapes is ankylosed or no pressure of the probe on the head of the stapes may be necessa the head of the stapes cannot be seen, it is advisable, as sugge Dench of America, to punch out part of the upper posterior ma the attic wall with the attic forceps (see p. 381).

The post-aural method. The preliminary steps of the operat the same as have been already described for removal of an e (see p. 342).

After separating and reflecting forward the membranous fr bony portion, the upper posterior part of the tympanic ring is c away until a view of the stapes can be obtained. The incus is th articulated from the stapes.

If the stapes be ankylosed by fibrous adhesions to the margins fenestra vestibuli, an attempt may be made to free it by cutting t

sions with a fine bistoury. If this be impossible, a sharp hook fixed into the margin of the plate of the stapes in the hope of extracting it. Some authorities advise chiselling away of the of the fenestra vestibuli. If an opening can be made into the e by this means, it is hoped that the resulting scar tissue will form rane more resilient than the ankylosed stapes, and, in this way, vibrations of sound to enter the labyrinth. This operation, how- ecessitates the complete mastoid operation in order to freely the region of the fenestra vestibuli.

er-treatment. It is sufficient to protect the ear with a small rain. Occasionally there may be considerable vomiting and ver- n immediate result of the operation; this usually passes off within hree days. Meanwhile the patient should be kept in a recumbent and, if necessary, given small subcutaneous injections of ie.

iculties. The chief difficulty is to obtain a good view; even if this ned it is difficult to extract the stapes without fracture of its crura.

gers. The chief danger is infection of the labyrinth, and this acknowledged to be so great as to have practically caused the on to be given up in non-suppurative cases. On the other hand, Boston[1] considers that removal of the stapes does not necessarily the hearing, but sometimes improves it, and that the danger of n to the labyrinth in non-suppurative cases is slight.

ults. The question of removal of the stapes from the point of hearing is purely experimental. If there be bony ankylosis, it found impossible to remove the bone, and an attempt to do so will a fracture of its crura. If, on the other hand, it be not ankylosed vable, probably massage or, in cases of perforation of the tym- membrane, direct mobilization of the bone will give results as those following stapedectomy.

most favourable results are to be expected in those cases in which ration is performed to relieve symptoms the result of previous ear suppuration. In otosclerosis no benefit is ever obtained, and re the operation is absolutely contra-indicated.

the other hand, there is ample evidence that the hearing power, of removal of the stapes, may be retained. As an example may ed a case in which the stapes was removed accidentally in curetting ear after the removal of the malleus and incus, and in which wards performed the complete mastoid operation owing to the ance of the middle-ear suppuration. In spite of this, whispering e heard at a distance of 20 feet.[2]

[1] *Archives of Otology*, vol. xxxi, p. 407.
[2] *Journal of Laryngology, &c.*, vol. xxii, p. 33.

CHAPTER IV

OPERATIONS UPON THE AUDITORY (EUSTACHIAN)

UNDER this heading may be considered manipulations r special technical knowledge and skill: (1) direct examinatio pharyngeal orifice of the auditory tube; (2) catheterization; (ing of bougies; and (4) washing out the tympanum through t tory tube.

DIRECT EXAMINATION OF THE PHARYNGEAL O OF THE AUDITORY TUBE

To examine the pharyngeal orifice of the auditory tube, H devised an electric speculum on the same principle as the cy It may either be passed into the pharynx through the mouth or post-nasal space through the nose, depending on which is m venient. Through it, a direct view, relatively speaking, of the p space and the pharyngeal orifice of the auditory tube can be obt

Yankauer has also devised a speculum for viewing the naso- directly. It is on the same principle as the rectal or vaginal s The soft palate is rendered anæsthetic by cocaine solution; the s is then passed into the mouth and presses up the soft palate, a di of the nasal portion of the pharynx being thus obtained. Y uses this speculum as a means to apply astringents to the p space or pharyngeal orifice of the auditory tube itself.

CATHETERIZATION OF THE AUDITORY TU

Indications. (i) *As a means of diagnosis* in order to d (*a*) the amount and character of the obstruction within the tube; (*b*) the condition of the mucous membrane and whe exudation is present within the middle ear.

(ii) *For the purpose of treatment.* (*a*) In order to instil m drops or vapours into the auditory tube and tympanum; (*b*) liminary measure to the passage of bougies into the auditory t washing out the tympanum through the auditory tube.

(iii) *Catheterization is preferable to Politzer's method* if onl is affected. Politzer's method, on the other hand, is preferable

tion (*a*) in small children; (*b*) in the case of slight middle-ear
h if both ears are affected; (*c*) if the passing of the catheter is very
lt and causes pain owing to nasal obstruction; (*d*) in nervous indi-
ls who object to the catheter; (*e*) if the sudden inflation by means
litzer's method is more effectual than by catheterization.

oints to notice before inflation. 1. Care must be taken that the
n of the catheter is not obstructed, and that the compressed-air
nd auscultation tube are also in working order.

The nose must be cleansed of all secretion; if filled with crusts
in a septic condition, inflation must be avoided.

The patient should be sitting. Sometimes on inflation of the ear,
ially for the first time, an attack of giddiness or faintness may occur.

The nose should always be examined to see that the passage is
If it be obstructed catheterization may be impossible, or some

FIG. 195. EUSTACHIAN CATHETER.

l manipulation may be required in order to pass the catheter
gh the nose.

In order to prevent muscular contraction of the palatine muscles,
n may grip the end of the catheter and so prevent its entrance into
rifice of the auditory tube, the patient should be told to breathe
y and keep the eyes open.

short silver or plated catheter is usually used. It is 5 inches in
h and curved at its extremity. To indicate the position of the
of the catheter in the post-nasal space, a ring is attached to its
and wider extremity corresponding with the concavity of the
ture of its beak (Fig. 195). The size of the catheter varies in
eter from Nos. 1 to 4 English size, that is, the same scale as used
rethral catheters. The source of compressed air used for the infla-
s usually a Politzer bag having an india-rubber tube attached. At
d is a vulcanite pointed nozzle which accurately fits into the wider
mity of the catheter.

Technique. The patient is seated facing the surgeon, the head
supported by a prop or by an assistant. If the patient be at all
tive, it is wiser to spray a small quantity of a 2 to a 5% solution
caine or eucaine into the nose, or, better still, to pass gently a

probe tipped with a small pledget of cotton-wool soaked in the solution along the inferior meatus. This will effectively anæsth region of the pharyngeal orifice of the auditory tube, which is t sensitive part.

The surgeon stands in front of the patient. The larger extr the catheter is held lightly between the thumb and first finge right hand, its beak being turned downwards, whilst the tip of is tilted up by the thumb of the left hand (Fig. 196). In introdu catheter into the nostril, the right hand is kept low down so stem of the catheter is almost in a vertical position. In this wa

FIG. 196. PASSING THE EUSTACHIAN CATHETER. Introduction of the catheter within the nostril.

FIG. 197. PASSING THE EUS CATHETER. Passage of the along the floor of the nose.

passes over the floor of the vestibule. As the catheter is gently through the nose the right hand is raised so that the instrument the horizontal position and passes backwards between the sept the inferior concha, its beak being kept in close contact with t of the nose (Fig. 197). As the beak of the catheter enters t nasal space, it will be felt to glide over the soft palate.

With regard to the best method of introducing the beak catheter into the orifice of the auditory tube, opinions vary. many methods advised only two will be given.

he first is more suitable to those who have not had much experience ng a catheter; the second is the one naturally adopted by an expert.

he first method. The catheter is pushed backwards until it is felt pinge against the posterior wall of the naso-pharynx. The beak, ı at this stage is directed downwards, is next rotated a quarter of cle inwards so that it points horizontally towards the opposite the position is shown by the ring at its outer extremity (Fig. 198). catheter is now gently withdrawn until the beak is felt to catch st the posterior edge of the vomer. During these procedures the

. 198. PASSING THE EUSTACHIAN ETER. Beak of the catheter in ost-nasal space. The catheter is l to the opposite side so that its impinges against the posterior r of the septum.

FIG. 199. PASSING THE EUSTACHIAN CATHETER. Catheter in position; act of inflation.

of the catheter should rest on the floor of the nasal cavity. The pulations are carried out with the right hand whilst the outer ex- ty of the catheter is kept fixed in position by means of the thumb inger of the left hand.

he catheter is next pushed a short distance backwards to free it the soft palate and rotated downwards, and finally round in a l direction until the ring points to the lateral canthus of the eye e side to be catheterized (Fig. 199).

he point of the instrument should now engage the auditory tube;

if, however, inflation shows this not to be the case the probability is
the catheter has been pushed too far backwards and rests on its poste
lip. This can be remedied by drawing it a little further outwards.

The second method. The catheter, with its beak turned downwa
is passed gently and rapidly along the inferior meatus of the n
cavity, and at the same time rotated slightly laterally against the infe
concha. Whilst the catheter is within the nose, this lateral rotatio
prevented by the narrowness of the inferior meatus, but as soon as
beak of the catheter has passed behind the level of the inferior cor
into the free post-nasal space, it will revolve laterally and upwards
in so doing will enter the auditory tube, which lies just behind and al
the posterior end of the inferior concha.

Provided there be no abnormal obstruction within the nose,
method is an exceedingly simple one. With the practised hand the
nipulation can be carried out so smoothly and quickly that the cath
will be in position before the patient has had time to realize the fact

Difficulties. 1. *Irritability of the mucous membrane.* The pas
of the catheter through the nose may set up a violent spasm of snee
or coughing. When the beak has entered the post-nasal space, the ir
tion may cause such intense contraction of the palatine muscles that
point of the catheter may become fixed and its movement rendered
possible. If this takes place, the catheter should be withdrawn and
part anæsthetized by means of cocaine or eucaine solution, which is
applied locally on a pledget of wool at the end of a probe.

2. *Partial nasal obstruction.* On inspecting the nose, the obstruc
is usually found to be due to a deviated septum or spur, or to adhes
situated at its anterior part. Sometimes a passage can be effected
simply diminishing the curve of the catheter. At other times the
struction can be overcome by introducing the catheter with its
held upwards and outwards, so that on entering the nose the beak
in beneath the anterior end of the inferior turbinate. As the cath
is pushed gently inwards its outer extremity is brought round wi
circular movement so that it gradually assumes the horizontal posi
No force must be used. As the catheter is pushed farther in, it
rotate to a varying degree according to the formation of the nasal ca
Sometimes, indeed, the catheter may make a complete rotation du
its passage through the nose. At other times, after the obstructio
passed, the catheter is best pushed through the nose with the beak p
ing directly upwards. The great point is gentleness; the catheter sh
be allowed to take whatever position suits it best, but after the
has entered the post-nasal space the stem should lie horizontally a
the floor of the nose and its beak should point downwards.

Complete nasal obstruction. If the obstruction be one-sided, then theter must be introduced into the nasal space through the op- side.

is is performed in the ordinary manner, except that the catheter e longer and possess a larger curvature. On reaching the post- space, its beak is turned round so as to point towards the lateral s of the eye on the affected side. It may be necessary to alter rve more than once in order to get the point of the catheter to engage into the orifice of the auditory tube.

both sides be completely obstructed, the only method to adopt eterization from the mouth. The ordinary catheter is used. It ed into the mouth, its beak being directed upwards until it reaches sterior wall of the pharynx. The catheter is then pushed directly ds until its stem impinges against the soft palate. The beak is rned outwards until it lies almost horizontally. In this position ld enter Rosenmüller's fossa. The catheter is now withdrawn and should be felt to pass over a slight obstruction—the posterior he orifice of the auditory tube. By gently pressing the beak slightly rds, it should engage within the entrance of the auditory canal.

Obstruction within the post-nasal space. A common error in ucing the catheter is to push it too far backwards, so that on n of the beak outwards it passes behind the auditory tube and the pharyngeal recess. In this position the sounds referred to the ner's ear through the auscultation tube during the act of inflation from the normal sounds in that they are soft and distant. In a f doubt inflation should again be practised with the catheter in g positions. If the catheter be in the correct position, the patient be able to talk without discomfort, and there should be no tend- o retching or coughing. If, however, the beak lies in the ngeal recess, considerable irritation is caused, and on inflation the feels the air in the throat and not in the ear.

theterization may be rendered difficult by the presence of a large adenoids or of a tumour; or inflation of air into the auditory ay be quite impossible owing to the occlusion of its pharyngeal the result of scarring.

ishaps. 1. *Rupture of the tympanic membrane.* With a normal rane this is difficult to produce, in spite of even forcible inflation. an accident usually occurs at the site of some previous scar or ic patch in the membrane. If it occurs, there may be a temporary of giddiness, noises, and pain in the ear. Inflation, of course, be stopped at once and the ear protected for a day or two by ng the meatus with a piece of cotton-wool.

2. *Severe epistaxis.* This is usually the result of trying to force catheter through an obstructed nose, but it may also take place, the rarely, when manipulations have been carried out in a gentle fashio

3. *Syncope.* This is fortunately of rare occurrence and usually happens on the first occasion that the catheter is passed. For this re the patient should always be in a sitting posture, and on the slig appearance of pallor or faintness the catheter should be withdrawn. attack invariably passes off, but for the moment it is very unpleasan

4. *Surgical emphysema.* If the point of the catheter lacerates mucous membrane, the air may be forced into the submucous tis This mishap, however, rarely occurs as the result of simple catheter tion, but is more likely to follow forcible attempts to pass a bougie the auditory tube.

PASSING OF THE EUSTACHIAN BOUGIE

Indications. This may be done for the following reasons:

(i) As a means of diagnosis, to demonstrate the existence and tion of a stricture.

(ii) To dilate a stricture.

(iii) As a therapeutic measure, to treat the mucous membrane o auditory tube by means of a medicated bougie.

FIG. 200. AUTHOR'S GRADUATED EUSTACHIAN BOUGIE.

Bougies are made of various materials, but for ordinary purp the gum elastic is the best. They are about 7 inches in length wi slightly bulbous point.

In the adult the length of the auditory tube is approximately inches, of which 1 inch forms the cartilaginous and ½ inch the os portion. The narrowest part of its lumen is known as the isthmus, a situated at the junction of its cartilaginous and bony portion. On ing the bougie through the catheter into the auditory tube, it is esse to know how far its point is projecting beyond the point of the cath For this purpose the bougie may be marked at its outer extremity. inches from the point of the bougie, that is, the same length a catheter, is a black band a centimetre in length; a centimetre fa up is another black band; and again after an intervening space centimetre is a third black band (Fig. 200).

Technique. The catheter is introduced in the ordinary way

tion within the entrance of the pharyngeal orifice of the auditory verified by means of inflation. It is kept fixed with the left hand, e bougie is pushed into the catheter until the beginning of the first n the former just reaches the outer extremity of the latter; the tip bougie will now be flush with the point of the catheter. If there pain and no resistance, the bougie is pushed on very gently until ginning of its second black band just enters the catheter. Its vill now project 2 centimetres within the auditory tube; that is, it the region of the isthmus. If the bougie has been successfully ced into the auditory tube, the patient generally states that the ment is felt within the ear itself. No force should be used for fear ing a false passage, and with gentle manipulation it is very rare ual pain to occur. On reaching the isthmus resistance may be met out by the exercise of slight pressure the bougie can usually be o pass through it; if there be much resistance the bougie should ndrawn and a finer one substituted. After passing through the s, the bougie may be pushed in another centimetre, but no farther, it may actually enter and injure the contents of the tympanum. ter the tip of the bougie has passed through the isthmus the n will hear its movements through the auscultation tube as a rub kling sound. It is left in position for five or ten minutes and then awn. The ear should then be gently inflated, when the air entry e tympanum will probably be found to be much more free.

the passage of the bougie causes a certain amount of reaction, it not be passed oftener than once a week. Although no force ever be employed, the largest possible bougie should be passed at ccessive sitting until complete dilatation has been obtained.

fficulties. 1. If the catheter be not in position, the bougie may ehind the tip of the pharyngeal orifice of the auditory tube and he pharyngeal recess. This can usually be felt by the patient ricking sensation in the throat, and may produce retching and ng.

A stricture of the auditory tube may be so great as to prevent ce of the bougie.

ngers. (*a*) Surgical emphysema. If the mucous membrane be ed by the bougie, air may be forced into the subcutaneous tissues ation, after its withdrawal. In some cases the surgical emphysema onsiderable as to involve the side of the neck and face, and indeed en known to necessitate the performance of laryngotomy.

e best treatment is to make the patient suck ice and to forbid all ts at blowing the nose and coughing. Sometimes it is also neces- o scarify the pharynx and soft palate with a small bistoury. Re-

covery may be hastened by gentle massage of the neck and fac
tion should not be attempted again for at least a week.

(*b*) The bougie may be pushed in too far and cause inju
contents of the tympanum.

(*c*) The tip of the bougie may break off whilst in the audi
With a gum-elastic bougie this is very rare, but it is more likel
if the brittle celluloid bougies are used. To prevent this un
disaster the bougie should be carefully examined before pass
see that it is not cracked nor broken. If such an accident does
is wiser to do nothing, because as a rule the fragment is after
pelled spontaneously.

Results. If the obstruction be fairly recent and limit
pharyngeal end of the auditory tube, excellent results may be
by using either the simple bougie or the catgut variety moist
a 5% solution of silver nitrate.

Owing to the general thickening of the tube, there is
tendency for further stricture to take place in the more chro
even if a temporary improvement is obtained, and for this r
use of the bougie is seldom to be recommended.

WASHING OUT THE TYMPANUM THROUGH AUDITORY TUBE

Indications. (i) In chronic middle-ear suppuration in
perforation is situated in the anterior inferior quadrant and th
ance of the otorrhœa is apparently due to the secretion not bei
drain from the tympanum. This method may be employed
drainage and in order to cleanse the tympanum thoroughly b
instillation of medicated drops. In these cases the floor of
panum is usually at a considerable depth beneath the lower lir
membrane (Fig. 172).

(ii) In order to remove a small foreign body lying on th
the tympanum which cannot be expelled by syringing. The
is only tentative and is seldom successful.

Contra-indications. (i) If there be acute middle-ear sup
(ii) if the perforation be very small, as there will be a conside
of the fluid being driven into the tympanic antrum and further in

Technique. A catheter of wide calibre is passed in the
manner. Inflation is practised to see if it is in the right posit
left hand fixes the outer extremity of the catheter at its entra
the nose and keeps it in position. The patient inclines the
to the affected side and holds a receiver beneath the ear. A s

Digitized by Google

e whose nozzle accurately fits the outer extremity of the catheter l. Slight force may be required during the act of syringing, but ıot be sufficient to cause pain within the ear. A certain amount of lways escapes into the throat although the catheter is in its right ɔn, and this may set up an attack of retching and coughing. To this the patient should incline his head slightly forward as well as affected side and breathe gently with the mouth open. If the ma- tion be successful the fluid will trickle out of the external meatus. foreign body is rarely expelled by this method, as the force of fluid ed into the auditory tube is seldom sufficient, and it is not wise too great pressure. In order to expel all the fluid from the tym- ı, the ear is afterwards inflated by Politzer's method, and at the time the fluid is mopped out of the ear by means of pledgets of -wool.

esults. If the continuance of the middle-ear suppuration has been due to the retention of the purulent secretion in the lower part tympanum, this method of treatment is frequently most satis- y. In other cases no benefit is obtained owing to the suppuration due to other causes.

angers. The chief danger is the infection of the mastoid cells.

CHAPTER V

OPERATIONS UPON THE MASTOID PROCESS: V INCISION AND SCHWARTZE'S OPERATION

WITH few exceptions the conditions requiring operative p on the mastoid process are the result of some suppurative les has originated within the tympanum.

The object of such operations is to arrest or eradicate t which, by further extension through the bony walls of the temp might eventually cause death by giving rise to some suppura cranial complication.

For their successful performance a knowledge of the anat lationships of the mastoid process is essential. It is sufficient l mind the reader of the main surgical points in this connexion (

SURGICAL ANATOMY OF THE MASTOID AREA

The tympanic antrum. At birth the tympanic a almost fully developed. In infancy it is situated superficial a much higher level in relation to the acoustic canal than in In the infant, also, the petro-squamous and the squamo-mast are still patent. As the mastoid cells develop, the antrum gra comes more deeply placed, so that in the adult it is from hal quarters of an inch from the surface.

Its roof, the tegmen tympani, is continuous with that of Anteriorly it is separated from the external auditory meat posterior wall of the acoustic canal, whose medial margin lateral wall of the aditus. On its medial wall lie the semicircu whilst posteriorly the transverse sinus is separated from it by vening layer of mastoid cells or compact bone. Between the se canals and the transverse sinus is a small area composed of a of bone, separating the antrum from the posterior fossa of t cavity.

The mastoid process. In the infant this is undeve is merely represented by a small bony protuberance. By the f it has practically reached the adult type.

ically the mastoid process can be subdivided into three chief the pneumatic, in which the cells are few and large; (2) the taining numerous small cells; and (3) the compact, in which s extremely dense. Mixed types are frequently found, the a rule, being more dense than the deeper portion. Occasion- niformly sclerosed, almost of the consistence of ivory, but in the condition is usually pathological, the result of chronic in- of the mas- ss.

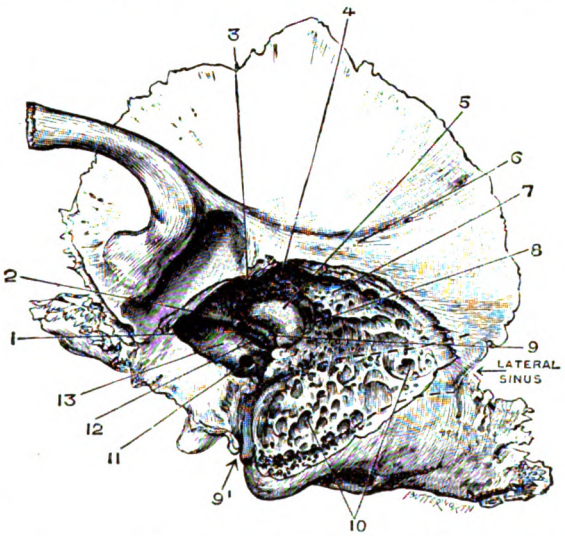

FIG. 201. LEFT TEMPORAL BONE, SHOWING ANATOMY OF THE MIDDLE EAR AND MASTOID PROCESS. 1, Anterior wall of external meatus, partly removed; 2, Canal for tensor tympani muscle, ending in processus cochleariformis; 3, Attic; 4, Aditus; 5, Lateral semicircular canal; 6, Posterior root of zygoma; 7, Tegmen tympani; 8, Tympanic antrum; 9, Facial canal for facial nerve; 9', Stylo-mastoid foramen; 10, Mastoid cells; 11, Foramen cochleæ; 12, Foramen vestibuli; 13, Promontory. Dotted line shows outline of sigmoid groove for transverse sinus.

astoid cells towards the antrum and divided into s: (1) those vertically s to the tip toid process; those lying he tympanic nd the sig- cess of the sinus. In ad- these two must not be hat cells may other direc- instance (*a*) along the the zygoma; eriorly, com- g with the the occipital) inferiorly, he floor of num and the jugular fossa: (*d*) internally, spreading inwards he apex of the petrous bone and surrounding the labyrinth; veloping the orifice of the auditory tube.

cial nerve, after dipping beneath the lateral semicircular canal, tically downwards through the mastoid process to emerge at mastoid foramen. Entering this foramen and running along are the stylo-mastoid branches of the posterior auricular artery. sels, if cut through by the chisel, may bleed in a marked man-

ner, thus drawing the attention of the operator to the fact th close proximity to the facial canal and nerve.

Surface anatomy. Although it is impossible to fo certainty before operation what the anatomical structure of t process may be, yet some information may be gathered from tion of the skull.

In the dolichocephalic type, the mastoid process is broa quently contains large cells, especially at its tip and round the sinus, which is usually deeply placed. In the brachycephalic t other hand, there is a greater tendency for the mastoid pro narrow and to consist of dense bone, for the middle fossa to down and to overlap the lateral wall of the tympanic antrum, a transverse sinus to project forward and superficially, even to 3 millimetres of the posterior border of the external acoustic

The posterior root of the zygoma may be considered, appr the line of demarcation between the roof of the tympanic a mastoid process, and the floor of the middle fossa of the sk however, is only a rough guide, as in some cases, especially of t cephalic type, the middle fossa may dip below this point. If is not well marked, then Reid's base-line must be taken as the

Just behind the acoustic meatus, at its upper posterior mar spine of Henle, which forms the anterior boundary of the s triangle. Macewen, who first described this triangle, gave it for the exposure of the tympanic antrum. Experience, ho shown that no reliance can be placed on this as a landmark, no means uncommon to expose the dura mater of the middl the bone is chiselled through at this point. A point 10 millime fifths of an inch) behind the spine of Henle corresponds to t border of the sigmoid sinus. Behind the suprameatal triang neath the zygomatic ridge is the body of the mastoid process a smooth surface and is perforated by small foramina thro pass tiny vessels.

The tympanic antrum, in the adult, is situated at a sligh level than the tympanic membrane, its floor roughly correspo a line drawn horizontally backwards through the middle of th wall of the bony meatus.

HISTORY OF THE MASTOID OPERATION

Although opening of the mastoid process, as an operative dates back to the eighteenth century, yet Schwartze, in 187 first to establish the operation as a practical procedure.

rtze's operation consisted in the simple opening of the antrum id cells, leaving the middle ear untouched. This procedure d out no matter whether the disease was recent or long stand- on became recognized, however, that this operation did not re in all cases, more especially in those in which the disease ne walls of the tympanum.

, in 1889, suggested removal of the posterior wall of the ex- ustic meatus, and about the same time von Bergmann advo- val of the lateral attic-wall. The Küster-Bergmann operation, sed by Zaufal, may therefore be considered to be the origin nplete mastoid operation.

's name is frequently, though wrongly, mentioned in associa- the complete operation, which is sometimes termed the -Stacke operation. Stacke's operation was devised with a moval of the ossicles and lateral wall of the attic in those cases he bone disease was limited to these regions. This operation, s occasionally of service in the performance of the complete eration (see p. 423).

he year 1889 may be considered as the starting-point of the nastoid operation. Since that date many modifications have duced, the majority of which are not worthy of reference.

he technique of the operation had been developed and practised ime, more careful attention was directed to the after-treatment. lier days of the radical operation it was the rule to leave the en and to plug it with gauze, or to insert a drainage tube which d through the membranous portion of the external meatus.

xt step was the making of post-meatal skin flaps, with closure terior incision and packing of the wound through the auditory the names most prominently associated with this are Panse, nd Stacke.

ore recently, in order to shorten the after-treatment, the wound been skin-grafted by the method first suggested by Sieben- afterwards amplified by Charles Ballance.

erations which will be considered are:

de's incision.

ening of the mastoid process and tympanic antrum.

complete or radical mastoid operation.

gh definite indications for the above operations will be given, remembered that in many cases the extent of the operation d very largely on the pathological condition found during the the operation itself, as frequently the clinical symptoms are

not sufficient to determine beforehand which operation should be performed.

In comparing the simple opening of the mastoid cells and tympanic antrum with that of the complete or radical operation, the fundamental difference is that in the former the tympanum and its contents are not interfered with, whereas in the complete operation the middle ear, tympanic antrum, and mastoid cells are converted into one large cavity. In consequence, complete recovery of hearing may take place in the former case; in the latter, however, this is not possible.

Although these operations, especially in the more acute conditions, are performed from the point of view of saving the life of the patient, due regard must also be given to the preservation or restoration of the hearing power, if this indeed is possible. If the hearing power be very poor, that is, if conversation cannot be heard more than 12 feet off, and especially if the deafness be partially due to changes having already taken place within the labyrinth, then the complete operation is to be preferred if it be doubtful whether Schwartze's operation will be sufficient to eradicate the disease. If, on the other hand, the hearing power of the affected ear be fairly good, and with this, there is deafness of the opposite side, then, unless it is absolutely essential that the complete operation should be performed, an attempt should be made to effect a cure by the simpler operation, provided it is first explained to the patient that it may perhaps be necessary to perform the complete operation afterwards.

WILDE'S INCISION

In cases of acute inflammation of the mastoid process or of a subperiosteal abscess lying over it, Wilde made a post-aural incision, incising the tissues down to the bone. The indications for doing this are now considered to be very few, but it must be remembered that in Wilde's day the mastoid operation had not been developed.

Indications. (i) In infants it is sometimes justifiable, as the pus may have escaped to the surface of the mastoid process either through the squamo-mastoid suture or along the posterior wall of the auditory canal, between the periosteum and bone, without there being any actual disease of the bone.

(ii) As a temporary measure, to permit of drainage of a subperiosteal abscess, if the operation on the mastoid process cannot be performed for twenty-four hours or more.

(iii) In acute middle-ear suppuration a free incision down to the bone may relieve the pain if there are symptoms of periostitis of the mastoid process; it is, however, rarely necessary.

ra-indications. In older children and adults (with the eptions) this operation is not sufficient, as the periostitis or sub- abscess over the mastoid process is secondary to underlying ase, which can only be eradicated by an operation on the mastoid self. Although healing may apparently take place, fistulæ or lences of mastoid disease almost invariably occur afterwards.

ation. In an infant a general anæsthetic is not necessary, but t gas anæsthesia is advisable. The mastoid region is surgically the auricle is pulled forward and a free incision is carried down ne, in a curved direction downwards over the mastoid process. Wilde made a vertical incision; but it is better, if possible, ncision should be the same as would be made in performing id operation, which indeed will probably have to be carried out ls. After the hæmorrhage has ceased and the purulent con- he abscess, if present, have drained away, fomentations should l and changed frequently during the first twenty-four hours. s a simple dry dressing is sufficient.

lts. Except in the case of tiny infants, this procedure is uccessful in curing the condition, and must be considered as mporary measure.

SCHWARTZE'S OPERATION

(Opening of the mastoid process and tympanic antrum)

ations. (*a*) *In acute middle-ear suppuration.* (i) As a gen- if, in spite of free drainage, earache, pyrexia, and tenderness *body* of the mastoid do not abate within three days. This is all urgent if the condition is the result of scarlet fever or influenza, e cases the disease may spread with extreme rapidity.

f there be an obvious abscess over the mastoid process; except s, in whom Wilde's incision may be attempted as a tentative although it is not recommended.

If there be symptoms of meningeal irritation.

If a profuse otorrhœa has continued for over four weeks and panied by sagging downwards of the upper posterior wall of the meatus; a definite sign that the antrum is involved.

f a profuse otorrhœa has continued for over eight weeks, with f abatement, even although the temperature may be normal and there may be no symptoms of inflammation of the mastoid The continuance of the otorrhœa is presumably due to accumu- pus in a large antral cavity. The object of the operation is to f free drainage and to prevent involvement of the mastoid self. The question of operation, however, must be considered

very carefully. There is no doubt that in many cases con measures may effect a cure even although the suppuration has existed for many months.

(*b*) *In chronic middle-ear suppuration.* Although the comp toid operation is usually indicated, yet the simple opening of panic antrum may be advised in certain cases, provided ther symptoms of inflammation of the mastoid process nor signs o of the bony walls of the tympanum:

(i) If the perforation, however large, be surrounded by tympanic membrane (showing that there is no disease of its b gins), and if the malleus be not adherent to the labyrinthine w tympanum.

(ii) If the hearing be good, that is, if speech is heard farther 12 feet, especially if the other ear (from whatever cause) be q

Politzer, among others, still maintains that there is frequ communication between the affected mastoid cells and the antrum if the mastoid abscess is the result of acute middle-ear tion. For this reason he considers that the antral cavity shoul opened if there be definite evidence of bone disease between th cavity and the antrum, or if symptoms of an extra-dural abscess intracranial complication be present. It is, however, difficult t that some communication, however microscopic, does not alw between the tympanic antrum and the mastoid cells, seeing latter originally developed as outgrowths from the antrum it must have become infected by direct extension from it. At time there is no doubt that complete recovery takes place in number of cases in which the antrum has not been opened.

In my opinion, it is always wiser, in such cases, to open the Politzer considers that if this be done, healing does not take rapidly as in those cases in which the antrum has not been ope the other hand, if the antrum be not opened, the main obje operation, that is, free drainage of the contents of the aural not attained.

Operation. *Preparation of the patient.* The head sl shaved for a space of two inches around the mastoid region; i the hair in front of the ear, instead of being shaved off, should b forward and plastered down with carbolic soap. By doing this can be arranged so as to cover the bald area during convale matter of great satisfaction to the patient.

The area of the operation and surrounding parts should painted with a 2% alcoholic solution of iodine. The head is t ered with a sterilized towel drawn tightly over the ear and

the towel being afterwards cut away so as to expose only operation. The patient should be in the recumbent position, esting on some hard substance, such as a partially-filled sand- urned over to the opposite side, so that the affected ear is

ition to the ordinary instruments, those specially required for tion are a well- mallet and several d chisels of vary- one or two sharp seeker, and a mal- unt-pointed silver ey should be steril- ordinary manner.

cision. The sur- ds at the side to be upon, facing the head. The auricle forward. An in- made through the inning just above a, and is carried ds in a curved di- wards the tip of the rocess, lying about nch behind the in- f the auricle (Fig. fore making the in- e tip of the mastoid should be deter- Care must be taken t the knife slip at of the incision and the neck tissues.

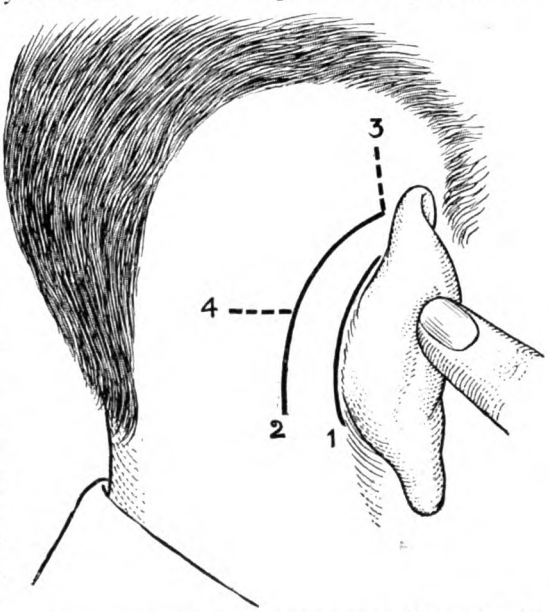

FIG. 202. DIAGRAM SHOWING POSITION OF SKIN INCISIONS IN POST-AURAL OPERATIONS. 1, For removal of foreign bodies or exostoses, or for excision of a stricture within the acoustic canal; 2, Usual incision for the mastoid operation; 3, Prolongation of incision upwards for exposure of temporo-sphenoidal lobe; 4, Extension of incision backwards, for exposure of transverse sinus or cerebellum.

The line of incision should correspond to afterwards be the middle of the wound cavity in the bone. If on be made too far forwards or too far backwards, one of the the skin incision may afterwards tend to overlap the opening ne and in this way hinder the dressing and perhaps lead to the n of a sinus. If there be much thickening of the soft tissues osteum, it may be necessary to make the incision longer than order to expose the field of operation sufficiently.

e upper angle of the incision the temporal fascia and the under-

lying temporal muscle will be exposed. Except in very mus
jects, in whom the muscle comes low down into the wound a
be cut through, it is better to push the lower border of the n
wards by means of a periosteal elevator. The incision is no
right down to the bone throughout its length.

If there be an abscess over the mastoid process, its purulen
should be allowed
away, the abscess
ing then irrigate
weak solution of
of mercury.

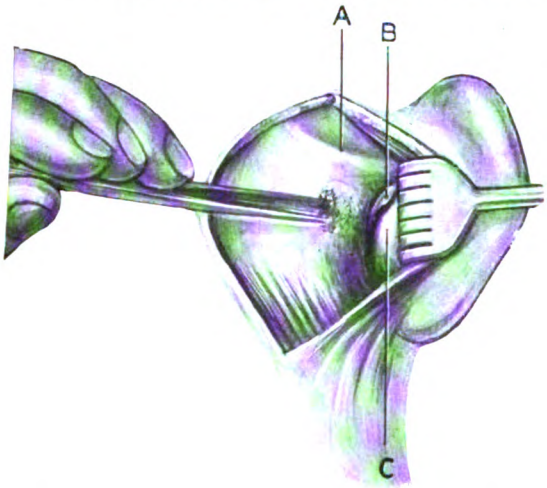

FIG. 203. SCHWARTZE'S OPERATION. Showing field of operation with anatomical landmarks and gouge in position for opening of antrum.

A, Zygomatic ridge; B, Spine of Henle: behind and above it is the suprameatal triangle; C, Fibrous portion of cartilaginous meatus, not separated from bony. (In this and the following diagrams the gouge or chisel is drawn small. In actual practice they may be much larger.)

Exposure of th
operation. The p
and overlying so
are then reflected
and backwards wit
until the following
brought into view
the upper posteric
of the bony meatu
care not to separa
brous from the bo
of the meatus) an
spine in front, the
ridge above, and
of the sterno-mast
below (Fig. 203).
of the mastoid
should just be see
this it may be ne
cut away some of
of the sterno-masto

If the surgeon has two assistants, the duty of one of them
apart the edges of the wound by means of retractors, whilst
is employed in keeping the wound dry. If there be only one
the edges of the wound may be held apart by metal retractor

Careful examination of the field of operation should now
There may be no external signs of disease. As a rule, how
result of the inflammatory process having already extende
surface, the periosteum is found to be much thickened, with
vascularity of the underlying bone, or there may be a sub
mastoid abscess of varying size.

Excepting in infants, in whom pus may escape through the squamo-toid suture, a subperiosteal abscess is always secondary to a fistula he bone, which is usually situated over the body of the mastoid ess just behind the suprameatal triangle. It may, however, occupy e other position.

In the case of Bezold's mastoid abscess (see p. 414), although no la may be seen on the surface of the bone, pus may be found to well rom beneath the mastoid process on cutting through the fibres of the no-mastoid muscle. In other cases there may be actual necrosis of one, as a rule involving the lower margin of the squamous portion he temporal bone (see p. 415).

The method of opening the tympanic antrum in a straightforward will first be described.

Opening the tympanic antrum. The approximate surface marking of antrum is the suprameatal triangle and the region just behind it, ch, however, as has been mentioned, is an uncertain guide. It is er, therefore, in all cases of operation on the mastoid process to me that the case is one in which the transverse sinus extends far vard and is superficial, and that the middle intracranial fossa is -lying.

The area of bone to be removed depends on the age of the patient; he adult it is about half an inch square, having as its boundaries the omatic ridge above and Henle's spine in front.

The bone should be removed by short decided taps of the mallet on gouge or chisel, held in contact with the bone in a sloping direction g. 203). This precaution is specially indicated whilst in the act of oving the bone from above downwards and from behind forwards, rder to prevent injury to the middle fossa, which may be low-lying, o the transverse sinus, which may project abnormally far forward g. 204).

To permit of better control over the instrument, the hand holding ay rest lightly against the patient's head, which is now covered with erilized towel. This control should always be sufficient to prevent chisel or gouge being driven unexpectedly too far inwards, an acci-t which may easily happen if, by chance, there is a sudden diminished stance to the stroke owing to unexpected softening of the bone or inadvertent exposure of the dura mater. It is this accidental slip-g of the instrument which is often responsible for injury to the trans-se sinus or the facial nerve. With regard to choice of instruments refer the gouge, as it is safer than the chisel owing to it having nded edges.

On removal of the superficial part of the cortex, the mastoid process

may be found to be sclerosed, or to consist of small or large
with granulations or purulent secretion.

(*a*) *If the bone be sclerosed.* The operation may be extre
cult, as the antrum is frequently of small size and very deep
As the tympanum must not be interfered with, it is not perm
insert the seeker along the acoustic canal into the attic in or
termine the position of the aditus. The only guides, therefor
anatomical landma

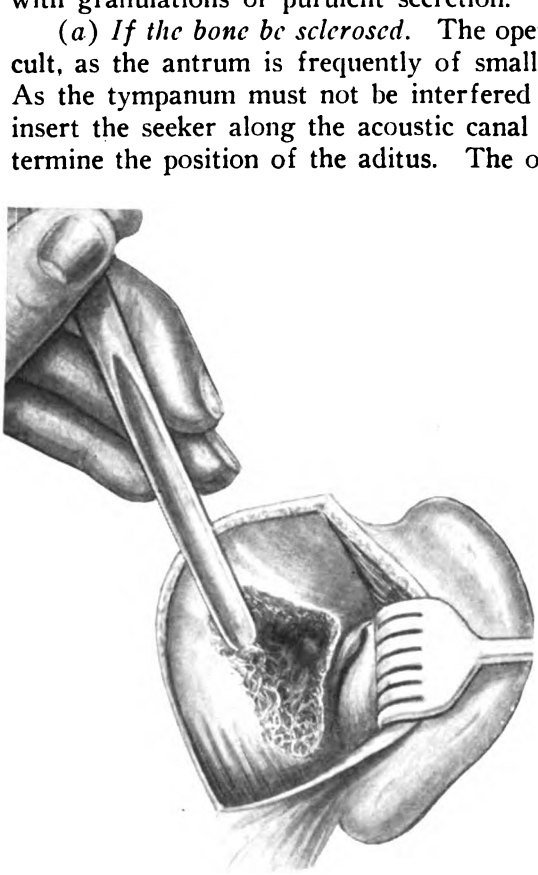

FIG. 204. SCHWARTZE'S OPERATION. Showing exposure of the tympanic antrum. Note sloping position of gouge in removal of bone in region of transverse sinus.

The best meth
chisel away the bo
and parallel to
posterior margin
ternal acoustic me
chiselling along
wall of the ope
gouge, instead of
rected downwards
the case in remov
outer portion of t
is now directed me
at the same time s
wards and forw
enlarging the lowe
the opening, the bo
elled away obliquel
and upwards. Th
of the gouge are m
nately from above
low, so that gr
funnel-shaped op
formed, having its
rected towards the

Anteriorly, the
removed as close to the posterior wall of the acoustic canal a
including the suprameatal spine. Above, the line of chiselling
extend beyond the zygomatic ridge, whilst below sufficient bo
be removed towards the tip of the mastoid process to permit of
of the deeper parts of the wound.

From time to time the operator makes use of the *seeker* (
This is a blunt-pointed probe whose tip is bent at right angles to
With it any opening should be probed carefully to see whe
merely a mastoid cell, the dura mater covering the lateral w

nsverse sinus, the middle cranial fossa, or the tympanic antrum itself. e chief mistake is to work too low down. If the antrum be small it y be missed, and the bone may be chiselled away too deeply in en- vouring to discover it, and in consequence the facial nerve or the ral semicircular canal may be injured. It is wiser, therefore, to rk high even if the dura mater of the middle fossa is exposed by doing This should not lead to any harmful result provided the dura mater ot injured.

As soon as the tympanic antrum is reached, pus will be seen to ooze ough the opening made, especially if it is under tension. The probe seeker can now be passed into a cavity of varying size. The antrum is gnized by its smooth surface, which has quite a different appearance that of the mastoid cells.

(*b*) *If the mastoid be not sclerosed.* The pathological condition found removal of the superficial cortical layer depends on the anatomical ucture and on the extent and virulence of the inflammatory process. ly a few cells may be involved, or, on the other hand, the whole mas-



Fig. 205. Schwartze's Seeker.

d process, if it be of the pneumatic type, may be converted into a mere ll of bone, forming a large cavity filled with masses of septic granula- n tissue, carious bone, and pus. Sometimes, indeed, owing to the men tympani or bony wall of the sigmoid sinus being already de- oyed, the dura mater above or the transverse sinus posteriorly may be nd already exposed within the cavity. If this is the case the pus y pulsate if present in large quantity. Any patches of soft carious ie or granulation tissue should be removed with the curette.

If the disease be limited to a few superficial mastoid cells, it is suf- ent, according to those who do not always explore the tympanic rum, to expose and curette the cavity freely and to do nothing further. is, however, should only be done if the bone surrounding the abscess ity is hard and apparently normal, and if there is no tract of granula- ns leading from it in any direction. If an opening be found leading ectly into the antrum, it should be enlarged with the curette or gouge. e extent of the antrum is next defined with the seeker, any overlapping ges of bone being removed by the gouge until the whole of its medial face is exposed.

The region of the aditus is now inspected under good illumination, ng a head-light if necessary. It is recognized as a small opening at

the anterior medial part of the antrum, on the floor of which m
the posterior border of the lateral semicircular duct, standi
a whitish rounded eminence. Bone may be removed from
inner margins, but the lower portion should not be interfere
fear of injuring or displacing the incus. To confirm the op
the aditus, a blunt-pointed curved probe may be passed for a
tance through the aditus into the attic (Fig. 206).

With the curette all granulations should be removed.

Treatment of the mastoid process. The question now a
how much bone to remove. This depends on the condition
chief point is to
tain of removing
fected cells.

In the case
sclerosis, the ope
not be large beca
bone between the
the antrum be s
hardly probable t
tion can spread th
any outlying cells
of the mastoid or

In the diploic
matic varieties,
must be used co
order to discover
lying cells, which
opened freely. I
done systematicall
cells may be found
tance away from
panic antrum itself

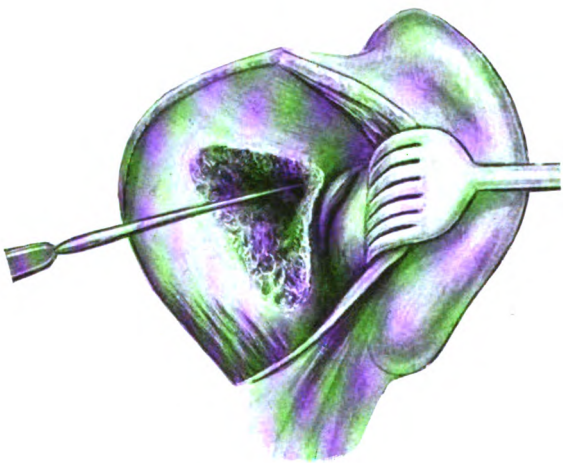

FIG. 206. SCHWARTZE'S OPERATION COMPLETED. The seeker is being passed through the aditus into the attic. Note the posterior border of the lateral semicircular duct which forms the medial and inferior margin of the aditus.

an area of apparently healthy bone lies between them and th
It must not be forgotten that cells may extend posteriorly as
occipital bone, or anteriorly along the zygomatic process, or
the upper posterior part of the acoustic canal itself (see p.
such infected cells be not discovered, healing will be prevent

However small or large the opening may be, all rough co
be removed, so that at the end of the operation a smooth fun
cavity exists. To obtain this *a burr* may be used, worked eit
electric motor or, if a portable one, by an assistant. The bu
various sizes and of the cross-cut variety recommended by

operators perform the operation by burring throughout. Person- prefer to use the gouge and mallet. If the operator has not had experience in the use of the burr there is always a slight risk, if not kept sufficiently under control and if too great pressure be of it being driven through the dura mater above or into the erse sinus posteriorly, or of it injuring the contents of the num.

emoval of part of the posterior wall of the acoustic canal. This may cessary if the anterior wall of the tympanic antrum and mastoid ss be affected. The fibrous portion of the acoustic canal is partially ated from the bony portion and held forward by means of a re- r. The outer posterior portion of the bony meatus can now be ved by the gouge or by the chisel, to what extent does not matter so s its innermost portion, 'the bridge,' is not interfered with; that is, g as the tympanum and aditus are not encroached upon.

xposure of the dura mater and transverse sinus. This may have ly occurred before the operation, as a result of extension of the bone e, or it may be necessary to do so during the course of the opera- Owing to the fact that an extra-dural abscess is a frequent compli- of acute inflammation of the mastoid process, Victor Horsley and er advocate the exposure of the dura mater and the transverse sinus ry case, especially if a tract of carious bone leads in their direction. arm is done in exposing these structures providing they are not in- and this measure precludes missing an extra-dural abscess. is better to expose the dura mater than to leave it covered with ed bone and septic granulations.

inal step of the operation. In order to make certain that a free ng exists between the tympanic antrum and the tympanum, some boric lotion should be syringed through the opening of the aditus. all syringe is used, having a fine piece of india-rubber tubing fixed its point. The end of the tubing is pushed into the entrance of the s. The fluid is then syringed through and should emerge from the nal meatus. This is also beneficial in order to cleanse the tympanum purulent secretion. To expel all the fluid from the middle ear ringe is emptied and the piston withdrawn to its full extent. Its is again placed within the entrance of the aditus and the piston ed home, so that air is forced through and so drives out any remain- luid from the tympanum into the external meatus, which in its should be carefully dried. If no perforation exist, or if it be very , the membrane should be freely incised before fluid is syringed gh the aditus.

mmediate treatment of the wound cavity. The wound cavity is

lightly packed with sterilized ribbon gauze, half an inch in width. Care must be taken to introduce the gauze right down to the aditus and to pack the cavity evenly.

The wound should be left open for a few days until the acute inflammation of the soft tissues has subsided, after which the upper and lower angles of the wound can be partially closed by sutures. A strip of gauze is also inserted into the acoustic canal and a light dressing of plain sterilized gauze and a pad of cotton-wool covers the ear and surrounding parts. The bandage should be passed round the head and not beneath the chin, as the latter method is often a source of great discomfort to the patient during the stage of vomiting following the anæsthetic.

Blake of America has suggested that the wound should be allowed to fill with blood-clot, on the supposition that the subsequent organization of the clot will result in a rapid closure of the wound. This method cannot be considered seriously owing to the impossibility of keeping the wound sterile.

After-treatment. There is seldom any shock, but there may be considerable pain during the next twenty-four hours.

If there has been no subperiosteal abscess, the dressing need not be removed for forty-eight hours. If an abscess has been present the dry dressing should be removed after twenty-four hours, and if there is much œdema and inflammation of the surrounding region, a compress of wet boric lint, kept in position by a few turns of a bandage, should be substituted, and changed every four hours.

Drainage tubes should be shortened and removed as soon as possible. The gauze within the wound cavity should be changed every second day, or daily if there be much secretion. If there be much discharge and the condition be very septic, an ear-bath of hydrogen peroxide may be given at each dressing and the cavity syringed out with a weak solution of biniodide of mercury; otherwise it is sufficient to use boric acid lotion.

If the operation has been successful, the purulent discharge from the tympanum rapidly diminishes, frequently ceasing before the third day. The auditory canal is then firmly packed with gauze, especially in its outer part, in order to prevent stenosis of its lumen, which is liable to occur if the posterior fibrous portion of the canal has been separated from the bony meatus during the operation. Granulations very quickly block the aditus and so separate the tympanic antrum and mastoid cavity from the tympanum. The wound can now be treated as an ordinary deep surgical wound, care being taken that it is packed from the bottom at each dressing.

If all the diseased bone has been removed, smooth healthy granulations will cover the wound. The continuance of pus from any spot, or

al growth of exuberant granulations, suggests the presence of an d cell or a fragment of carious bone. Under cocaine anæsthesia, rt should be inspected carefully, and, if necessary, curetted freely. er cases the local application of chromic or trichloracetic acid is nt.

ter the second week the wound becomes shallower, actual healing wound depending on the size of the cavity.

less a very large amount of bone had to be removed, the resulting ity is not great and usually only consists of slight sinking in of n. In some cases the final result is only a fine scar, which can lly be concealed by the hair.

e difficulties and dangers of the operation are considered in the apter (see p. 438).

sults. 1. If the operation has been successful (and this is the case), pyrexia and pain rapidly disappear, the patient ex- cing remarkable relief from the head symptoms, so that within -four hours he feels almost well. Healing of the wound is usually te within six weeks, and before this date the hearing power will ly have been restored to normal.

The operation may not have been successful and the following urable symptoms may occur:

) The pyrexia may continue irregularly for a few days. If there ther symptoms, this is probably due to septic absorption from the and need not cause very great alarm. If accompanied by pain, either mean that all the infected mastoid cells have not been , or suggest the onset of osteomyelitis of the temporal bone. If, tion, such symptoms as rigors, delirium, optic neuritis, headaches, niting occur, they indicate some intracranial complication.

cases of doubt it is wiser to explore the wound under a general etic and then to determine what further operation may be ary.

) The general condition of the patient may be excellent, but otor- r a fistula over the mastoid process may persist. Continuance of œa, in spite of healing of the wound posteriorly, means that al- the disease involving the mastoid process has been eradicated, yet lls of the tympanum are themselves involved. This will probably tate the subsequent performance of the complete mastoid operation. the other hand, the suppuration may cease from the middle ear omplete recovery of hearing, and yet a fistula of the mastoid may . This means that all the diseased bone has not been removed. hould now be done.

TREATMENT OF SPECIAL CONDITIONS

In an infant. In an infant under two years of age th should be somewhat higher than usual. In making it, too much should not be used, as the bone is frequently thin at this ag carious it may be so soft that the knife may possibly enter cranial cavity. In exposing the area of operation, it must be re that the posterior root of the zygoma and the tympanic antr a much higher level than in the adult. The opening into th therefore, should be made above rather than behind the marg acoustic canal. In these cases a fistula usually is present, and may be sufficiently soft to be removed by means of a sharp curette. At the same time, the aditus should be exposed and th made funnel-shaped in order to allow of proper dressing.

Sub-periosteal abscess. The treatment depends on t of the abscess. If it be small, the lining membrane may be away, the wound being afterwards treated in the ordinary ma the abscess cavity extends upwards towards the parietal regio wards along the temporal fossa, then drainage tubes should be their ends being brought out into the mastoid wound. It is rar sary to make counter-incisions. The completion of the op seldom difficult, as the fistula actually leads into the tympani If the fistula be a large one and the bone is carious a sharp s be used; otherwise a gouge is necessary.

Bezold's mastoid abscess. If the lower portion of th process be composed of large cells, the abscess within the ma break through the bone at its inner surface in the region of the fossa. In consequence of this the pus may infiltrate the ne beneath the fascia of the sterno-mastoid muscle and form a lar recognized clinically as a hard and painful swelling situated mastoid process instead of over it. This condition was first by Bezold.

After exposing the tympanic antrum in the ordinary way, the mastoid process is opened freely. It is usually found to cor cells filled with pus. Any granulation tissue is curetted awa cavity dried. The inner surface of the bone is then inspected in order to find the opening, which usually leads into the digas The margins of the fistula should be curetted freely and th enlarged, if necessary. If the deep-lying cervical abscess be finger may be passed into the abscess cavity behind the mastoi between it and the cut fibres of the sterno-mastoid muscle. It the limits of the cavity can be made out, and any pockets

oken down. A counter-incision should be made through the the neck at the lower limit of the abscess. The opening should ntly large to permit the insertion of a large drainage tube into . If the abscess be small it may not be necessary to make opening, but merely to insert a drainage tube into it, passing ove downwards along the passage made by the finger.

osis. In children necrosis of the temporal bone is not unespecially if the middle-ear suppuration occurs in the course of fever or is the result of tuberculous infection.

art usually affected is the lower margin of the squamous portion mporal bone and the tympanic ring. Sometimes, however, the s very extensive, involving a large area of the petrous bone, the labyrinth. These cases are always grave, and if a fatal urs it is usually in consequence of meningitis.

ults necrosis is rare excepting as a localised patch usually sitrficially in the cortex of the mastoid process. Partial necrosis yrinth, more especially of the vestibule and the portions of the ar ducts, is also met with occasionally. When the necrosed perficial, such as the squamous portion of the temporal bone tex of the mastoid process, it should be removed. If, however, ated more deeply, forcible removal should not be attempted sequestrum becomes loose, the wound cavity being meanwhile septic as possible.

omyelitis. In children, as the result of acute inflammation stoid process, the bone may be found riddled with small points metimes termed osteomyelitis. As a result of free opening of d cavity, recovery, as a rule, takes place in the ordinary manner. ct from this is another condition in which thrombosis of the ins occurs. It is, fortunately, a rare complication of mastoid It may occur before operation or be the result of infection of s a result of operation. The infection tends to spread in every more especially upwards along the parietal region and towards it. With this, localised areas of necrosis or abscesses may ing rise to painful swellings on the head, and usually are ac- l by cellulitis of the scalp, pyrexia, and intense headaches.

nly chance of recovery is to expose the affected area freely, oughly remove all the diseased bone. To do this it may be to lay bare the dura mater over a considerable area. If, how- disease be not quickly eradicated, death will eventually occur lt of extension of the septic infection to the larger veins, or e other intracranial complication.

CHAPTER VI

THE COMPLETE MASTOID OPERATION

BEFORE considering the question of the radical operation, it is assumed that conservative treatment has been attempted and has failed, and that the middle-ear suppuration has existed for a considerable period.

Indications. (i) As a prophylactic measure. If there be merely a perforation of the tympanic membrane and no evidence of disease of the ossicles nor of the walls of the tympanum, the probability is that the continuance of the suppuration is due to an affection of the mucous membrane rather than of the underlying bone; for example, to a chronic empyema of a large tympanic antrum which, owing to its anatomical structure, will not drain freely.

In such cases the complete mastoid operation is only indicated if the deafness is extreme, the bone conduction diminished, and the high tuning-forks not well heard, or if the ossicles are bound down by adhesions to the inner wall of the tympanum, as it is then obvious that the hearing power cannot be restored completely.

It must, however, be remembered that in many cases a slight discharge may exist for years without giving rise to any complications. If the patient be made aware of the slight danger which exists in every case of middle-ear suppuration, and be in a position to obtain medical attention if retention of pus occurs, then operative measures may be deferred indefinitely. If, on the other hand, the patient intends going to some remote country where medical attendance is impossible, then it is wiser to submit to the complete operation rather than risk future trouble.

(ii) If there be recurrent attacks of giddiness, nausea, or headaches radiating up the affected side which are not arrested by the ordinary methods of treatment. These symptoms of retention of pus within the tympanic antrum and mastoid process should be considered as danger signals. In this case also it is assumed that the hearing cannot be restored, and in consequence there is no object in performing Schwartze's operation.

(iii) If there be recurrence of polypi and granulations within the tympanum in spite of curetting, especially if the operation of ossiculectomy has already been performed.

) If there be symptoms of retention of pus due to want of free
ge in the case of stenosis of the external meatus, whether due to
contraction of its soft parts, or from the presence of exostoses.
If cholesteatomatous formation be present. Even if there be no
ms necessitating immediate interference, operation is usually in-
owing to the fact that cholesteatoma is the commonest predis-
cause of intracranial suppuration and septic thrombosis of the
rse sinus.

) If there be a fistula of the bony wall of the mastoid process,
r it extends anteriorly into the auditory canal or externally
n the skin over the region of the mastoid process. It must not be
en, however, that simple opening of the tympanic antrum and
l cells will be quite sufficient if the condition is the result of a
and acute inflammation of the mastoid process.

) If there be facial paralysis occurring in the course of a chronic
-ear suppuration. This may mean either that there is bone disease
ng the facial canal, or that the inflammatory process has spread
n the facial canal towards the inner ear. In either case operation
ated.

i) As a preliminary step in intracranial suppurative lesions of
rigin.

) In tuberculosis of the middle ear. If the patient's general condi-
rmits of it, and if the pulmonary disease be slight or arrested, the
te operation should always be done. The difficulty is to remove
diseased bone. If this can be done the wound will heal quite well.
In acute inflammation of the mastoid process occurring in the
of chronic middle-ear suppuration, the complete mastoid opera-
ould be performed, as in these cases the attic, aditus, and tympanic
are always involved.

) Amongst the rarer conditions for which the complete operation
necessary are removal of a foreign body which has been pushed
tently into the region of the attic and aditus and cannot otherwise
oved; and actinomycosis of the temporal bone.

METHODS OF OPERATION

e actual method of carrying out this operation varies. For those
ve not had great experience the best method is first to open the
, as in Schwartze's operation, and then to remove the 'bridge' of
etween it and the tympanum (Küster-Bergmann operation, some-
alled the Schwartze-Stacke operation). Instead of doing this,
per posterior part of the acoustic canal may be chiselled away
neously during the act of exposing the tympanic antrum (Wolf's

operation). On the other hand, the mastoid and tympanic ant be exposed from within outwards by removing the outer attic working backwards (Stacke's operation).

The Küster-Bergmann (or Schwartze-Stacke) op The preliminary preparation, the position of the patient, and t ments required are the same as in opening the antrum.

The incision is begun just above the upper insertion of the p is carried downwards in a curved direction behind the auricle margin of and scalp authorities make the close behin along the p ular fold. of the inci placed far l concealmen scar by Also, as it somewhat to the actu cavity, it sl by prima and with displacemer auricle. In if it be nec expose the sinus, this c be done b retraction c parts.

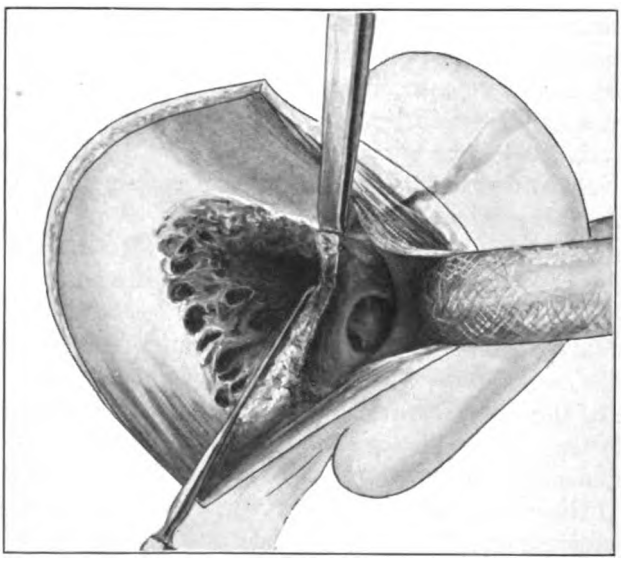

FIG. 207. THE 'RADICAL' MASTOID OPERATION. To show removal of the 'bridge' from above. The seeker, inserted into the aditus, acts as a protector to the underlying lateral semicircular duct and the facial nerve.

[The mastoid cells in this and the following illustrations are shown diagrammatically; in reality they are removed to render the surface of the bone smooth.]

The exposure of the field of operation is the same as in t opening of the tympanic antrum, excepting that the soft tissu be separated a little further forwards and above the exter meatus, as in this operation the upper posterior wall h removed.

The tympanic antrum is opened as already described (see p

The fibrous portion of the external meatus is separated caref the posterior wall of the bony meatus by means of a periosteal and is pulled forward by a retractor. The external portion of the

is now removed in a wedge-shaped fashion by alternate strokes of hisel from above downwards (Fig. 207) and from below upwards. upper level of the bone to be removed corresponds with the zygo- ridge. After a small portion has been removed, a pair of forceps is ed into the acoustic meatus and its point made to project into the nd posteriorly through the end of the now detached fibrous portion ne acoustic canal. With the forceps a piece of gauze is drawn ugh the acoustic meatus in the form of a loop. By its means the le and fibrous portion are pulled well forward, thus exposing to the tympanum. Two openings are now seen: one, the acoustic and tympanum, in front, and the other, the tympanic antrum and oid cavity, behind. Between them is the 'bridge'; that is, the most portion of the posterior wall of the auditory canal.

Any granulations present are curetted away gently from the tympanum. The seeker is next passed into the tympanum, and its point directed upwards and backwards into the aditus, so that it rests on the floor of the latter, or its point may be inserted into

FIG. 208. STACKE'S PROTECTOR.

ditus through the mastoid wound. Beneath it lies the eminence of ateral semicircular duct and the facial nerve. This is a most im- nt landmark. Provided the seeker is kept in this position, all the lying superficially to it can be removed without injury to the semi- lar duct or facial nerve.

n this connexion may be mentioned Stacke's probe or 'protector' . 208). Although historically an instrument of importance, I do not e use of it. It is so large and of such sharp outline that, unless used extreme care, it is itself very liable to injure the facial nerve. For reason I prefer the seeker, a much finer and more delicate instru- , which will serve the purpose without the same risk (Fig. 205).

The 'bridge' is now carefully removed by the gouge or chisel, fre- t use being made of the seeker. As the roof of the tympanic antrum, us, and attic is a continuous one, the bone to be removed is neces- y at a higher level than the roof of the bony meatus. This is a point h must not be forgotten, as the great fault of the beginner is to ove the bone too low down.

As the aditus is approached, the strokes of the chisel must be very le. If too much force be used, the chisel, on breaking through the

innermost portion of the 'bridge,' may injure the deeper lying parts, more especially the facial nerve.

Some authorities advocate removal of the 'bridge' by means of bone forceps. This, however, is not so sure a method as by the chisel or gouge.

After removal of the bridge, the tympanum, tympanic antrum, and mastoid will form a continuous cavity. As a rule the outline of the lateral semicircular duct appears as a well-marked white eminence, and projecting beyond it are the remains of the posterior wall of the acoustic canal. In removing this ridge good illumination is essential. The bone is removed in layers with the chisel, beginning at the tip of the mastoid process, and working parallel to the acoustic canal and the underlying facial canal. If necessary the seeker may be used as a guide, its point being allowed to rest on the floor of the aditus, superficial to the semicircular duct (Fig. 209).

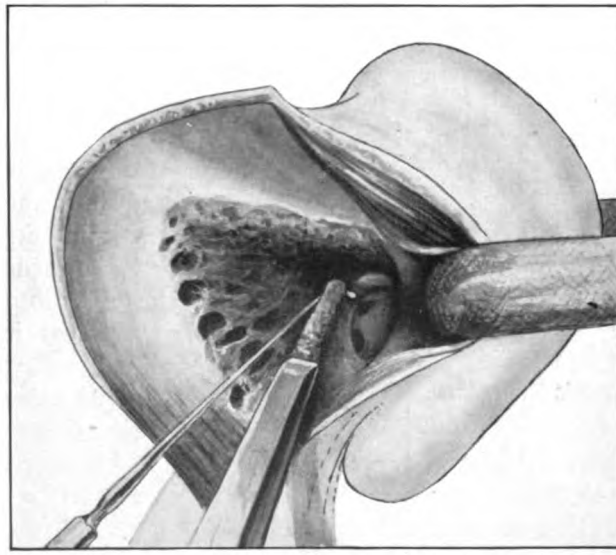

FIG. 209. THE 'RADICAL' MASTOID OPERATION. Showing removal of the remains of the posterior wall of the acoustic canal; the seeker acting as a protector.

The amount of bone removed should be such that at the end of the operation the acoustic canal is only separated from the main cavity of the tympanic antrum by a slight eminence, the remainder of the posterior wall, which is continuous with that of the lateral semicircular duct.

Occasionally the facial canal and the stylo-mastoid canal are abnormally superficial. Provided the bone be removed in the manner just described, the facial nerve should not be injured, even though it may be exposed inadvertently. A warning of this occurrence is given by bleeding from the vessels within the canal (see p. 399).

If the malleus and incus be still *in situ*, they can now be seen and can usually be removed by the curette. No force must be used. Removal of the incus is a matter of no difficulty. In the case of the malleus there

nay be some resistance owing to the attachment of the tendon of the ensor tympani muscle. If so, the malleus should be grasped by a

FIG. 210. PFAU'S CURETTE FOR THE AUDITORY TUBE.

ne pair of forceps and the tendon severed by means of Schwartze's enotomy knife.

The overhanging edge of the lateral wall of the attic can now be felt y means of the eeker. It is best re- noved by gentle taps f the chisel or small ouge. Especial care nust be taken not o drive the gouge oo far inwards. f this be done inad- ertently, the trans- erse portion of the acial nerve passing long the labyrin- hine wall of the ympanum may be njured. As a safe- uard some surgeons se an attic punch- orceps or a burr, thers a Stacke's rotector which hould be inserted to the attic before chiselling away its lateral wall.

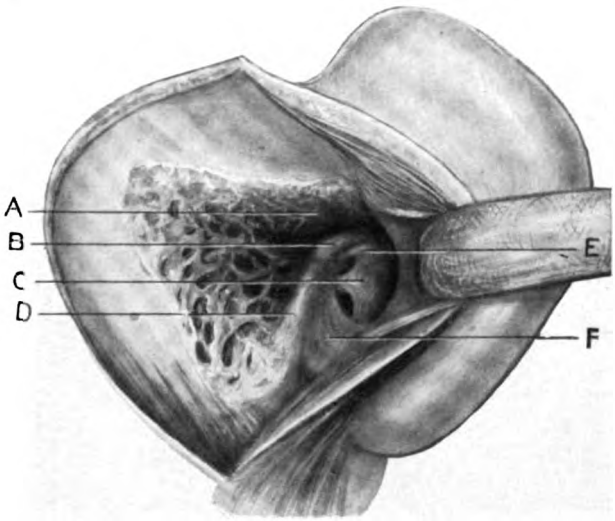

FIG. 211. THE 'RADICAL' MASTOID OPERATION COMPLETED. A, Attic and tympanic antrum; B, Lateral semicircular duct; C, Promontory and labyrinthine wall of tympanum; D, Remains of posterior wall of acoustic canal; E, Facial nerve canal; F, Floor of acoustic canal.

After the lateral attic wall has been removed, the roof of the acoustic nal and the attic should be continuous. This is verified by inserting e seeker, with its point turned upwards, within the attic, and then ithdrawing it; no ridge of bone should now prevent its withdrawal.

Granulations or the epithelial lining of cholesteatomata should be moved from the recesses of the tympanum with a small curette. Care ust be taken not to injure the surface of the promontory, or the region the foramen vestibuli and foramen cochleæ. It is especially important curette away the mucous membrane from the orifice of the auditory

tube in order that scar tissue may obliterate its lumen and so prevent reinfection of the middle ear from the naso-pharynx. For this purpose a narrow curette is necessary (Fig. 210).

Removal of the innermost portion of the floor of the acoustic canal is not always necessary. Sometimes, however, the 'hypotympanum' is well marked, and in order to ensure a good result it is wiser to remove this projecting piece of bone. If the ridge of bone be removed piecemeal, and if the gouge or chisel be kept parallel to the floor of the canal, there should be no danger of wounding the bulb of the jugular vein. Cases, however, have been recorded in which this has occurred.

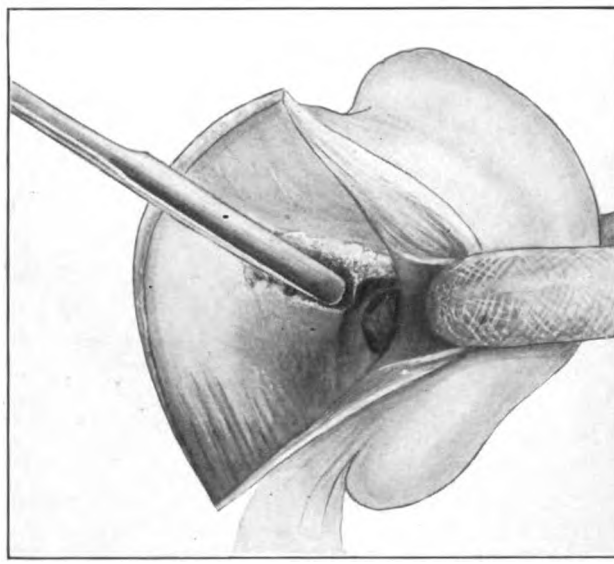

FIG. 212. WOLF'S OPERATION.

The final step is to see that no pockets nor overhanging ledges or ridges of bone remain, and that all the diseased area has been removed. The cavity, although irregular in outline, should be a continuous one with a smooth surface (Fig. 211).

Wolf's operation. This slight modification of the Küster - Bergmann operation requires merely a note of description. The position of the patient and the preliminary steps of the operation are the same as in the former operation.

In this operation, instead of first exposing the tympanic antrum cavity and afterwards removing the posterior wall of the external meatus, this procedure is performed in one step.

The chisel or gouge is first brought into contact with the bone just behind the upper posterior margin of the acoustic canal. The bone is removed in layers by chiselling it away in a forward direction and in such a manner that each stroke of the chisel is carried directly into the acoustic canal (Fig. 212). With each successive stroke, begun a little more posterior and inferior to the one preceding it, more bone is removed until at length the tympanic antrum is exposed. There should

no risk of injuring the lateral semicircular duct nor the facial nerve, ing to the fact that the lateral wall of the tympanic antrum lies super- al to the tympanum and aditus.

After the tympanic antrum has been exposed, the technique of the eration is the same as that already described in the Schwartze and ister-Bergmann operation.

Advantages. 1. If the surgeon be experienced it saves much ne, as the preliminary steps of the operation can be carried out very idly.

2. If the mastoid be sclerosed and there are no landmarks, the trum, however small, is und to be reached by king use of this thod, by keeping high and, if necessary, ex- sing the dura mater. verify the depth to ich the bone may be re- ved and also the posi- n of the antrum, the ker should be inserted casionally through the npanum into the aditus.

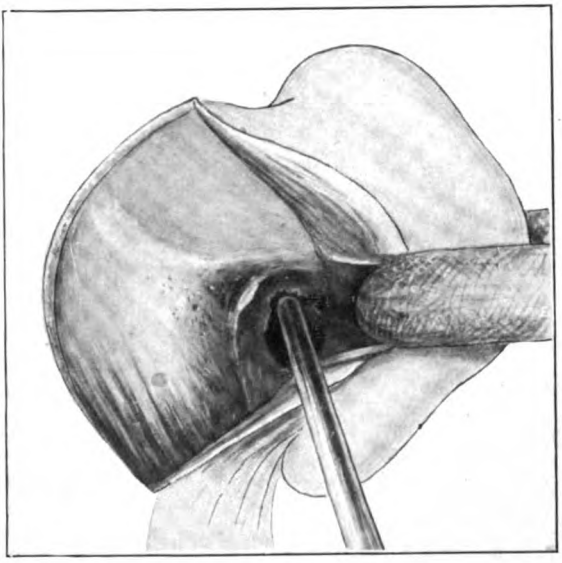

FIG. 213. STACKE'S OPERATION.

Disadvantages. If surgeon be not ex- ienced, it is not so safe nethod as that of first posing the antrum.

Stacke's operation. After exposure of field of operation, as in the Küster-Bergmann operation, the fibrous rtion of the auditory canal is separated posteriorly from the bony rtion.

Any granulations, together with the malleus and incus, are removed m the tympanum (see p. 377). Under a good illumination, using ead-lamp if necessary, the surgeon passes a seeker along the acoustic al, its point being made to project into the attic in order to define its its and that of the aditus. The innermost portion of the upper pos- ior wall of the acoustic canal, that is, the lateral wall of the attic, is v removed piecemeal by means of a small gouge (Fig. 213). By rking backwards the aditus is approached, the bone being removed efully in small fragments. The seeker is inserted repeatedly into

the entrance of the aditus so as to rest on the lateral s
duct, in order that the position of the latter and the underl
nerve may be kept constantly in mind. More bone above
to this point is removed in small fragments, until at length
and most medial portion of the antral wall is removed and
thus exposed. The cavity is gradually enlarged by removing
bone in a backward and outward direction, until finally it
that left after the complete operation. Stacke originally d
method in those cases in which he considered that the d
limited to the ossicles, the walls of the attic, aditus, and m
portion of the antrum. It was, indeed, merely a more radi
of performing ossiculectomy.

Advantages. Although this operation has practically
doned as a method of performing ossiculectomy, yet under th
conditions it may be adopted during the performance of th
operation:

1. If the mastoid be very sclerosed and if the tympanic a
not be exposed, although the bone has been removed to a d
sponding to its usual position.

2. If there be difficulty in exposing the tympanic antr
performance of the radical operation owing to the transv
projecting far forwards and the middle intracranial fossa ove
externally.

Disadvantages. The chief disadvantage is that it is mo
and tedious to begin the operation within the depth of the w
if the meatus is very deep and narrow it may be almost im
carry out.

**Preservation of the ossicles and tympanic membr
performing the complete mastoid operation.** This
operation is well known and has been performed for some y
cially by Jansen of Berlin, and in America.

The only indication for this modification of the comple
operation is disease involving the antrum and mastoid proc
tensively as to require complete removal of the posterior w
acoustic canal, without there being any co-existing bone dise
walls of the attic or of the ossicles.

As the complete mastoid operation is only performed for s
tion due to chronic middle-ear suppuration, it is difficult to im
the ossicles and attic region could remain unaffected when th
the disease necessitates the complete operation.

I consider that, if it be necessary to remove the 'bridge
necessary to remove the lateral wall of the attic and with this t

incus. If, on the other hand, there be no bone disease of the attic on or of the ossicles, Schwartze's operation, or some modification of hould be sufficient. The majority of aurists agree that, excepting hose cases in which the continuance of the suppuration is due to an yema of the antral cavity, the ossicles almost invariably are carious greater or lesser extent in chronic middle-ear suppuration. This is supported by Grunert's researches,[1] who found that the ossicles e normal in only five out of a series of 113 cases in which the com- e operation had been performed.

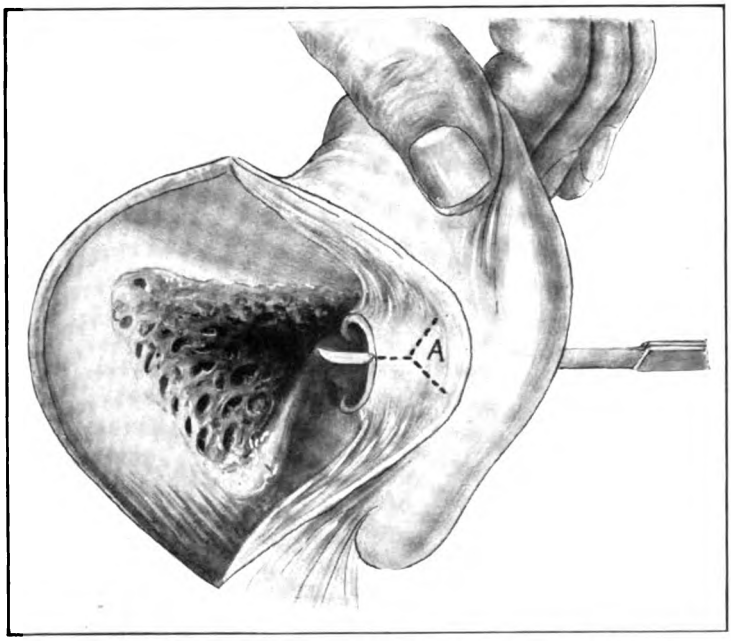

IG. 214. POST-MEATAL SKIN FLAPS (*Author's method*). Bistoury incising the erior fibrous portion of the acoustic canal. The dotted line shows the line of sion. A is the Y-shaped flap afterwards sutured to the skin behind the auricle.

Although removal of the 'bridge' may eradicate the disease within mastoid process and antrum, yet, if the ossicles are left, post-suppura- adhesions will almost certainly afterwards bind them down and so se a greater deafness than if they had been removed originally. Still, w isolated cases have been reported in which hearing to the extent of feet or more has been obtained as the result of this operation. The e results, however, frequently occur after the performance of the plete operation with removal of the malleus and incus. Until we

[1] *Archiv für Ohrenheilkunde*, Band 40, 1896, p. 188.

have a large and consecutive series, recording the results of
ticular operation in detail, together with information regarding
tion of the symptoms, the previous treatment, and the conditi
ear before operation, it is impossible to judge the value of this n

In this connexion I may mention an operation advocated b
Heath. In my opinion it is merely a modification of the
Schwartze-Küster operation, in which the posterior wound was
and packed.

Heath removes the posterior bony wall until only the 'bridg
then fashions a flap from the fibrous portion of the posterior me
closes the
wound by su
inserts a rul
draining
the meatus
antro-masto
In both the a
erations th
panum and
are not in
with, excep
Heath remo
curette any
tions block
aditus. Fr
own statistic
claims very
sults, but t
largely due
fact that he
practice of c
very early

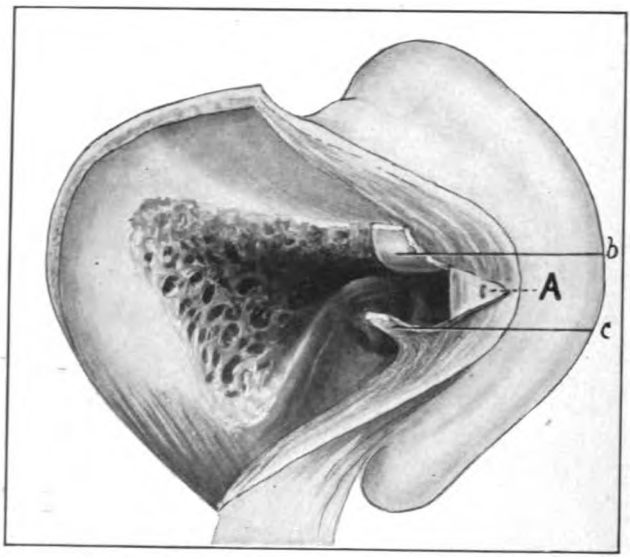

FIG. 215. POST-MEATAL SKIN FLAPS (*Author's method*). Flaps cut: A, Y-shaped flap sutured to the skin; *b*, Superior flap; *c*, Inferior flap.

of middle-ear suppuration, in many of which, according to the op
the most experienced and well-known otologists, a longer period
servative treatment first might have been attended with an equa
cessful result. In the more chronic cases in which there is disea
bony margin of the tympanum, Heath's operation is not suffic
classical complete mastoid operation being the one indicated.

THE FORMATION OF POST-MEATAL SKIN FLAPS

This is done for two reasons: firstly, to prevent stenosis
acoustic canal; and secondly, to aid the growth of the epithelium
wound surface, so that the latter will heal as rapidly as possible.

These flaps may be formed in several different ways. The following
the technique I adopt: A long, narrow, curved bistoury is passed
wn the acoustic meatus so that it projects through the detached end
the fibrous portion, its point being directed backwards. The auricle
held well forward and the fibrous portion of the meatus cut through
steriorly, from within outwards, for a short distance (Fig. 214). The
ge of the bistoury is then directed in a slanting direction upwards
d outwards, and the incision continued as far as the cartilaginous
rtion of the meatus, care being taken not to cut into the concha. The
stoury is then withdrawn and reinserted at the point at which it was
st made to turn upwards. It
now directed downwards and
twards and, in a similar man-
r, the incision is made in a
anting direction towards the in-
rior margin of the cartilaginous
eatus. In carrying out these
anipulations care must be taken
at the outer portion of the bis-
ury does not injure the tragus
other portion of the auricle,
mistake which can easily occur.
ne fibrous portion of the meatus
thus divided by a Y-shaped
cision into three small flaps;
mely, a posterior or external
-shaped flap, and a superior and
inferior flap (Fig. 215).

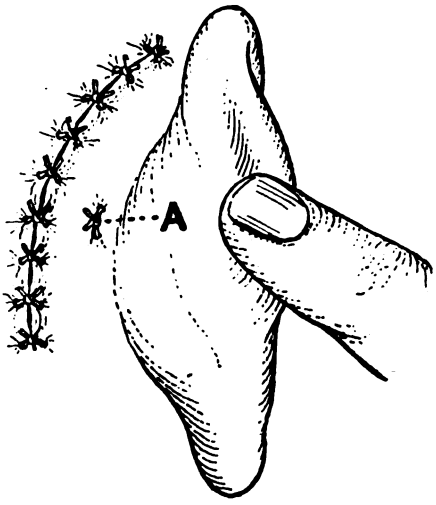

FIG. 216. CLOSURE OF WOUND AFTER 'RADICAL' MASTOID OPERATION. A is the point at which the Y-shaped meatal flap is sutured to the skin.

The outer flap is fixed to the
in behind the auricle by means
a catgut suture (Fig. 216), and
e auricle is then pulled back into its normal position. By inserting
e tip of a finger into the meatus, the upper and lower flaps are pressed
wards and downwards against the roof and floor of the mastoid cavity,
d can be kept in position afterwards by suturing the flaps to the sub-
taneous tissue or by packing the cavity through the meatus with a
ip of ribbon gauze.

Amongst other methods the following may be mentioned:

Körner's method (Fig. 217). The parallel incisions are made in
ongitudinal direction through the fibrous portion of the posterior wall
the meatus and are prolonged outwards as far as the concha. On
e auricle being restored to its normal position, this posterior flap is

pressed backwards and so covers a large area of the posterior wound surface. The chief objection to it is that, owing to involvement of the concha, there is considerable enlargement of the meatal opening and therefore subsequent disfigurement.

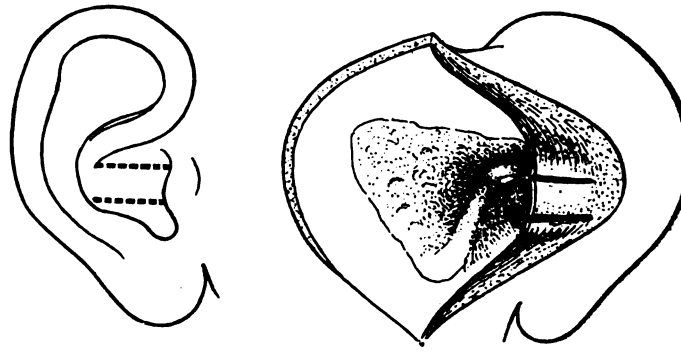

FIG. 217. KÖRNER'S POST-MEATAL FLAP.

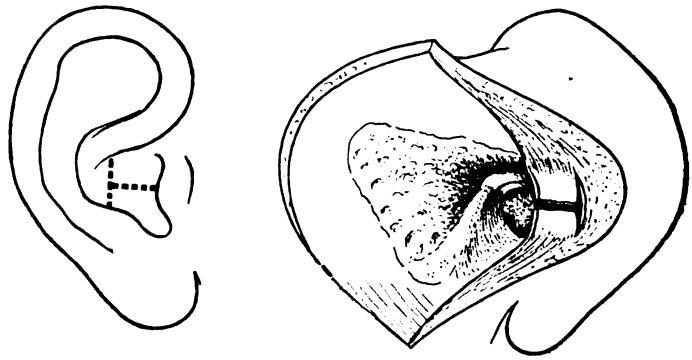

FIG. 218. PANSE'S POST-MEATAL FLAP.

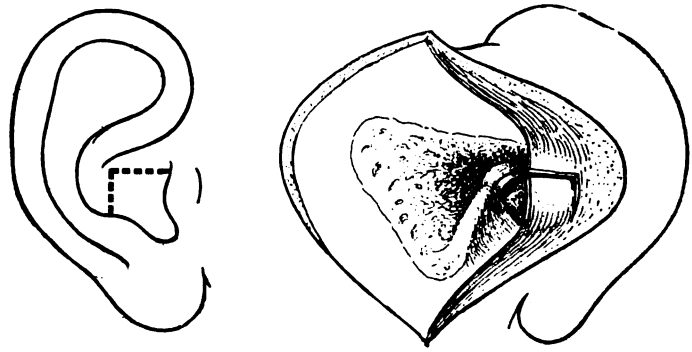

FIG. 219. STACKE'S POST-MEATAL FLAP.

s method (Fig. 218). A transverse incision is carried through
ior margin of the meatus, at the junction of the concha and
anal posteriorly. With a pair of scissors or knife, the posterior
ie fibrous portion of the canal is now split by a longitudinal
In this way two flaps are formed, a superior and inferior one.
fixed into position by catgut sutures through the subcutaneous
the upper and lower angles of the wound.

's method (Fig. 219). This consists of a large inferior flap,
y making a longitudinal incision along the posterior upper
the fibrous portion of the acoustic canal and a transverse in-
eting it at right angles, the latter cutting through the fibrous
the meatus at its junction with the concha.

ler that these flaps may be thinner and more adaptable, the
ous tissue should be cut away. Of these flaps the Y-shaped
most practicable, as it is suitable whether the posterior wound
r left open.

r's method has the objection that there is subsequent disfigure-
ng to the large meatal opening formed by cutting into the
It has the advantage, however, that the large posterior flap will
posterior surface of the wound cavity to a considerable extent,
hat it will permit a good view of the surface.

s flap is only of service if the posterior wound is left open and
s not sufficient tissue left to make a posterior flap owing to
lestruction of the posterior wall of the auditory canal.

's method is good if skin-grafting is afterwards employed.

CLOSURE OF THE WOUND

ting under the conditions mentioned below, the posterior wound
y bringing together the edges of the skin incision with fine silk-
sutures (Fig. 216). Before this is done, the wound cavity
irrigated with a weak solution of biniodide of mercury, dried,
eeper parts of the wound plugged with a strip of gauze inserted
ie external meatus. This will not only arrest the hæmorrhage
the inner part of the wound dry, but at the same time will
kin flaps in position. After the wound has been closed, firm
hould be applied in front and behind the ear to press out any
n the cavity.

inal step the gauze which has been inserted into the meatus is
and the cavity again packed evenly and lightly from the bottom
ound with a fresh strip. The ear and surrounding parts are

protected with a pad of sterilized gauze covered with cotton-wool and kept in position with a bandage.

The posterior wound should be left open under the following circumstances:

1. If there be an abscess over the mastoid process. Although it may be possible to excise the whole of the lining membrane of the abscess cavity, it is wiser to leave the wound open for the first few days. The innermost portion of the wound cavity is packed through the external meatus, only the superficial part being packed through the posterior wound incision. As healthy granulations appear, the posterior packing is diminished, so that the edges of the incision gradually come together. If necessary, the edges of the wound can also be freshened and brought together by silkworm-gut sutures under cocaine anæsthesia.

2. If there be extensive disease of the bone, especially if the dura mater and transverse sinus are covered with septic granulations.

3. If there be bone disease of the anterior and inferior parts of the tympanum. The after-treatment of packing or the curetting away of granulations can be carried out more easily through the posterior wound than through the external meatus, as it gives a better view of these regions.

4. In young children it is frequently advisable to leave the posterior wound open owing to the difficulty of packing the wound cavity through the small external meatus.

SKIN-GRAFTING AFTER THE MASTOID OPERATION

In order to shorten the duration of healing, a large Thiersch's skin graft may be transplanted into the wound cavity. If this procedure be adopted it may be carried out in several ways. The skin may be transplanted in one large piece or in several small portions, and it may be introduced into the wound cavity either immediately after the completion of the mastoid operation or from seven to ten days later.

There is considerable diversity of opinion as to whether skin-grafting should be employed or not, and also when it should be done.

This may be partially accounted for by the fact that although theoretically, the application of skin grafts is easy, yet, practically, the technique is difficult. Those who favour skin-grafting point to the fact that healing of the wound may take place within five weeks, whereas, if grafting be not undertaken, cicatrization of the cavity, even under favourable conditions, can hardly be expected to occur before eight to twelve weeks.

The skin-grafting operation as suggested by Charles Ballance is generally performed as a second stage, some ten or more days after the

ıary operation. This, from the patient's point of view, is a serious ter; and the disappointment caused by the grafting not being always essful has induced many to give it up and to be content with what ıs to be a more certain, though more prolonged, after-treatment.

More recently, however, it has been shown that in suitable cases skin fts, if applied at the time of the completion of the primary operation, take just as well as at a later date. This altogether alters the aspect ne case. If at the end of the primary operation it be certain that all diseased bone has been removed and the cavity has been rendered tic, there can be no objection to the immediate application of skin fts. If the result be successful, the period of after-treatment is con-rably curtailed. If, on the other hand, it be not successful, the ent, beyond having a raw surface on his arm or leg for a few days, is vorse off than if the graft had not been applied.

Skin-grafting, however, cannot be done in every case. Two condi-s are necessary for its success: firstly, that all the diseased bone has removed; and secondly, that the wound cavity is aseptic.

Immediate skin-grafting, therefore, should not be employed if, in tion to the chronic disease, there be acute inflammation of the mastoid ess, or of the subcutaneous tissues covering it; nor should it be e if it has been necessary to expose the dura mater over a large area, if there be any possibility of some subsequent intracranial compli-on. In such cases it may be justifiable to do skin-grafting after the e symptoms have subsided. If, however, the case be progressing factorily, the advisability of submitting the patient to a second ation should be a matter of careful consideration.

Disease of the labyrinthine wall of the tympanum, or around the ce of the auditory tube, is also a contra-indication against grafting, ne graft, if applied, will not take over these areas. My opinion with rd to skin-grafting is that if it can be applied immediately after the pletion of the primary operation it is good practice to do so, but if conditions be such that they will not permit of this it should not be e at all.

Technique. *When the grafting is done at the completion of the toid operation.* The first step is to see that the mastoid wound cavity endered thoroughly aseptic and dry. All bleeding points in the soft ues are arrested by means of pressure forceps. The mastoid cavity is filled with hydrogen peroxide lotion, and afterwards syringed with a warm saline solution, the cavity being dried with sterilized os of gauze and finally packed from the bottom with a fresh strip.

The size of the graft, which is usually taken from the thigh, should bout 2 inches in width and 4 inches in length. The skin is cleansed

by washing it with soap and water, then with ether, and finally with normal saline solution, the part being afterwards dried with a sterilized towel. It does not matter what type of razor is used to remove the graft, so long as it is sharp. The chief point to observe, in order to secure success, is to see that the skin is kept uniformly stretched—the tighter the better. The technique of removal of grafts is described elsewhere. The graft taken from the leg is transferred to a large spatula and smoothed out over its surface. The auricle is now pulled forward, and the gauze strip is removed from the mastoid cavity. The spatula is laid across the surface of the cavity so that it rests on the anterior margin of the wound surface (Fig. 220). With a sharp probe the edge of the graft, which just overlaps the spatula, is held in position at this point, the spatula being gently retracted so as to leave the graft stretched across the surface

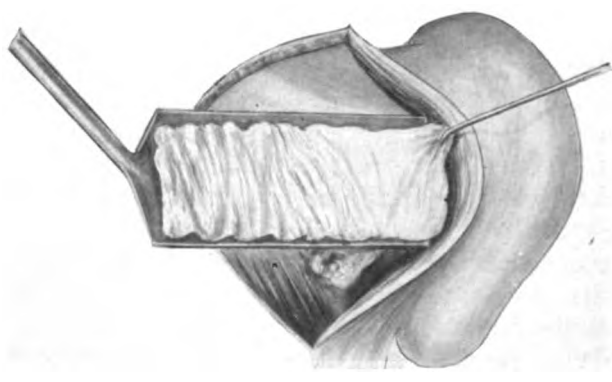

FIG. 220. SKIN-GRAFTING OF MASTOID WOUND CAVITY AFTER OPERATION. Skin graft being transferred from the spatula to the mastoid cavity.



FIG. 221. BALLANCE'S 'STOPPER' FOR PUSHING IN THE GRAFT.

of the wound cavity. With a 'stopper' (Fig. 221), the graft is now pushed inwards towards the tympanum.

A glass pipette (Fig. 222), having a curved beak, is then passed inwards beneath the graft until its point, directed downwards, lies within the tympanum (Fig. 223). Any blood which has accumulated between the bone and the graft is now sucked out, and in doing this, the graft becomes closely applied to the bone surface (Fig. 224). After remov-

the pipette, any part of the graft which is not adherent to the bone moothed out over its surface. The tympanum and mastoid cavity are

IG. 222. PIPETTE FOR SUCKING AIR AND FLUID FROM BENEATH THE GRAFT.

n plugged with a strip of sterilized ribbon-gauze, its end being brought through the external acoustic meatus.

The posterior part of the graft, still projecting beyond the posterior rgin of the wound, is v turned forwards so o form a covering over gauze filling up the und cavity (Fig. 225). the auricle being re- ed to its normal posi- , this portion of the ft is brought into con- with the subcutaneous ues of the skin forming post-aural flap, which forms the outer wall he mastoid cavity. The erior incision is closed n sutures and a dry ssing and bandage are ied to the ear.

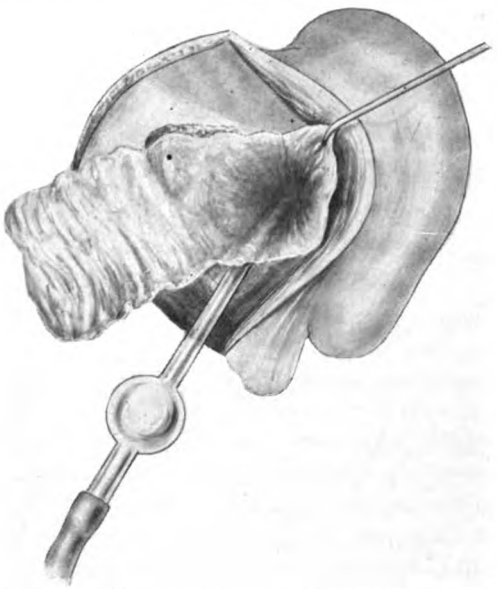

FIG. 223. SKIN-GRAFTING OF MASTOID WOUND CAVITY AFTER OPERATION. Skin graft in the act of being sucked into position by the pipette.

If skin-grafting be formed a week or more r the primary oper-

The post-aural wound, now healed, has to be reopened. In doing so e may be considerable bleeding, which must be arrested. The mas- cavity is usually found to be covered with a fine layer of granula- s. They are curetted away carefully, special attention being paid to region of the auditory tube and the floor of the tympanum. After

removal of the granulations, the bone should appear uniforml
though somewhat vascular. If any points of carious bone be fc
should be removed freely with the gouge or burr. Consider
may have to be spent in arresting the oozing from the surface of
cavity. This is best done by washing out the cavity with
peroxide solution and then plugging it tightly for a few mom
gauze impregnated with adrenalin solution. The gauze is with
a few moments. If there still be oozing, the pressure will
be repeated until it ceases. The method of applying the graft is
as already described.

The outer dressing may be changed every second day, but tl
itself, if possible, should not be interfered with until the eighth

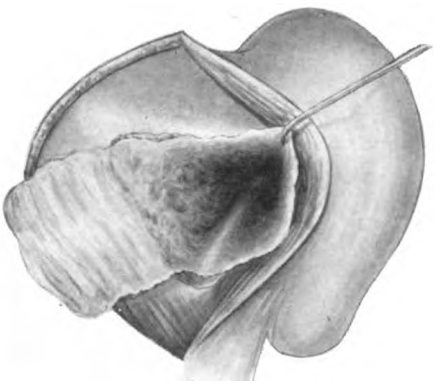

FIG. 224. SKIN-GRAFTING OF MASTOID WOUND CAVITY AFTER OPERATION. Skin graft in position.

FIG. 225. POSTERIOR PO SKIN GRAFT COVERING OUTE OF WOUND CAVITY.

asepsis has been obtained, the posterior wound has usually c
healed, so that the stitches can be removed at the first dressing.
to the secretion from within the cavity there may be a certain
of odour, and as a rule some purulent discharge from the meatus
good illumination the strip of gauze is removed through the n
means of forceps. The ear is now syringed out with a weak so
hydrogen peroxide and afterwards dried by mopping it out w
wicks of cotton-wool.

A speculum is next inserted into the meatus and the cavity th
examined. Any portions of the graft not in absolute contact
bone or which overlap the skin of the meatus will have died, ar
removed by forceps. Care, however, must be taken not to pull
portions too forcibly, as in doing so other pieces of the graft ma

The external meatus is then plugged with a tiny piece of gauze
ry dressing applied. If the graft has not taken and has died, it
expelled at the first dressing on syringing.
nost cases the external layers of the graft desquamate and are re-
at the first dressing: this does not mean that the graft has not

ther treatment consists in syringing and afterwards drying the
laily. From day to day the outer layers of the graft will gradu-
ne away piecemeal. At the end of the second week the patient can
go home and carry out the treatment for himself, but he should
by the surgeon at least once a week until complete healing has
ace. If the graft has not taken uniformly over the surface of the
mall patches of granulations may be seen covering these areas.
cocaine anæsthesia these patches should be curetted. If the
tions recur repeatedly, it means that there is some underlying
bone, and that healing will not take place until the tiny fragment
ually exfoliated.

ults. Statistics vary. There is no doubt that the results are
ccording to the experience of the surgeon with regard to grafting.
only applied in those cases in which it is certain that all the dis-
one has been eradicated at the primary operation, then the percent-
success with relation to failure is very high. If, however, skin-
g be adopted as a matter of routine, the ultimate result is prob-
so good as in a similar series of cases in which grafting has not
ne.

n-grafting through the external meatus. This has been ad-
iefly in order to avoid a second operation.
technique of applying this graft is practically the same as that
nsplanting a large graft. The same care must be taken to get
rior of the mastoid cavity aseptic and dry. To avoid a general
tic, the small grafts may be removed from the arm or leg under
æsthesia produced by a subcutaneous injection of Schleich's solu-
The graft is transferred from a small spatula to the edge of the
and then coaxed into position within the cavity by means of
The grafts are kept in position by small pellets of cotton-wool
with gauze. If successful, the grafting may shorten the duration
fter-treatment. It is not, however, so satisfactory a procedure
ing a large graft directly through the post-aural wound.
ldart Barr of Glasgow has introduced an ingenious method of
grafts into position. The graft is manipulated over the end
tably bent glass tube, having attached to the other end a piece of
ubing with a glass mouthpiece or small rubber bag. The graft

at the end of the tube is passed through a wide speculum to th wall of the tympanum, when, by blowing air through the tube, th is spread out over the medial surface, including the tympani aditus, and tympanic antrum.

AFTER-TREATMENT OF THE RADICAL MASTOID OPERAT

If the posterior wound has been closed. Provided the temp keeps normal and there be no pain nor head symptoms, the first d need not take place until the fourth or fifth day. By this time th of the skin incision may have united, so that the stitches can be re although occasionally the wound may have to be opened up to pe drainage on account of septic infection. The withdrawal of th from the acoustic canal may cause considerable pain, which, h can be prevented by continuous irrigation of the ear before and its removal.

After the gauze has been removed the ear is mopped out with p of cotton-wool. To relieve the pain a few drops of a sterilized tion of cocaine may be instilled and left within the ear for a few r

Under good illumination, the largest possible speculum is into the meatal orifice. The cocaine solution is mopped out, a cavity dried, in order that careful inspection of the deeper parts made. The chief point is to see that the flaps are in position. may be slight oozing from the surface of the wound, but as a r bone appears almost white, owing to the fact that granulations h yet begun to form. The wound is then packed gently and even gauze and the ear protected again with an external dressing and b

Until the first dressing has taken place, the patient should be bed. After this, provided the condition be satisfactory, he r allowed to get up for a few hours every day, the period being gr increased; by the tenth day or so he is practically well. In an plicated case there is seldom any shock or discomfort after the op so that frequently the patient is anxious to be up and about even the first dressing has been performed. It is wiser, however, to in rest for the first few days.

The subsequent dressings should be done every second or thi depending on the condition found. If the wound cavity be clean, there be no odour, it is sufficient to irrigate it with a simple sa boric lotion. Granulations begin to cover the bone about the ten when there may be some purulent discharge necessitating daily dre To keep the parts sweet, an ear-bath of hydrogen peroxide (10 v may be given, the ear being subsequently irrigated with a 1 in 5,00 tion of biniodide of mercury.

ovided the patient be doing well there should be no temperature, ior headaches. If any of these symptoms occur, or if the patient ll, or has attacks of sickness and becomes drowsy, the surgeon at once be suspicious of some impending intracranial complication. the case be progressing favourably and all the diseased area of bone en completely removed, granulations do not become exuberant, rm a fine smooth layer over the wound surface, the last portion ome covered being the region of the lateral semicircular duct and ge forming the remains of the posterior wall of the bony meatus. rant granulation tissue is significant of underlying bone disease. hes be observed, a 10% or stronger solution of cocaine should be l to the part, which should afterwards be curetted. This process ave to be repeated on several occasions until, perhaps, a small of bone is removed, after which granulations usually cease. As a e bone is completely covered with granulations by the fifth or sixth Meanwhile, owing to the growth of epithelium from the edges of ps, the raw surface within the wound cavity gradually becomes r, and with this there is diminished secretion.

e gauze packing can usually be discontinued about this period, or erably earlier, perhaps even by the third week. In its stead an s solution containing 50% of rectified spirit, with 10 grains of boric the ounce, may be instilled into the wound cavity after it has been d and dried.

mplete cicatrization of the cavity should take place within two or nonths, depending on the size of the cavity.

the posterior wound has been left open, the first dressing should e on the second or third day.

e subsequent treatment depends on each individual case. If the has been left open on account of its septic condition, or owing to a mater having been exposed and found covered with granulations, es may be brought together by sutures after a period of ten days when the wound cavity looks clean, and the packing carried out h the meatus.

the other hand, if the wound has been left open on account of bone involving the labyrinthine wall of the tympanum or region of the y tube, the packing should be continued through the posterior g until the patches of carious or necrosed bone heal or are ex- l. In these cases the granulation tissue tends to become fibrous acter in consequence of the necessary curettings, and eventually n a thickened pad covering the inner wall.

er complete healing has taken place, the patient, before being dis- should be warned to visit the surgeon at least once in three

months. Owing to the large cavity being lined with epithelium, d
mation takes place to a greater or lesser extent, so that the wound
may gradually become filled with masses of epithelial débris or cer
In consequence the cavity may become septic, and on removal
epithelial débris underlying ulceration may be found. This can u
be cured by aseptic treatment, but if granulations have already occ
curetting and the application of trichloracetic and chromic acid n
necessary.

DIFFICULTIES AND DANGERS OF THE OPERATION

Anatomical difficulties. The chief difficulties are due to a
fossa overlapping the antral cavity, a transverse sinus projecti
forwards and lying superficially, and a sclerosed mastoid having nc
marks to indicate the way into the tympanic antrum. Unfortu
these conditions are frequently associated.

Formerly it was advised that it was wiser not to proceed further
antral cavity could not be discovered after chiselling to a depth of
quarters of an inch. This advice, however, is no longer reliable,
the combination of the Stacke, Wolf, or Küster-Bergmann metho
anatomical difficulties should certainly be overcome.

An inexperienced operator may mistake a large mastoid cell f
antrum and in this way may get into difficulties. The opening in
antrum, however, can always be identified by passing a bent ma
silver probe in a medial and forward direction into the aditus. I
a large cell has been opened, the probe will show that it is a limited

Hæmorrhage. In the majority of cases this is more of an
venience than a danger, being chiefly due to a general oozing fro
soft tissues. It is, however, very necessary that the surgeon should
a clear view of the deeper parts whilst operating. If he works blin
a pool of blood he courts disaster.

The hæmorrhage is best prevented by first curetting away any g
lation tissue and then packing the cavity firmly with a strip of gauz
this be not sufficient, it may be again packed with gauze conta
adrenalin solution. It will repay the surgeon to have a good assist
keep the field of operation dry. Troublesome bleeding, coming
a small vessel in the bone, may be arrested by the local applicatio
small fragment of Horsley's sterilized wax.

Wound of the transverse sinus. This is a serious matter fo
reasons: firstly, it may prevent completion of the operation; and sec
it may lead to infection of the sinus.

If the sinus has already been exposed before the accident occur
surgeon promptly arrests the hæmorrhage by placing the forefinger

directly over the wound in its wall and exerts sufficient pressure
y to obliterate the sinus at this point. With his finger kept
osition, the wound cavity is carefully dried, and, if there be
room, a piece of sterilized gauze is then packed between the
the outer wall of the sinus, both above and below the site of
y. If there be not enough room to do this, then the surgeon
right hand, or the assistant, should punch away more bone by
bone forceps. After the lumen of the sinus has been obliterated
d below the injured area, the finger may be removed. If the
as been successful, there will be no bleeding; if there be still
eding, it can be controlled by further pressure. If possible, this
hould always be carried out, as it practically excludes any chance
nfection of the sinus.

e injury takes place before the sinus has been sufficiently ex-
permit of direct pressure with the finger, then the only thing
o press in a small strip of gauze and plug the opening. As to
uld be done next is a matter of opinion. Some surgeons are
o leave the gauze *in situ*. The author prefers to expose the sinus
as in the former case, and to make certain that it is obliterated
d below the injured area. No doubt, if the injury be slight,
ure of the strip of gauze covering the puncture will be sufficient
l the hæmorrhage, and the patency of the sinus may be main-
healing. At the same time, infection of the sinus has been
take place, although the symptoms of this may not occur for ten
wo weeks after the operation.

e sinus projects far forwards, the gauze plugs may so incon-
the operator as to prevent him completing the operation, which
may have to be delayed for at least a week. If, however, the
njured at an early stage of the operation and the symptoms for
is being performed are urgent, then, in spite of all difficulties,
m, at any rate, must be opened to permit of drainage, the opera-
g completed at a later date.

y to the facial nerve. The nerve may be injured in any part of
e within the tympanum, or in its vertical course through the
toid foramen. To avoid this injury, curetting of the tym-
ould always be performed gently, and care should be taken not
too low down,—the usual fault of the inexperienced.

hing of the face means that the nerve has been touched. If the
e under deep anæsthesia, it is difficult to say whether the nerve
njured or divided. In a case of doubt, it is wiser to discontinue
hetic until the conjunctival reflex returns, when it can easily be
ated whether the facial nerve is affected or not.

If the injury be the result of curetting, it is wiser to do
Recovery almost invariably takes place, owing to the fact
paralysis has been caused by slight injury of the nerve. If, howe
nerve has been chiselled through, and the injury has occurred in
portion, it should be freely exposed over this area. The severed
the nerve should then be approximated and left *in situ*. In
permanent paralysis is possible.

The after-treatment consists in avoidance of pressure in pack
giving of strychnine internally, and faradism or galvanism to
the tone of the facial nerve and the muscles it supplies. Carefu
of the electrical reaction will show whether nerve regeneration
place or not. If the paralysis has existed for six months, and if
tion there be a definite reaction of degeneration, then the que
anastomosing the peripheral portion of the facial nerve to the a
nerve, or what is more advisable, to the hypoglossal nerve, may
sidered.

Injury to the labyrinth. Of the semicircular ducts the later
more liable to injury. The cochlea may also be injured from
curetting of the labyrinthine wall of the tympanum, or infected f
lodgement of the stapes; or it may even happen that a careless
may inadvertently chisel through the labyrinthine wall of the ty
itself. In consequence of these accidents, vertigo, vomiting, and
mus may persist for several days, but as a rule they gradually
and disappear.

The treatment is expectant. As a result of pyogenic infecti
puration of the labyrinth may occur. Even if this does not tak
complete deafness may result.

Injury to the dura mater. The subsequent danger is me
fortunately a rare occurrence. The immediate treatment is to
the part with weak biniodide of mercury solution, and then to
more bone over the site of the injury. The intracranial press
keep the dura mater in close contact with the bone, so that if sub
infection occurs there will be free drainage. The site of injury sh
carefully isolated from the general mastoid wound cavity by cov
with sterilized gauze. If signs of meningeal irritation occur, the
should be inspected, and if there be any evidence of localised me
it should at once be surgically treated.

RESULTS OF THE OPERATION

With regard to life. If, at the time of the operation, the dis
limited to the mastoid cavity, there should be no immediate danger

With regard to recovery. (i) *The operation is suc*

ly speaking, this occurs in at least 80 per cent. of the cases, com-
ealing taking place within eight to twelve weeks. If skin-grafting
en successfully performed the duration of healing may be consider-
horter. If the bone disease has been eradicated with complete
g of the cavity, the possibility of intracranial complications in the
can be excluded. On this account the patient may be considered
ealthy individual from an insurance point of view.

) *The after-treatment may be prolonged.* The chief causes of de-
healing and continuance of the suppuration are sepsis and caries
ne part of the bony wall, usually the labyrinthine wall or floor of
npanum, or around the orifice of the auditory tube. In the former
ar-baths of hydrogen peroxide or of rectified spirit, or frequent
ing of the cavity with a weak solution of biniodide of mercury, and
ards drying it and protecting it with gauze, may be sufficient to
a cure. In the latter case the local condition must be treated.
other condition delaying cure is reinfection from the throat
h a patent auditory tube. In this case, although the mastoid cavity
es lined with epithelium, mucous membrane may still cover not only
gion around the orifice of the auditory tube, but the main portion of
npanum. The chief object in these cases is to close the orifice of
ditory tube. Sometimes this can be done by curetting under
e; in other cases by actual cauterization. After closure has been
ed, the cavity should be dried and gently packed with gauze im-
ted with boric acid or aristol powder.

ain, cholesteatomatous formation may be the immediate cause of
es. In these cases it is very difficult to remove all the diseased
Even although the patient may apparently be cured, yet, unless
nder close observation, recurrence of cholesteatomatous masses
lace, and frequently causes further caries of the underlying bone.

nally, delay in healing may be due to careless after-treatment:
cavity has not been properly packed, granulations spring up in the
of the aditus and gradually form a partition between the tym-
antrum and tympanum. If this takes place, further disease of the
nay occur owing to the retention of the secretion.

i) *Symptoms may occur pointing to some intracranial complica-*
nd further operation may become necessary.

ith regard to hearing. The hearing power depends not only on
ndition before operation, but also on the result of the after-treat-
The average hearing power after the removal of the malleus and
s about 12 feet off for ordinary conversation. The same result
be obtained after the complete mastoid operation, provided there
nternal-ear deafness and provided the stapes be not already anky-

losed within the foramen vestibuli. If the patient, before operation, hears conversation at a greater distance than 12 feet he should be told that the hearing power may be reduced to this amount. If, however, there be considerable deafness, due to polypi or granulations blocking up the tympanum and acoustic canal, the hearing power may be improved by the operation. The ultimate hearing depends on the condition of the stapes within the foramen vestibuli: if it remains freely movable, the hearing power may be extremely good. The great object, therefore, of the after-treatment is to prevent the labyrinthine wall of the tympanum becoming covered with granulations which may become organized later into a fibrous pad covering the labyrinthine wall of the tympanum, and thus prevent movement of the stapes and, consequently, marked deafness. The prevalent idea that the hearing power is destroyed irrevocably, as a result of the complete operation, is quite wrong: equally so is the harmful statement that, as a result of this operation, complete restoration of the hearing can be obtained.

CHAPTER VII

OPERATIONS UPON THE LABYRINTH

GENERAL CONSIDERATIONS

; to our more exact knowledge of suppurative disease of the
it is now recognized that its occurrence is of far greater fre-
n has hitherto been supposed; according to different authorities
to occur in from 1 to 2 per cent. of all cases operated on for
iddle-ear suppuration. It is a rare complication of acute
suppuration, but, as such, makes the prognosis very grave, as
greater tendency for the infection to spread to the meninges.
ıer hand, it is a matter of experience that in the case of acute
suppuration, drainage of the middle ear and opening of the
ocess usually results in subsidence of the symptoms of labyrin-
ımmation, because in many cases these symptoms are really due
nia of the labyrinth or to peri-labyrinthitis. This is an impor-
which should be remembered, as otherwise the labyrinth may
d unnecessarily, with considerable risk to the patient's life.
ses of labyrinthine suppuration are tuberculous disease of the
one; a traumatic lesion, from fracture of the base of the skull,
illed attempts to extract a foreign body from the middle ear, or
ry to the labyrinthine walls during the performance of the
peration.
ost frequent paths of the infection are through the lateral
ar duct, labyrinthine wall of the tympanum, and the foramen
or from direct extension of the inflammatory process through
self, in rare cases the sequel of a deep-seated extradural abscess
ous bone.
deciding the question of operation every available means
used to determine: (1) whether the symptoms are merely the
isturbance of the labyrinthine function in consequence of sup-
still limited to the tympanum and tympanic antrum; (2)
e labyrinthine lesion is localised or general; or (3) whether the
ıe suppuration is associated with some intracranial complica-
especially meningitis or cerebellar abscess.
oms suggestive of labyrinthine suppuration are vertigo, vomit-
aneous nystagmus, and disturbances of the equilibrium. In

the more acute cases there may be loud tinnitus, pyrexia, rapid deafness (with inability to hear high tuning forks and loss of b duction), facial paralysis, and deep-seated pain.

As the indications for the various operations on the labyrinth on the type of labyrinthitis present, and as the differential frequently cannot be made without the aid of certain physical is essential for the surgeon to be acquainted with these tests, knowledge of which we are chiefly indebted to Bárány,[1] of Vien

The space at my disposal prevents me giving the physiologica for these tests, and it is only possible to state them briefly and their practical significance.[2]

1. **The Rotation Test.** This test depends on the move endolymph in the semicircular ducts during the act of rotatio which only the canals lying in the horizontal plane are affected. of rotation produces nystagmus, and, to obtain the maximum e patient should be revolved ten times, at the rate of one revo two seconds. The *after-nystagmus,* after the rotation ceases, tween 30 and 40 seconds.

To test the lateral semicircular ducts, the patient sits upri the head bent forward 30 degrees, this bringing the lateral sem ducts into the *horizontal* plane. On rotating the patient to t a *horizontal* after-nystagmus will be elicited to the left, whi creased in intensity if the patient turns the eyes towards the On the patient being rotated to the left, nystagmus is produced the right side. If both lateral ducts be normal, the duratio nystagmus on each occasion should be about equal. If one du functioning the nystagmus will be markedly diminished towa side when the patient is rotated to the opposite (the sound) sid if the patient be rotated to the affected side, the duration of th mus towards the sound side will remain normal.

Similarly, to test the vertical ducts, the patient should be r the same manner, the head now being bent 90 degrees forward clined so that the face looks towards the right or left shoulde former case the right superior and left posterior ducts lie in the h plane; in the latter, the left superior and right posterior ducts occupy this position. Rotation normally will cause a *rotatory* ny towards the side opposite to the direction of rotation, but if on non-functionating the nystagmus will be diminished towards the side, on rotating the patient towards the sound side.

In a circumscribed lesion of the lateral semicircular ducts

[1] *Physiologie und Pathologie des Bogengang-Apparates beim Mens*
[2] *The Labyrinth,* Braun and Friesner, 1913.

e a matter of importance. Supposing the right lateral semicircular s found to be non-functionating, the test should then be applied vertical ducts. If they are found to react normally, the diagnosis ocalised lesion can be safely inferred. On the other hand, if the l semicircular duct is found to be normal, it is not necessary to the test to the vertical ducts, as there is no evidence at present ircumscribed lesion of these ducts can occur without involvement lateral semicircular ducts.

The Caloric Test. The ear is gently irrigated with hot or cold No pressure must be used. It is best to irrigate by means of a continuous stream. Bárány states that the cold water should be 30° rade (86° Fah.). A lower temperature may be used to bring about e rapid reaction, although this may produce great discomfort to tient by causing nausea and vomiting. For the hot-water test, the rature should be about 110° Fah., and is chiefly used in cases where aneous nystagmus is present. The average time required to produce gmus is 30 to 40 seconds, and in a normal case it has duration of two minutes. To obtain the best results the duct to be tested must the *vertical plane*. To test the lateral semicircular duct the head ed about 60 degrees backwards and inclined 45 degrees towards ffected side. With cold water, a horizontal nystagmus to the op- side is obtained; with hot water, to the same side. If no nystag- s obtained the lateral semicircular duct is non-functionating. To ne vertical ducts the head is thrown forward 90 degrees—that is, grees forward from the vertical plane. If the vertical ducts are , a rotatory nystagmus will be obtained; if they also are non- ionating, nystagmus will not be obtained.

The Fistula Test. This test depends on there being a fistula gh the labyrinthine bony wall (usually the lateral semicircular whilst the labyrinth itself is still functionating. On inserting the a Politzer bag into the meatus, or placing a Bier's cup over the e itself and then compressing the air, nystagmus and movements e eyes will be produced. The result depends on the position of the ; as a rule, the eyes deviate in the opposite direction to the nys- us, which is of the horizontal rotatory type. Nystagmus produced ction is weaker than, and is in the direction opposite to, the nys- us produced by compression. If the labyrinth is non-functionating, stula test will be negative. On the other hand, in cases in which the on and caloric tests fail, this test may be positive, and then becomes ry great importance as an aid to diagnosis.

pontaneous nystagmus occurs in recent cases of labyrinthitis if the ed labyrinth is still functionating, or if sufficient time has not yet

elapsed (after the affected labyrinth has become non-functionat the sound labyrinth on the opposite side to compensate fully for of function on the affected side.

Spontaneous nystagmus is affected by the rotation and calo In these cases Bárány uses a ' fixator ' which consists in a head which is attached a horizontal rod (about 6 inches in length) w be moved from side to side. At its farthest point is fixed a ver ending in a small knob. The rod is turned towards that point the spontaneous nystagmus disappears when the patient fixes upon it. Immediately after the rotation and caloric tests, th once more fixes his gaze upon the vertical rod, and the an nystagmus elicited by the test is then estimated.

In the majority of cases the nystagmus is directed to the so and is of the combined rotatory and horizontal type. In the stages of the disease, especially in a circumscribed lesion of th semicircular duct, nystagmus may be directed to the affected sid the affected side becomes non-functionating, the nystagmus is to the sound side and becomes more marked if the eyes be turne side: conversely, on directing the eyes away from the sound the affected side, it is diminished or even arrested. It is char of vestibular nystagmus that it tends to diminish in intensity, nystagmus produced by a cerebellar lesion tends to increase in during the progress of the disease.

Associated with vestibular nystagmus are vertigo and ataxi bear a definite relationship one to the other. Thus, a patient from acute labyrinthitis on the right side will have a nystagmus to the left side (the sound side), the surrounding objects appe rotate towards the left (the sound side), and the patient himsel or fall gradually towards the right (the affected side). A pat vestibular nystagmus tends to fall in the direction opposite nystagmus. Thus, if the nystagmus is to the left, he will fa right; if the head is turned towards the left shoulder, he will fall forwards; and if the head is turned towards the right sho will tend to fall backwards. In cerebellar abscess, the nysta usually directed to the side of the lesion and the patient also fall to this, the affected, side.

Hearing tests. These are of importance. Unless the p completely deaf—that is, unless he fails to hear any of the tuni either by air or bone conduction—a general suppurative laby should not be diagnosed. In a circumscribed lesion of the late circular duct, the hearing may not be affected, and if so, o certain degree. In diffuse serous labyrinthitis, which close

s suppurative labyrinthitis, some remnant of hearing nearly always ains.

Indications for operation. 1. **In non-suppurative labyrinthitis.** (*a*) *To relieve vertigo.* This operation was first introed into this country by Richard Lake,[1] who removed the roof of the ral semicircular duct, and then enlarged the opening along the duct the vestibule, the roof of which he also thoroughly removed. The es was then extracted to make a counter-opening. If the patient is eady completely deaf, this operation may be justifiable to relieve the tigo. If, however, there be considerable hearing power in the affected an operation should not be undertaken unless the patient clearly derstands that as the result of this operation he will become completely f. Before any such operation is suggested, it is essential to make tain that the attacks of vertigo originate from some lesion within semicircular ducts.

(*b*) *To relieve tinnitus.* Extirpation of the cochlea has been sugted by Lake and Milligan for this affection, but it cannot be recomnded except as an extreme measure, as this surgical procedure, hough successful as an operation, has been very disappointing with ard to curing or even relieving the tinnitus. Apparently it is imsible to state in which cases it will do so.

If tinnitus and vertigo co-exist, then a complete labyrinthectomy y be of some value. It is necessary, however, to wait for further orts from the various clinics before a definite opinion can be formed to whether such operations are justifiable or not.

2. **In suppurative labyrinthitis.** Under this general term is inded (i) a circumscribed lesion (*a*) of the semicircular ducts and (*b*) the cochlea; (ii) diffuse suppurative labyrinthitis.

Although much attention has recently been directed to these operans, opinions still differ with regard to their indications and to their hnique.

It can, however, be stated definitely that the labyrinth should not be ened unless the signs and symptoms of a suppurative lesion are clearly sent: to open a normal labyrinth in the course of a middle-ear supration often leads to a fatal issue. In *acute* inflammation of the labyth, operation should only be undertaken as an extreme measure, as re is no doubt that the risk to the patient's life is much greater during acute stage than in the chronic stage: in the latter case, the inflamtory adhesions have already shut off the infective labyrinth from its mmunications with the intracranial cavity.

The indications, therefore, of these operations are best discussed by sidering each type of labyrinthine lesion.

[1] *Lancet*, January 6, 1916.

(i) A circumscribed lesion of the semicircular ducts. It is now universally accepted that an operation should only be undertaken if the labyrinth is non-functionating. If the labyrinth be functionating, it is sufficient to perform the complete mastoid operation, the erosion of the semicircular duct being left severely alone. In the majority of cases the symptoms will then subside, but if, subsequently, a general labyrinthitis occurs, further operation must be undertaken.

(ii) Diffuse suppurative labyrinthitis. The patient may come under observation in the *acute* or *latent* stage, during the course of an acute or chronic suppuration of the middle ear, or as a sequel to some operative procedure on the middle ear.

(1) *In the acute stage.* (*a*) If occurring in the course of acute middle-ear suppuration, the mastoid cells should be opened and the tympanic membrane freely incised. Provided there are no signs of meningeal irritation, nothing further should be done, in the hope that the symptoms of labyrinthine inflammation may subside. Continuance or increase of the symptoms may require further operation in order to prevent meningeal infection.

(*b*) If the acute symptoms arise during the course of a chronic middle-ear suppuration, the complete mastoid operation should be performed and the labyrinthine wall of the tympanum and region of the semicircular ducts carefully inspected to see if there be a fistula, granulations, or exudation of pus. If there is no actual disease of the labyrinthine wall, it is wiser to wait in order to see if the symptoms subside rather than to operate at once; their continuance means operation, especially if the labyrinth is proved to be non-functionating.

(*c*) If symptoms of acute labyrinthine suppuration occur immediately after the mastoid operation (usually the result of dislocation of the stapes or injury to the promontory and semicircular ducts), or in consequence of an unskilled attempt to extract a foreign body, opinions differ as to whether the labyrinth should be opened or not. Alexander, of Vienna, considers this should be done. Personally, I think it wiser to wait, to see if the symptoms subside, and only to operate on the labyrinth when it is certain that acute labyrinthitis or symptoms of meningeal irritation are present. I have recently published a case of this type,[1] in which the superior semicircular duct was deliberately cut through in order to obtain room to search for and to drain an extradural abscess situated at the apex of the petrous bone. As a result of this procedure there was diffuse serous labyrinthitis, but the patient made a good recovery.

(2) *In the latent stage.* (*a*) Operation is indicated if, in the course

[1] *Lancet*, April 19, 1913.

chronic middle-ear suppuration, there is a definite history of labythine inflammation and the tests show that the labyrinth is nonnctionating. (*b*) If, on performing the complete mastoid operation, vious inflammation of the labyrinth be discovered, such as a fistula, anulations, or pus exuding from the labyrinthine wall of the tymnum, foramen cochleæ, or foramen vestibuli, or from the semicircular cts (unless the lesion in this case be definitely localised). (*c*) If there e definite symptoms of cerebellar abscess and the labyrinth be nonnctionating.

Surgical anatomy. The facial canal, it will be remembered, tends horizontally backwards above the labyrinthine wall of the tymnum, and passes downwards superficially to the inferior portion of e vestibule, lying between the foramen vestibuli below and the ampuly ends of the lateral and superior semicircular ducts above. The rve then extends directly downwards towards the stylo-mastoid foraen, being situated deeply within the posterior meatal wall.

Of the semicircular ducts, the lateral is the most prominent and the ly one visible during the performance of the ordinary mastoid operan, its lateral border forming the medial and inferior boundary of the itus, and usually recognized as a white eminence. The superior semicular duct can only be seen on careful removal of the overlying bone; ampullary end is found lying just above that of the lateral duct. It rms the highest point of the labyrinth, becoming fused with the innerst portion of the tegmen tympani, and is in such close relationship th the superior surface of the petrous bone as to cause a smooth elevan on its surface. It is at this point in the operation for removal of e semicircular ducts that the greatest risk is encountered of breaking rough the petrous bone and of injuring the dura mater, which at this uation is very adherent to the bone and tears readily.

The posterior semicircular duct lies at right angles to the lateral ct, and is best exposed by careful removal of bone just posterior to e latter.

The lateral half of the first whorl of the cochlea is formed by the yrinthine wall of the tympanum. Anteriorly it is in close relationship th the carotid canal, whilst below lies the dome of the jugular fossa. edially the modiolus is only separated from the internal auditory atus by a very fine rim of brittle bone, which can easily be broken; nishap which may permit of escape of the cerebro-spinal fluid, and o of possible infection of the meninges through the internal meatus.

Methods of operation. Opinions still differ with regard to e method of operation, but it is now universally accepted that a free ening into the vestibule is essential after operating on the semicircular

ducts. If this is not done, sufficient drainage will not be obtained, and such an operation, instead of removing the danger of infection to the meninges, may indeed increase it. On the other hand, it is seldom necessary to remove the semicircular ducts in their entirety.

It is also an undecided question whether the cochlea should always be opened after opening the vestibule. Since free opening of the vestibule will in itself cause complete deafness, if not already present, the only reason for not opening the cochlea is to avoid further risk of infection through it to the meninges. The risk of opening the cochlea, if properly performed, is less than the risk of leaving it unopened, after an operation in the vestibule and semicircular duct. If, after such an operation, no counter-opening has been made through the promontory, and septic infection of the cochlea occurs as the result of the vestibular operation, the danger of meningitis ensuing is a very real one.

Technique of operation. Whatever operation be adopted, the first step is to perform the complete mastoid operation. The chief difficulty is to expose the field of operation so as to obtain sufficient room for the necessary manipulations. To do this the following steps should be carried out. The tip of the mastoid process and the remains of the posterior wall of the acoustic canal are removed to their extreme limit without injury to the underlying facial nerve. The floor of the acoustic canal is also chiselled away until the lower level of the tympanum is brought freely into view, the amount of bone removed depending on the anatomical condition found. To expose the anterior portion of the tympanum the skin incision is extended slightly forwards, but not far enough to wound the temporal artery, the soft tissues being then separated from the bone and the auricle pulled still further forwards and downwards.

Skin meatal flaps are now fashioned—either the Y-shaped flap or Stacke's flap (see p. 426)—and are afterwards kept in position by means of sutures. Good illumination is necessary, and for this reason a headlight should be used. One assistant is employed to retract the soft tissues from the wound, another to keep it as dry as possible.

Curetting away of a localised lesion of the labyrinthine wall. It has been already stated that, provided the labyrinth is still functionating, it is not justifiable to explore it on the mere discovery of an erosion of the semicircular duct. At the same time, if a definite fistula from which granulations protrude is present, a small fragment of bone may be chipped away, the granulations being afterwards removed by the curette. Unless pus is found to exude, it is not necessary to do anything further at the moment, but if, at a later period, symptoms of labyrinthine infection occur, then it will be necessary to explore the semicircular

and vestibule further, the extent of the operation depending on is discovered at the time of the operation.

Sometimes it is impossible to make an examination of the labyrinthine of the tympanum before operation, owing to the acoustic canal g filled with polypi or granulations, and consequently an unsuspected la of the promontory may only be discovered on performing the plete mastoid operation. Not infrequently these cases are tubercu- in origin and are accompanied by facial paralysis. Provided there o labyrinthine symptoms, it is sufficient to curette out the granula-s, but only gently. ent curetting may k through the bar- between the infected and the internal tus and so lead to ingitis. It is wiser urette too little than much, but if the fis- in the labyrinthine of the tympanum small, the opening t be enlarged.

A further condition ch may be met with ecrosis of a portion he labyrinthine wall ne tympanum, of the s of the vestibule, or ne semicircular ducts. ne sequestrum is not e at the time of op- ion, it should be left *situ*, provided there no intracranial symptoms. After the operation, the wound cavity uld be kept open, so that the sequestrum can be removed after it has rated from the living bone.

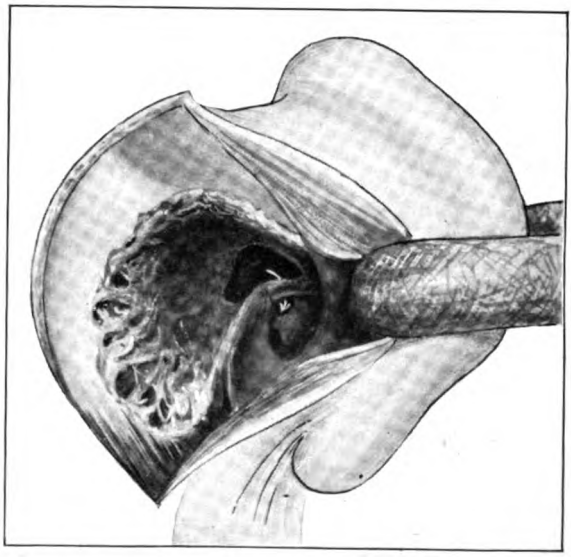

FIG. 226. OPERATION UPON THE LABYRINTH. To show the opening into the vestibule above the facial nerve with partial or complete removal of the semicircular ducts. The arrow passes behind the facial canal between the vestibule and the foramen vestibuli.

Opening of the vestibule with partial or complete removal of the icircular ducts. This can be done either above or below the facial e, called by West and Scott[1] 'superior' and 'inferior' vestibulotomy.

Superior vestibulotomy. The exposed portion of the lateral semi- ular duct is first identified, and its eminence is then removed. This

[1] *ceedings of the Royal Society of Medicine,* Otological Section, April 1908.

is best performed by means of a small gouge and mallet, the direction of the instrument being parallel to the plane of the canal. The bone is removed in small layers as, owing to its brittleness, it is very apt to splinter and involve the facial canal. Once a sufficient opening has been made so as to expose the interior of the canal, it is followed forwards and upwards until its ampulla is opened. After this has been done, a fine probe, bent at right angles, is passed into the opening, and the limits of the vestibule are made out as far as possible. The bone is then removed in an upward direction until the ampulla of the superior semicircular duct is reached. The opening may then be extended backwards so as to remove the lateral wall and roof of the vestibule—that is, the portion of bone which lies between the ampullæ of the superior and lateral semicircular ducts. The opening must be sufficiently free so as to expose to view the inner portion of the vestibule. During each step of the operation a clear view must be obtained. The lateral margin of the lateral semicircular duct should be left intact to avoid injuring the facial canal.

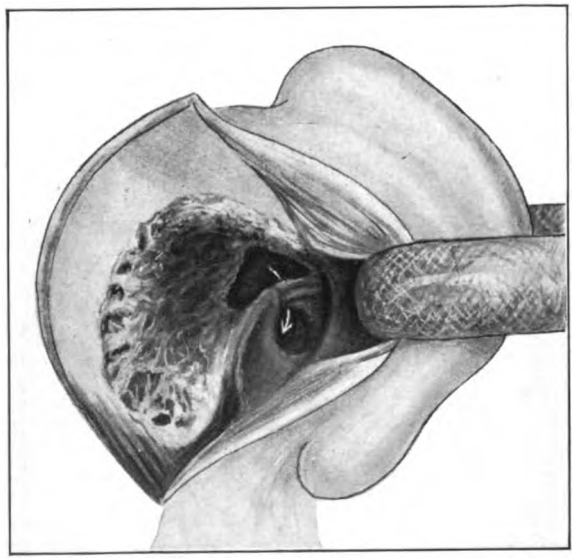

FIG. 227. EXTIRPATION OF THE LABYRINTH. The vestibule is freely opened and the greater portion of the semicircular ducts and cochlea is removed.

This is practically Jansen's original intratympanic operation. He also advocates another method of reaching the vestibule posteriorly by tracing the lateral semicircular duct backwards and following it round to its posterior inner opening into the vestibule, which is then opened by removal of the bone parallel to and above this semicircular duct.

Inferior vestibulotomy consists in removal of the stapes, if this ossicle be present, and in cutting away the bone between the foramen vestibuli and the foramen cochleæ rotundum. No bone should be removed above the foramen vestibuli. The advantage of this method of opening the vestibule is that the first half-whorl of the cochlea can also be opened by removing the anterior portion of the labyrinthine wall of the tympanum.

berg also recommends this method as the first stage of opening inth. After removal of the labyrinthine wall of the tympanum, s a small probe, bent at right angles, into the opening. This is ehind the facial canal and 'bridge' of bone, and serves to indi- position of the roof of the vestibule.

ble vestibulotomy consists in the combination of both superior rior vestibulotomy.

rpation of the labyrinth. This consists in *complete* removal emicircular ducts, cochlea, and vestibule, leaving only the facial act. Richards,[1] of America, is the chief exponent of this method. oval of the semicircular ducts is an extremely difficult and procedure. When possible, the outlines of the ducts are first

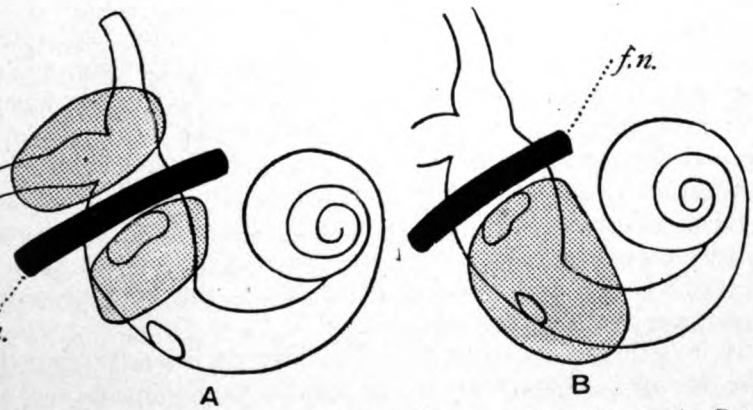

228. DIAGRAM TO ILLUSTRATE THE AREAS CONCERNED IN A, DOUBLE LOTOMY; AND B, INFERIOR VESTIBULOTOMY WITH PARTIAL REMOVAL OF HLEA. *f.n.*, facial nerve. (After West and Scott.)

Unfortunately, the bone is sclerosed in the majority of cases, ng an anatomical exposure of the ducts an impossibility. The duct is followed backwards, its lateral upper wall being removed se its interior. Similarly, the superior duct is explored upwards vards, special care being taken not to tear the dura mater, which point is very adherent to the superior arcuate eminence—that is, f of the superior semicircular duct.

opening and removal of the posterior semicircular duct is best just behind the semicircular duct, by following it upwards and ds until it reaches the superior duct. The solid bone which lies n the planes of these three ducts Richards describes as the 'solid

[1] *Trans. of the American Laryng., Rhin., and Otol. Society*, 1907.

angle.' If the bone be here removed in a forward and downward direction, the vestibule will be entered.

Before extirpating the cochlea, it is essential, according to Richards, to define the exact position of the carotid artery by exposure of its canal; to do which the removal of the floor of the acoustic canal and the convexity of the innermost portion of its anterior wall together with the lip of bone overhanging the mouth of the auditory tube and avulsion of the tensor tympani muscle are necessary. These extreme measures, however, are not generally adopted, although frequently the floor and part of the anterior wall of the innermost portion of the acoustic canal must be removed.

In removing the first whorl of the cochlea, a small sharp gouge is used, the labyrinthine wall of the tympanum being removed in a forward direction until the carotid eminence is reached. The remainder of the cochlea is situated further forward and is much more deeply placed. To expose it, the bone is chipped away in a downward and forward direction, as its apex forms the most prominent part of the anterior inner surface of the tympanum, being situated internally to the orifice of the auditory tube and just above and behind the knee of the internal carotid canal.

West and Scott also advise that the cochlea should be opened at its lateral and posterior surface, but that the lower and lateral part of the cochlear capsule should not be interfered with. Great care must be observed not to fracture the modiolus, as, if this be done, infection of the meninges may occur.

If it be necessary to remove the ridge of bone carrying the facial nerve, Richardson shaves down the roof of the Fallopian canal by means of a curette with a cutting edge, in the direction from above downwards parallel to the course of the nerve. When the nerve is exposed, it is gently raised from its bed and the portion of the bridge lying between the vestibule and fenestra vestibuli is then removed.

Neumann's operation. Neumann's operation deserves special mention, as it is specially designed as an operation of emergency in order to expose the posterior surface of the petrous bone as far forward as the internal acoustic meatus, especially in those cases in which a localised meningitis of the posterior fossa or a cerebellar abscess has been diagnosed.

The complete mastoid operation is performed. The transverse sinus is exposed, the triangular area of bone situated between it and the tegmen tympani and roof of the middle fossa being removed so as to expose the dura mater of the posterior fossa between the transverse sinus behind and the semicircular ducts in front. The posterior surface of the petrous bone is then gradually cut away by means of a chisel or

ge in a forward direction until the posterior semicircular duct is osed. The duct may first be recognized as a short vertical tunnel. he bone is cut through, two small circular openings will be seen, esenting cross-sections of its upper and lower limits. The posterior ient of the lateral semicircular duct is then exposed and its lumen ed. The bone is still further removed in a forward direction parallel e anterior wall of the posterior fossa, until the vestibule is reached. dura is carefully separated from the petrous bone by means of a osteal elevator. In doing so it is very easy to tear the dura mater, h at this point is very adherent to the bone. A guide to the vestibule be obtained by passing a fine probe through the posterior limb of the al semicircular duct, which, during the operation, is seen midway een the two openings of the posterior duct. The vestibule can also ened, as described in superior vestibulotomy, namely, at the junction ie lateral and superior semicircular ducts. Neumann removes the ous bone until he has reached the posterior wall of the internal stic meatus and has actually exposed the facial and acoustic nerves. operators are not so bold. The operation is completed by perform- nferior vestibulotomy to act as a counter drainage.

The chief advantage of this method, as already stated, is the exposure e dura mater and posterior fossa. In this way an extradural abscess be discovered; if there be symptoms of localised meningitis, the mater can be incised; or if a cerebellar abscess has been diagnosed, esult of the internal-ear suppuration, the brain may be explored at oint (see p. 505).

Whatever operation has been performed, the medial wall of the vesti- and cochlea should always be carefully examined in order to see if ous is exuding through a fistula from the intracranial cavity. If so, eans that in addition to the labyrinthine suppuration there is an dural abscess of the posterior intracranial fossa, drainage of which sential in order to obtain a complete recovery.

After the operation has been completed, the cavity should be filled hydrogen peroxide and then gently syringed out with weak biniodide ion, finally dried, and lightly packed with sterilized gauze.

After-treatment. If the suppuration has been limited to the nal ear, a successful result may be expected if the symptoms subside ly as a result of the operation. If there has been complete destruc- of the labyrinth before operation, its performance should give rise symptoms of shock nor further disturbance of equilibrium.

n the majority of cases, however, owing to the nerve-terminals being n a state of activity, the irritation set up as a result of the operation cause increased attacks of nystagmus, vertigo, and vomiting. The

vomiting is the first symptom to disappear, and then the nystagmus; but complete recovery of equilibrium may not occur for a considerable period, during which time the patient, though otherwise well, may still have a slightly staggering gait.

If the operation has been limited to the lateral semicircular duct, and the hearing power still exists, the after-treatment should be carried out as already described in the complete mastoid operation. If, on the other hand, the cochlea has been interfered with, or if it be certain that there is no longer any hearing power, then there is no object in trying to preserve the patency of the tympanum, which in this case may be allowed to granulate up from its depth like an ordinary surgical wound.

The immediate anxiety of the surgeon after the operation is the possible onset of meningitis or the presence of a cerebellar abscess, which will necessitate further operation unless otherwise contra-indicated.

Comparison of the operations. The operation of *double vestibulotomy* as described by West and Scott can be accepted as the standard operation for internal-ear suppuration.

Jansen's operation, limited to the labyrinthine vestibule, is no longer generally practised, as it is considered that there is greater risk to the patient's life if the inferior portion of the vestibule and cochlea is not also drained.

Richards's operation is the most complete but the most difficult to perform. It is only indicated in the chronic mild forms of suppuration and in non-suppurative cases where an attempt is being made to cure tinnitus and vertigo by complete extirpation of the labyrinth.

Neumann's operation is most suitable for urgent cases, especially if an extra- or intra-dural lesion of the posterior fossa be suspected, but if no such lesion exists, an increased risk of causing meningitis is thereby incurred.

Intracranial complications. If, in addition to the labyrinthine suppuration, intracranial suppuration be suspected, the labyrinth should first be explored; but when possible the operation should be arrested at this point to see if the symptoms subside. If they continue, the exploration of the intracranial cavity can then take place through the internal ear, after a delay of twenty-four hours or more.

Of the intracranial complications, meningitis is most frequent, and next in order cerebellar abscess. In addition, thrombosis of the bulb of the jugular vein may take place from infection through one of the smaller tributary veins; or a localised extradural abscess may be found situated along the posterior portion of the petrous bone in consequence of direct extension of the infection through the internal acoustic meatus, or as

a result of empyema of the endolymphatic sac. This latter condition is almost impossible to diagnose, but may be discovered accidentally if the vestibule is opened by the posterior route according to Neumann's method.

Difficulties. The chief difficulties are anatomical, and the inability to obtain a clear view owing to general oozing of blood.

The first is generally due to insufficient removal of bone; the second can usually be controlled by means of good assistants and the frequent employment of hydrogen peroxide or of adrenalin solution.

Dangers. *Injury to the facial nerve.* This, as might be expected, is not infrequent. If a burr be used, the nerve may be completely torn across and permanent paralysis may result. If, however, the gouge and mallet be employed, complete recovery usually takes place, as the injury seldom consists in complete destruction of the nerve.

Opening up of the internal meatus. This may be accompanied by a gush of cerebro-spinal fluid. There is nothing to be done except to try and keep the part as clean as possible and see that there is free drainage. Undoubtedly, as a result of this mishap, death has afterwards occurred in consequence of septic meningitis.

Injury to the internal carotid or bulb of the jugular vein. These are possibilities which, however, should not occur if ordinary care is taken.

Prognosis. The prognosis of labyrinthine suppuration is always grave, owing to the frequency of intracranial complications.

The most favourable cases are those in which the disease is localised and is of chronic duration. The most unfavourable are those in which acute suppurative labyrinthitis is accompanied by extensive bone disease.

The mortality, in cases not operated upon, is very high; but as a result of operation, and owing to increased knowledge and improved technique, the mortality has been reduced to less than 10 per cent. In the majority of cases the ultimate fatal result cannot be put down to the operation itself, as the patient is frequently seen too late—that is, after intracranial complications have already occurred. There is no doubt that the death-rate will diminish proportionately according as the necessity of operating early becomes more and more recognized.

With regard to hearing, extensive operations upon the labyrinth lead to complete deafness; nor, indeed, can recovery of hearing be expected except in those cases in which the disease and operations have been limited to a localised lesion of the semicircular ducts, and even then recovery of hearing is exceptional, if the membranous canal is affected.

INTRACRANIAL DIVISION OF THE ACOUSTIC NERVE

Wallace and Marriage[1] first reported such a case, operated on to relieve tinnitus and vertigo, but the patient died three weeks later.

Lake[2] quotes eight cases, by various surgeons, in which there were two successful results, three failures, and three deaths.

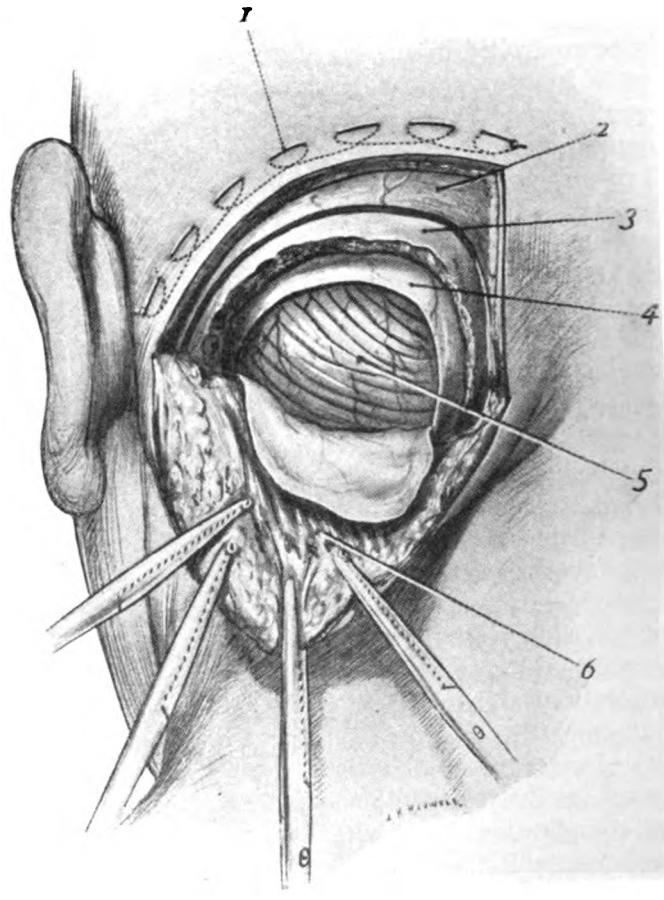

FIG. 229. INTRACRANIAL DIVISION OF THE ACOUSTIC NERVE. *First stage of operation.* Showing exposure of left lobe of cerebellum. 1, Continuous overlapping silk suture; 2, Pericranium; 3, Bone; 4, Dura mater; 5, Cerebellum; 6, Musculo-cutaneous flap. (After Chas. H. Frazier.)

Recently Frazier,[3] of America, has again suggested this procedure as a means of relieving aural vertigo. The operation, however, is so severe, and the risk of facial paralysis or meningitis is so great, that it is doubt-

[1] *Lancet*, i. 1907. [2] *B. M. J.*, October 16, 1909.
[3] *Surgery, Gynæcology, and Obstetrics*, November 1912.

ful whether it will ever be accepted as being justifiable. Personally, I have never performed this operation, but the procedure according to Frazier is as follows:

The patient lies in the prone position with the head flexed, the body and shoulders elevated to an angle of 45°. The incision is that for a unilateral occipital craniectomy. If there is much hæmorrhage from the scalp, this can be controlled by a continuous overlapping skin suture introduced half an inch above the line of incision. The bone is removed so as to expose the cerebellar hemisphere on the affected side. After

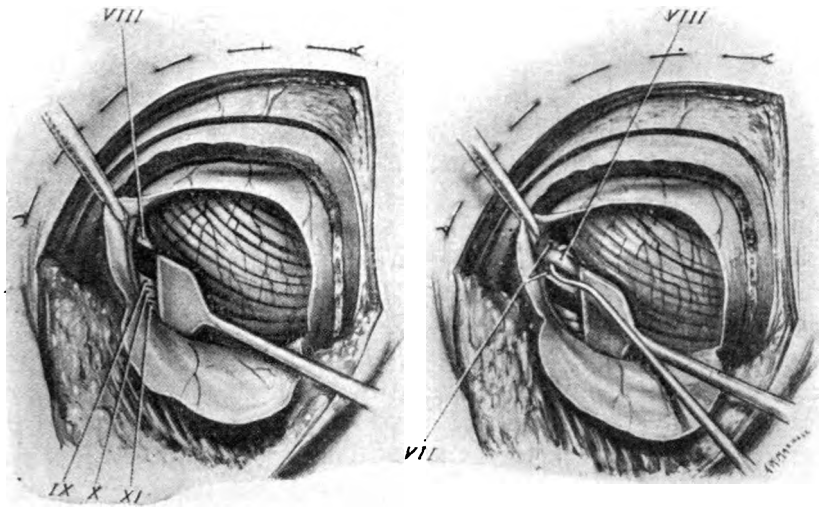

A B

FIG. 230. INTRACRANIAL DIVISION OF THE ACOUSTIC NERVE. A. *Second stage of operation.* The cerebellum is retracted, exposing the acoustic nerve at the entrance of the internal acoustic meatus, the IXth, Xth, and XIth nerves lying somewhat posteriorly. B. *Third stage of operation.* The acoustic nerve (VIII) has been separated from the facial nerve (VII) by means of a blunt hook. (After Chas. H. Frazier.)

hæmorrhage has been arrested, the dural flap is turned down (Fig. 229). The cerebellar lobe is gently retracted, caution being taken to prevent pressure on the medulla or pons, until the internal acoustic meatus is reached and the acoustic nerve exposed. The difficulties of the operation are to retract the cerebellum sufficiently, and to identify the acoustic nerve from the facial nerve which it surrounds. Frazier teases away the acoustic nerve until the facial comes into view, which is then identified by applying the galvanic current (Fig. 230). After the facial nerve has been identified, the acoustic nerve is divided. The dura-mater flap is then closed by means of sutures, as well as the skin incision, a small drain being inserted through an opening in the flap.

CHAPTER VIII

OPERATIONS FOR EXTRADURAL ABSCESS AND MENINGITIS OF OTITIC ORIGIN

ON INTRACRANIAL COMPLICATIONS IN GENERAL

As the intracranial complications of otitic origin are due to direct extension of the pyogenic infection through the temporal bone to the cranial cavity, it follows that they will depend on the extent of the disease within the temporal bone, the direction in which it has spread, and the virulence of the infection. For this reason, also, the site of the intracranial lesion is always in close relationship with the area of the diseased bone. Thus, if the infection spreads upwards through the attic and tegmen tympani, it may lead to extradural abscess or to meningitis of the middle fossa, or to a temporo-sphenoidal abscess. Similarly, disease of the mastoid cells posteriorly may give rise to an abscess round the transverse sinus, to meningitis of the outer surface of the posterior fossa, to transverse sinus thrombosis, or to a cerebellar abscess situated superficially and involving the outer portion of its lateral lobe just behind the transverse sinus; or caries of the floor of the tympanum may give rise to thrombosis of the jugular bulb; or internal-ear suppuration to an extradural abscess occupying the posterior surface of the petrous bone, to meningitis of the posterior fossa, or to an abscess of the cerebellum deeply placed in its anterior inferior angle.

Operation is always imperative unless the patient is seen too late and it is obvious that the condition is hopeless.

Before operation is decided on the following points must be carefully considered: (1) Is it possible that the symptoms simulating the intracranial lesion are due to suppuration still limited to the temporal bone? (2) What is the character of the lesion? and (3) What is its situation?

As a rule, so long as the suppurative process is limited to the middle ear and to the mastoid region, the symptoms are those of a local septic infection. At the same time it must be remembered that in infants and in young children it is not uncommon for retention of pus within the middle ear to produce a clinical picture closely simulating an intracranial suppurative lesion. The ear, therefore, should always be inspected in every case. Sometimes a bulging membrane is discovered, or the exist-

ing perforation is found to be insufficient for drainage. In such cases the symptoms may subside on free drainage being obtained by the simple act of paracentesis of the tympanic membrane.

If, however, free drainage already exists, the mastoid operation should be performed at once.

If the intracranial symptoms be still somewhat indefinite, and there is no apparent urgency, the intracranial cavity should not be explored immediately, unless this is found to be imperative at the time of operation. This can be done later, if the symptoms do not subside.

Although exploration of the intracranial cavity is always urgent when it is certain that an intracranial suppurative lesion is present, it is a grave misfortune to explore with a negative result, owing to the possibility of infecting the cranial cavity.

Although the surgeon may be certain that an intracranial lesion is present, it may be very difficult to determine its character or whether several lesions coexist, and he must therefore be prepared to act according to what he finds at the time of operation.

Thus, if exploration of the temporo-sphenoidal lobe be negative, and the cardinal symptoms point to an intracranial abscess, the cerebellum must also be explored. Again, if the diagnosis of intracranial abscess be doubtful before operation, and if, during the operation, lateral sinus thrombosis be discovered, it is wiser to limit the operation to tying of the jugular vein and removal of the septic thrombus. The bone, however, should be removed above and behind the sinus so as to expose the dura mater covering the temporo-sphenoidal lobe and the cerebellum.

In such cases, if the symptoms of intracranial suppuration still continue, it is an easy matter to explore the temporo-sphenoidal lobe or cerebellum at a subsequent operation.

Although under exceptional circumstances (see p. 499) it may be justifiable to open an intracranial abscess by trephining the skull over it, free opening of the mastoid process should be the first step in the operation, as the primary focus of the disease exists within the temporal bone. In addition, much information may thus be gained in a doubtful case with regard to the situation of the intracranial lesion.

OPERATIONS FOR EXTRADURAL ABSCESS

This is far more common as a sequel of acute than of chronic disease of the mastoid process.

Indications. Operative interference is indicated in order to permit of drainage. An extradural abscess is frequently discovered accidentally, especially if the surgeon follows out the golden rule to trace any patch

of carious bone to its limit. In doing so he may suddenly meet with a gush of purulent discharge coming through an opening in the bone in the region of the tegmen tympani or sigmoid sulcus.

Although an extradural abscess may give rise to no special symptoms, the following are suggestive:

1. If, in spite of opening up the mastoid cells and tympanic antrum, pyrexia and headache persist, especially if the headache be localised to the affected side and accompanied by tenderness on pressure above the ear or behind the mastoid process.

2. If, before operation, there be a very profuse discharge from the ear, apparently too copious to come from the tympanic cavity or mastoid antrum.

3. In children, an extradural abscess may give rise to symptoms of cerebral irritation or compression if it extends upwards from the tegmen tympani along the parietal region; or, if situated in the posterior fossa, to retraction and stiffness of the neck.

Although such symptoms may also be associated with an intracranial abscess or meningitis, yet, if on exploration of the intracranial cavity a large extradural abscess be discovered, further operation may be postponed (unless its extension is obviously necessary) until time is given to see whether the symptoms will subside or not.

Operation. If the mastoid process has not been opened already, the simple or the complete operation is performed, according to whether the suppuration is recent and acute, or is of long standing.

If, however, this has been done, the wound is reopened, all granulations being curetted away, and the cavity cleansed and dried.

The tympanic antrum and mastoid cavity are then thoroughly examined. If a fistula in the bone already communicates with the abscess, pus may be seen to ooze through it. If not, careful search is made for any carious tract of bone, which is now followed up until the dura mater is reached.

After the pus has drained away, more bone is removed so as to expose the dura mater fully over the infected area, which is usually vascular or covered with granulations. The latter, however, should be left severely alone. If the abscess be situated in the middle fossa above the tegmen tympani, the bone is best removed by chiselling upwards until the lower margin of the squamous portion of the temporal bone is reached. Then, with a pair of bone forceps, more bone can be punched away until a sufficient opening is obtained (Fig. 231).

Exploring with the probe and curetting away of granulations should be avoided as far as possible for fear of injuring the sinus. If its wall be already inflamed, it may be torn through, and the resulting hæmorrhage

may render the further steps of the operation a matter of extreme difficulty.

Before completion of the operation, a blunt-pointed seeker should be passed round the edge of the opening in the bone to see that its margin is smooth and even, and all sharp edges of bone bordering on the dura mater should be removed. If this precaution be neglected, a splinter may get pressed inwards and injure the dura mater, and thus set up meningitis.

If possible the bone should be removed until the healthy dura mater is reached. If the extent of the abscess prohibits this, its limits, however, should be ascertained. This can be done by pressing the dura mater inwards with a spatula so as to separate it from the overlying bone.

The final step is to irrigate the cavity with warm boric or saline solution and to insert drains of gauze or of fine india-rubber tubing between the dura mater and bone. The wound cavity is then lightly packed with gauze and a simple dry dressing applied.

After-treatment. Provided there be no other intracranial symptoms, recovery should be as rapid as in the case of simple inflammation of the mastoid process. In the after-dressings, however, special care should be taken not to press in the gauze roughly or tightly against the still inflamed dura mater, in case of injuring its surface and causing further extension of the pyogenic infection to the meninges or lateral sinus. The dressings should be changed daily. It is sufficient to irrigate the wound with some mild aseptic lotion and afterwards to repack it lightly. If Schwartze's operation has been performed, the after-treatment is similar to that already described (see p. 436). In the case of the complete operation, after the purulent discharge has ceased and the surface of the wound appears healthy, the packing of the cavity may be carried out through the meatus, instead of through the posterior wound, the latter being then allowed to close.

Intracranial complications. Infection of the transverse sinus is the most frequent complication, but meningitis, ulceration of the surface of the brain, or intracranial abscess may also occur.

One or more of these complications may already exist at the time of operation, but may not be sufficiently marked to warrant further exploration of the intracranial cavity. It is wiser, therefore, to give a guarded prognosis during the first few days after the operation, not only with regard to recovery, but also to the possibility of further operative procedures becoming necessary.

MENINGITIS OF OTITIC ORIGIN

Formerly the onset of symptoms of meningitis was a distinct contra-indication to operation, but recently this view has become modified. as it has been shown definitely that recovery is possible if operation be undertaken sufficiently early, before the inflammation of the meninges has become diffuse.

Although pachymeningitis externa (inflammation of the extradural surface of the dura mater) is sometimes included under the term meningitis, it is better considered as an early stage of an extradural abscess, the term meningitis being then confined to intradural inflammation of the meninges.

Different types of meningitis, or, more correctly speaking, lepto-meningitis, may occur, but with regard to otitic meningitis only two varieties need be mentioned: (1) *serous meningitis* and (2) *purulent meningitis*, which may be circumscribed or diffuse. In addition, the term pseudo-meningitis may be applied to those cases which simulate meningitis but in which the symptoms are really due to irritation of the meninges, the result of suppuration still confined within the temporal bone, especially seen in infants. Clinically, it is often difficult to determine before operation which variety is the cause of the symptoms. Serous meningitis can usually only be diagnosed by the complete recovery of the patient, although it may be inferred by the symptoms being less severe than those in diffuse purulent meningitis.

OPERATIONS FOR MENINGITIS OF OTITIC ORIGIN

Indications. Operation is indicated as soon as the onset of meningitis is diagnosed, and should be performed without delay; expectant treatment, until all the cardinal symptoms have occurred, will never save life. The only possibility of recovery is to operate whilst the inflammatory process is still localised. Every effort, therefore, should be made to diagnose these cases as early as possible and to take advantage of all known clinical and bacteriological tests which recent research has shown to be of considerable value.

Lumbar puncture. This should always be performed. If the cerebro-spinal fluid be clear and sterile, diffuse meningitis can usually be excluded, although at the same time it must be remembered that it does not negative a localised meningitis without increase of intracranial pressure. An increased flow of cerebro-spinal fluid indicates increase of intracranial pressure, perhaps the result of serous meningitis. Slight turbidity suggests early purulent meningitis, which is confirmed if bac-

teria are present, but does not necessarily mean that the case is hopeless. If the fluid be definitely purulent, the condition is practically always hopeless, although cases have been recorded in which recovery has taken place.

Lumbar puncture, also, is a sound therapeutic measure in order to relieve increased intracranial pressure.

With regard to cytological examination of the fluid, as a rule, increase of the polynuclear cells is in proportion to the severity of the acute inflammation, whereas a decreased number of the polynuclear cells may be taken as a sign of diminution of the meningeal irritation; with this, an increase of the lymphocytes may be looked upon as a hopeful sign of eventual recovery.

Another test is the amount of albumen present; normally the cerebro-spinal fluid contains only a trace, but with the onset of meningitis the quantity is greatly increased.

Kopetzky's Test. The normal cerebro-spinal fluid is slightly alkaline and contains a carbohydrate, a glucose, which has the power of reducing the copper in Fehling's solution. Kopetzky,[1] who has done very valuable work in examination of cerebro-spinal fluid at all stages of meningitis, has shown that the power to reduce Fehling's solution is diminished as inflammation of the meninges takes place and increases. In the examination of thirteen cases he found that the absence of copper reduction was always obtained long before the bacterial cultures or smear preparations gave information of value, and so concludes that the evidence seems to justify the belief that there is always present in the cerebro-spinal fluid a carbohydrate, which at the onset of bacterial infection is utilized by the microbes as a food, and that it disappears from the spinal fluid early in the disease to reappear later simultaneously with a falling off in the numbers or with the disappearance of the micro-organisms. In this test, therefore, we have one of the earliest and most reliable signs of meningitis and later a reliable test to afford information as to the progression and retrogression of the meninges.

Alkalinity test. Araki and Ziellesen[2] have proved experimentally that lactic acid and other acids are reproduced in the tissues themselves, in conditions associated with lack of oxygen. Kopetzky[3] quotes thirty-six cases in which the cerebro-spinal fluid was alkaline or amphoteric if obtained from cases which were normal as regards the meninges, whereas in cases of meningitis and other diseases giving bulbar symptoms similar to pressure symptoms, the cerebro-spinal fluid gave an acid reaction of varying degree.

[1] *Trans. American Laryng., Rhin., and Otol. Soc.*, p. 153, 1912.
[2] *Zeit. für Phys. Chem.*, No. 15, 1891.
[3] *Trans. American Laryng., Rhin., and Otol. Soc.*, p. 138, 1912.

Blood-pressure test. Harvey Cushing proved experimentally that as the intracranial pressure increased, the blood-pressure was similarly raised, and, as a further result of intracranial pressure, cerebral anæmia eventually paralysed the various nerve centres. A rising arterial blood-pressure, being indicative of increased intracranial pressure caused by the increased secretion of the cerebro-spinal fluid, may therefore (in conjunction with other symptoms and tests) afford one of the first indications of meningeal infection.

Operation. Although no set operation can be described, the principles of the operation are to remove the primary focus, to establish free drainage of the meninges, and to relieve intracranial pressure by means of a decompression operation. The extent of the operation will therefore depend largely on what is found during the course of the operation itself.

1. In an infant or young child, if the symptoms develop in the course of an acute otitis media, the tympanic membrane should first be inspected to see if there is sufficient drainage. If not, it should be freely incised, and opening of the antrum and mastoid may be delayed for at least twelve hours.

2. In an adult, immediate exploration of the mastoid and tympanic antrum is indicated at the onset of meningeal symptoms, even although they occur during the course of an *acute* middle-ear suppuration.

If the symptoms of meningitis are as yet indefinite, and if pus is found under tension within the mastoid cavity, or if an extradural abscess exists, the dura mater should not be incised at once, but a delay of twenty-four hours should be advised; in many cases complete recovery will take place. If, however, the symptoms continue, intracranial exploration is indicated.

3. In chronic middle-ear suppuration, meningitis is usually secondary to, or accompanies, other intracranial complications or internal-ear suppuration, the symptoms of which it may mask.

After performing the mastoid operation any tract of carious bone is followed out to its limits.

According as to what he finds, the surgeon may first expose the dura mater covering the lower portion of the middle fossa (Fig. 231), or the posterior fossa behind and in front of the transverse sinus; these are the usual sites of infection. The removal of bone must be free, in order to get well beyond the limits of the infected area, if this be possible. The dura mater is incised to the limits of its exposure either crucially or by cutting it through in the form of a large flap.

The dura mater is usually congested, but if an extradural abscess or

lateral sinus thrombosis is present, it may be thickened and of a leathery appearance; or in the latter case almost gangrenous.

The further steps depend on the conditions met with on incision of the dura mater.

1. *In serous meningitis* a certain amount of clear fluid may escape and the brain surface may be only slightly congested. After removal of the bone and of the dura mater over the infected area, the surface of the brain should be scarified in various directions to make certain that the pia-arachnoid has been incised, and fine drainage tubes should be

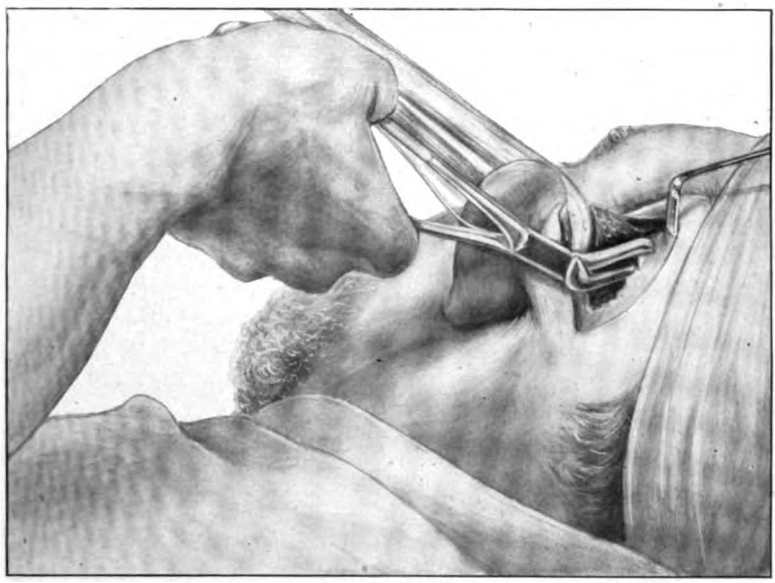

FIG. 231. METHOD OF REMOVAL OF BONE BY THE FORCEPS. In this instance the bone is being removed above the tegmen tympani in order to expose the lower portion of the middle fossa.

inserted between the latter and the dura mater. In these cases a hernia seldom occurs, although the brain surface may bulge slightly into the wound.

2. *In purulent meningitis* the surface of the brain is usually covered with a turbid fluid or purulent lymph, which may be localised to the site of the diseased bone, or may have spread from this point to a varying extent over its surface.

If the limit of the infection cannot be reached in spite of removal of a considerable extent of bone and dura mater, all that can be done is to irrigate the exposed area with warm saline solution and to insert

fine drainage tubes between the brain and dura mater, at the same time (as in the case of serous meningitis) incising the meninges in various directions.

3. *Purulent meningo-encephalitis.* If localised by adhesions an accumulation of pus may occur, forming an abscess on the surface of the brain, which also may be superficially ulcerated or necrosed. If there be intracranial pressure from encephalitis, the brain tissue usually protrudes as a dark, hæmorrhagic friable mass, in which shreds of necrotic brain tissue will be seen. In other cases, if there be no increased intracranial pressure and if the condition be quite localised, no hernia may occur, but the surface of the brain may be rough or eroded.

Any purulent secretion should be removed by irrigation, care being taken not to disturb the brain more than is necessary, so as to diminish the risk of breaking down the surrounding adhesions. A hernia may or may not form immediately. If no hernia takes place, it is wiser to do nothing further; that is, provided sufficient bone and dura mater have been removed to reach the limits of the infected area. Some authorities, however, consider that the necrosed portion of the brain should be curetted out. Although in other parts of the body the removal of necrosed tissue is a proper procedure, yet in the case of the brain there is considerable risk of setting up further œdema or septic cerebritis, the progress of which may have become arrested at the time of the operation.

If the inflamed brain tissue protrudes to an excessive degree during the operation itself, the opening in the skull should be enlarged, if it be not already of considerable magnitude, and the dura mater incised to the full limits of the opening. The protruding mass may then be cleanly excised by means of a scalpel. If, however, the brain tissue continues to prolapse, the wound cavity should be simply cleansed and protected by a dressing of sterilized gauze. If the encephalitis subsides, the hernia will not increase in size, and if the wound cavity be kept aseptic, it will gradually shrink.

After-treatment. This consists in covering the wound surface lightly with gauze so as to permit of free drainage, and changing the dressing as often as may be necessary.

In serous meningitis a large quantity of cerebro-spinal fluid may escape, in which case the dressings must be changed frequently. If recovery be going to take place, the temperature will gradually become normal and the symptoms of meningitis disappear. In involvement of the posterior fossa, the head retraction gradually diminishes and after a few days free movement is noticed. Adhesions form rapidly, binding together the surface of the brain, meninges, and the overlying bone.

For this reason the drainage tubes, already inserted between the dura mater and brain, can be removed within a day or two. The exposed dura mater usually becomes covered with granulations from which a certain amount of purulent discharge may be secreted. The duration of the after-treatment depends on the extent of the operation and the size of the wound. Eventually the skin flaps grow together and cover the brain, which afterwards may be felt pulsating through the scar. In these cases it is usually necessary to provide the patient with some protection, such as an aluminium plate.

If, however, a hernia forms and gradually increases in size, the brain should be explored again to see if another abscess can be discovered; or the lateral ventricle itself may be tapped in case of it being distended with fluid. Both these operations, however, must be looked upon as extreme measures.

If the patient otherwise recovers and a hernia still persists, the question arises what to do. Conservative treatment should first be employed, aseptic dressings being maintained, and slight pressure applied with compresses soaked in rectified spirit. If these measures fail, then the projecting portion of the hernia may be excised.

Although too much reliance cannot be placed on the treatment by vaccines, yet if a micro-organism is found in the cerebro-spinal fluid, an autogenous vaccine should be prepared and given. I have also given intravenous injections of urotropine—30 to 40 grains in 10 ounces of normal saline solution. It also can be given, as originally proposed by Harvey Cushing, as an intraspinal injection. A lumbar puncture is first performed and 40 c.c. of cerebro-spinal fluid allowed to escape. The syringe containing the urotropine solution is then attached to the hollow needle and slowly injected into the vertebral canal. This may be repeated once or twice daily. I have not personally performed this intraspinal injection, but in more than one case of encephalitis following a localised leptomeningitis secondary to intracranial operations, especially in association with transverse sinus thrombosis, I have certainly seen good results follow intravenous injection; but whether *post hoc* or *propter hoc* it is always difficult to say.

Other methods of surgical treatment. In the attempt to diminish the terrible fatality of meningitis, many operations have been attempted, and although few recoveries have been made in proportion to the failures, they demonstrate the possibility that something can be done and that considerable advance has been made in recent years in this direction.

(i) **Repeated Lumbar puncture.** As a therapeutic measure it can only be of value to diminish intracranial tension, and then only if free

communication still exists between the spinal theca and the subarachnoid space.

In diffuse purulent meningitis it is impossible by this means to bring about a cure. In addition it must be remembered that a certain amount of danger is attached to repeated punctures owing to a too great withdrawal of the fluid, and fatal results have already occurred as a result of this procedure.

(ii) **Continuous drainage through the vertebral canal.** This has been suggested by Friedrich, of Kiel, by means of a laminectomy in order to permit of drainage of the entire dural sac. It cannot, however, be recommended.

(iii) **Puncture of the lateral ventricle.** The temporo-sphenoidal lobe is pierced with a trocar, just above the zygomatic ridge, until the ventricle is reached; this has been performed frequently in order to relieve intracranial pressure. I know of only one recorded instance in which recovery has taken place in spite of there being pyogenic infection of the lateral ventricle—a fact which was proved by tapping the ventricle and removing from it a drachm and a half of purulent fluid.[1]

(iv) **Drainage of the internal ear.** West and Scott have suggested this method. In a case of meningitis which occurred after the labyrinthine wall of the tympanum had been curetted, they opened up the labyrinth and inserted a wire drain through the internal acoustic meatus, at the same time making a counter opening in the lumbar region through which they drained the vertebral canal. The patient, a child, ultimately recovered. The risks, however, of this operation are so great as to make it doubtful of being accepted as a practical procedure. The risk of further infecting the cerebro-spinal fluid is too great.

(v) **Drainage of the cisterna magna by the suboccipital route.** This operation is undertaken in order to diminish the intracranial pressure. Charles Ballance was the first to attempt it in 1891. He trephined the occipital bone on both sides just above the foramen magnum. Since then drainage of the subarachnoid cavity has been carried out by various surgeons, recovery taking place in a few instances.

Recently Haynes[2] has described a method by which to reach the cisterna magna by an easier and more direct route. The chief feature of his operation is removal of the bone in the median plane down to the foramen magnum itself. This is to obviate the risk of a cerebellar hernia or of blocking of the foramen magnum by downward displacement of the brain after removal of the fluid through an opening in the bone situated laterally.

[1] *Archives of Otology*, vol. xxxv, p. 535.
[2] *Trans. American Laryng., Rhin., and Otol. Soc.*, 1912.

Technique of Haynes's operation. The patient is placed in the prone position with the head leaning well over the table. After shaving the scalp, the incision is made in the mid-line from above downward from the occipital protuberance, to the spinal process of the axis. The periosteum is stripped from the bone, taking with it the origin of the attached muscles, the occipital bone being exposed for about 1½ to 2 inches vertically and 1 inch transversely right down to the foramen magnum. After retracting the soft tissues, a ⅝ trephine is applied in the mid-line, an inch above the margin of the foramen magnum. On removal of the disk of bone, dural separators are inserted so as to separate the dura mater from the bone between the trephine opening and the foramen magnum. A wedge-shaped piece of bone occupying the position

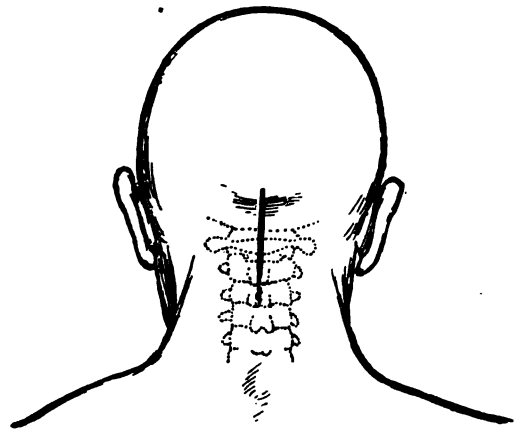

FIG. 232. HAYNES'S OPERATION. *The Position of the Skin Incision.*

between the outer margins of the trephine opening and the foramen magnum is now removed by cutting through the bone with a De Vilbiss' bone-cutter, along two linear incisions beginning at the outer margin of the trephine opening and extending down into the foramen magnum (Fig. 233). The occipital sinus, either single or double, can now be seen through the dura mater. If double, the dura mater is incised between them; if single, it should be tied just above its point of bifurcation. Only a very small incision should first be made in the dura mater, because if the arachnoid is adherent it will be cut through at the same time and the cerebro-spinal fluid will escape. By making a very small opening this can be controlled (a necessary precaution) (Fig. 234). If, however, the arachnoid can be separated from the dura mater without puncturing it, the dura is then slit up along the length of the wound from above downwards. A small incision is now made in the arachnoid

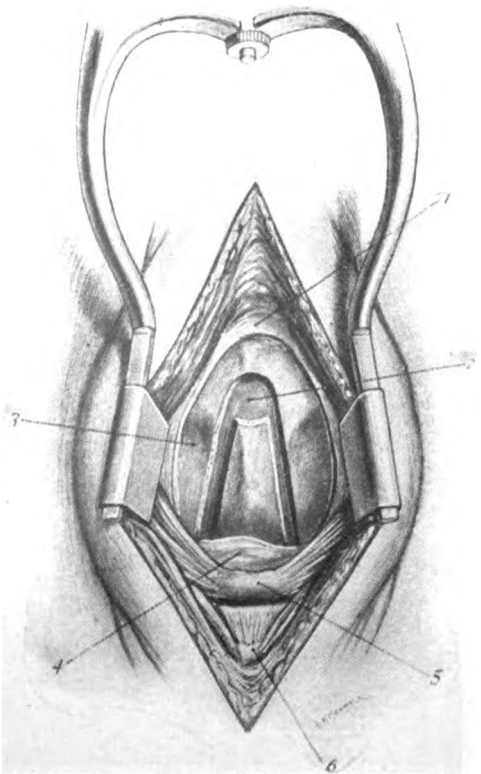

FIG. 233. HAYNES'S OPERATION. *The Trephine Opening, and the Grooves cut into the Foramen Magnum.* 1, Pericranium; 2, Dura mater; 3, Occipital bone; 4, Atlanto-occipital ligament; 5, Atlas; 6, Axis. (After Haynes.)

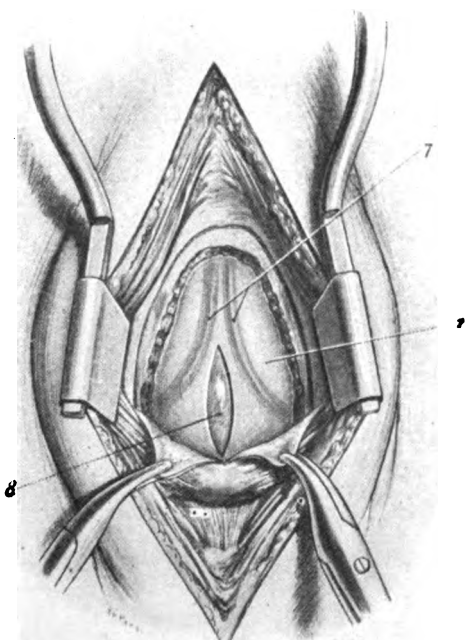

FIG. 234. HAYNES'S OPERATION. *The Incision through the Dura Mater, with exposure of the Arachnoid.* 2, Dura mater; 7, Occipital sinus; 8, Arachnoid. (After Haynes.)

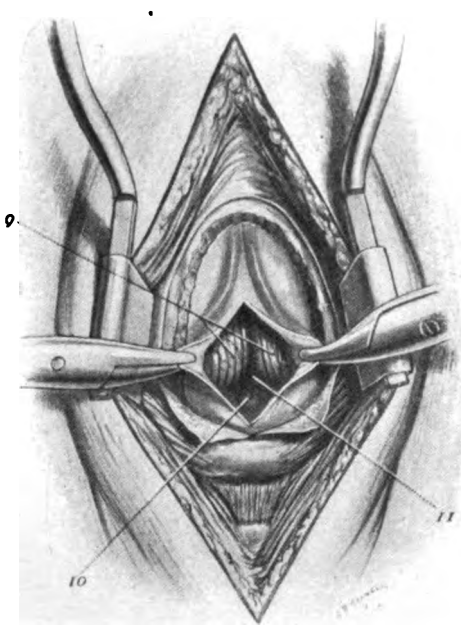

FIG. 235. HAYNES'S OPERATION. *Completion of the Operation;* the Arachnoid has been divided, and the Cisterna Magna opened. 9, Lobes of cerebullum; 10, Medulla; 11, Cisterna magna. (After Haynes.)

bulges into the wound. The escape of the cerebro-spinal fluid is led by means of the finger. After the excess of fluid has escaped, chnoid is opened throughout the length of the wound. If neces- ıe lobes of the cerebellum should be raised in order to inspect the n of Magendie, the opening through the occipital bone being d if required (Fig. 235). A small drain of rubber tissue is now within the margins of the dura and arachnoid and allowed to pro- rom the wound. The muscles are lightly sutured together and the cision closed at the upper and lower margins of the wound. ive dressings are applied, as much cerebro-spinal fluid may escape. er the operation, care must be taken to keep the patient in a re- ıt position; all movement should be avoided.

e advantages of the operation are that the cisterna magna is opened nost favourable spot and that the foramen Magendie can be in- ; also protrusion of the cerebellum into the opening and blocking flow of cerebro-spinal fluid is prevented, which is one of the chief ıntages in the other methods of reaching the subarachnoid space. r, owing to the incision being made in the mid-line, the hæmor- ıs comparatively slight. Lastly, the operation can be performed .

ynes quotes four cases. The operation was only performed as a esort, three of them being in the last stages of septic meningitis. gh they all died, the result of the operation was to remove the anial pressure and to relieve the most distressing symptoms. If procedure were adopted in suitable cases at an earlier stage, s considers there is no reason why a successful result should not ined.

ognosis and after-results. Unless saved by operation, itis is almost uniformly fatal. Even if the patient recovers, r as the result of operation or not, deaf-mutism or mental de- frequently occurs. In a few cases, however, complete recovery en place.

CHAPTER IX

OPERATIONS FOR TRANSVERSE SINUS THROMBOSIS OF OTITIC ORIGIN

GENERAL CONSIDERATIONS

THE sigmoid portion of the transverse sinus is the part usually infected. Thrombosis, however, may occur primarily in the region of the jugular bulb from direct extension of the pyogenic infection through the floor of the tympanum; this, though less frequent than involvement of the sigmoid sinus, is not so rare as has hitherto been supposed.

Operative treatment is imperative as soon as septic thrombosis of the sinus has been diagnosed, but this is not always an easy matter. Sometimes, indeed, there are no clinical symptoms, the condition only being discovered whilst performing the complete mastoid operation as a prophylactic measure. In such cases the sinus is generally exposed accidentally whilst following out a tract of carious bone, and pus or granulations may be seen to exude or protrude from an opening in its outer wall. On further exposure of the sinus on each side of the thrombus, the dura mater may appear to be of a dark colour for a short distance, but beyond this to be of normal appearance.

Seeing that there are no symptoms, the presumption is that the sinus is occluded on each side of the septic thrombus by a non-infective clot. It is, therefore, sufficient in such cases simply to excise the sinus wall over the septic area. If the case be so treated, it is essential that the sinus should only be curetted gently over the exposed opening, but otherwise left undisturbed. Also this limited operation should only be performed if the surgeon is satisfied that the septic focus is surrounded on each side by an organized normal clot—the condition, in fact, being treated as a simple abscess.

To secure free drainage, only the depth of the mastoid wound should be packed with gauze, the surface being protected by a simple dry dressing. The after-treatment is the same as that already described for the complete mastoid operation in which the posterior wound has been left open.

In other cases, if there be an acute inflammation of the mastoid process and if only one rigor has occurred, it may not necessarily mean

thrombosis of the sinus has taken place, as the rigor may simply be to septic absorption. In such cases it is justifiable to delay opening sinus if it is found exposed within the wound cavity and to be covered granulations.

The bone, however, should be freely removed until the normal dura er is reached, and the cavity afterwards rendered as aseptic as pos- by syringing it out with hydrogen peroxide lotion. In a large portion of cases a favourable result occurs, the pyrexia and head ptoms disappearing and an uneventful recovery taking place. On other hand, gradually increasing pyrexia or a sudden rigor may occur, haps not until *ten days* or so after the primary operation, showing that sinus has become infected after all. This possibility is not sufficiently gnized. It is, however, of importance, because if during the per- nance of the mastoid operation the transverse sinus has been exposed, occurrence of increasing pyrexia, even without a rigor, is almost ain evidence of the transverse sinus becoming infected. In my own erience of over sixty cases of transverse sinus thrombosis, in six cases ction occurred as the result of the mastoid operation; in two of which d myself performed the mastoid operation; in the other four, my col- ues. In the first of these cases, owing to not realizing this fact, ration on the transverse sinus was delayed until the occurrence of rs, and when performed the thrombosis was so extensive that the ent eventually died. In the other cases, owing to the jugular vein g at once ligated, the transverse sinus opened, and the septic clot re- ed, complete recovery took place.

In a typical case there is a history of repeated rigors, and in addition e may be attacks of vomiting, headache localised to the affected side, and tenderness on pressure behind the mastoid process, and optic itis. These symptoms, however, do not always exist; in many cases e are no external signs of mastoid disease at all: in others, slight erness over the mastoid process which can easily be overlooked. In e cases, typhoid fever may be suspected and treated accordingly, cially if the physician has no special knowledge of ear work. A defi- abscess over the mastoid process is an exception rather than the rule. Optic neuritis is an inconstant sign; out of thirty-three cases ex- ned I found it in nineteen—that is, over 50%. Sir Victor Horsley recently drawn attention to the fact that unilateral optic neuritis ts to an intracranial lesion on the same side; with this I agree. here be chronic middle-ear suppuration on both sides with no external s of mastoid inflammation, this clinical sign, if present, may be of e. Of these nineteen cases in which optic neuritis was present, it rred nine times on the affected side alone, twice in an uncomplicated

case of transverse sinus thrombosis, five times in meningitis, once with cavernous sinus thrombosis, and once with general pyæmia. In four cases it was more intense on the affected side; twice with no complications, once with transverse sinus thrombosis, and once with meningitis associated with a temporo-sphenoidal abscess. In no case was the optic neuritis on the sound side more intense than on the affected side.

In the more severe cases there may also be evidence of thrombosis of the jugular vein or cavernous sinus. On the other hand, there may be no definite symptoms, especially in children in whom an intermittent pyrexia may take the place of rigors.

As a further aid to diagnosis, examination of the blood for micro-organisms should be undertaken. The presence of bacteria in the blood definitely points to a septic infection of the blood-stream, and if there be a suppurative lesion of the middle ear, it may be assumed (unless some other cause can be definitely found) that the cause of the infection is due to disintegration of the clot in some part of the transverse sinus or jugular bulb, or of the sinus in connexion with the petrous bone.

Duel and Wright [1] state that after examination of the blood in fifty-seven cases of middle-ear suppuration, with and without complications, bacteria were found in nine cases of uncomplicated mastoid disease, all of which recovered after performing the complete mastoid operation.

My experience is to the contrary, as in all cases of uncomplicated mastoid suppuration in which the blood has been examined, it was found to be sterile.

The value of blood cultures as an aid to diagnosis fails in that so much time is wasted in obtaining the cultures. In every case of suspected transverse sinus thrombosis I always operate at once, and then act according to what I find on exposing the sinus.

In certain cases, however, when the symptoms are very definite—for instance, if a pyrexia occurs within a few days after performing the complete mastoid operation (in spite of the progress of the case being otherwise satisfactory)—the presence of bacteria in the blood will justify opening of the transverse sinus with ligation of the jugular vein.

The principles of surgical treatment are to expose the sinus and remove the infective clot completely.

In connexion with this operation two points cannot be impressed too forcibly on the reader:

1. The operation must be performed at once. The greater the experience of the surgeon the more he realizes that expectant treatment is nearly always fatal, and that a successful result depends largely on early and complete operative measures.

[1] *New York Medical Journal*, October 30, 1909.

Before the sinus is interfered with in any way it is essential to e its lumen below the thrombus in order to prevent any portion ng swept into the circulation during its removal.

EXPOSURE OF THE TRANSVERSE SINUS

ications. (i) In doubtful cases to decide whether thrombosis r not.

As a preliminary to opening the sinus with or without ligature of ular vein.

eration. The first step is to perform the complete mastoid on, except in the case of acute inflammation of the mastoid when Schwartze's operation will be sufficient.

expose the field of operation more freely, an incision of an inch or length is made horizontally backwards, beginning at the mid- f the posterior margin of the primary incision (Fig. 202), the ts being reflected upwards and downwards from the bone, and the formed being then retracted. Above, the bone should be exposed the level of Reid's base-line, which roughly corresponds to the the transverse sinus; below, the tip of the mastoid should be until the mastoid vein is reached. If it be thrombosed it may be d that the lower part of the transverse sinus is also thrombosed. g from the bone at this point may be arrested by temporarily g the foramen with a fragment of sterilized wax.

condition found on opening the mastoid process varies consider- If the result of acute inflammation of the mastoid process, the l cells surrounding the sigmoid sinus usually contain pus or tions, on removal of which a fistula may be seen to communicate e outer wall of this sinus; or the bone around the sigmoid groove ready be destroyed, with free exposure of the sinus within the With this there is frequently an extradural abscess. In other f the infective process has been very virulent, evil-smelling pus, nes intermixed with bubbles of gas, may escape on chiselling n the mastoid cortex. This is a sure sign of extensive disease, us wall often being gangrenous and the bone surrounding it d and discoloured.

ccurring in the course of a chronic middle-ear suppuration, very sease of the mastoid process may be found except along the path ch the infection has spread.

er the sinus wall has been reached, sufficient bone should be re- to expose its outer surface for at least half an inch above and he supposed infected area.

The decision as to whether thrombosis exists or not may have to be made during the operation itself, and is based partly on the appearance of the sinus wall and partly on the symptoms, the relative value of each varying in each individual case.

Normally the sinus pulsates and is of a bluish-grey colour. If thrombosed, the wall of the sinus may be of a yellow or dark colour and may not pulsate, but neither discoloration nor the absence of pulsation is an absolutely reliable sign of thrombosis. Again, if the sinus be covered with granulations or purulent lymph, it is sometimes impossible to say whether it is thrombosed or not, especially if the clot is limited and parietal. Further, the thrombus may be situated low down towards the jugular bulb, so that if it has not extended very far upwards the exposed portion of the transverse sinus may still be normal in appearance. Palpation of the sinus with the finger or aspiration with a hollow needle is sometimes advised as an aid to diagnosis. These procedures, however, are extremely unwise, owing to the risk of dislodging a small fragment of the infected clot, which may easily occur if the latter does not obliterate the sinus completely. As a means of diagnosis the withdrawal of blood by the aspirating needle is of no value, as it does not negative the presence of a partial thrombus, owing to the possibility of the needle passing through it into the free lumen of the sinus.

OPENING OF THE TRANSVERSE SINUS

Indications. The sinus should always be opened as soon as it is certain that septic thrombosis has occurred.

Contra-indications. The only contra-indication for opening the sinus and removing the thrombus is the certainty that either the patient's general condition will not permit of the operation being performed, or that the septic thrombosis has spread beyond the region from which it is possible to remove it.

For this reason, operation is unjustifiable if the patient is already suffering from septic pneumonia, pericarditis, or acute septicæmia; or, on the other hand, if there are symptoms of cavernous sinus thrombosis on both sides, or general meningitis. If, however, the patient's general condition be good, operation may be attempted as a last resource even although a pulmonary empyema or a one-sided cavernous sinus thrombosis already exists.

Operation. After exposure of the transverse sinus, the next point to determine is the site and extent of the infected area (Fig. 236). On this will depend whether it will be necessary or not to tie the jugular vein in the neck.

he sinus is first exposed towards the jugular fossa until its surface ars normal for at least half an inch. It is wiser, however, always pose the sinus as low down as possible. A strip of sterilized gauze en pressed in between the bone and the lateral wall of the sinus so obliterate its lumen at this spot. Instead of removing the bone above downwards, the sinus may first be exposed at its lowest by chiselling directly through the tip of the mastoid process. In way it can be obliterated by a strip of gauze before attacking the of infection. The overlying bone is afterwards removed from be- upwards until the thrombosed area is reached.

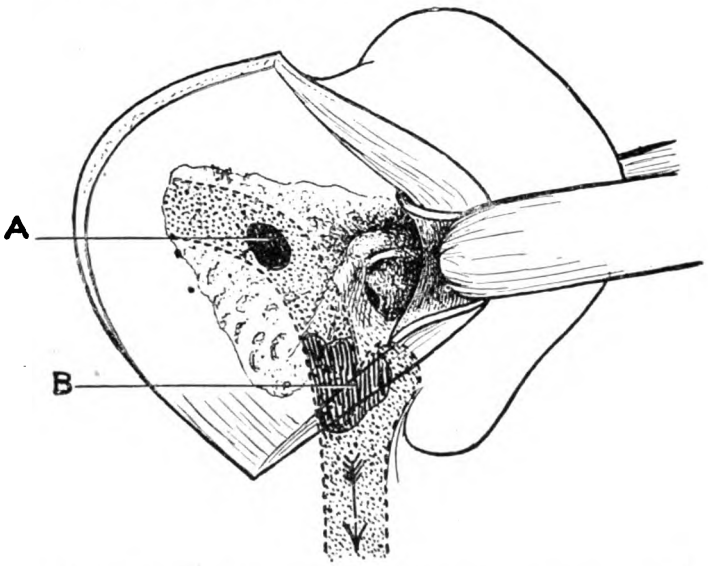

G. 236. DIAGRAM TO SHOW THE USUAL POINTS AT WHICH THE TRANSVERSE S IS PRIMARILY INFECTED. A, High up; from the posterior mastoid cells. In ase it may not be necessary to tie the jugular vein. B, Low down; involving ugular bulb. This necessitates ligature of the vein.

n removal of the bone from above downwards there is a certain of small particles of clot being dislodged into the circulation, or, e sinus wall is injured, of hæmorrhage taking place if the thrombus s particular point does not completely occlude the sinus. If, how- the sinus be first exposed and obliterated at its lowest limit, risks are greatly minimized. There is no special technique in ving the bone beyond that already given in the description of the lete mastoid operation.

he next step is to expose the transverse sinus behind the infected and follow it backwards until the dura mater appears normal for at

least three-quarters of an inch. If necessary, the skin incision must be prolonged still farther backwards, in order to permit of removal of the bone overlying the transverse sinus, which may, perhaps, have to be exposed even to the confluens sinuum.

In removing the bone overlying the infected thrombus, the gouge and chisel should be used rather than the bone forceps or burr. With the latter there is greater risk of dislodging particles of clot into the circulation, owing to pressure of the instrument on the sinus wall.

After the sinus has been exposed well beyond the region of the thrombus, the bone forceps may safely be used, especially in exposure of the transverse sinus; and this is a much more rapid method than removing the bone by means of the gouge and mallet. To prevent the inner blade of the forceps from nipping the sinus wall between it and the bone, the dura mater forming the outer wall of the sinus should be separated from the overlying bone by means of a dura-mater separator. In the region of the infected area the sinus wall may be adherent to the bony wall as a result of the inflammatory adhesions, and, in addition, may be extremely friable and so easily torn through.

In exposure of the sinus two points should be remembered: firstly, that it is sometimes difficult to differentiate it from the dura mater covering the temporo-sphenoidal lobe above and the cerebellum below; and secondly, that the transverse sinus is a very much broader vessel than is imagined, being even half an inch in width. Not much force is required to obliterate its lumen, but care must be taken to pack the gauze evenly across its whole width.

After the sinus has been occluded above and below the area of infection, it should be incised with a small knife along its whole length between the obstructing plugs of gauze (Fig. 237). If there be bleeding, it may be due to the sinus being obliterated incompletely, or it may come from the superior petrosal sinus. To find out where the bleeding comes from, the finger should be pressed upon the sinus at its upper and lower limits, close to the obstructing plugs of gauze. If the bleeding stops, it shows that the sinus has not been obliterated completely; this can now be done by further plugging with gauze. If, in spite of this, bleeding still continues, it presumably comes from the petrosal sinus.

All clot and granulations are now rapidly curetted out and the transverse sinus plugged with gauze. After a moment the gauze is withdrawn and another small piece is pressed into the transverse sinus at the point of entrance of the petrosal sinus. After the bleeding has been arrested, the outer wall of the transverse sinus is excised by cutting it away with blunt-pointed scissors. The interior of the sinus is then inspected, special

attention being given to the lower portion to see if its lining is normal. If this be not the case, even if there be no signs of thrombosis, it means that the surgeon has failed to get well below the infected area, and therefore the internal jugular vein must be ligatured. If, however, it be normal, the gauze plug already placed between the sinus wall and the overlying bone is left undisturbed.

If there be no bleeding from the sinus (excepting a slight amount from the blood contained within the isolated portion), the thrombus is curetted out and the inner surface of the sinus inspected. After

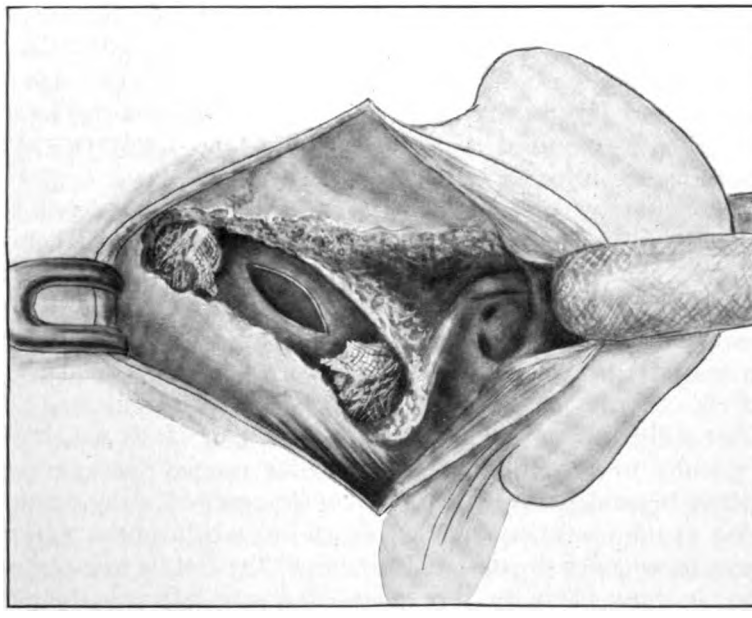

FIG. 237. THE TRANSVERSE SINUS EXPOSED AND OPENED. The lumen of the sinus is obliterated above and below the region of the infected thrombus by plugs of ribbon gauze pressed in between the sinus wall and the overlying bone. In this case it is not necessary to tie the jugular vein.

excising the outer wall, search is made for the superior petrosal sinus, which presumably is thrombosed, although perhaps only by normal clot. To expose this tributary, which enters the transverse sinus at the point at which it turns downwards to form the sigmoid sinus, bone must be removed in front of the transverse sinus along the angle forming the roof and inner wall of the mastoid and antrum; that is, along the superior margin of the petrosal bone. If the inner surface of the transverse sinus in its neighbourhood be normal, nothing need be done. If,

however, the sinus wall be infected, the petrosal sinus should be followed out, if possible, its outer wall being incised and the clot removed, bleeding being afterwards arrested by pressure.

As a final step, the gauze plugging which still obliterates the lumen of the sinus in its upper part is removed. If the sinus be normal at this point, free hæmorrhage will occur; this is arrested at once by again introducing a strip of gauze between the sinus and the bone. Although during the earlier stages of the operation the inner lining of the posterior portion of the sinus may have seemed to be normal, yet it occasionally happens that hæmorrhage does not at once occur on removing the plug of gauze; but after a moment or two a long smooth clot, gradually tapering at its end, may be shot out from the opening within the sinus, being followed by a gush of blood. The terminal portion of this clot is non-infective and of recent formation. Its appearance is always a matter of satisfaction, as it means that the sinus has been freely exposed and opened behind the infected area.

If on exposure of the sinus it be found that the clot extends so low down that it will be impossible to obliterate the sinus well below the infected area, the jugular vein should be ligatured at once before interfering further with the sinus from the mastoid wound.

Attempts to remove the clot from the jugular bulb by curetting out the sinus from above are only referred to to be condemned. The surgeon who believes in this method hopes that all the infected portion of the clot will be swept out by the flow of blood. It is not, however, always possible to introduce a curette into the jugular fossa, and if the clot extends beyond this region it cannot be curetted away completely. The result of the operation does not depend so much on the skill of the surgeon as on whether the terminal portion of the clot be infected or not. Recovery is most likely to take place if a non-infected clot already extends beyond the region of the curette and so obliterates by natural means the lumen of the vein below the point reached by the surgeon. If, on the other hand, free hæmorrhage occurs as a result of curetting, it means that the lumen of the vein has been restored, but there is no guarantee that all the clot has been completely removed. If any infective portion remains, a fatal result will almost certainly occur as the result of pyæmia.

LIGATURE OF THE JUGULAR VEIN

Indications. Unfortunately, opinion is not unanimous with regard to this matter. The chief arguments raised against ligature of the jugular vein are: (1) That it favours extension of the thrombus along the veins communicating with it, especially along the inferior petrosal

ndyloid veins, which enter the jugular bulb. (2) That it in no events the spread of infection along other paths, owing to the n with which its tributaries communicate with one another. a result of obstruction in the circulation, acute inflammation of ebellum may take place.

ce the jugular vein should only be ligatured if the symptoms point nset of a general infection of the circulation and if at the same be found impossible to obliterate the sinus below the infected us, and since this vein is the chief route by which this infection lace, it seems a matter of common sense that it should be liga- At the same time, as many as possible of its tributaries above nt of ligature should also be ligatured well beyond the point at hey may be thrombosed.

nough extension of the infection may take place along other fter ligature of the jugular vein, it is impossible to say whether ult is *post* or *propter hoc*. Against ligature, statistics have been to show that in a series of cases in which the jugular vein has n tied the percentage of recoveries is just as high as in those ch it had been ligatured. This argument is not quite sound, there is no doubt that in those cases in which ligature of the vein is justified, the chances of recovery, owing to the extension hrombus downwards, must be less than in the less serious cases ch it is admittedly unnecessary to tie the vein. It is also im- to say how many cases would otherwise have ended fatally if had not been performed.

he majority of cases the vein is ligatured after exploration of the rse sinus. In a few cases, however, the symptoms warrant it erformed as a primary step of the operation, even before the l process has been opened.

er exposure of the transverse sinus. (i) If the clot extends so vn that it is impossible to obliterate the lumen of the sinus below er limit.

If there be thrombosis of the bulb of the jugular vein. This on is sometimes difficult to diagnose. There may be no symp- xcepting, perhaps, rigors, occurring during the course of chronic ear suppuration, as even the lower portion of the sinus may be ormal in appearance owing to the clot being limited entirely to the bulb. The probability of the diagnosis being correct is strength- the presence of granulations or carious bone on the floor of the um. It is better to risk tying a normal vein than to fail to tie eady infected.

) If the sinus was obliterated above the jugular bulb at the pri-

mary operation and rigors occur subsequently, showing that the sinus is infected still lower down.

Before exposure of the transverse sinus. (i) If there be thrombosis of the jugular vein. In addition to the ordinary signs of transverse sinus thrombosis, there may also be infiltration of the tissues, or tenderness along the anterior border of the sterno-mastoid muscle. The prevalent idea that a thrombosed jugular vein can be felt on palpation as a hard cord extending down the neck is erroneous. If anything be felt it is probably some enlarged cervical glands lying along the line of the vein. In any case it is bad practice to palpate the jugular vein, as by doing so there is considerable risk of dislodging particles of the septic clot.

(ii) If, as a result of septic infection, the general condition of the patient be so serious that a prolonged operation seems unjustifiable. In such cases, the transverse sinus is rapidly exposed and incised after tying the internal jugular, its contents being curetted out and the wound cavity lightly plugged; the completion of the operation, consisting of the opening up of the mastoid cells and tympanic antrum, and possibly also exploration of the intracranial cavity, may be performed next day or later.

(iii) If it be doubtful whether septic thrombosis of the sinus has already occurred, it is justifiable in certain cases merely to expose the sinus freely and not to open it (see p. 477). If rigors subsequently occur in these cases and it becomes evident that the sinus has become infected after all, then it is wiser to tie the jugular vein as a primary step of the operation before opening up the sinus itself.

The writer's reason for doing so is that at the second operation he has always found the clot to be extensive, or, at any rate, to be situated so low down as to prevent the sinus being obliterated below the infected area.

Operation. Formerly it was considered sufficient to divide the vein between two ligatures and to leave it *in situ*. Now, however, the upper portion of the vein is brought out through the wound in the neck after this has been done.

The patient lies in the recumbent position with the affected side close to the edge of the table. The head and shoulders should rest on a hard pillow in such a fashion that the neck is slightly extended, the chin being drawn upwards and the head turned a little to the opposite side so that the anterior border of the sterno-mastoid muscle can be clearly defined throughout its whole length. The surgeon stands at the side to be operated on. The neck is carefully cleansed, but in doing so care should be taken not to rub the neck too violently, nor should any attempt be made to palpate the line of the jugular vein in the hope

of feeling it. There is no object in doing so, and if it is thrombosed a portion of the clot may be dislodged.

An incision, at least three inches in length, is made along the anterior border of the sterno-mastoid muscle, the mid-point of the incision corresponding to about the level of the cricoid cartilage. On cutting through the skin and platysma some small veins may be met with: they should be clamped with forceps and divided. If, however, the anterior jugular vein be exposed, it should be drawn to one side, if possible, and not divided. The anterior border of the sterno-mastoid muscle is clearly defined, until the upper border of the omo-hyoid muscle is reached (Fig. 238). Its edge is then drawn slightly outwards by means of a retractor and separated from the underlying deep fascia. Beneath this fascia is the carotid sheath, which encloses not only the carotid artery but the internal jugular vein and the vagus nerve. The vein is lateral and somewhat superficial to the artery, and the vagus nerve lies behind. A vein of varying size will be seen crossing obliquely downwards and outwards to pierce the deep fascia at a level corresponding to the cornua of the hyoid bone; this is the common facial vein about to enter the internal jugular (Fig. 239). If the surgeon has not had much experience and has difficulty in finding the jugular vein, a certain method of doing so is to find the facial vein and then follow it down until it enters the jugular. The carotid sheath should be opened about this point, and the position of the vein ascertained by feeling the pulsations of the carotid artery. The sheath of fascia covering the jugular vein is picked up with a pair of fine forceps and cut through with a sharp scalpel, which should be inclined obliquely outwards so that the flat of the knife is held towards the vessel. Any enlarged lymph glands lying over the vein must be removed.

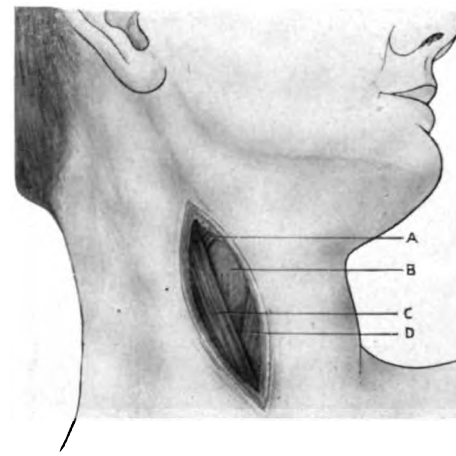

FIG. 238. INCISION FOR EXPOSURE OF THE JUGULAR VEIN. The illustration shows the superficial structures. A, Common facial vein; B, Fascia covering the hyoid bone; C, Anterior border of the sterno-mastoid muscle; D, Omo-hyoid muscle.

When the vein has been identified, a blunt dissector is passed between its outer wall and the sheath, so as to separate the two. The sheath is

incised upwards and downwards until the vein is freely exposed. If the vein be patent, it will be of a bluish colour, expanding and diminishing in volume with each act of respiration. If it be thrombosed, there is usually accompanying periphlebitis which may make the separation of the sheath from the vein and the surrounding tissues difficult. If there be no periphlebitis, the thrombosed portion may be purplish, or, if the clot be of long standing and breaking down, more of a yellowish colour; the vein stands out as a cord and does not pulsate. If the thrombus be limited to the portion above the entrance of the common facial vein, the upper portion of the jugular may be small and collapsed, only becoming full and pulsating below the point at which the facial joins it.

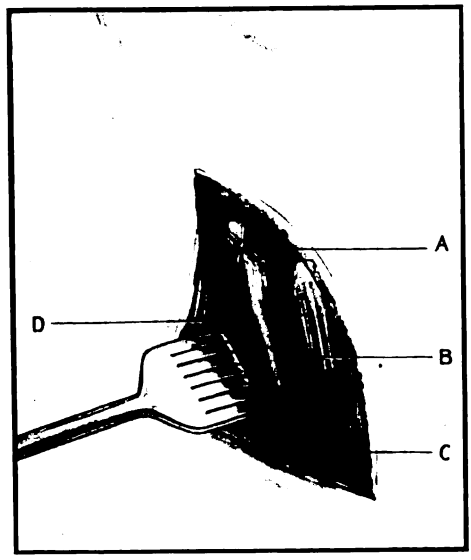

FIG. 239. EXPOSURE OF THE JUGULAR VEIN HIGH UP. A, Common facial vein; B, Sterno-hyoid muscle; C, Omo-hyoid muscle; D, Anterior border of the sterno-mastoid muscle retracted outwards. A ligature is placed around the jugular vein just above the common facial vein. When the jugular is ligatured at this spot it is not necessary to tie the facial vein. In actual practice the vein, of course, would be tied and cut between two ligatures, the upper portion of the vein being brought out into the neck.

The next step in the operation is to get well below the point at which the jugular is thrombosed. If the thrombus be practically limited to the jugular fossa the vein may be ligatured above the common facial; if not, as low down the neck as possible. In ligaturing the vein low down in the neck, the skin incision must be extended downwards, and as the lower portion of the neck is reached, the omo-hyoid will have to be pulled aside. The probe should be passed all round the vein so as to make certain that it is freed from its sheath, and especially that it is separated from the vagus nerve which lies behind it.

An aneurysm needle threaded with silk is now passed around the vein from within outwards. The loop of silk is cut so as to form two ligatures, and the aneurysm needle then withdrawn; the lower ligature is first tied, its ends being cut short. The upper ligature is then tied

a short distance above it, but in this case the ends are left long. The vein is raised from its bed by slight traction on this ligature and is cut across between the two, the lower portion being allowed to sink back into the wound. The upper portion is then carefully separated for some distance upwards. Lying behind the vein may be seen the vagus nerve (Fig. 240). Any tributaries are clamped between two forceps, cut across, and ligatured, the upper end of the vein being brought out into the upper angle of the wound. Care must be taken that enough of the vein is dissected out to allow of this being done, especially if the ligature is applied above the level of the common facial; in this case the facial need not be tied.

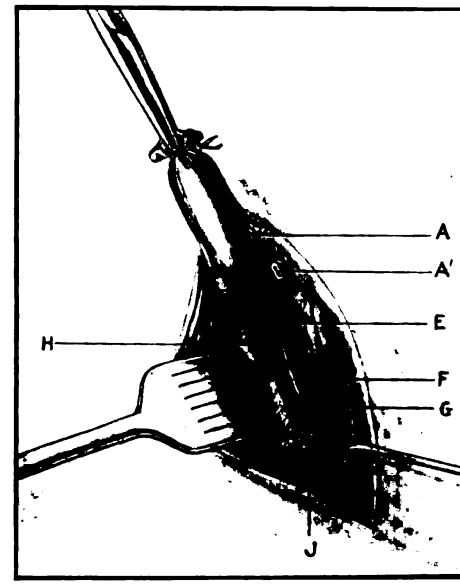

FIG. 240. LIGATURE OF THE JUGULAR VEIN LOW DOWN IN THE NECK. The upper portion of the vein is dissected out and brought into the neck. A, A', Cut ends of the ligatured facial vein; E, Descendens hypoglossi nerve; F, Carotid sheath and internal carotid artery; G, Vagus nerve; H, Lymph gland; J, Lower end of the internal jugular vein. The hook pulls aside the omo-hyoid muscle.

If there be no periphlebitis, inflammation of the soft tissues, or thrombosis of the vein itself in the neck, the wound may be closed by means of silkworm-gut sutures, excepting at its upper and lower angles, the jugular vein being tied to the margin of the upper wound, and a tube inserted at the upper and lower points of the incision. If, however, the vein be thrombosed, and especially if there be periphlebitis, the wound should be left open, except perhaps at its lower angle, and should be lightly packed with gauze, as in these cases cellulitis of the neck may afterwards occur.

After completion of the operation in the neck the surgeon turns to the mastoid process. If the ligature of the vein has been the primary step, the mastoid operation is now performed and the transverse sinus is freely exposed for a considerable distance behind the thrombus. If, however, the mastoid operation has been the first stage, and the jugular has been tied as soon as exposure of the sinus showed it to be thrombosed, the opera-

tion on the mastoid is now completed and the sinus opened as already described (see p. 478). The next step is to incise the sinus freely from above downwards towards the jugular fossa and curette out the thrombus.

If there be considerable hæmorrhage, it means that the thrombus is probably parietal and situated within the jugular bulb, the bleeding presumably coming from the inferior petrosal sinus or other tributaries which enter the bulb or upper portion of the jugular vein. If the bleeding be excessive, the sinus is plugged after a moment or two, by inserting a piece of gauze into its lumen towards the jugular bulb.

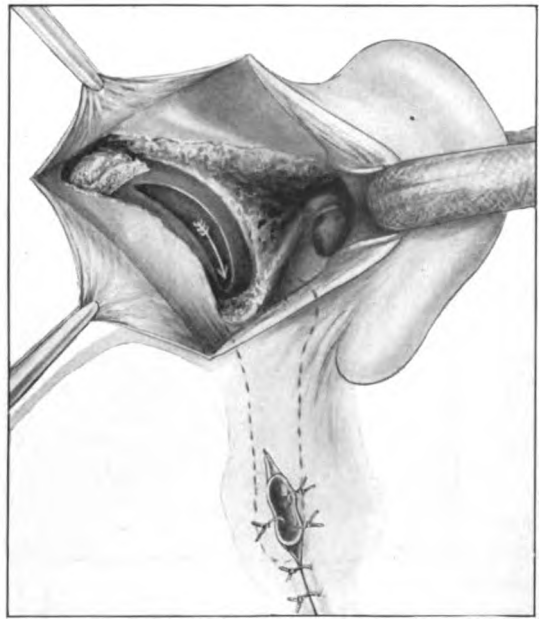

FIG. 241. FREE EXPOSURE OF THE TRANSVERSE SINUS, WHICH HAS BEEN INCISED, WITH LIGATURE OF THE JUGULAR VEIN. The transverse sinus is obliterated posteriorly by a plug of gauze pressed in between its outer wall and the underlying bone. The sinus is freely exposed almost down to the jugular fossa. The vein has been ligatured and its upper portion sutured to the skin wound in the neck. The arrow shows the direction along which the sinus and vein are syringed.

In this case the portion of the vein brought into the neck is usually also filled with blood. After isolating it from the deeper tissues by packing strips of gauze round it, the vein is deliberately opened just above the ligature. The bleeding usually stops after a moment or two, but if it cannot be controlled, the lumen of the vein must again be closed by a ligature, the end of the vein being allowed to project on to the neck.

If there be no bleeding from the lower portion of the transverse sinus and jugular bulb, it means that the vessel is completely thrombosed at this point. The clot should now be removed by curetting through the sinus from above downwards towards the jugular bulb, and also from below upwards through the open end of the jugular vein.

The venous channel is afterwards syringed through from above

wnwards. To do this, a piece of rubber tubing is inserted into the ening in the transverse sinus and some warm saline solution is injected rough it with a syringe. If the clot be not firmly adherent it can ually be washed out through the opening in the vein. No force should used. If gentle syringing be not sufficient to expel the clot, the tempt must be given up. The chief objection against syringing is the ssibility of particles of the septic thrombus being forced into the veins mmunicating with the jugular bulb. A small drainage tube is inserted thin the sinus.

In order to keep the lumen of the vein in the neck open, it should be tched to the edge of the wound surface by several catgut sutures. If e bleeding necessitated plugging of the lower end of the sinus and re- ıtion of a ligature on the vein in the first instance, syringing should be stponed until the first dressing; the portion of the vein left protruding rough the skin wound in the neck is then cut across, and the edge of e vein sutured to the margin of the wound under cocaine.

The mastoid cavity is lightly plugged with gauze and a dry dressing plied. The wound in the neck is similarly treated.

After-treatment and progress of the case. There is fre- ently considerable shock after the operation, especially if exposure the jugular bulb has been undertaken, partly owing to the duration the operation and to hæmorrhage. If the patient be very collapsed, continuous saline injection, to which some brandy may be added, may given per rectum according to Moynihan's method. After the primary ock has passed off, the immediate result is usually satisfactory.

If the jugular vein has not been ligatured, the first dressing should performed within forty-eight hours, the gauze packing being removed, e wound syringed out, and afterwards repacked. The plugs of gauze, ıich were pressed in between the outer wall of the sinus and the over- ng bone in order to obliterate the lumen of the latter, should not be erfered with for at least six days. If the case progresses favourably, e temperature becomes normal within a day or two, the patient feels ll, and the wound assumes a healthy appearance. If, on removal of the uze plugging, hæmorrhage takes place, then the plugging must be ıewed and not touched again for three or four days. After it is pos- ıle to remove these plugs, the wound is treated as has already been scribed in Schwartze's operation or in the complete operation in which e posterior wound was left open.

If the jugular vein has been ligatured, the sinus and vein should be ringed through daily, and this should only be stopped after all secre- n has ceased, usually a matter of a week or ten days.

When the sinus, jugular bulb, and vein have been exposed throughout

their length the wound is treated as an ordinary surgical one, being packed until it granulates up from the bottom (*vide infra*).

Apart from intracranial and pyæmic complications, the progress of the case may be delayed owing to the enfeebled and septic condition of the patient, and also from the occurrence of abscesses in the neck, or region of the mastoid itself. These abscesses are the result of septic thrombosis occurring in some tiny vessel. The first sign of their occurrence is an attack of pyrexia, shortly followed by a painful swelling at the affected spot. Any collection of pus should be drained at once. Although it is quite good practice to close the incision in the neck in a clean case, yet there must be no hesitation to open it up on the slightest sign of it becoming septic.

The case may appear to progress favourably for the first week or ten days, and then an intermittent and increasing pyrexia may occur for no obvious reason. This is usually due to extension of the infection along the petrosal sinuses, or perhaps along the transverse sinus.

Symptoms of involvement of the cavernous sinus may arise, perhaps even with formation of a peri-orbital abscess; or, on the other hand, the patient may gradually sink in consequence of septic toxæmia; or the end may come more suddenly with the onset of basal meningitis. Unfortunately, these cases are almost hopeless from the first, as very little can be done from a surgical point of view owing to the fact that they are not seen soon enough.

In thrombosis of the cavernous sinus the only hope of recovery lies in its exposure and incision of its wall. The sinus may be approached by tracking forwards the superior petrosal sinus—a matter of considerable difficulty, and seldom justifiable. Recently Charles Ballance has suggested the adoption of the Hartley-Krause route for extirpation of the semilunar ganglion, and says he has found the operation easy and effectual. If pus be evacuated from the sinus he considers it advisable to adopt the recommendation of Voss, who cuts away the zygoma and removes more bone from the basal aspect of the skull so as to get direct drainage.[1]

EXPOSURE OF THE JUGULAR BULB

This may be performed either by following the sinus downwards or through the floor of the acoustic canal and tympanum. The former method was first described by Grunert;[2] the latter by Piffl.[3]

[1] Allbutt and Rolleston's *System of Medicine*, 1908, vol. iv, part ii, p. 495.
[2] *Archiv für Ohrenheilkunde*, 1902, vol. liii, p. 287.
[3] *Ib.*, 1903, vol. lviii, p. 76.

Indications. The object of the operation is to remove the septic
t situated within the jugular bulb in the hope of preventing extension
the infection along the veins leading into it, more especially the in-
ior petrosal sinus. This indeed has been known to occur even after
transverse sinus has been curetted out, the jugular vein ligatured,
l the venous channel syringed through.

Grunert's operation. After free opening of the mastoid process
l exposure of the outer wall of the transverse sinus, the skin incision is
tended downwards beyond the tip of the mastoid. The soft tissues are
n separated from the bone forwards and backwards so as to expose
mpletely not only the mastoid process, but also the digastric fossa and
se of the skull immediately behind it, up to the outer bony margin of
jugular foramen. Unless care is taken, the forcible traction forwards
the soft tissues necessary to expose the field of operation may injure
tear the facial nerve as it emerges from the stylo-mastoid foramen.

The tip of the mastoid process is removed first. The transverse sinus
then freely exposed to its lowest possible limit by removing the over-
ng bone. In doing this it must be remembered that the sinus becomes
rizontal just before it ends in the jugular fossa, so that at this point
e skull forms its floor instead of its outer wall.

After having exposed the sinus as freely as possible, the 'bridge'
bone separating it from the outer wall of the jugular foramen is
moved in small pieces by nipping it away with narrow biting forceps
til the jugular bulb is exposed from its outer surface. The facial nerve
ould not be injured, as it lies in front and lateral to the portion of
e bone to be removed.

In performing the later stages of the operation, the patient's head
ould be turned well over to the opposite side in order to get a good
ew of the parts lying behind and beneath the mastoid process; and in
acking the sinus downwards, the probe should be used carefully in
der to try to define the exact position of the jugular fossa.

Piffl's operation. Owing to the anatomical difficulty of reaching
e jugular bulb by following the sigmoid sinus downwards, especially
those cases in which the sinus lies far forwards and in which, at the
me time, there is a very well-developed jugular fossa, Piffl recommends
posure of the jugular bulb from above through the acoustic canal.
he object of this method is to prevent injury to the facial nerve, which
states is almost certain to occur in Grunert's operation, if carried out
cases such as those just mentioned.

After the complete mastoid operation has been performed, the skin
cision is extended downwards and forwards in order that the soft tis-
ues may be freed from the floor and anterior surface of the bony portion

of the acoustic canal as far forward as the petro-tympanic fissure. The soft tissues are pulled forward with a blunt hook to give sufficient room. The lower portion of the tip of the mastoid is removed by means of the gouge, as far as can be done without injuring the facial nerve, which in this operation is pulled backwards with the soft tissues at the posterior inferior margin of the wound. The lower bony margin of the acoustic canal, now freely exposed, is removed by means of a pair of fine biting forceps until the jugular surface of the tympanum is reached. If there be not sufficient room, the bone may be clipped away as far as the styloid process, which also may be removed by bone-forceps after the muscles attached to it have been dissected off.

In freeing the styloid process, its posterior surface must be approached with caution for fear of injuring the facial nerve, which here lies in close connexion with it. In the front of the wound the capsule of the mandibular joint may be exposed, but must not be interfered with.

After removal of the styloid process, the uppermost portion of the jugular vein should be seen emerging from the jugular fossa. This is followed upwards by careful removal of the bone between it and the floor of the acoustic canal and tympanum, until the jugular bulb is brought into view. This part of the operation must be proceeded with very cautiously, the bone being nibbled away in small fragments with gouge forceps which are of sufficient strength to nip through the bone without having to wrench it away. The amount of bone to be removed and the difficulty of the operation depend largely on the anatomical condition found.

Whether Grunert's or Piffl's operation has been employed, the operation may be completed either by incising the outer wall of the sinus and jugular bulb, then curetting out the thrombus, and finally washing through the lower portion of the vein from above downwards, or by the more radical method of also exposing the upper portion of the jugular vein throughout its whole length. To do this the post-aural incision is continued downwards until it joins the one previously made in the neck. To obtain room, the neck must be somewhat extended and the jaw pulled well forward and the sterno-mastoid muscle backwards. The jugular vein is then dissected upwards towards the bulb.

The nearer the jugular fossa is approached the deeper and more difficult becomes the exposure of the vein. Passing in front of it may be found the stylo-pharyngeal, stylo-hyoid, and digastric muscles. In Grunert's operation they need not be cut through as the vein will lie posterior to them. In Piffl's operation these muscles probably have been already reflected forwards, after removal of the styloid process.

Particular care must be taken not to injure the nerve trunks, which

in such close relationship with the vein. Lying immediately behind vein is the vagus nerve; the accessory nerve passes downwards and wards behind it, and the glosso-pharyngeal and hypoglossal nerves wards between the vein and the internal carotid artery.

After the vein, the jugular bulb, and the sigmoid sinus have been osed throughout their course, their outer wall is cut through with air of blunt-pointed scissors along its whole length, so as to convert venous canal into an open gutter. The thrombus is then curetted out the dissected portion of the jugular vein cut off as high up as pos-e. Any bleeding from the inferior petrosal sinus or condyloid veins, ch may not be thrombosed, should be arrested by direct pressure of rip of gauze over the bleeding points. The wound cavity is then hed out with a weak solution of biniodide of mercury and dried.

The lower portion of the incision in the neck may be closed with ires and a small drainage tube inserted at its lower angle. The upper tion of the wound, now directly continuous with that of the mastoid ity, is left open and packed lightly with gauze, which is inserted into remains of the venous channel.

Comparisons of operations for transverse sinus thrombosis.

cept when the thrombus is limited to the upper part of the sigmoid is, it is undoubtedly wiser to tie the jugular vein than to be content n curetting out the clot after obstructing the sinus above and below means of gauze plugs. With increasing experience I am more in our of ligation of the jugular vein. I have to regret at least two fatal ults for not having done this. I cannot point to any instance in which y ligation of the jugular vein has prevented recovery, although, on the er hand, I feel sure that in many cases recovery would not have taken e without this procedure. Exposure of the jugular bulb is so difficult operation and requires so much time, especially if the whole length he upper portion of the jugular vein is also dissected out, that it is om advisable to perform it; nor will it often be justifiable owing to condition of the patient, who is seldom strong enough to undergo n a prolonged operation. The records of this particular operation are few that it is impossible as yet to determine its value.

If the sinus be exposed as low down as possible, and the jugular vein ected out and brought out into the neck, and the venous channel rwards syringed through, the chances of recovery should be almost good as in the case of free exposure of the jugular bulb.

If the inferior petrosal sinus be already infected before the operation, oes not matter whether the operation performed is that of syringing ough the jugular bulb or freely exposing it, as in either case the rior petrosal sinus cannot be followed out.

Curetting of the lower portion of the sinus without previous ligature of the jugular vein should never be done.

Difficulties and dangers of the operation. The chief difficulty in these operations is anatomical; the chief danger is hæmorrhage.

If the hæmorrhage be due to accidental tearing of the wall of the sinus in the earlier part of the operation, and if it be impossible to obliterate the sinus below this point by pressing in gauze between its wall and the underlying bone, then the jugular vein should be tied before anything else is done.

Extreme vascularity of the bone is not unusual after ligature of the jugular vein. In these cases the surgeon must rely on the cleverness of the assistants in keeping the field of operation clear by careful swabbing.

In exposure of the jugular vein there may be difficulty in finding the vessel, especially if the cervical glands are enlarged, or if there be matting together of the tissues in consequence of periphlebitis or cellulitis. In these cases the best plan is to identify the common facial vein and then trace it down to its entrance into the jugular vein.

With regard to the sinus, the chief danger is injury of its inner wall whilst curetting out its contents: this may afterwards give rise to meningitis or a cerebellar abscess. Accidental pricking of a non-thrombosed jugular vein may allow of entry of air into the vein and so cause death: this is a catastrophe I have not yet met with. Also, if the operator be careless or inexperienced, he may injure the carotid artery or vagus nerve; in the former case the only thing to do is to ligature the artery above and below the wound.

Complications. The chief intracranial complications are meningitis and cerebellar abscess; the former usually from extension of the septic thrombosis along the petrosal sinuses. If, at the time of operation, it be doubtful whether intracranial suppuration already exists or not, the surgeon should content himself with removing the septic thrombus from the sinus and await further symptoms. At the time of the operation, however, sufficient bone should be removed to expose the dura mater over the cerebellum. If, in addition to the clinical symptoms, the appearance of the dura mater, the increased intracranial tension, and the absence of palpation suggest the presence of an abscess, the cerebellum should then be exposed and explored (see p. 505). Before doing this, the wound should be made as aseptic as possible and a fresh set of sterilized instruments used.

The complications resulting from general septic infection are pyæmia and septicæmia.

Prognosis. The prognosis depends entirely on whether the septic focus can be completely removed or not. Failure to do this is frequently

due to the operation not having been sufficiently extensive. It is a matter of experience that if a second operation has to be performed recovery seldom takes place. For this reason the first operation must be thorough.

If such cases could be operated on in the earliest stage whilst the infective thrombus was still limited, without doubt a higher percentage of recoveries would be obtained. Unfortunately, the surgeon may not be summoned until too late, owing to the seriousness of the condition not having been realized.

In any individual case it is impossible to tell for the first few days after the operation what the ultimate result will be. Without operation a fatal termination is practically certain.

The following are the results of sixty cases on which I have operated:

Recoveries	
Thrombosis of the transverse sinus and jugular vein	8
Thrombosis of the sinus:	
(*a*) Extensive	9
(*b*) Localised	10
(*c*) With intracranial complications	3
Deaths	
Meningitis:	
(*a*) With extensive thrombosis, including jugular vein	9
(*b*) With internal-ear suppuration	5
Pyæmia:	
(*a*) With empyema	4
(*b*) With pyopneumothorax	5
Cavernous sinus thrombosis	3
Cerebellar abscess	2
Cerebral abscess	1
Collapse after operation	1

In the majority of cases which died, there were already other intracranial complications before operation took place.

Infection of the intracranial cavity by direct extension of the disease may indeed be unavoidable. Death from general pyæmia would, in my opinion, be much less frequent if the case could be operated on early enough. In the cases which recovered, although in a fair proportion the infection of the sinus and even of the jugular vein was extensive, serious intracranial complications or general pyæmia had not occurred. The jugular was not tied in five of these cases; in three, the sinus was found infected at the operation with no other symptoms, the condition being that of a localised abscess; in the other two there was an early parietal thrombus, the diagnosis having been already established by the

occurrence of repeated rigors. Of the cases which died, in a very few was there any hope of recovery even before operation was attempted. In two cases a fatal result, in my opinion, was owing to the jugular vein not being ligated. In the one there was a localised clot at the knee of the sigmoid sinus, and after its removal the sinus was simply obliterated above and below. Within forty-eight hours septic pneumonia with empyema of the lung occurred. Autopsy showed the sinus, jugular bulb and vein to be absolutely free. Infection of the lungs no doubt took place during the operation from a small fragment of the clot becoming disintegrated, which I feel sure from my experience of other cases would have been avoided if the jugular vein had been ligated in the first instance.

The other case was a child suffering from acute mastoid disease in which the sinus was covered with granulations. As there were no rigors or evidence of septic infection, the sinus was not opened, nor the vein ligated. Within a few days, owing to pyrexia, the sinus was opened. As the clot was quite localised, the walls of the sinus were obliterated above and below. In this instance again, owing to downward spread of the septic thrombus, death eventually occurred from pyæmia.

CHAPTER X

OPERATIONS FOR INTRACRANIAL ABSCESS OF OTITIC ORIGIN

An intracranial abscess, the result of disease of the temporal bone, is usually situated close to the surface of the brain, and is in close relationship with the diseased area of bone through which the infection has taken place. The actual track of the infection can frequently be traced through the bone to the dura mater and brain substance itself; sometimes, indeed, a fistula is found to pass through the bone and to communicate with the intracranial abscess. On the other hand, though rarely, the surface of the bone to all appearances is normal and there are no adhesions between it and the dura mater and underlying brain substance, and the abscess may be situated deeply within the brain.

With regard to the comparative frequency of temporo-sphenoidal and cerebellar abscess, in 100 cases collected from the records of the London Hospital the writer found that in children under ten years of age temporo-sphenoidal abscess occurred in 87% and cerebellar only in 13%, whereas in adults cerebral abscess occurred in 65% and cerebellar in 35%; and that a cerebral and cerebellar abscess occurred together only in 5% of the cases.

These statistics are practically the same as Körner's.[1] Ballance, on the other hand, considers cerebellar abscess a more frequent occurrence than temporo-sphenoidal.

Multiple abscess may be met with, usually the result of pyæmia.

Indications. An intracranial abscess must always be opened and drained.

Indications pointing to such a condition are persistent headache, purposeless vomiting, a slow pulse, a subnormal temperature, and optic neuritis. With this there is usually some change in the mental condition, especially in the case of a temporo-sphenoidal abscess. In the early stages there may be attacks of simple forgetfulness or mental aberration, or, on the other hand, that of extreme mental excitement. Owing to the intracranial pressure caused by the increase in size of the abscess, the mental state becomes impaired and the condition known as slow cerebration or the 'dream state' may be observed.

[1] *Die otitischen Erkrankungen des Hirns, der Hirnhäute und der Blutleiter.*

It must, however, not be forgotten that the same clinical picture may be produced by other conditions, such as an intracranial tumour: in the case of a middle-ear suppuration, however, an intracranial abscess may be diagnosed unless this can otherwise be excluded.

Before operation is decided on, the site of the lesion must be determined. This can only be done if certain localising symptoms are present.

In a temporo-sphenoidal abscess, if the cortical region be affected, there may be paralysis or paresis of the opposite side, beginning with the face and then spreading to the arm and leg; or in the opposite order if the internal capsule be involved.

If the left temporo-sphenoidal lobe be the site of the lesion, aphasia may be met with, and if the abscess extends backwards, word-blindness may occur. If the centre of hearing be affected there may be complete deafness of the opposite side owing to its destruction; or tinnitus or hyperacusis if the centre be only irritated by the proximity of the abscess; or if the anterior extremity be involved, anosmia or parosmia may be noticed. Another important sign, occurring in conjunction with the above symptoms, is a fixed pupil on the affected side.

In a cerebellar abscess the symptoms are less marked, or may even be absent, so that the abscess may remain undiagnosed during life and only be discovered at the autopsy, which may perhaps have been performed on account of the sudden and unexpected death of the patient from rupture of the abscess itself. In walking, in addition to a peculiar staggering gait, there is a tendency for the patient to direct his course gradually towards the affected side. Lateral nystagmus, if present, is usually directed towards the affected side and has to be differentiated from that due to internal-ear disease. In contra-distinction to vestibular nystagmus it varies in being usually directed to the side towards which the eyes are deviated. The slowness of the pulse-rate (bradycardia) becomes increasingly marked as the abscess increases in size, sometimes being reduced to less than fifty beats a minute; this sign may be of considerable diagnostic importance in differentiating a cerebellar abscess from internal-ear suppuration. Unilateral co-ordination of movement may be demonstrated by lack of precision to touch a point with the finger; for example, to touch the tip of the nose with the eyes shut. This movement will be defective on the affected side. Babinsky has drawn attention to another test which he terms dysdiadokokinesis. If the patient performs a simultaneous movement such as rotation of both hands, it will be found that on the affected side the movement is carried out much more slowly and imperfectly. Optic neuritis and vomiting usually are more severe than in temporo-sphenoidal abscess. Headache, if present, may be referred to the occipital region, and there may also be slight

retraction of the neck or pain behind the mastoid region as a result of localised and early meningitis of the posterior fossa. If the abscess be very large, there may be paresis or paralysis of the facial nerve and perhaps also of the upper extremity. The deep reflexes may also be altered, the knee-jerk being frequently absent on the affected side. The patient in the late stage usually lies curled up in bed on the side opposite to the lesion, with the knees flexed.

Methods of operation. Two methods may be employed:

1. Trephining directly over the area of the abscess (rarely necessary).

2. First performing the mastoid operation and then following out the route of infection (usual method).

In the case of middle-ear suppuration, trephining has practically been abandoned, and rightly so, since it has become recognized that the intracranial abscess is due to direct extension of the pyogenic infection from the middle-ear and mastoid cavities.

The only circumstances in which trephining may be advised are—(1) If the diagnosis be certain and the operator has no experience of aural surgery. In a case of emergency he is wiser, perhaps, to trephine and drain the abscess, leaving the mastoid to be dealt with afterwards by someone competent to do so. (2) If, after performing the mastoid operation, the situation of the abscess be doubtful. In order to diminish the risk of infection of the brain by an exploratory puncture which may prove negative, the bone may be trephined a little beyond the mastoid wound, either above or behind, according as a temporo-sphenoidal or cerebellar abscess is suspected. If, however, it be considered advisable to make a fresh opening in the bone beyond the septic wound cavity, the aural surgeon will probably prefer to do so by means of the gouge and bone-forceps, to which he is more accustomed.

Trephining has also been advised if the patient is so ill that a prolonged operation is impossible; or if there is cessation of respiration during the operation itself, which may occur in a cerebellar abscess as a result of pressure on the medullary respiratory centres. To those accustomed to perform the mastoid operation, the opening of this cavity and the necessary removal of bone can be done more rapidly by the gouge or bone-forceps than by the trephine.

For whatever reason trephining is done, it is afterwards essential to perform the mastoid operation and to remove the primary focus of the disease, otherwise one of the fundamental principles of surgery will be neglected.

Operation. The preliminary preparation of the patient is the same as for the mastoid operation, only the head should be shaved over a wider area. The exposure of the field of operation is the same whether

the brain is explored through a trephine opening or from an extension of the mastoid operation.

In the case of the temporo-sphenoidal lobe, it is necessary to extend the incision behind the auricle vertically upwards for an inch or more (Fig. 243); whereas if the cerebellum has to be explored, an incision is carried backwards at right angles to the post-aural incision, just below its mid-point (Fig. 244). In the former case, on reflecting the soft tissues from the underlying bone, the squamous portion of the temporal bone, immediately above the zygomatic ridge, will be exposed; in the latter, the base of the skull behind and below the mastoid process and lateral sinus will be laid bare.

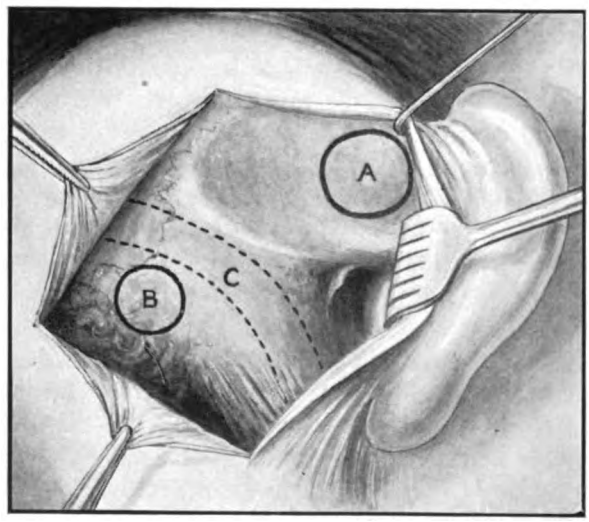

FIG. 242. TOPOGRAPHY OF THE AUDITORY REGION OF THE SKULL. A, Point of trephining for a temporo-sphenoidal abscess; B, For a cerebellar abscess; C, Dotted line marking a portion of the transverse sinus.

1. **Trephining.** The trephine used should be three-quarters of an inch to one inch in diameter according as the patient is a child or an adult. Either the hand trephine or Macewen's improved pattern mounted with a guard may be used. If available, the trephine may be worked by a motor, but in this case it should be remembered that the bone will be pierced more quickly than by the hand instrument.

Trephining for a temporo-sphenoidal abscess. The object of the operation is to expose the lowest portion of the middle fossa just above the roof of the tympanic antrum and tympanum. The trephine, therefore, should be placed so that it is situated just above the suprameatal spine, its lowest margin being slightly above the zygomatic ridge (Fig. 242). After the disk of bone has been removed the exploration of the abscess is then carried out.

Trephining for a cerebellar abscess. The point at which the bone is trephined must be behind and below the curve formed by the transverse and sigmoid portion of the transverse sinus; that is, behind the mastoid process and below Reid's base-line.

If the mastoid operation has not been performed, the centre pin of e trephine should be placed at a point 1½ to 1¼ inches behind the ntre of the external acoustic meatus, and an inch below Reid's base-e (Fig. 242). If, however, the mastoid has already been opened and e transverse sinus exposed, the trephine should be placed so that its terior border is just behind the sinus and its upper border well below id's base-line.

2. **After performing the mastoid operation.** If this has been done eady, the wound is pened, and cleansed filling it with drogen peroxide. ter gently curetting ay any granula-ns the wound cav-is irrigated and n packed in order dry it. Under good mination, careful pection is made to if a fistula or a ct of diseased bone tends in any direc-n. Whether the ddle or posterior ssa should first be plored depends not ly on the clinical mptoms but also on condition found opening the mas-d cavity.

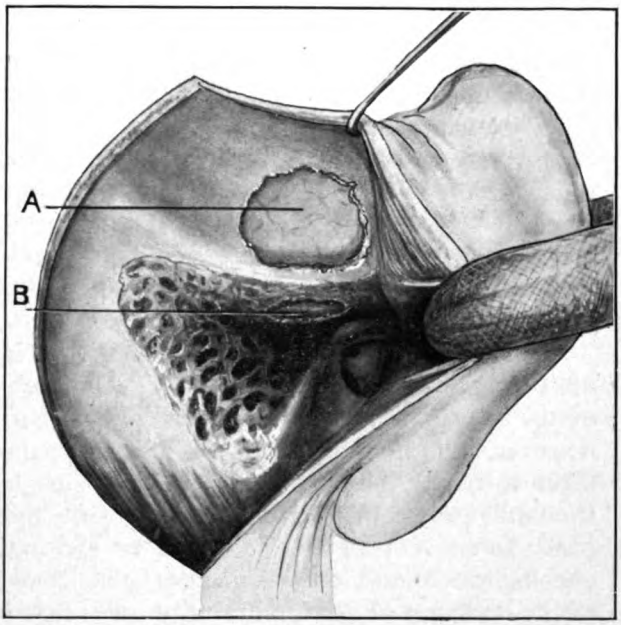

FIG. 243. EXPLORATION FOR A TEMPORO-SPHENOIDAL ABSCESS. A, Above the tegmen tympani; B, Through the tegmen tympani. Occasionally these methods are combined; the bone between the openings being also removed.

Opening of a tem-ro-sphenoidal abscess. A temporo-sphenoidal abscess may be explored ner through its lowest point, that is, through the roof of the antrum l floor of the middle fossa, or through its outer wall just above the gomatic ridge. To obtain a view of the roof of the antrum and stoid cavities, the head of the patient should lie almost flat on the erating table and be turned well over to the opposite side. The bony of of the tympanic antrum and mastoid is removed by means of the ge and mallet, and so exposes the dura mater covering the floor of middle fossa (Fig. 243). If a fistula communicates with the cavity

of the antrum and the middle fossa, the bone surrounding it is first attacked. In removing the bone, it must be remembered that the tegmen tympani is exceedingly thin, and unless care is taken, pieces of bone may be pressed inwards on to the overlying dura mater. Sufficient bone should be removed to determine whether the dura mater is normal or not. To do this it may be necessary to chisel away the tegmen tympani outwards until the squamous portion of the temporal bone is reached, after which a pair of bone-forceps may be used until a sufficient opening is obtained.

The condition found on examination of the dura mater varies. In many cases it is congested or covered with granulations at the site of the infection, and usually it is adherent to the underlying bone. At other times it seems normal.

Increase of the intracranial pressure, as shown by the bulging outwards of the dura mater, and absence of pulsation are suggestive of an abscess. These signs, however, are not conclusive, as on the one hand increased intracranial pressure may be due to other causes and on the other it is quite possible to have pulsation if the abscess be small and deeply placed.

If an extradural abscess be present, the intracranial cavity should not be explored at once unless this is absolutely necessary, but this step of the operation should be delayed for at least twenty-four hours. If, however, immediate operation be necessary, special precautions must be taken to render the part as aseptic as possible, and a fine layer of gauze should be packed between the margin of the bone and the dura mater in order to prevent further infection of the brain or meninges. In an uncomplicated case only sufficient bone should be removed to permit of the insertion of a large drainage tube; that is, the dura mater should not be exposed over a larger area than the size of a shilling.

If there be disease of the tegmen tympani and the symptoms point to a temporo-sphenoidal abscess, the brain should be explored through this opening in the bone (Fig. 243), as the abscess is thus not only drained through its most dependent part, but also through its stalk.

If, however, the diagnosis be doubtful, the temporo-sphenoidal lobe may be explored through a fresh opening, just above the tegmen tympani. This will diminish the risk of septic infection from the mastoid cavity. After the dura mater has been exposed sufficiently a small incision is made in it, taking care to avoid wounding any of the vessels. With a pair of forceps the cut edge of the dura mater is drawn outwards and the incision is prolonged in each direction with a pair of blunt-pointed scissors. Similarly, the dura mater is cut through at right angles to the

primary incision, so that four small flaps are made and turned back so as to expose the outer surface of the brain.

As a rule the dura mater, arachnoid, and pia mater are fused together by inflammatory adhesions, so that from a practical point of view they need hardly be considered as separate structures. Similarly, at the site of infection, the point of the so-called stalk of the abscess, the cerebral membranes are adherent to the underlying brain, especially if there has been any localised meningitis. For this reason it is sometimes necessary to peel away the dura mater from the brain, in order to expose the latter.

As a rule, very little fluid escapes; if present in considerable quantity, and if it escapes from between the dura mater and brain, it is an unfavourable sign, as it generally signifies early meningitis.

If meningitis be present, purulent lymph or secretion may be seen on the surface of the brain, either localised or spreading from the site of the infection.

If the intracranial pressure be great, the brain will bulge through the opening in the dura mater. If the abscess be very large and situated superficially, the thin layer of brain substance forming its outer wall may rupture as soon as an opening has been made in the dura mater. Sometimes, indeed, the pus may be seen to ooze through an opening in the dura mater, which may be found to communicate with the abscess cavity.

The next step is to open the abscess. Formerly a trocar and canula were used. This method is no longer in favour for the following reasons. If the wall of the abscess cavity be very thick, it may not be pierced; secondly, the trocar may pass through the abscess cavity and enter the brain substance beyond, without draining it; and thirdly, even if the trocar enters the abscess cavity the pus may be so thick as to plug its lumen. For these reasons a fine pair of Lister's sinus forceps or a narrow-bladed bistoury is recommended. In the ordinary case Lister's forceps can be used.

The direction in which the brain is explored depends upon the point at which this is done. Thus, if the procedure be carried out through the tegmen tympani, the brain is explored in an upward direction. The forceps are made to pierce the brain for about an inch; the blades are then slightly dilated and the forceps partly withdrawn. If a large abscess exists, the cavity is usually opened at once and pus flows out along the track of the forceps. If the abscess be small and deeply placed, its cavity may not be entered on the first thrust of the forceps. In this case they are closed and withdrawn. The brain is then explored by thrusting the forceps first upwards and forwards, then upwards and

backwards, and finally upwards and inwards; in the latter case it is unwise to pierce the brain for more than an inch and a quarter for fear of entering the lateral ventricle.

If the brain be explored through the outer wall of the temporo-sphenoidal lobe, the first direction in which this is carried out is directly inwards. If this be not successful, the brain is further explored in a direction forwards, upwards, or backwards, the exploratory instrument at the same time pointing slightly inwards.

If exploration proves negative, it may also be necessary to explore the cerebellum. If, however, the surgeon be still convinced that a temporo-sphenoidal abscess exists, he may next pierce the brain with the bistoury, in case the forceps has failed to enter the abscess cavity, perhaps owing to its walls being very thick. If all efforts fail to find the abscess, the little finger may be inserted into the brain itself to see if the resistant wall of an abscess can be felt. This procedure, however, should be avoided if possible, as by doing so it causes destruction of a certain amount of brain tissue.

On opening the abscess cavity a varying quantity of pus escapes, usually evil-smelling. In the more chronic cases it is thick and greenish; in the acute cases it may contain shreds of necrosed brain tissue or be intermixed with bubbles of gas. Sometimes there is also an escape of turbid cerebro-spinal fluid, which if excessive is suggestive either that the lateral ventricle has been opened inadvertently or that the abscess has already burst into it. In these cases the patient is usually comatose or in the state of muttering delirium at the time of the operation.

After the abscess has been opened, the forceps or bistoury should be retained in position until the pus has drained away. A large tube is then pushed into the abscess cavity along the line of the forceps or bistoury. It is only permissible to withdraw the instrument with which the abscess has been opened after the end of the tube is well within the cavity. The outer end of the tube should be flush with the surface of the wound. To prevent it slipping too far into the brain, it may be anchored to the edge of the dura mater by a silkworm-gut suture. If the abscess be drained through the tegmen tympani, it will be difficult to bring the tube out into the wound without kinking it. For this reason I prefer to incise the brain substance slightly outwards after the abscess cavity has been reached, so that a tube can be inserted obliquely upwards and inwards at a point corresponding to the angle between the tegmen tympani and the squamous portion of the temporal bone. If the exploratory puncture has been made above the tegmen tympani and an abscess discovered, the question arises whether another drainage tube should not also be inserted into the brain through an opening in the roof of the

antrum so as to drain the abscess from below. This, however, I do not think necessary.

In addition to the rubber tube, many varieties of drainage tubes have been suggested, such as decalcified chicken bone, as originally used by Macewen, and glass or silver tubes; the object of the latter being to resist the pressure of the brain, which may compress a rubber tube. The rubber tube is the simplest form of drainage, and if sufficiently thick it should be employed. To make more certain of free drainage, some surgeons use two tubes placed side by side. I think, however, one large tube (half an inch in diameter) is better than two small ones.

Irrigation of the abscess cavity is still a matter of opinion. If the abscess be small and circumscribed, the best method is to open it with as little disturbance as possible to the surrounding parts, insert a large drainage tube, and to do nothing further.

If, however, the abscess be large and irregular in shape, so that the drainage is not free, and especially if it be very septic and contains necrosed brain tissue, irrigation is justifiable if gently carried out. The best method is to insert a fine tube along the lumen of the large one and allow some warm saline solution to flow slowly along it into the abscess cavity, the fluid returning along the larger tube. If two tubes have already been inserted into the abscess cavity, the fluid injected through one will escape by the other. Whatever method is employed, care must be taken that there is free exit for the fluid, as otherwise the abscess cavity may become over-distended, and in consequence rupture of a portion of its wall may take place, especially the inner, which perhaps only consists of a thin layer of brain tissue separating the abscess from the lateral ventricle. During the act of irrigation there is a risk of some of the fluid, now loaded with septic particles, escaping between the surface of the brain and the dura mater and thus setting up a secondary meningitis.

Opening of a cerebellar abscess. The cerebellum may be explored from two different points, either in front or behind the transverse sinus. The posterior route is adopted if the abscess is superficial in the outer portion of the lateral lobe, usually the result of transverse sinus thrombosis or disease of the posterior mastoid cells. The anterior route is indicated if it is thought that the abscess is deeply placed in the anterior inferior portion of the cerebellum, that is, in those cases in which it is apparently a complication of labyrinthine suppuration, or the result of disease of the inner wall of the antrum and mastoid cavities (Fig. 244).

(*a*) *Behind the transverse sinus.* After exposure of the transverse sinus the bone is removed either by means of the gouge and mallet or by bone-forceps, until a considerable area of the dura mater is exposed

behind and below the curve of the sinus (Fig. 244). The dura mater is then incised as already described.

The cerebellum is explored by thrusting the instrument inwards for about an inch. As a rule the abscess is found at once. If it be not discovered at the first attempt, the instrument should be directed forwards, upwards, and inwards towards the posterior surface of the petrous bone. Care, however, must be taken that it is not pushed in too far, otherwise it may pierce the anterior upper margin of the cerebellum, and if an abscess be present, the meninges may thus become

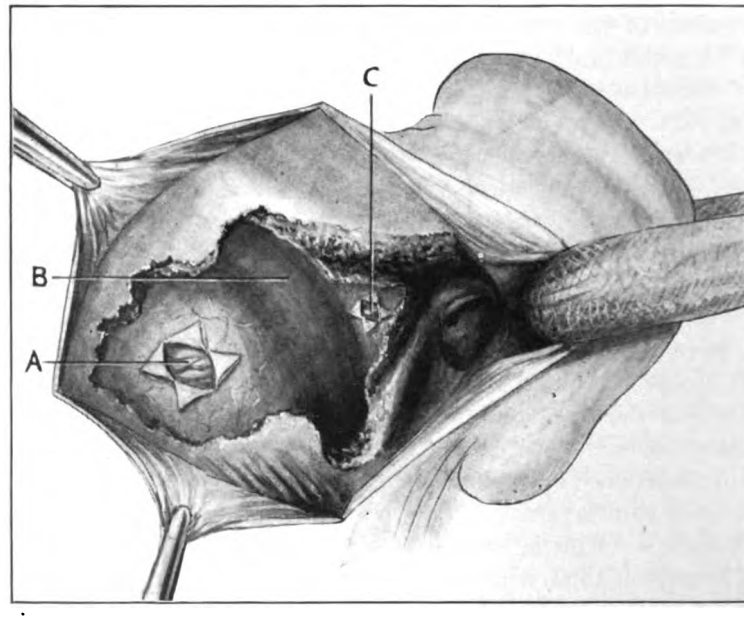

FIG. 244. EXPLORATION FOR A CEREBELLAR ABSCESS. A behind, and C in front of the transverse sinus; B, transverse sinus.

infected. If the surgeon has exposed the dura mater by trephining, it is necessary to push the exploratory instrument at least two inches inwards and forwards in order to reach an abscess situated in the anterior inferior portion of the cerebellum. In such cases it is by no means difficult to miss a small abscess, and further, drainage is frequently incomplete when an abscess is discovered. For this reason, if the cerebellum be first explored behind the transverse sinus and no abscess is discovered, it should further be explored by the anterior route in front of the transverse sinus. If the cerebellar abscess is secondary to transverse sinus thrombosis, and if there is no doubt as to the diagnosis, the

inner wall of the sinus should be made as aseptic as possible, and the dura mater forming it incised freely; the cerebellum being thus explored through the site of infection.

(*b*) *In front of the transverse sinus.* The transverse sinus is first exposed (Fig. 244). The triangular area of bone situated in front of it, between it and the semicircular ducts and forming the inner boundary of the antrum and mastoid cells, is now removed with the gouge and mallet or with a suitable pair of forceps. If it be certain that internal-ear suppuration exists, or if the operation be secondary to opening of the labyrinth, the posterior wall of the petrous bone may be removed until the internal acoustic meatus is almost reached. If, however, the labyrinth be intact, care must be taken not to chisel away too much bone for fear of encroaching on the posterior semicircular duct. On exposure of the dura mater an extradural abscess may be met with, usually the result of internal-ear suppuration. Even if no pus be seen, it is always a wise precaution, if internal-ear suppuration co-exists, to separate the dura mater from the posterior wall of the petrous bone by means of an elevator in order to prevent any deeply situated extradural abscess being missed. After the dura mater has been exposed sufficiently it is opened by a crucial incision. In this region absence of increased tension within the brain and lack of bulging outwards of the cerebellar tissue do not necessarily imply the abscence of an abscess; the cerebellum to all appearances may appear normal and flaccid, although a small abscess may be present.

The cerebellum is explored in various directions to a distance of not more than one inch. After the pus has been evacuated a tube is inserted as described above. In the majority of cases this method is far superior to opening the cerebellum behind the transverse sinus, especially as it is now recognized that the chief cause of cerebellar abscess is internal-ear suppuration.

After-treatment. This is similar to that of any ordinary abscess, but care must be taken that free drainage is maintained. The main part of the mastoid wound is lightly plugged with gauze, the tube inserted into the brain abscess being brought flush with the surface of the skin. The gauze filling the wound cavity should be arranged around the tube so that its rests comfortably within the wound and is not kinked. If the drainage tube be in its proper position, pus should be seen to ooze out of it.

Although the mastoid cavity itself need not be dressed daily, if necessary the outer dressings may be removed twice a day, in order to see that drainage of the abscess is continuous. After the first two or three days, the tube is gradually shortened. If the abscess be a recent one and not encapsulated, it becomes rapidly obliterated by pressure of the

surrounding brain tissue, so that the tube may be forcibly ejected within a few days. On the other hand, if the abscess has existed for a considerable period and is bounded by a thick wall, which may be extremely resistant, the purulent discharge may continue for many days and necessitate the continuance of drainage. Generally speaking, the tube may be shortened every second or third day, and can usually be dispensed with by the end of the second week, if not before. It is, however, very necessary that the tube should not be withdrawn until it is certain that the abscess cavity has been obliterated completely.

The general treatment of the case in no way differs from that already described for the mastoid operation in which the wound has been left open posteriorly.

Complications. (i) On turning back the flaps of the dura mater, a hernia, consisting of friable congested brain tissue, may occur at once. This is extremely rare as a result of a simple abscess of the brain, but is significant of encephalitis frequently associated with meningitis (see p. 468). If an abscess be suspected, the brain should be explored as already described. If, however, no abscess be discovered, the treatment consists in removal of more bone and further incision of the dura mater, in order to permit of free drainage and to relieve tension.

(ii) Opening into the lateral ventricle. This may be due to rupture of its wall owing to the sudden diminution of pressure from too rapid drainage of the abscess cavity, or it may occur accidentally from thrusting in the exploratory instrument or drainage tube too deeply. Its occurrence is evidenced by the sudden gush of cerebro-spinal fluid. The ultimate danger is subsequent infection of the cavity, which, unfortunately, frequently occurs.

(iii) Cessation of breathing. This is more likely to occur in a cerebellar abscess in consequence of direct pressure on the medullary respiratory centres. The immediate treatment is to do artificial respiration and to open the cerebellar abscess by the quickest method possible. If this be successful, respiration probably will be restored.

Prognosis and subsequent progress. In an uncomplicated case a favourable prognosis may be expected, provided the abscess is successfully opened and drained without much disturbance of the surrounding parts. Many factors, however, may lead to a fatal result. With regard to recovery: in 100 cases taken from the records of the London Hospital during a period of ten years, recovery took place in 20% operated on for cerebral and 10% for cerebellar abscess. Other statistics give a much higher percentage of recovery, but it must be remembered that in hospital patients a large number of the cases are only seen by the surgeon at a very late stage, when the brain abscess is complicated by other

racranial or suppurative lesions, and the patient is in an almost mori-nd condition; so that the operation may only have been undertaken as a rlorn hope.

If the operation is going to be successful, the head symptoms quickly sappear. Even if the patient was comatose before operation, the covery may be so rapid that his mental condition may be almost rmal within twenty-four hours. In many cases, if the abscess be a ge one, convalescence will be tedious or prolonged; sometimes, indeed, mplete restoration of the mental faculties, in spite of a most successful eration, will not be obtained. The chief relief to the patient is the ssation of the terrible headaches from which he has been suffering.

Unfavourable symptoms are the sudden onset of pyrexia accom-nied by delirium usually the result of diffuse meningitis, or of infection the lateral ventricles. In the latter case there is a rapid termination drowsiness, coma, and death.

Although the brain abscess may be draining freely, the patient for me days may lie in a semi-comatose condition as a result of œdema inflammation of the surrounding brain tissue; in such cases prognosis difficult, but hope of recovery may be entertained if the pulse and nperature keep practically normal.

Recurrence of symptoms. This may take place within the st few days after the operation as a result of infective cerebritis, the esence of another abscess, or faulty drainage; or at a much later period, ing to the formation of another abscess or to a cyst within the brain the site of the former abscess.

If the recurrence of the symptoms appears immediately after the eration, the wound should be inspected carefully, if necessary under anæsthetic. If drainage be not free, the tube should be removed and air of forceps inserted along the track leading into the abscess, their des being then slightly opened and withdrawn. On doing this an cumulation of pus may escape. The cavity may then be irrigated ntly with saline solution and a larger tube inserted.

If, however, this procedure does not give a satisfactory result, the ger may be inserted into the brain to feel if the abscess is loculated. this means any existing septa may be broken through; or if a feeling resistance suggests the presence of another abscess, this part of the in can also be explored. It must also be remembered that although emporo-sphenoidal abscess has been opened successfully and is drain-; well, the continuance of the symptoms may be due to a co-existing scess of the cerebellum, or *vice versa;* in other cases, in spite of all e, the patient gradually sinks, partly from exhaustion and partly from neral toxæmia, the result of infective cerebritis.

2. Recurrence of symptoms at a later period. The occurrence of a fresh abscess is usually owing to the fact that the primary focus of the disease has not been completely removed at the first operation; for instance, if the surgeon only trephined and drained the abscess without performing the mastoid operation.

A cyst is usually the result of the abscess having been encapsulated and its wall not having been removed at the first operation. If a cyst be discovered on exploring the brain in consequence of these symptoms, its wall should be removed if possible.

Apart from symptoms of intracranial pressure, the patient may suffer from attacks of Jacksonian epilepsy from time to time, presumably due to the post-operative adhesions. If they continue in spite of conservative treatment, it may become necessary to operate in order to remove this source of irritation.

SECTION V

OPERATIONS UPON THE LARYNX AND TRACHEA

BY

W. DOUGLAS HARMER, M.C. (Cantab.). F.R.C.S. (Eng.),
Captain R.A.M.C.(T.)

Surgeon to the Throat and Nose Department, St. Bartholomew's Hospital

CHAPTER I

ENDOLARYNGEAL OPERATIONS

Indications. (i) *Tumours.* Tumours of the larynx are more often innocent than malignant. Sir F. Semon[1] collected 12,297 cases seen between 1862 and 1888 by 107 laryngologists, and of these 10,747 (or 88%) were benign and 1,550 (or 12%) were malignant. Of the innocent forms, papilloma, either simple or multiple, occurred in 39%; fibroma, sessile or pedunculated, was next in frequency; cystic tumours were not nearly so common; and other forms, including myxoma, angeioma, adenoma, lipoma, and enchondroma, were rare. The period during which these tumours are most common is between the ages of 20 and 40 years, but they are also frequent during childhood.

Malignant growths occur at a later age, mostly between the ages of 40 and 60, and attack males more than females. Carcinoma is far more common than sarcoma, and is generally of the squamous-celled variety. Endothelioma has not often been discovered.

The importance of distinguishing innocent from malignant tumours is greater now than in former years, since it is agreed that endolaryngeal operations are preferable for the eradication of the former, while the latter are better treated by extra-laryngeal methods. Moreover, the differential diagnosis has steadily improved, owing to the more general use of the laryngoscope and the introduction of recent methods of examination. Thus, by direct laryngoscopy it is possible to investigate children as easily as adults. Microscopical examination of fragments removed with laryngeal forceps is of great value in confirming the clinical diagnosis; the sections can be made by freezing, or in paraffin, the latter method requiring, with recent improvements, not more than twenty-four hours. Semon, who has done more than any other man to improve the early diagnosis of malignant disease of the larynx, is strongly in favour of such examinations. It must be remembered, however, that the result is sometimes inconclusive, for it is difficult to be certain that the actual growth has been removed. In cases that are thought to be malignant, it is better to open the thyreoid cartilage than to rely upon endolaryngeal operation, as there is a danger of stimulating the growth to greater

[1] *Internat. Centralblatt für Laryngol.*, Jahrgang v u. vi, 1888–9, 'Die Frage des Ueberganges gutartiger Kehlkopfgeschwülste in bösartige, speciell nach intralaryngealen Operationen.'

activity, especially by repeated interference. When the thyreoid cartilage has been opened, the whole disease can be explored thoroughly and a fragment selected from which to make a frozen section. In the majority of cases a definite diagnosis can thus be arrived at, and even when it is necessary to examine several fragments the amount of time lost is small.

As regards the value of skiagraphy, Walsham and myself have found that photographs can be made of tumours of the larynx which in some instances determine accurately the position and extent of the disease. Fig. 245 is a photograph showing a cancer of the upper opening of the

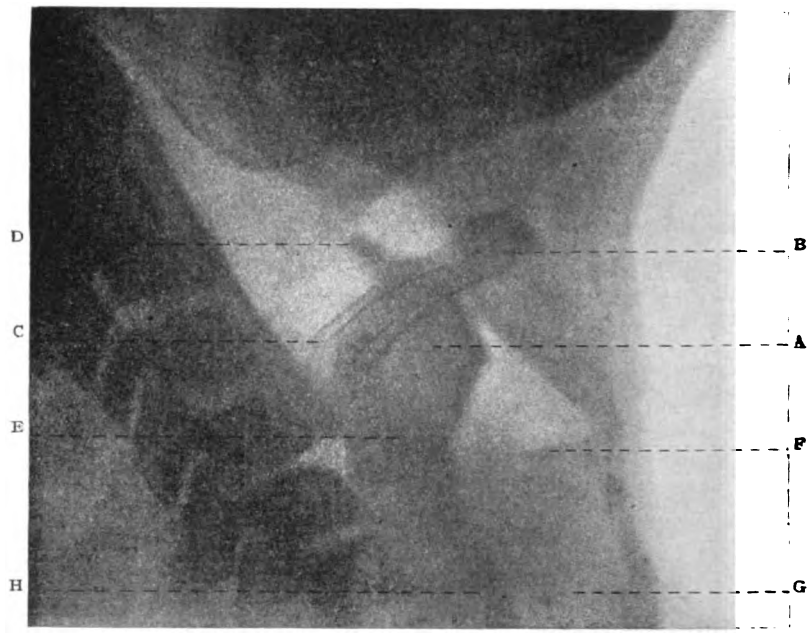

FIG. 245. SKIAGRAM SHOWING A TUMOUR OF THE LARYNX. A, Tumour; B, Body of hyoid; C, Greater cornu of hyoid; D, Epiglottis; E, Posterior plate of cricoid; F, Vocal fold; G, Trachea; H, Œsophagus.

larynx, lying above the vocal folds, the position of which was proved to be accurate by later operation upon the patient. It is, however, doubtful whether the method will eventually assist in the differential diagnosis between innocent and malignant growths.

(ii) *Tuberculosis.* Endolaryngeal operations are successfully performed for chronic conditions such as ulceration or tumour, and, rarely, in acute forms such as abscess, necrosis, and the like. Removal of a portion of the epiglottis occasionally gives great relief to a patient who is suffering from dysphagia.

(iii) *Strictures* resulting from trauma, from the ulcerations of philis, diphtheria, and other inflammatory diseases, or caused by connital webs.

(iv) *Foreign bodies* impacted in the larynx.

(v) *Œdema* of the mucous membrane due to trauma or inflammation, cal abscess, necrosis, and other allied conditions, in which obstruction likely to supervene.

The operation may be performed either by indirect or by direct ryngoscopy.

OPERATION BY INDIRECT LARYNGOSCOPY

It being essential that the patient should be tolerant, this method chiefly applicable in the case of adults. The operation may require course of instruction, but this presents no difficulty if given with distion. The employment of cocaine, novocaine, and adrenalin is of the eatest importance to both surgeon and patient. Cocaine, which is nerally to be preferred, may be used in strong solutions—10 or even %—if applied to the mucosa by a small swab of wool; but, if used as spray, weaker solutions are employed (4%). With neurotic patients caine must be applied cautiously, as a sense of suffocation is sometimes oduced. It is necessary first to treat the soft palate, the uvula, base the tongue, pharynx, and epiglottis; secondly, with the help of a ryngeal mirror, the interior of the larynx must be cocainized; this can accomplished by expelling a few drops of the solution from a laryngeal ringe or by means of a swab attached to a suitable wool-carrier. fteen to twenty minutes must be allowed to gain the full effect of æsthesia. The patient must be instructed on no account to swallow e saliva. The secret of successful intralaryngeal operations lies in e thorough application of these principles, and in not attempting the eration until the patient is able to tolerate the presence of an instrument ithin the larynx. The surgeon must be experienced in the use of ryngeal instruments, and must be provided with a complete equipment, cluding forceps (Mackenzie's, Whistler's, Grant's, &c.), which must be different lengths to suit the patient, snares, galvano-cautery, curettes, obes, and other instruments for the application of drugs. Proper umination is also very important.

When removing an intralaryngeal growth, the surgeon sits facing e patient. The mouth is opened to the fullest extent, and the tongue awn well forward and held by the patient's right hand. The mirror introduced in such a way that the tumour is distinctly seen. If the iglottis overhangs, it can be drawn forward with the forceps; or, in re instances, a special instrument (Fig. 246) can be used for transfixing

its upper margin with a thread, the latter being grasped by a pair of pressure forceps, which, being allowed to hang, will automatically raise the obstruction.

The forceps, having been warmed, are taken in the right hand when the tumour is on the right side of the larynx and in the left hand when the tumour is on the left, thus allowing a clearer view than when the same hand is employed irrespective of the position of the disease. It is introduced as follows: firstly, the handle is directed towards the patient's left ear until the point of the forceps has passed beyond the back of the tongue and lies behind the epiglottis; secondly, the instrument is quickly rotated so that the handle lies below the chin; thirdly, the hand is raised so that the point is directed forwards; fourthly, the whole instrument is quickly lowered and the beak of the forceps directed towards the growth. This manipulation is made more difficult by the laryngeal image being reversed in an antero-posterior direction.

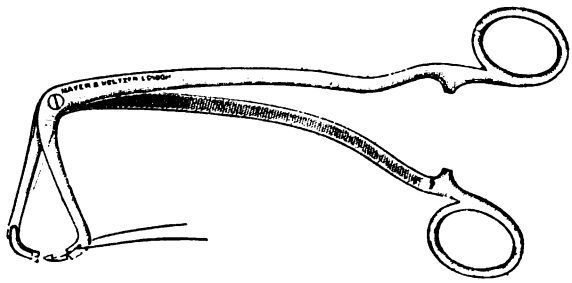

FIG. 246. HORSFORD'S INSTRUMENT FOR TRANSFIXING THE EPIGLOTTIS.

When the point is seen to rest upon the growth, the instrument is opened, and the tumour grasped and avulsed: with careful manipulation there is little danger of wounding the normal mucosa, and hæmorrhage is insignificant. When dealing with multiple growths the patient must understand that it may be necessary to repeat the operation, either immediately or after an interval. Given suitable instruments, sufficient experience, and a tolerant patient, it is possible to remove, with the help of cocaine, the majority of simple tumours. Operations upon cysts, the scarification of mucous membrane with a guarded knife, the curettement of tuberculous ulcers, and cauterization of the larynx, are all conducted upon similar lines. Foreign bodies can sometimes be removed with forceps; thus, F. A. Rose[1] reported a case in which part of the breast bone of a chicken, measuring 1 inch in length and over ¾ of an inch in width, was removed after having been impacted in the larynx for nearly forty-eight hours. In most instances such an operation is not advised; *e. g.* with a foreign body firmly impacted, multiple papillomata, or an intolerant patient, general anæsthesia is preferred, so that removal may be effected through a tube-spatula or by external incision.

[1] *Proc. Roy. Soc. Med.*, London, vol. i, No. 2, Laryn. Sect., p. 5, 1907–8.

After-treatment. Intralaryngeal wounds generally heal well, but ery effort should be made to prevent infection of the parts, to allay ıy inflammation that may arise, and to avoid catarrh and swelling of e mucosa. It is advisable to order complete vocal rest until the redness ıs subsided, and the patient should refrain from coughing; the sucking ice, or the inhalation of benzoin or other medicated steam, has a seda- ve action upon the parts. If the larynx becomes septic or filled with irri- ting discharge, the use of sprays or powders is indicated; in such a case e patient may be given a parolein spray, with menthol, eucalyptus, or her antiseptic, for constant use; or a powder such as orthoform, the tter being sucked into the larynx through a warmed glass tube (Leduc's sufflator), or applied by the surgeon. In the later stages the patient ay be treated by the local application of caustic fluids, or by galvano- utery, as occasion requires. The success of such operations depends rgely upon the skill of the surgeon; if attention be given to the after- eatment the results are very good, and the voice is generally recovered. s Semon has shown conclusively, there is no practical danger of the ccurrence of malignant degeneration through the influence of instru- entation.

OPERATION BY DIRECT LARYNGOSCOPY [1]

Indications. (i) *Multiple papillomata.* These tumours occur ost commonly during the early years of life, and operations for their moval present great difficulties, first, in their removal, and, secondly, ving to their inveterate tendency to recurrence whatever operation performed; moreover, in some instances operation seems to stimulate e growths to greater activity. The case reported by Stoker is a well- own instance. He was consulted by a man thirty years of age who ıd suffered from papilloma for twenty-three years, during which period ıe surgeon had performed 100, and a second 120 operations.

(ii) *Benign tumours* other than papillomata, which are not amenable operation by indirect laryngoscopy.

(iii) *Foreign bodies.* Direct laryngoscopy is advised for patients who e intolerant (*e. g.* young children), or when the object is firmly im- ıcted, or when other methods of treatment have failed. Thus in one my cases a man presented himself with a long pin impacted trans- ersely above the vocal folds; it was found impossible to remove it by direct laryngoscopy without serious injury to the parts. An anæsthetic as therefore given and a large tube-spatula passed into the larynx: ith strong forceps the pin was bent upwards and removed with ease.

[1] Bruenings, W., *Direct Laryngoscopy, Bronchoscopy, and Œsophagoscopy,* nglish edition, translated by W. G. Howarth, 1912.

(iv) *Granulations, ulcers, necrosis, and other inflammatory conditions* such as are caused by diphtheria, tubercle, syphilis, and many other diseases.

(v) *For diagnostic purposes.* Direct laryngoscopy is of the greatest value in determining the nature of doubtful laryngeal conditions. If the upper parts of the larynx be swollen, if there be any stenosis such as follows ulceration, or if the patient be intolerant, the air-passages cannot be thoroughly examined with the laryngoscope alone. With the newer method many of these difficulties have disappeared, and it is now possible for the surgeon to diagnose with certainty many conditions which would otherwise have remained doubtful.

FIG. 247. MULTIPLE PAPILLOMATA OF THE LARYNX. (*From Specimen No. 1647 in the Museum of St. Bartholomew's Hospital.*)

The apparatus required consists of: (*a*) The *tube-spatulæ.* The tube originally suggested by Killian was made of straight metal and circular in section, the distal end being cut obliquely with the projecting portion fashioned like a spatula. A strong handle, at right angles to the tube, was used for manipulation. Different sizes were required for children and adults. Various modifications of these tubes are now in use, notably those of Bruenings, Jackson, Mosher, and Hill: the instrument recommended by the former is easier to manipulate and gives a better view than the earlier forms described.

(*b*) The *lamp* for illumination. Different forms of head-lamp (Killian's, Kirstein's) and hand-lamp (Caspar's) have been devised for illumination from the outside, and Chevalier Jackson has invented a lamp which is sufficiently small to pass to the distal end of the tube, where it lies in a compartment of its own lest it should be broken and fall into the trachea. Recently these electroscopes have been improved upon by Bruenings and Kahler. In these instruments the lamps are more powerful and are attached to the handles in such a manner that they can be easily swung into position when

required. A condensing lens has also been added and the light can be focused to any desired distance. If preferred, an ordinary forehead-

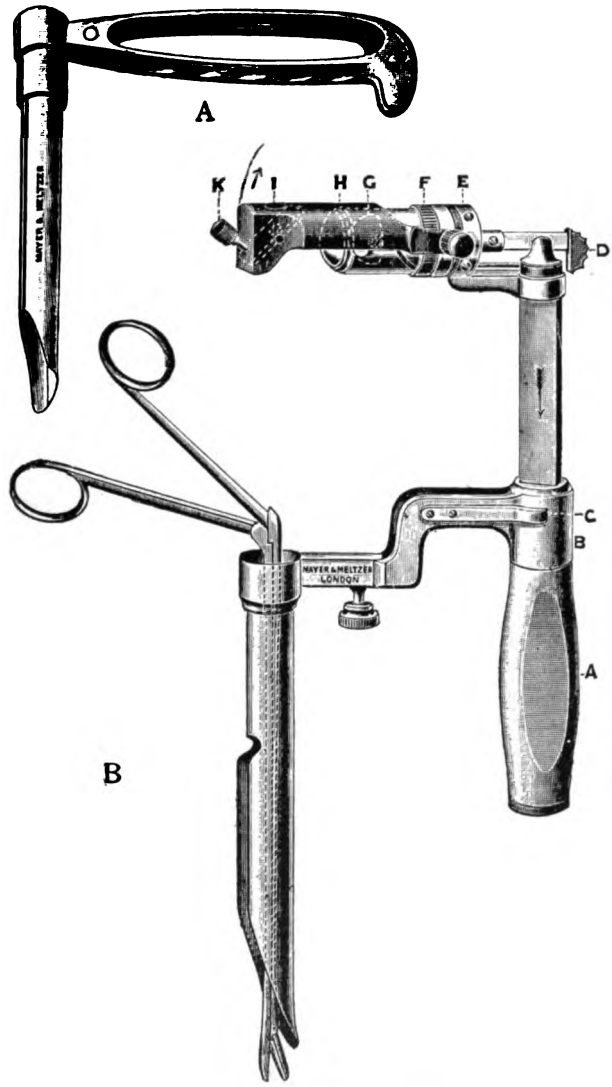

FIG. 248. TUBE-SPATULÆ USED FOR LARYNGOSCOPY. A, Killian's. B, Bruenings'. A, Handle; B, Collar to allow rotation; C, Fixation spring; D, Switch: E, Socket for lamp; F, Focus; G, Lamp; H, Lens; I, Aperture for eye; K, Reflector.

mirror reflecting the light from a powerful Nernst lamp (100 c. p.) can be employed.

(*c*) The *instruments* for operation. Various forms of forceps for removal of tumours have been devised by Killian, von Eicken, Bruenings, Patterson, and many others. In any form that is employed it is necessary, in order to allow of clear vision, that the handle should be set at an angle with the shaft. For foreign bodies, hooks of different shapes are also useful. Other requirements include a gag for opening the mouth, a tongue depressor, tongue forceps, suitable cotton-wool carriers, the requisites for tracheotomy, and a darkened room.

Operation. The operation can be performed with local or general anæsthesia. With patients who are intolerant chloroform is more reliable, and is preferable to other drugs, which tend to excite secretion. Chloroform should always be employed for children. It should be given slowly and in the smallest possible quantity, the head of the patient being kept lower than the body to allow blood and mucus to drain away from the trachea. To make the parts more tolerant, cocaine can also be applied to the vocal folds, or a dose of morphine and atropine (codeine is advised in children) can be given half an hour before the operation. The importance of a skilled anæsthetist cannot be too strongly emphasized (see p. 602). With chloroform, the patient should lie upon the back or right side, with the head projecting beyond the end of the table, so that the neck can be extended as required. With cocaine the upright position is often preferred, and the patient should sit on a low stool facing the surgeon. When the patient is recumbent, the surgeon should sit or kneel behind the head. He should observe the strictest aseptic precautions, and should introduce no instrument which has not been properly sterilized; further, the tubes should be previously warmed to prevent 'fogging', and oiled with sterilized liquid paraffin before introduction. There should be two assistants, one (the chloroformist) to support the head and watch the respiration and pulse, the other to help with instruments.

In order to examine the larynx, the mouth is opened by a gag, and the tube-spatula is passed to the upper border of the epiglottis; when this has been inspected the spatula is pushed behind it, and the upper portion of the cricoid plate is examined; the tongue is then pressed forward by the tube so that the larynx can be seen. The examination should be methodical, and should include the vocal folds, ventricular folds, and openings of the ventricles. The whole manipulation can be performed with great delicacy, and is entirely guided by the eye, so that there is little fear of injury even in young children.

In this and the further technique the chief difficulties are caused by: (*a*) *The prominence of the upper teeth.* This may seriously interfere with the easy passage of a straight tube, even when the neck is fully

tended. The difficulty can be overcome by turning the head laterally, that the tube passes through the opposite angle of the mouth, or use of counter-pressure on the front of the larynx which renders toscopy easier for the erator and patient (Fig. 9). (*b*) *The mucus,* nich collects in the tube d obstructs the vision. his must be overcome using a secretion as-rator, by frequent onging, or, as suggested Ingals, by giving a evious dose of atropin.) *Intolerance of the rts,* which can be coun-racted by the judicious e of cocaine (10%). may be noted that this mbination of chloro-rm and cocaine is not ngerous, even in young ildren, so long as the caine is prevented from nning into the pharynx. The condition of the rynx having been oroughly examined, the eration can proceed. he method of removing ultiple papillomata will st be described. In me cases it will be found at better exposure of e tumours is obtained the end of the tube is aced above the epiglottis ther than in the larynx elf. The position of the growths having been determined, a suitable rceps is selected and introduced through the tube. The papillomata e seized and avulsed separately, without injury to the normal tissues. o arrest the bleeding it may be necessary to apply cocaine and adrenalin

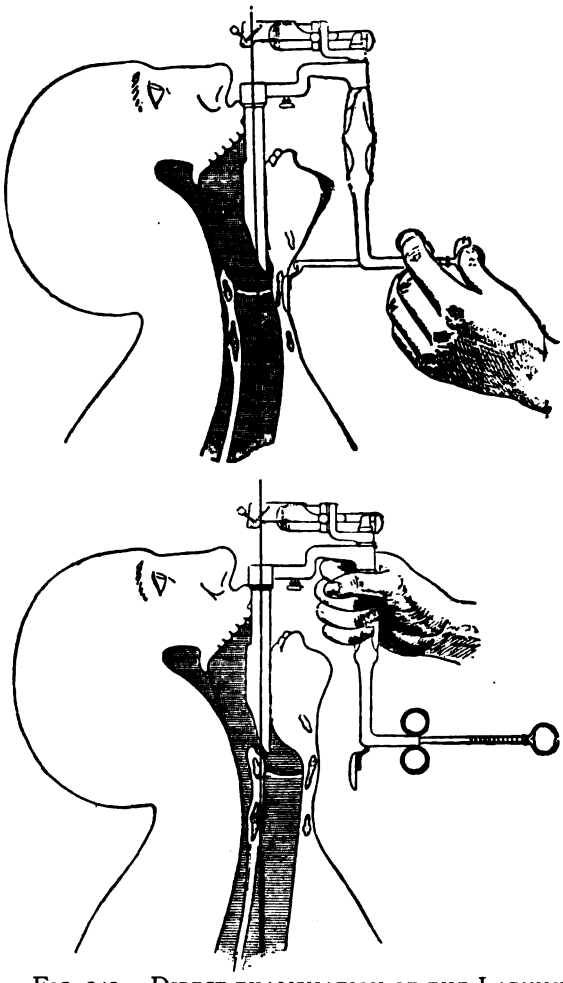

FIG. 249. DIRECT EXAMINATION OF THE LARYNX BY BRUENINGS' COUNTER-PRESSURE METHOD (*from Direct Laryngoscopy, Bronchoscopy and Œsophagoscopy* by Bruenings, translated by W. G. Howarth, 1912).

mixture, and to raise the foot of the table so that the blood drains away from the field of operation. As far as possible, all the growths should be removed; it may be difficult to attack those which are situated in the anterior commissure or subglottic region, but this difficulty may be overcome by the use of specially devised instruments; thus, von Eicken has invented a tube which is long enough to pass through the larynx and into the trachea, the portion lying in the larynx being provided with a lateral window which can be turned in any direction, so that a growth can be made to project into the tube, where it can be easily removed.

At any moment during this operation the surgeon may be called upon to push the endoscope between the vocal folds into the trachea or to perform tracheotomy.

After-treatment. This must be carried out upon the same lines as those already suggested; everything must be done to relieve congestion and irritation. Killian advises internal administration of arsenic for a period of several months, and, if this fails, potassium iodide in large doses. It should be remembered that in some instances syphilis seems to play an important part in the causation of these conditions. Ingersole suggests that X-rays prevent recurrence, and may even cause shrinkage of existing growths.

Recurrence occurs in most cases in some degree, and requires further operation; this may be carried out after an interval of a week or longer, according to the case. At these secondary operations it may not be necessary to use the forceps; local applications such as absolute alcohol, salicylic acid in absolute alcohol (2–10%), solutions of silver nitrate or chromic acid, and many other drugs, have been advised by different surgeons. Wylie is strongly in favour of the galvano-cautery, and is of opinion that the technique is more reliable and the liability to local infectivity diminished. If the latter method be employed, very little should be done at one sitting, otherwise great inflammatory reaction may be set up, entailing tracheotomy. A tracheotomy tube may be required for a short time while such treatment is being carried out: some surgeons, with whom the author does not agree, always perform preliminary tracheotomy, and claim that the papillomata are less likely to recur if complete rest is thus given to the larynx.

Results. In discussing the value of the above method it is necessary to refer to the results obtained by other operations, such as—

(i) *Tracheotomy* (see p. 563). This operation has been advocated as a method of curing papillomata. It has been noted that by giving rest to the larynx the congestion is relieved, the papillomata decrease in size, and in some cases completely disappear. Mackenzie [1] published

[1] *Brit. Med. Journ.*, 1901, vol. ii, p. 883.

even cases which he had had under observation for a minimum of two ears, with four recoveries, the canula having been worn for periods arying from six to fifteen months. He also mentioned thirteen other ases in which good results had been obtained by other surgeons, and was f opinion that the method was most successful with 'virgin' cases. here are, however, many objections to this form of treatment. For stance, it is often necessary to retain the tube for a prolonged period, vo years or longer, and even then the result is doubtful; moreover, the rolonged use of a canula is disastrous to the larynx, not only in retarding evelopment, but also in the production of stenosis; there is also a danger f bronchitis, of broncho-pneumonia, and possibly of tuberculosis. In gard to the last, G. A. Wright,[1] in reporting a case in which tubercle pervened, argues that 'presumably there is more risk of this happening the wearer of a tracheotomy tube than when breathing in a normal way rough the mouth or nose.' Further, the line of treatment is difficult enforce on account of the aversion shared by most parents to the rformance of tracheotomy.

(ii) *Laryngo-fissure* (see p. 525). Under this head are included thy-otomy, or complete division of the thyreoid cartilage; partial thyrotomy, here a small portion of the upper or lower part of the thyreoid cartilage left intact (an operation which does not give a good exposure of the rynx); infra-thyreoid laryngotomy, which is only applicable to adults; icotomy, with division of the cricoid cartilage and crico-thyreoid embrane; and sub-hyoid pharyngotomy. Of the above, thyrotomy the most satisfactory operation, because it gives the best exposure of e parts and facilitates removal of the growths; recurrence, however, frequent, permanent injury to the voice is common, and stenosis may sult.

The results of these operations, especially during childhood, are by means satisfactory. In the statistics carried up to 1896, collected by osenberg and von Bruns,[2] laryngotomy was performed 143 times on 99 children; 11 were operated upon twice, 3 children three times, and child seventeen times. 52 of the children were under 4 years of e; 20 died, principally from suffocation with recurrent papillomata; showed recurrences after repeated operation; 40 were cured (*i. e.* 6%), d of these 10 showed disturbance of voice.

It must be admitted that operations for the treatment of papillomata not meet with any great measure of success. It seems probable, wever, that the results obtained by endolaryngeal removal are better an those obtained by either tracheotomy or laryngo-fissure. To quote

[1] Ashby and Wright, *Dis. of Child.*, 4th ed., p. 350.
[2] Bergmann, E. von, *Sys. Pract. Surg.*, vol. ii, p. 231.

Killian[1]: 'Formerly, and especially from the standpoint of the surgeon, laryngotomy for laryngeal papillomata was very frequently done in little children in whom removal was impossible by endolaryngeal methods. In my judgment, direct laryngoscopy renders such a surgical procedure unnecessary. We can in all cases, with the aid of a tube-spatula under narcosis, remove papillomata, and the operation can be repeated as often as seems necessary.' These remarks express the general feeling of the present day, and the most important factor in determining the success of operative treatment is early diagnosis. Such diagnosis divides the cases into two classes: those in which the growths are localised, and those in which they are diffuse. The first class is easy to treat by endolaryngeal methods, and, given careful after-treatment, the prognosis is satisfactory. The second class is serious, and far more difficult to treat; when Killian's method fails the prognosis is very bad. Finally, it must be borne in mind that, as recurrence may not occur for several months, a guarded prognosis must be given in every case.

(iii) *Radium*. The treatment of papillomata by radium is of more recent origin, but the first results seem promising, and it is possible that the method will supersede all others and that operations will be unnecessary in the majority of cases. T. J. Harris, of New York, has collected thirteen cases treated by laryngologists in different countries. In the earlier cases 15 to 20 mg. of radium was used and recurrences were common. Six cases treated more recently in New York with 100 mg. of the salt with stronger radio-activity appear to have been cured. It was noted that there was no immediate change in the size of the tumours and some patients required many applications, one case having fifteen sittings of nine hours. Even after prolonged treatment there was no reaction or sloughing of the parts.

The removal of other benign tumours and of foreign bodies, and the treatment of granulations, are conducted upon similar lines, and are attended with excellent results.

[1] *Trans. Amer. Laryng. Assoc.*, 1907, p. 127. Discussion of paper by C. G. Coakley on 'Removal of papillomata of the larynx by direct instrumentation with the aid of Killian's tubes.'

CHAPTER II

EXTRA-LARYNGEAL OPERATIONS

THYROTOMY

Indications. This operation is performed for two purposes:

(i) To obtain access to the cavity of the larynx when the diagnosis is certain, or as a preliminary to other operations.

(ii) As a method of eradicating certain diseases, of which the following are important:—

1. *Malignant tumours,* both carcinoma and sarcoma, in which an early diagnosis has been made, and so long as they remain intrinsic.

It is advisable to follow Krishaber in the separation of all forms of laryngeal cancer into two classes, the *Intrinsic* and the *Extrinsic*. The term 'intrinsic' implies a growth springing from the vocal folds, the ventricular folds, the sinuses of the larynx, or the subglottic space, and the growth must lie entirely within the laryngeal cavity. 'Extrinsic' is the term used for a growth affecting the arytænoids, the posterior part of the cricoid cartilage, the arytæno-epiglottic fold, or the epiglottis. Such a growth is not entirely limited to the larynx, but also involves some part of the pharynx.

2. *Extrinsic localised malignant tumours* which are attached to the epiglottis, or to the arytæno-epiglottic fold.

3. *Innocent tumours* which are too extensive for endolaryngeal operation or are of a doubtful character. In either of these cases it is justifiable to perform an external operation, which may be thyrotomy, or occasionally, an atypical operation: thus Semon[1] removed a large papillomatous tumour of the larynx by submucous resection, without opening the cavity of the larynx.

4. *Stenosis* following syphilis, trauma, acute exanthemata, scleroma, and other rare diseases. C. Jackson has reported twenty-four cases coming under this head, nineteen of which lived more than a year after the operation with useful voices. If the surgeon is satisfied that the disease is quiescent, he should point out to the patient that it may be possible to cure the obstruction by thyrotomy. It must, however, be remembered that tertiary syphilitic lesions may again become active as a result of operative interference. It is probable that slight cases

[1] *Brit. Med. Journ.*, 1905, vol. i, p. 6.

of stenosis can be treated better by intubation than by thyrotomy. Thyrotomy has also been suggested to relieve stenosis caused by double abductor paralysis of the vocal folds, but such cases are better treated by tracheotomy or intubation.

5. *Foreign bodies.* Thyrotomy is rarely necessary, and should be reserved for irregular or sharp-pointed bodies, such as tooth-plates or bones, which are so firmly jammed that removal by other methods is

FIG. 250. INTRINSIC TUMOUR OF THE LARYNX. (*From Specimen No.* 1649 *in the Museum of St. Bartholomew's Hospital.*)

FIG. 251. EXTRINSIC TUMOUR OF THE LARNYX. (*From Specimen No.* 1653 *in the Museum of St. Bartholomew's Hospital.*)

impracticable. If there has been much laceration of the soft parts, a tracheotomy tube should be retained for a few days until the swelling has subsided.

6. *Tubercle.* Thyrotomy has been successfully performed in such cases, mostly under the impression that the disease was malignant. The differential diagnosis between tuberculous and malignant growths is sometimes very difficult until the tumour has been explored. In cases that are known to be tuberculous, the feeling prevails that thyrotomy

not to be recommended. It should be remembered that the external ound is liable to become tuberculous.

Instruments. Scalpel, curved scissors, dissecting forceps, pressure rceps, aneurysm needles, double hook retractors, bone shears (Wagtt's) or bone scissors, tenaculum forceps, needles on handles, catgut in rious sizes, a Hahn's tube, and tracheotomy equipment. A head-light required for illumination of the deeper parts during removal of mours.

Operation. In England, owing to the fact that the administraon has been in skilled hands, chloroform is not considered dangerous, d the operation is well tolerated even for three or four hours (*e. g.* in ryngectomy). On the Continent, however, Kocher, von Bruns, and hers advocate local anæsthesia with cocaine or novocaine. Jackson ggested rectal etherization as an alternative, but this has many dangers. my opinion a general anæsthetic should be given, as it enables the eration to be performed more thoroughly and is followed by less shock. must nevertheless be borne in mind that, if the growth is intrinsic d of large size, it is difficult to administer chloroform, and the patient liable to suffer from urgent dyspnœa. In such a case it is advisable perform preliminary tracheotomy with novocaine alone (see p. 584).

As regards the operation, the important question arises whether acheotomy ought to be performed several days prior to the main operaon, in order to accustom the patient to the tube and the new method of eathing. The following reasons are advanced in favour of this: the ain operation is shortened, and relief is given to the larynx and lungs, that congestion subsides and broncho-pneumonia is less likely to pervene. The objections are also important, namely, that there are o operations instead of one, and perhaps two anæsthetics (though this n be avoided if local anæsthesia is used for the tracheotomy); that the acheotomy wound becomes septic, and infection of the trachea and onchi is apt to occur, with consequent bronchitis; that the air which sses into the lungs is devoid of moisture and heat; that the trachea comes surrounded by adhesions; and that it is altogether unnecessary. he objections in my opinion outweigh the advantages claimed; it is tter to perform tracheotomy as a first stage in the operation of removal cept in cases where there is great laryngeal obstruction, where dyspnœa present, or where bronchitis fails to yield to other forms of treatment. such cases tracheotomy should be performed first, and the second eration should be carried out a week or ten days later when all the nditions are favourable.

When operating upon the larynx the surgeon must use every precaun to prevent blood from running into the lower air-passages, and this

may be accomplished by a tampon in the trachea or by keeping the head of the patient lower than the body. Some surgeons prefer to use a Hahn's canula, although the sponge requires from ten to fifteen minutes to swell. This canula is more reliable than Trendelenburg's, whose inflated bag is apt to slip or collapse suddenly. As soon as the thyreoid cartilage has been opened, a second sponge should be inserted above the canula, and by this means the air-passages are completely blocked.

If an ordinary tracheotomy tube be used, the operation must be performed either with the head lower than the body (Rose's position), or with the whole body inclined (Trendelenburg's position), or with a combination of the two; and in any case a sponge should be placed in the upper part of the trachea after the thyreoid has been opened. Under no conditions must blood be allowed to pass below the tube. Whatever form of canula is used, it should be fitted with a Hahn's tube and funnel (Fig. 258), so that the anæsthetist can give the chloroform without interfering with the surgeon. The patient should lie upon the back on a flat table, the head extended slightly over a small cushion in the position for tracheotomy.

First stage. A vertical incision is made in the middle line from the hyoid almost to the sternum, so as to expose the thyreoid cartilage and the pretracheal muscles; these are retracted, so that the anterior aspect of the trachea is exposed; the isthmus of the thyreoid gland is completely divided, and search made for bleeding points until the wound is quite dry. A large opening is made accurately in the middle line of the trachea; this will be at least two rings below the cricoid cartilage in order that the tube may be well away from the region of the growth. In adults, if a Hahn's tube be employed, the section should include at least three rings of the trachea.

Second stage. The anterior aspect of the thyreoid cartilage, and the crico-thyreoid membrane, are freely exposed, the infrahyoid muscles being separated by at least one inch, and, if necessary, retracted. Ten minutes after the tube has been inserted, the crico-thyreoid membrane is punctured, exactly in the middle line, in order to admit the inner blade of the bone forceps; the latter is pushed upwards, slowly and without force, between the posterior portions of the vocal folds, until the whole length of the thyreoid cartilage is included between the blades; the forceps are then forcibly closed, great care being taken that the outer blade is cutting exactly in the middle line. By quickly opening the cartilage in this manner there is practically no danger of destroying the anterior attachments of the vocal folds or cutting through the substance of one of them. The two halves of the larynx are forcibly separated and retained in this position by hooked retractors, so that the interior of the larynx is exposed.

rder to give a free exposure, it is necessary, as a rule, to divide with
ife the crico-thyreoid membrane; but the thyreo-hyoid membrane
ld not be touched, nor should the attachments of the epiglottis be
rbed. The separation must be performed carefully in order to avoid
acture of the cartilages. The pharynx is plugged with gauze, so that
saliva can enter the
nd, and after all
etion has been re-
ed from the larynx
all sponge or plug is
rted into the upper
of the trachea. Co-
e, 20%, is freely
ied with a swab of
l to every part of the
nx in order to con-
t the vessels; per-
nt hæmorrhage can
ntrolled by plugging
cavity with wool
ed in cocaine; 'this
suffices . . . and the
loyment of adrena-
as I have personally
rienced in one case,
eases the risk of sec-
ry parenchymatous
orrhage' (Semon).
her, and this is of
rtance, by the use
caine the irritability
he larynx and the
ngeal reflex are de-
ed. The tumour
now be inspected; it
be thoroughly ex-
l by cutting through the soft or hard structures (cricoid if neces-
) so that its limits can be determined, thus enabling the surgeon
ecide whether it is possible to obtain a satisfactory result by local
val.

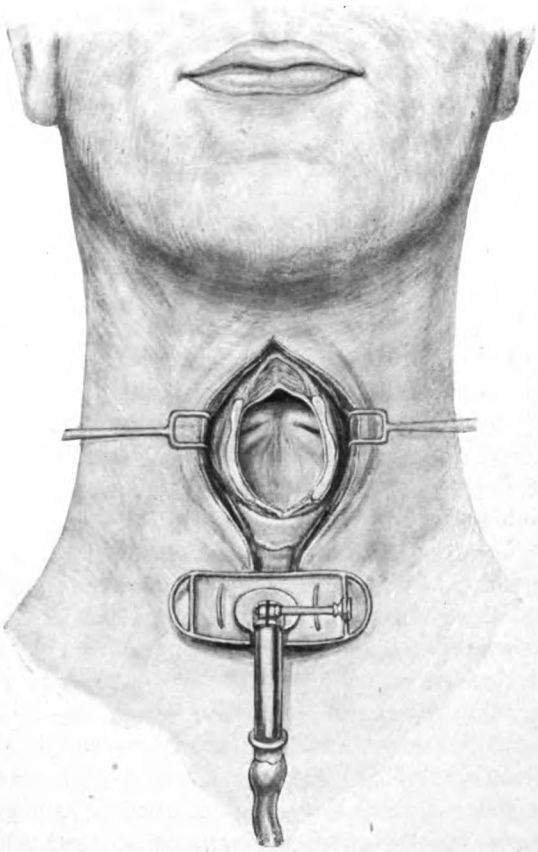

FIG. 252. THYROTOMY. Showing exposure of the larynx, and tube for the anæsthetic.

Third stage. In the words of the late Sir Henry Butlin[1]: 'An in-

[1] *Op. Surg. Malig. Dis.*, 2nd ed., p. 191.

cision is carried around it (the tumour) with knife or scissors, including more than half an inch of the surrounding apparently healthy tissues, without respect to the after use of the voice or any other consideration except the complete removal of the disease. The included area is cut out right down to the cartilage, which is laid bare and finally scraped absolutely bare with Volkmann's sharp spoon.' The cavity is then plugged for a few moments until the bleeding has been controlled. The hæmorrhage is never serious, and can be controlled by catgut ligature if necessary. The wound must be completely dry. It is then dusted with a powder such as orthoform; the retractors are removed, and the alæ of the thyreoid cartilage allowed to fall together. In relation to the removal of the tumour, Butlin has shown that there is 'little liability of malignant disease infiltrating the cartilage of the larynx,' so that, as a general rule, the latter can be left if all the soft tissues, including the perichondrium, are removed from its surface; this is comparatively easy to accomplish in the case of the thyreoid, but more difficult with the arytænoids and cricoid cartilage. C. Jackson has criticized the use of a sharp spoon as likely to cause infection of the cartilage.

Fourth stage. In some instances it is possible partially to unite the divided mucous membrane, and so to lessen the granulating area: when this is done it is of the utmost importance that the lumen of the larynx should not be constricted, as any constriction will increase the danger of stenosis. In many instances it is not advisable to attempt to repair the wound that has been produced.

In suturing the external wound the alæ of the thyreoid are brought accurately into the position which they occupied before division, in order that the anterior attachments (if left) of the vocal folds should heal at their proper level. In some instances the cartilages fall naturally into the desired position, especially if one or two catgut sutures are inserted into the hyo-thyreoid membrane; in other cases it may be advisable to insert one or two similar sutures through the cartilage itself and thus obtain correct apposition. These sutures should lie on the outer aspect of the mucosa, so as not to traverse the cavity of the larynx itself. In cases where only the anterior portion of a vocal fold has been removed, Semon recommends that the divided end be sutured to the ventricular fold: it is reasonable to suppose that, by attention to this detail, a better voice will be afterwards obtained. The infrahyoid muscles are approximated with one or two catgut sutures in the upper part of the wound; the skin is united with a continuous silk suture, as far downwards as the lower part of the thyreoid cartilage. The lower part of the wound is left open, to procure free drainage through the crico-thyreoid and tracheal openings. The whole of this lower wound is packed very loosely with gauze, so that

discharges are not retained. It is necessary to emphasize the importance of not plugging the cavity of the larynx. The Hahn's tube is removed as soon as the operation is completed, and replaced by a tracheotomy canula; the whole wound is covered by a loose pad of antiseptic gauze, which is kept in position by tapes or loosely applied bandages. No dissection for removal of lymph glands is required.

The above may be called the typical operation for malignant disease in which the growth is intrinsic; it gives better exposure of the parts than other operations such as transverse laryngotomy (division of the thyreoid cartilage at the level of the sinuses of the larynx), subhyoid pharyngotomy, partial thyrotomy, cricotomy, and crico-tracheotomy; the removal of tumours is therefore easier and better after-results are obtained. If the growth be found more extensive it may be necessary to modify the procedure. For example:

(*a*) When the epiglottis is involved, an extensive dissection of the hyo-thyreoid membrane can be made in order to expose and remove the growth thoroughly together with any soft parts or cartilage which appear to be involved. Branches of the superior thyreoid arteries, or the hyoid branch of the lingual artery, will be ligatured. The superior laryngeal nerves should always be preserved whenever possible, as loss of sensation increases the liability of food passing into the larynx.

(*b*) When the arytæno-epiglottic fold is involved, a transverse incision can be made through the hyo-thyreoid membrane, immediately above the thyreoid cartilage on the same side, and the wound enlarged until the tumour is exposed. In this manner I was able to remove the large carcinoma shown in Fig. 245, including the soft parts of the right half of the larynx, the right half of the epiglottis, the right arytænoid, and the wall of the pharynx in relation to the right piriform recess: the lymph glands were not removed. One year later the patient continued to enjoy good health with no signs of any recurrence. In this connexion it is important to emphasize that when the disease is very extensive, and particularly when the posterior portion of the cricoid and arytænoids is involved, such an operation is useless, and the surgeon must decide whether partial or complete laryngectomy should be performed. In rare instances the operation should be abandoned in favour of tracheotomy (palliative).

(*c*) When the tumour extends downwards into the subglottic region, it is necessary to split the cricoid anteriorly and divide the upper rings of the trachea, after which the tumour can be removed with as much of the structures as may be desirable.

(*d*) When the growth extends across the median plane in the anterior commissure, or when a second growth is situated directly opposite on

the other side of the larynx, the whole disease must be removed regardless of damage to the tissues which are not affected.

(*c*) When the operation is performed for stenosis, it is necessary to remove freely all the fibrous tissue without attempting to preserve any part that is diseased. The hæmorrhage is generally severe and necessitates preliminary plugging of the trachea with a Hahn's canula.

After-treatment. This must be conducted so as to prevent the chance of broncho-pneumonia and sustain the strength of the patient. With Butlin's method the patient is placed on his side, or face downwards, with the head low and with only a small pillow, so that all secretions pass out of the air-passages through the external wound. This undoubtedly gives better drainage to the wound, and is less exhausting than the upright position during the early stages of convalescence. The dressings on the wound must be changed, especially in the early days, as often as they become soaked; it is also an advantage to insufflate an orthoform powder, or an antiseptic parolein preparation, with the object of cleansing the larynx. The tracheotomy tube should be retained, usually from ten to twenty days, until the patient can swallow well and as long as there is a flow of pus from the wound.

'During the day of the operation nothing is swallowed, although fragments of ice may be kept in the mouth for the comfort of the patient. If there is fear of collapse and the patient is feeble and very old, brandy and beef-tea may be administered by the rectum. On the following morning the first attempt is made to swallow. The patient leans far forwards with the head down, and the dressing is taken off the wound, beneath which a basin is placed. Cold water is drunk out of a glass. If the experiment is successful, all the water passes down into the stomach; if it is only partially successful, some escapes into the larynx; but the posture of the patient ensures that the liquid runs out through the wound and does not pass into the air-passages. As soon as water can be readily swallowed, milk, beef-tea, and other liquids may be drunk, for the fear of "Schluck-pneumonie" is practically at an end. The wound is generally closed within ten or twelve days of the operation and the patient is rarely confined to the house for more than ten days.' (Butlin.) It is probable that the healing by this, which is called the 'open' method, is as rapid as with Moure's, in which the whole length of the incision is closed; the open method would also appear to be safer and less often attended by complications.

Complications. (1) *Broncho-pneumonia* is most to be dreaded. Death from shock or collapse, from hæmorrhage, from septic conditions of the wound, or from iodoform poisoning, is now rarely met with and can more easily be prevented. Even pneumonia is uncommon, owing

more scientific methods of treatment. It is still to be feared in very ld patients; in those who already suffer from bronchial catarrh at the me of the operation; in alcoholics; and in cases with old-standing enal, pulmonary, or heart affections. The improvement in this direction due to greater antiseptic precautions, and to the prevention of aspira- on of blood and septic secretion during and after the operation by ree drainage of the wound.

(2) *Stenosis.* It sometimes happens that a considerable mass of ranulation tissue appears in the anterior commissure, or upon the rface of the cartilage that has been bared by the operation; if this e left untreated it may gradually enlarge in size until a prominent shion is produced, which reaches to the opposite side and thus causes enosis with definite laryngeal obstruction. Such a swelling may be istaken for recurrence, but is nearly always of inflammatory character. is by no means certain what is the causation of this condition, which ppears to occur more with some surgeons than with others; it has een suggested that the presence of sutures in the region of the anterior mmissure may cause an irritation, especially if silk is used. It appears me, having in mind similar conditions in other surgical wounds, that ie cause is to be found in some form of sepsis, and that it can be pre- ented to a great extent by precautions at the operation and by proper fter-treatment. If there be any obstruction to breathing, the larynx is spected and the projecting granulations are removed by intra-laryngeal rceps. The remainder of the mass generally shrinks and disappears. the stenosis be troublesome (chiefly in syphilitic cases), the prolonged se of a laryngo-tracheal canula (p. 402), or of an intubation tube, or latation with bougies, may be necessary. In rare instances a per- anent tracheotomy tube is required, with a valve to encourage expira- on through the mouth.

HEMI-LARYNGECTOMY

This operation is suitable for certain cases of malignant disease which strictly limited to one half of the larynx. The requirements and *rst and second* stages of the operation are similar to those for thyrot- ny (see pp. 527, 528).

Third stage. A transverse incision is made on the side affected along e upper border of the thyreoid cartilage, through the skin and fasciæ; nd, if necessary, a second transverse incision is made at the level of the wer border of the cricoid so that a skin flap can be turned back. The ffected half of the larynx must now be considered as a tumour to removed. The infra-hyoid muscles are dissected away from the

'tumour' and retracted; the upper part of the lateral lobe of the thyreoid gland (the isthmus having been previously divided) is displaced outwards by blunt dissection, and the soft tissues above the thyreoid are similarly treated: the larynx should be pulled well over to the opposite side while this is being effected, great care being necessary to avoid wounding the carotid artery in the deeper part of the dissection. The branches of the superior thyreoid artery, the crico-thyreoid artery, and the veins of this region are ligatured with catgut. In some instances, when the growth has not perforated the cartilage, the separation can be performed subperiosteally. Superiorly, the hyo-thyreoid membrane is completely divided on the same side, and the mucosa is cut through above the upper limit of the growth. If the growth extends upwards, the epiglottis may be removed either totally or partially. Inferiorly, a transverse incision must be made through the crico-thyreoid or crico-tracheal membrane, or lower in the trachea. The inferior constrictor of the pharynx is divided as close to the attachment to the thyreoid as possible, and the cavity of the pharynx is opened behind the growth. The cricoid plate is split with bone scissors in the interarytænoid interval, and the final attachments are rapidly divided with a few touches of the knife.

In this operation, as with other operations for cancer, the main thought of the surgeon must be to remove the tumour thoroughly, including the soft tissues of the neck when these are diseased, the lateral wall of the pharynx, and the cervical glands upon the same side, whether they are known to be affected or not. In this respect the operation differs materially from thyrotomy; and I agree with Semon that, if hemi-laryngectomy is necessary, the lymph glands of the same side should in all cases be removed. The two dissections may be accomplished at the same time, or one may be performed later at a second operation; in the latter event an incision along the anterior border of the sterno-mastoid muscle is preferred. The operation must be very complete in order to be successful, and requires a knowledge of the anatomy of the lymph vessels and glands.

THE ANATOMY OF THE LARYNGEAL LYMPH VESSELS

The following description is Cuneo's[1] and has been confirmed by de Santi.[2]

The lymph vessels which drain the mucous membrane of the larynx are divided into two distinct regions, namely, the supraglottic and the infraglottic zones. These regions are separated by the vocal folds,

[1] Poirier and Cuneo, *Lymphatics*, Eng. ed., 1903, p. 286.
[2] De Santi, *Malignant Disease of the Larynx*, 1904, p. 10.

and injection of the folds themselves generally passes into the upper zone. The upper region is most densely supplied, and covers the epiglottis, the arytæno-epiglottic folds, the ventricular folds, and the laryngeal sinuses.

The lymph vessels communicate freely in the posterior wall of the larynx (not in the anterior commissure), but though an injection into one half of the larynx easily passes into the mucous membrane of the other side, it is exceptional for it to pass as far as the corresponding glands of that side. The lymph vessels of the larynx anastomose to a large extent with the networks of the adjacent organs (tongue, pharynx, trachea).

The supraglottic lymph vessels perforate the hyo-thyreoid membrane where the superior laryngeal arteries enter, and end in (1) a substernomastoid gland under the posterior belly of the digastric; (2) glands on the internal jugular vein opposite the bifurcation of the carotid artery; and (3) glands on the same vein opposite the middle of the lateral lobes of the thyreoid gland. The glands in the front of the hyo-thyreoid membrane receive lymph vessels from the pharynx, but none from the larynx.

The subglottic lymph vessels perforate the crico-thyreoid membrane in two places (*a*) anteriorly, near the middle line, ending in (1) a prelaryngeal gland which lies in the V-shaped space between the crico-thyreoid muscles or under one of the same (a gland above the isthmus of the thyreoid gland is rarely present), and (2) a pretracheal gland (or glands) below the isthmus; (*b*) laterally, to end in (1) the glands which lie parallel to the recurrent nerve, from which trunks run to (2) the substernomastoid group and (3) the supraclavicular glands.

It is important also to consider the question from the clinical aspect. With 'intrinsic' growths, involvement of lymph glands is very uncommon unless the posterior (cricoid) zone is affected; it seems to be equally rare with tumours of both supra- and infra-glottic zones; extension to the lymph vessel of the opposite side is likewise improbable. With 'extrinsic' growths, the lymph glands are rapidly involved; tumours that were originally intrinsic follow this rule as soon as they begin to affect the cartilages and extrinsic lymph vessels of the larynx. These facts must be remembered because palpation of the neck may be quite misleading in early stages of the disease. On the other hand, in many advanced cases, such as those requiring palliative tracheotomy, the lymph glands become massive and form definite tumours. The sub-sternomastoid chain is, clinically, the situation that is specially affected; and any of its glands, from the digastric muscle above to the supraclavicular region below, may be involved. The prelaryngeal gland is rare, as are likewise the pretracheal and recurrent forms; nevertheless, the recurrent glands become attacked by advanced disease, affecting the upper part of the trachea.

TOTAL LARYNGECTOMY

Indications. This operation is performed for malignant tumours which have affected (*a*) the whole of the interior of the larynx, including the cartilages, or (*b*) the posterior portion of the larynx, including the arytænoid cartilages and pharyngeal aspect of the cricoid plate. In other words, it is employed in cases of extrinsic cancer in which the growth is not too advanced to render the prospect of its eradication hopeless. The operation should not be performed for tuberculosis.

It is essential that the patient should be in good health; one who is emaciated or who has organic disease, especially incurable bronchitis, is quite unsuitable for laryngectomy. On no account ought the operation to be undertaken unless the diagnosis of malignant disease has been confirmed, and unless the growth is known to be too extensive for thyrotomy. In many instances, therefore, thyrotomy is the first stage in the operation of total laryngectomy.

Operation. The instruments, anæsthetic, and position require the same consideration as with thyrotomy (see p. 527).

First stage. A vertical incision is made, in the middle line, from the hyoid to a point one inch above the sternum, and the anterior aspects of the thyreoid cartilage and trachea are exposed, with complete division of the isthmus of the thyreoid gland. The infrahyoid muscles are dissected from the larynx and widely retracted. By blunt dissection the upper part of the lateral lobes of the thyreoid gland is separated and bleeding arrested. The trachea, having been isolated in this manner, is divided obliquely from the front, upwards and backwards, as close to the cricoid cartilage as the disease allows without injury to the œsophagus; the lower end is carefully freed from the œsophagus, and two strong catgut sutures are passed through it with which the divided stump can be drawn forwards. If possible, a small transverse incision is made through the skin immediately above the suprasternal notch and made to communicate with the upper incision; the trachea is brought beneath the bridge of skin into the button-hole thus formed, and firmly attached by means of sutures. In some cases the trachea is sewn into the lower part of the original incision. A tracheotomy tube is inserted, through which the anæsthetic is continued. By this means the lower air-passages are completely cut off from the region of the tumour, and no blood or septic matter can pass into the lungs.

Second stage. The lateral aspect of the larynx is freely separated so that the attachment of the inferior constrictors is defined. The superior laryngeal artery is ligatured on each side, and divided, together with the internal laryngeal nerves. The hyo-thyreoid membrane is

transversely divided, and the pharynx is opened so as to expose the upper limit of the growth; this may necessitate a transverse incision through the skin, or a vertical division of the hyoid bone in the middle line with retraction of its two halves. The larynx having been isolated above, below, and laterally, its removal can be completed according to the situation of the growth, in most cases from below. The lower end of the larynx is hooked forward, and dissected away from the œsophagus by means of scissors or a sharp scalpel (Fig. 253). While

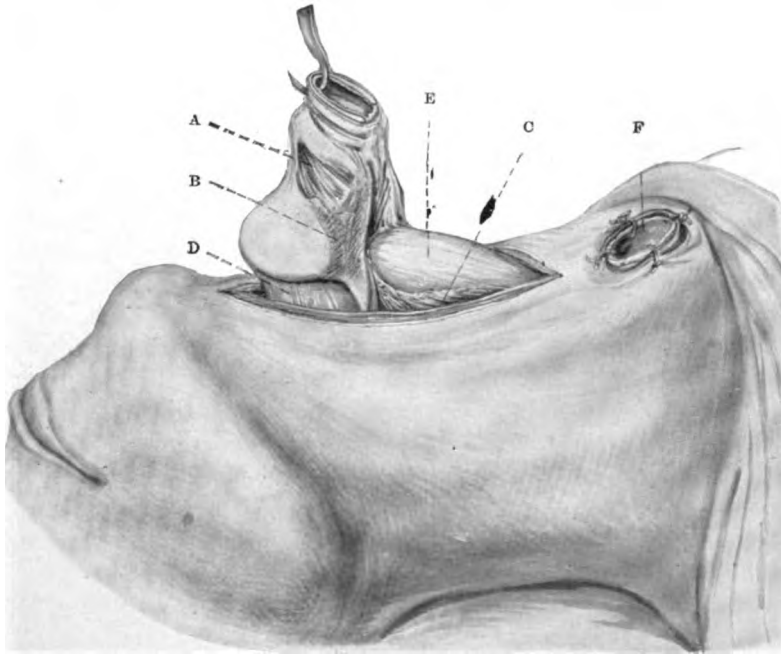

FIG. 253. TOTAL LARYNGECTOMY. A, Crico-thyreoid muscle; B, Attachment of inferior constrictor of pharynx to thyreoid cartilage; C, Cut edge of inferior constrictor; D, Hyo-thyreoid membrane; E, Œsophagus; F, Trachea.

this is being effected, the extent of the growth must be constantly examined by inspection and palpation, so that the whole mass is removed, including, if necessary, the pharynx and upper part of the œsophagus. It is important not to drag upon the œsophagus; C. Jackson has shown experimentally that this causes severe shock by affecting the depressor fibres of the vagus, which may result in death. It follows, therefore, that this part of the operation, though easy in the dead body, requires the utmost care and detailed technique. The division of the constrictors should be as close to their attachment as possible, and the final division

of the pharyngeal mucosa should be half an inch beyond the limit of the growth. The epiglottis should generally be removed.

Third stage. The toilet of the pharynx and œsophagus remains to be decided. In order to restore the cavity of the pharynx, the upper end of the œsophagus is brought upwards whenever possible and accurately united to the pharynx in the region of the hyoid bone, this being accomplished by a double layer of catgut sutures uniting the mucous membranes. The infrahyoid muscles are then brought together by a vertical row of stitches, so as to cover and support the line of union. The wound having been thoroughly packed with gauze, the skin is sutured, excepting the lower end, which remains open for drainage. In cases where the pharynx is thus completely closed, a tube must be passed previously through the nose into the œsophagus, and retained for purposes of feeding. This is preferable to sewing the tube into the wound itself, and is rarely troublesome if the tube is sufficiently stiff to prevent its displacement by retching. At the conclusion of the operation the tracheotomy tube is replaced by an ordinary silver canula, and the wounds are lightly dressed.

After-treatment. This is conducted upon similar lines to those adopted in the after-treatment of thyrotomy. During the first ten days, until the pharyngeal wound is firm, the patient must be fed through the tube and by rectal administration. Sterilized water may be sucked uphill, and, as swallowing improves, food may be administered by the mouth. In most cases a pharyngeal fistula results, which may require a later plastic operation. A second operation is necessary for the removal of lymph glands, probably on both sides of the neck.

The complications are similar to those following thyrotomy (see p. 532).

Modifications. The above operation, which in the main has been planned by surgeons in America (S. Cohen, Keen, &c.), is preferable to the numerous modifications, of which the following may be mentioned as examples:—

Gluck's operation. In this there is no preliminary tracheotomy. A large rectangular flap is turned to one side to expose the front of the larynx and trachea, the latter being isolated laterally and the thyreoid isthmus divided. A transverse incision is made through the hyo-thyreoid membrane in order to expose the upper aperture of the larynx thoroughly. By plugging the pharynx and adopting a low position for the head, saliva and blood are prevented from running into the air-passage. The interior of the larynx having been cocainized, a tracheotomy tube is inserted between the vocal folds. This is sutured in position in such a manner that the cavity of the larynx is completely

ut off from the pharynx. If a general anæsthetic be employed, it can continued through the canula by a Hahn's adjustment (Fig. 258). ne larynx, and any part of the pharynx or œsophagus which is diseased, e separated from above downwards, the trachea being severed transrsely as a final stage and sewn into a button-hole immediately above e sternum. A soft rubber tube having been introduced through the se into the œsophagus, the walls of the latter are united over the be by a double row of catgut sutures, completely isolating the gullet.

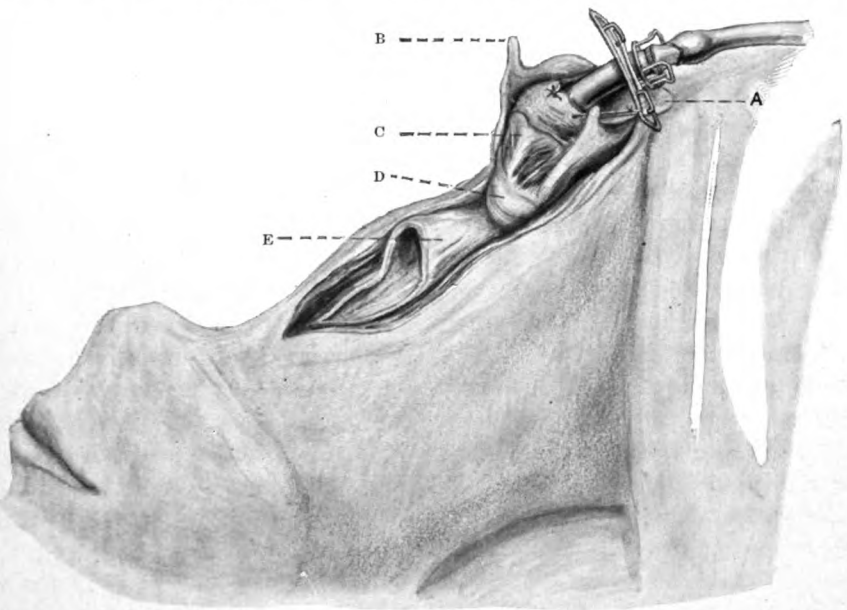

FIG. 254. TOTAL LARYNGECTOMY. GLUCK'S METHOD. Tracheotomy canula th rubber tube for Hahn's adjustment tied into the upper opening of the ynx. A, Epiglottis; B, Superior cornu of thyreoid cartilage; C, Posterior surce of cricoid with crico-arytænoid muscles; D, Trachea; E, Œsophagus.

ne cavity is covered with gauze, and the skin flap is partially sutured to its original position. An ordinary canula is placed in the trachea d the wounds are dressed.

In cases where the pharynx has been extensively removed a fistula mains, but Gluck has devised a plastic operation by means of which is can afterwards be closed. In some cases this fistula may be oblitered by the natural falling in of the parts, without further operation; d in the meantime the patient is provided with a funnelled tube for eding, placed in the œsophagus with the upper end below the base the tongue.

The advantages claimed by Gluck for this operation are the avoidance of preliminary tracheotomy, the prevention of blood from passing into the trachea, the complete separation of the trachea from the gullet, and the early feeding through the mouth. These, however, are chiefly met by the former operation.

Chiari and le Bec perform the operation in two stages. In the first, the trachea is isolated and divided transversely, the lower end being sutured above the sternum. The second operation, undertaken one or two weeks later, consists of a complete removal of the disease.

Föderl suggests the possibility of uniting the lower end of the trachea (after laryngectomy is completed) to the tissues beyond the hyoid bone, and thus restoring the air-passages; but the method is not free from danger, and the trachea is apt to slough.

S. Handley [1] performed a complete transverse resection of the pharynx, with laryngectomy, for malignant growth in the following manner: Preliminary gastrostomy was performed; a week later, when the patient had recovered, a low tracheotomy was effected, the trachea being plugged with gauze above the tube. The whole of the larynx and a complete section of the pharynx were then removed as described in Gluck's method; and, the trachea having been brought into the lower part of the wound, the pharynx and œsophagus were closed by sutures. The patient recovered with a pharyngeal fistula through which the saliva passed, the latter being led to the stomach through the gastrostomy opening. In a second similar case the result was fatal. 'The patient died on the table, apparently from irritation of the vagus, after the operation was practically complete.' Handley believed that the failure was due to a defect in his technique, and that, if he had frozen the two vagi below the point at which he was working, death would not have occurred.

COMPARATIVE RESULTS OF THE DIFFERENT EXTRA-LARYNGEAL OPERATIONS

In order to obtain a trustworthy idea of the value of the various operations for malignant disease, it is necessary to refer to the history of the operation.[2] Czerny, in 1870, was the first to demonstrate by experiments on dogs the possibility of removing the entire larynx, and various attempts were afterwards made by different surgeons, notably by Billroth, to accomplish the same in man. In 1881 Foulis was able to collect twenty-five cases of total laryngectomy, and found that not one of them was alive twelve months after the operation. Partly in con-

[1] *Proc. Roy. Soc. Med.*, London, vol. i, No. 4, 1908, Clin. Sect., p. 66.

[2] An account of the history of these operations will be found in a paper by Sir F. Semon, *Brit. Med. Journ.*, 1903, vol. ii, p. 1113.

equence of this, thyrotomy was given a trial, and in 1887 P. Bruns ollected nineteen cases, with two deaths and sixteen local recurrences. Ie therefore concluded that 'attempts to extirpate the disease by means f thyrotomy have shown themselves to be altogether insufficient and seless'; and so it came about that all external operations, at this date, ere considered by most authorities to be unsatisfactory. Much atten- on was, however, drawn to the subject by the illness of the German mperor, and Semon particularly emphasized the great importance of arly diagnosis. The result of this was marvellous. The importance of Irishaber's division of carcinoma of the larynx into two forms, intrinsic nd extrinsic, was recognized by the late Sir Henry Butlin, to whom the reatest credit is due for having first shown that thyrotomy ought to e reinstated. Butlin and Semon have since perfected this operation, hich has rightly been described as the English operation. It is now ecognized throughout this country as the operation which gives perfectly eal results, so long as it is restricted to early stages of intrinsic malig- ant disease (in which an early diagnosis is indispensable) and is thor- ughly carried out. As Semon concludes, 'if these demands be com- ied with, the position of thyrotomy, as being the operation in the early ages of malignant disease of the larynx, will remain impregnable, so ng as we have to fight malignant disease by operation.' That this is ue will be seen by the results mentioned later.

It is also necessary to refer to the other side of the question, namely, ie position of laryngectomy. Many well-known surgeons in Europe nd the United States have been convinced that laryngectomy, partial r complete, is the only possible treatment for cancer in this region. luck says:

'As showing the progress that has been made during the last fifteen ears in this subject, I may mention that in my first series of ten cases nly two were successful, and in nine cases of another series I had four eaths. Since then I have performed many operations with ever im- roving results. Thus in one series of thirty-five hemi-laryngectomies I ad three deaths: one twenty-four days after the operation, of heart ailure, when the wound was already healed; another independently of ie operation, of phlegmon of the right gluteal muscle; the third of neumonia five days after operation.

'My most recent results show a series of twenty-two complete laryn- ectomies with one death, that of a man of seventy, who died on the eventh day of iodoform poisoning. Of the partial extirpations of the rynx and pharynx, generally combined with removal of infected lymph ands, I can point to a series of twenty-seven cases with only one death. his was a case in which the carotid had been tied, and death occurred rom hemiplegia five days after the operation.

'At present I could show you thirty-eight living patients who have been cured by these operations; the oldest case was operated on thirteen years ago. Of those already dead, a number have lived 11, 8, 6½, 5½, 4½, and 3½ years after the operation in good health, and some have died of other illnesses, not of recurrence. One man, nine years after hemi-laryngectomy, had recurrence in the other half of the larynx and in the lymph glands; after the second operation he lived over two years, and died at seventy-six. The operations lengthened his life for eleven years.

'A man of seventy-six had the larynx and pharynx extirpated, and lived 11½ years after the operation. Twice I have performed complete laryngectomy for tubercle; one case died in spite of that of consumption; the other was done four years ago and the patient is perfectly well.

'In all I have performed 125 of these operations since the year 1888, and the record is one of great progress, both in technique and also in the elaboration of plastic operations and mechanical appliances for the improvement of the post-operative condition.'

Many large operations of this description have undoubtedly been performed because of the statement that it is impossible to obtain a lasting cure by performance of thyrotomy. Even at the present day this opinion holds its ground, and so long as there is a general grouping of the cases, progress cannot be made.

Thyrotomy. I shall attempt to show that thyrotomy is the best operation for early malignant disease, whether carcinoma or sarcoma, so long as it remains intrinsic. No attempt will be made to separate the different forms of these diseases. The points to be considered are the following:—

The *mortality* of the operation itself has been greatly reduced. Von Bruns[1] states that 'between 1890 and 1898 there was an immediate fatality of 15%' in sixty cases collected by Schmiegelow and himself. In comparison with these figures, the recent results of English surgeons have been very favourable. Thus Butlin and Semon have performed forty-eight thyrotomies for malignant disease since 1890 with only two deaths. In Butlin's case the patient was over seventy years of age, very obstinate, very intractable and persisted in sitting up from the time of the operation. He died, in the course of three or four days, of septic pneumonia. The results of other surgeons have been excellent, but are not included for three reasons: There is still considerable confusion in the selection of cases suitable to this operation; the operation is often performed by those who are not conversant with the difficulties and dangers that may arise; and it has sometimes to be undertaken for a patient who is also suffering from bronchitis or constitutional disease. Moreover, the above

[1] Bergmann, E. von, *Sys. Prac. Surg.*, vol. ii, p. 245.

figures are sufficient to show that the immediate mortality from this operation under favourable circumstances is not large.

Recurrence, in Semon's cases, occurred in 13.6%, which is not a large proportion. It usually occurs early or not at all. Semon and Jackson noted that none of their patients suffered from recurrence after the lapse of the first year. This is a point of great importance; and in this connexion Semon points out, as an additional advantage of thyrotomy, 'that even in the cases in which either the operation has not been complete, or in which unfortunately genuine recurrence has taken place, the operation does not bring us to the end of our resources; but that, on the contrary, by a repetition of the operation, or by hemilaryngectomy, or by total extirpation of the larynx, a lasting cure may still be obtained, where the minor operation has failed.'

Cures. I hope it will soon become generally recognized that the radical operation of thyrotomy for removal of early intrinsic malignant disease is attended by a remarkable number of complete cures, and compares favourably with almost any other operation for similar conditions in other parts of the body. Butlin (see Table, p. 545), Semon C. Jackson, and Thomson have all obtained, in recent years, from 60 to 80% of lasting cures. In Semon's twenty-five cases,[1] one died of the operation, three cases recurred within a year, and one was too recent to be included; the remaining twenty were cured for varying periods, namely:

1 case over 15 years.
4 cases between 10 and 15 years.
4 cases between 5 and 10 years.
2 cases over 4 years.
3 cases over 3 years.
2 cases over 2 years.
1 case just 2 years.
1 case 1 year and 10 months.
1 case died 5 years after operation from pulmonary embolism.
1 case died 4 years after operation from pneumonia.

In both the last cases recurrence was excluded.

StClair Thomson has also reported ten cases,[2] with lasting cures in 80% and no death as a result of the operation. Of the two cases who died of the disease one had local recurrence and the other a separate development of cancer in another part of the body.

The *condition* of the patient after thyrotomy. The voice results are often surprisingly good even when a free excision of soft parts, including one or both vocal folds, has been required. In from 40 to 60% of cases that are cured, the speaking voice is practically normal, though rough and

[1] *Trans. Med. Soc. London,* 1907, vol. xxx, p. 130.
[2] *Brit. Med. Journ.,* February 17, 1912.

reduced in volume and range. Of the remainder, the majority recover sufficiently to produce a considerable whisper, and only a few suffer complete loss of voice. The causes of a complete loss of voice, when it occurs, are chronic inflammation, cicatricial contractions, or improper union of the cartilage. Further, a loss of voice is probable in the event of a recurrence of the growth.

The breathing is not affected unless the operation is followed by stenosis. The power of swallowing is soon regained, and the general condition of those who are cured is one of complete happiness and general excellence of health.

These results may now be briefly compared with those obtained by laryngectomy, whether partial or complete.

Hemi-laryngectomy. The immediate *mortality* of this operation also has been greatly reduced. Sendziak collected 108 cases, up to 1894, showing a mortality of 26.3%; von Bruns 106 cases, between 1890 and 1898, with a mortality of 17%; Gluck has performed thirty-five such operations with only three deaths—8.1%. The number of cases reported in England is too small to be of value, chiefly because thyrotomy or total extirpation has been considered better. Taking, therefore, the best published results, it appears that the mortality is at least twice as great as with thyrotomy.

The danger of *recurrence* is also greater, partly because the glands are affected. Statistics show that recurrence occurs in at least one-fourth of the cases, possibly more, and is generally fatal. It is impossible to give a prognosis as to cure in the early stages after operation, but there are instances of life being prolonged for many years; a case of Gluck's lived for eleven years.

The after-condition is not unsatisfactory. The permanent wearing of a tracheotomy tube is rarely necessary. Swallowing is soon recovered, and the voice is often good.

Total laryngectomy. Although the mortality of this operation has been greatly reduced by many improvements in recent years, it still remains higher than that of thyrotomy. As far as can be judged from the small number of cases that have been reported by English surgeons, there seems to be a direct mortality of at least 20% from these operations. C. Jackson[1] has, however, performed eight consecutive total laryngectomies without a death in the first thirty days. He writes: 'Of eight total laryngectomies done by me, three were hemi-laryngectomies followed by recurrence and the total operation. Of the eight laryngectomies, one lived seven years. I felt justified in claiming a cure, but upon inquiry a few weeks ago I was informed by

[1] *Brit. Med. Journ.*, 1906, vol. ii, p. 1480.

relatives that he died of cancer of the stomach. One case lived three years without recurrence, dying of cerebral hæmorrhage, and one eight months, dying of alcoholism. Of the remaining five, three recurred within a year, one apparent cure was lost to observation after a year, and one is too recent to record: one of the three prompt recurrences had metastases in the lungs, liver, and pancreas. Thus, of eight laryngectomies, no absolute ultimate cures can be claimed, though three were apparent cures at the end of one year.'

Butlin has performed total laryngectomy upon seven patients, only one of whom died from the operation. He says: 'I first removed a large mass of glands on both sides, and later took out the larynx, which was so diseased, that the surrounding parts were infiltrated for a considerable distance. He lived six weeks after the second operation, and then died of double pneumonia, which was attributed to an attack of influenza when he was up and about his room. I do not know whether the pneumonia was due to that cause or to sepsis of the lungs, for we had on several occasions some difficulty in feeding him, and in getting a tube properly down his œsophagus.'

The following is a table showing Butlin's operations since the year 1890, from a paper which was read at the Second Congress of the International Surgical Society at Brussels in 1908:

Operations:		
23	Thyrotomy [1]	21 patients
1	Hemi-laryngectomy	1 patient
7	Laryngectomy [2]	6 patients
31	operations on	28 patients

Died of the operation (1 thyrotomy, 1 laryngectomy)	2
Died of recurrence	4
Died of intrathoracic disease, probably cancerous glands, within 2 years	1
Died of cancer of tongue [3]	1
Lost sight of after operation	1
Alive after operation for recurrence	2
Well within 3 years	3
Died of other disease after 3 years	1
Well after 3 years [4]	13
	28

[1] In two patients the operation was repeated.

[2] In one patient thyrotomy was followed by laryngectomy, but the patient was included amongst the thyrotomies only.

[3] This was regarded as a second attack of cancer, for the disease of the tongue was some distance from the larynx, and there was no sign of cancer of the intervening parts. Also more than a year elapsed before he began to suffer from cancer of the tongue.

[4] Periods during which patients remained well lasted from 3 to 15 years.

Recurrence after laryngectomy is, therefore, more frequent than after thyrotomy, and it is difficult to estimate the proportion of cases that are cured by this operation. Butlin writes: 'Of the six patients who survived the operation, one died of probable cancerous glands in the mediastinum, one had inoperable recurrence in the cervical glands, three were alive within three years, and one was well three years after the operation.' He says: 'I began to perform laryngectomy three years ago on account of Gluck's success, and of the excellent modification due to Solis Cohen. I wish I had begun to perform it earlier. I am sure that several of the cases on which I performed thyrotomy were much better fitted for laryngectomy, and I cannot help thinking I might have saved one or two patients in whom recurrence took place if I had then removed the larynx. I think the glands ought to be removed in every case in which there is extensive carcinoma of the larynx, even if it be intrinsic, unless the disease is limited to the middle zone of the interior of the larynx. Even in these cases it would probably be a wise precaution to remove the glands. I have never removed the glands and the larynx at one sitting.' Von Bruns,[1] from statistics of all total operations since 1890, gives the following proportions:

Cure, over 3 years	8.6 per cent.
Cure, 1 to 3 years	17.4 „
Cure, under 1 year	32.0 „
Recurrence	23.4 „
Death due to operation	18.5 „

The voice after laryngectomy. Many efforts have been made to replace the lost voice. The artificial larynx, as first devised by Gussenbauer, consisted of three distinct parts: a tube for the trachea through which the patient inspired; a tube communicating with the pharynx so as to allow of expiration through the mouth; and a phonation canula which fitted into the former. This canula was supplied with a valve which closed during expiration so as to allow of breathing through the mouth, and a phonation apparatus for production of the voice. A large number of modifications of this larynx have been made at different times but have rarely been successful. The irritation and pain caused by the pharyngeal portion, the difficulty in swallowing and in keeping the tubes clean, and the exhaustion caused by prolonged use, have combined to make the apparatus unsatisfactory.

As the result of recent improvements in laryngectomy, most surgeons isolate the trachea as already described, and thus entirely shut off all communication with the mouth. The patient then has a choice of two methods—(1) the bucco-pharyngeal voice, or (2) a phonetic apparatus

[1] Bergmann, E. von, *Sys. Pract. Surg.*, vol. ii, p. 245.

such as that described by Gluck, consisting of (*a*) an external tracheotomy canula for breathing, (*b*) an internal canula, possessing a valve which closes during expiration and causes the air to pass upwards to another compartment containing a small rubber band or tongue, the vibration of which forms the voice, and (*c*) a third tube of rubber, which is easily fitted to the upper part of the inner canula and is of sufficient length to reach the mouth. When the patient wishes to speak, the upper end of the last-mentioned tube is either placed in the angle of the mouth or passed through the nose to the back of the pharynx, and the air which has been made to vibrate in the inner tube is thus carried to the mouth.

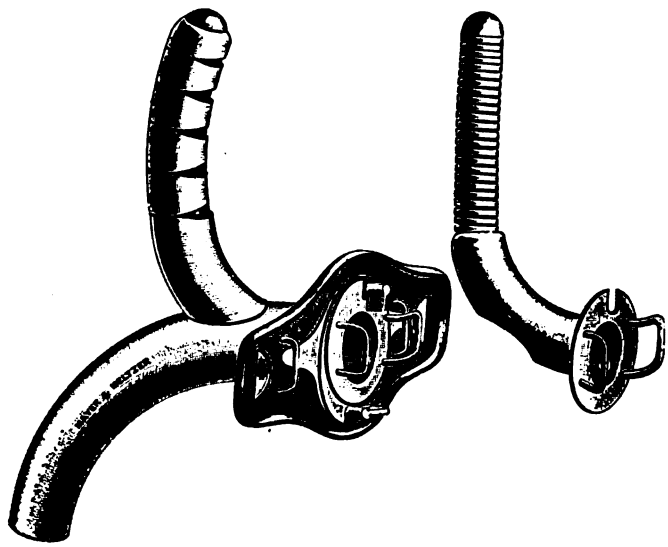

FIG. 255. MODIFIED VON BRUNS'S PHONATION TUBE.

This instrument is easy to adjust and clean, and produces remarkable phonetic effects. A modification of von Bruns's apparatus (Fig. 255) for cases where an opening into the pharynx is maintained is also worthy of mention. In some cases, however, a patient can make himself understood without an instrument of any kind. 'A whispered voice remains even after the pharynx has been completely shut off from the air-passages and, as shown by experience, may be developed by practice until it is quite sufficient for the demands of the patient. Hans Schmidt's case has become more or less celebrated, in which, under conditions of this sort, a loud though rough and monotonous voice was developed. One of Mikulicz's patients was even able to sing. Gottstein explains the development of a pseudo-voice by the formation of an air-chamber in the

pharynx and œsophagus, which is voluntarily inflated and emptied by the patient' (von Bruns).

Swallowing after laryngectomy is satisfactory, and the general health in many cases improves. The mental condition of the patient is often disappointing. 'Even in favourable cases, when the tumour does not recur after laryngectomy, the patient finds himself in such a condition of inferiority to his fellows, that he may, with some reason, ask himself (at least in certain cases) whether death would not have been preferable to such an existence as is left to him' (Moure[1]). With recurrence of the disease the patient's life is terribly sad.

It must therefore be admitted that laryngectomy is at present an operation of necessity, suitable for certain cases only, capable of prolonging life, and, rarely, of curing the patient. It is difficult to foreshadow the future of this operation; but, in the words of Gluck, 'our first object must be to save life; our next, to leave the patient in such a physical condition that the life so saved is worth living.'

The above statistics are sufficient to show that the results of laryngectomy for extrinsic disease compare unfavourably with the results obtained by thyrotomy in intrinsic forms of cancer. In this country there have not been sufficient cases to estimate accurately the percentage of recoveries. The disease may recur at any period after the operation, and the prospect of a cure is always doubtful.

It is, however, to be hoped that, with improved methods of examination, earlier diagnosis, and a careful selection of the cases, better results will in future be obtained. Authorities such as Butlin and Semon support this view, and agree that further attempts must be made to make this operation successful.

INFRATHYREOID LARYNGOTOMY

In order to avoid confusion with other operations included under laryngotomy, this term is used to denote the operation in which the larynx is opened through the crico-thyreoid membrane. The operation is an easy one in adults, but in children the crico-thyreoid space is so small that it is almost impossible to introduce a tube without division of the cricoid cartilage (see Crico-tracheotomy, p. 568).

A tube introduced through the crico-thyreoid membrane lies in the subglottic space well below the vocal folds, and the latter should not be injured when the operation is performed with care. If inflammation supervenes, there may be a swelling of the subglottic region, making the tube difficult to manipulate; and for this reason the operation is

[1] *Brit. Med. Journ.*, 1903, vol. ii, p. 1148.

particularly suited to cases which require a tube for a short period only such as—

Indications. (i) Sudden laryngeal obstruction due to impaction of food or other foreign body. This is more common in adults: in children dyspnœa is rarely so urgent as to necessitate an operation.

(ii) Sudden œdema of the larynx caused by trauma, fracture, or acute inflammation, when the equipment for tracheotomy is not obtainable; or,

(iii) As a preliminary to major operations upon the upper air-passages, in order to prevent blood from passing down into the trachea.

This last method of treatment marks a distinct advance in the surgery of the throat. Attention was first directed to it by Bond,[1] who has used the method for the past sixteen years with intent to make such operations less dangerous to life, and to increase, therefore, the number of cases that could be operated upon. His objects were to prevent respiration through the pharynx, thus obviating the coughing and struggling due to imperfect anæsthesia and making the anæsthetic easier and safer to administer; to shorten the operation and make it easier for the surgeon; and to get rid of preliminary tracheotomy whenever possible.

FIG. 256. INFRATHYREOID LARYNGOTOMY. Position of the incision.

The value of this practice is well recognized by many surgeons. Butlin wrote: 'I do not know how many times I have employed this preliminary laryngotomy, but certainly more than a hundred times, so that I am now in a position to urge the importance of it on the profession.' It has now been adopted at many of the hospitals in England before removal of tumours in the naso-pharynx, the upper and lower jaw, the tongue, palate, floor of mouth, and tonsil, in those cases where bleeding is likely to be severe.

In order to ascertain the feeling of my colleagues on this subject I have collected a large number of the major operations performed

[1] *Brit. Med. Journ.*, 1907, vol. i, p. 7.

upon the upper air-passages during the last eleven years at St. Bartholomew's Hospital. These are tabulated below.

TABLE SHOWING OPERATIONS UPON THE UPPER AIR-PASSAGES DURING THE YEARS 1902–12 INCLUSIVE AT ST. BARTHOLOMEW'S HOSPITAL

	With Laryngotomy.		*Without Laryngotomy.*	
	Cases.	*Deaths.*	*Cases.*	*Deaths.*
Excision of Tongue	26	4	18	3
„ „ half Tongue	37	2	92	1
„ „ Floor of Mouth	19		20	1
„ „ Tongue and Floor of Mouth	12	1	3	1
„ „ Palate	11		3	
„ „ Upper Jaw	20		16	
„ „ Lower Jaw	3		15	1
„ „ Tumour of Gums	1			
„ „ Tonsil	6		6	1
„ „ Naso-pharyngeal Tumour	3			
Total	138	7	173	8

From this table it will be seen that in operations for excision of half the tongue laryngotomy was only performed in 28.3% of the cases. In other operations, however, it was performed in 55.5%. There is also evidence to show that laryngotomy has to some extent taken the place of preliminary ligature of one or both linguals. The former operation is simple, rapid, and meets all requirements.

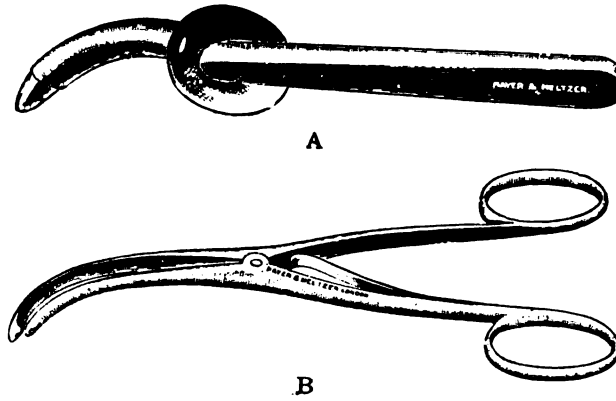

A

B

FIG. 257. INSTRUMENTS FOR LARYNGOTOMY. A, Tube and introducer (Butlin's); B, Sharp-pointed dilator (Bailey's).

Operation. In cases of extreme emergency the operation can be performed with almost any kind of knife, but the following instruments are preferred: a sharp-pointed bistoury or tenotome, a sharp-pointed dilator (Fig. 257, B), a tube and introducer. The tube should be small, short, with a fixed collar, and made of silver; an introducer such as Butlin's is a great advantage

(Fig. 257, A). As bleeding may occur, it is necessary to prepare dissecting forceps, retractors, pressure forceps, and catgut.

A general anæsthetic is usually employed when infrathyreoid laryngotomy forms the first stage of the main operation, but it should be remembered that the amount of chloroform required is less when given through a tube.

The preparation of the skin and the position of the body are the same as for tracheotomy. A transverse incision one inch in length is recommended, and this should lie directly over the crico-thyreoid interval, which is easy to determine in the adult. The incision can be made quickly by pinching up a vertical fold of skin, transfixing immediately above the cricoid, and cutting outward: with this method the anterior

FIG. 258. LARYNGOTOMY CANULA FITTED WITH INNER TUBE. Funnel for administration of anæsthetic.

jugular veins are rarely wounded, but if any vessel has been pricked it should be seized and tied at once.

The sharp dilator, placed exactly in the median plane immediately above the cricoid, is pushed backwards between the infrahyoid muscles until the resistance caused by the crico-thyreoid membrane is reached. It is then firmly stabbed into the larynx and widely dilated so as to tear open the membrane: the dilator having been withdrawn, the tube, with tapes attached and mounted upon the introducer, is rapidly inserted, a proceeding which is made easier by first smearing the instrument with a small amount of glycerine. The whole operation can be performed in less than a minute, and is rarely attended by serious hæmor-

rhage; moreover, when the original puncture is immediately above the cricoid there is less danger of wounding the crico-thyreoid artery. The operation is attended by few difficulties, and is superior to one in which dissection or cutting is employed.

At this stage a prolonged period of apnœa is usually encountered, and this symptom is more marked than with tracheotomy; when seen for the first time it may be alarming, and it is therefore of practical importance. In a few moments, however, the patient settles down to the altered conditions of respiration; coughing may be excited but soon disappears. When the breathing becomes regular, the tapes are tied round the neck and a rubber tube is attached (Fig. 258) similar to that used with Hahn's apparatus, and through the tube the chloroform is continued. This method has the following advantages: it gives far more room to surgeon and anæsthetist, and enables the latter to manipulate the laryngotomy tube and to prevent it from tilting in such a way that the lower end impinges against the front of the trachea with consequent obstruction; further, the opening into the larynx is completely blocked, blood and lotion being unable to enter from outside.

As soon as true anæsthesia with regular automatic breathing has been obtained, the lower part of the pharynx should be plugged with a soft marine sponge to which a piece of tape or silk is attached, this being pushed down behind the tongue and firmly wedged in position; it is advisable to use a large sponge, as this blocks the pharynx and pushes forward the tongue, an advantage to the surgeon when operating upon that structure. If the mouth be obstructed by a tumour, the same result can be obtained by two or more smaller sponges passed in succession; or, as suggested by Bond, a small sponge may be pulled down into the larynx. As soon as the pharynx has been completely shut off, the main operation can proceed, and those who have once used this method can appreciate how much more quickly it can be performed and how much more comfortably for all concerned.

At the conclusion of the operation, when all bleeding has been controlled, the laryngotomy tube should be removed. The wound should not be sutured or plugged, and only a light dressing should be applied; the latter can be kept in place by a bandage, which, however, must on no account be tight, owing to the danger of emphysema.

Complications may arise—(*a*) *During the operation.* There may be troublesome bleeding owing to pricking of a vein, superficial or deep, or of the crico-thyreoid artery; this occurred in eight of the cases mentioned above, and in four was severe. In one of the latter the bleeding continued for thirty minutes before the vessel was finally secured. The condition is simple to treat: the wound must be enlarged, and the infrahyoid muscles separated so that the crico-thyreoid membrane is thor-

oughly exposed; the bleeding vessel can then be seized and tied, after which the tube is inserted. This is preferable to attempting to stop the bleeding by the introduction of the tube.

Difficulty in introducing the tube may occasionally occur. It may be due to imperfect division of the membrane; thus in one case the tube was passed down between the coats of the larynx and not within its cavity; and another case is recorded where the mucous membrane was similarly pushed backwards owing to the dilator having split the cricoid cartilage. Care must be taken, therefore, that the membrane is properly punctured, and that the opening is thoroughly dilated before any attempt is made to introduce the tube. Replacement of the tube was necessary in only one case, on the second day, owing to recurrence of bleeding from the wound in the mouth.

(*b*) *After the operation.* Emphysema occurred in six of the 138 cases; in two it was slight; in three it was extensive and involved the chest, neck, and face; and in one, where death supervened twelve hours after the operation, there was emphysema of the mediastinum. In two of these cases the laryngotomy wound had been sutured; in two others the operation was attended with severe hæmorrhage, and the mouth was plugged with gauze to control it. It is probable that emphysema is more likely to occur if there is any obstruction to breathing through the mouth after the operation, such as may be caused by the falling back of the remaining part of the tongue. The following precautions should be observed to prevent it: The laryngotomy wound must always be left open, and covered by a loose piece of gauze which does not press upon the neck; the patient must be nursed on his side, not upon the back; suturing the remaining part of the tongue is not sufficient; if plugging is left in the mouth, the tube must be temporarily retained, and removed after a few hours when breathing is not obstructed; early removal, however, is preferred.

Bronchitis is mentioned in three of the cases already quoted, pneumonia in one case, pneumonia and empyema in one, and purulent mediastinitis in one, with three deaths in all. Of these six cases, four had operations upon the tongue. On the other hand, without laryngotomy, bronchitis was more common (eight cases, one death) and bronchopneumonia occurred in four, all of which died. In order to throw more light upon the subject, we have examined the charts of all the cases after the operation, and have found that in most of them there was a rise of temperature to 99° F., or slightly higher, which lasted for periods varying from one to seven days; the pulse and respiration were little affected. In laryngotomy cases there were only eighteen instances of temperatures of over 100° F., as against twenty-five where no laryngotomy had been performed. Here again the pulse and respiration were

only slightly affected, so that the condition was probably due to local inflammation and not to involvement of the lung. The results are by no means conclusive, but justify the general feeling that laryngotomy does not increase, but probably diminishes, the danger of infection of the lungs.

Healing of the wound may take place in normal conditions in about five days, but the period is frequently longer—from ten to twenty days: suppuration is uncommon, and was only mentioned in two instances where the wound had been sutured. The scar left after laryngotomy is often depressed for several months, but eventually becomes loosened and is then scarcely noticeable.

Death occurred in seven cases, but there was no evidence to show that there was any connection with the laryngotomy; on the contrary, the operations were more severe, and infrathyreoid laryngotomy was per-

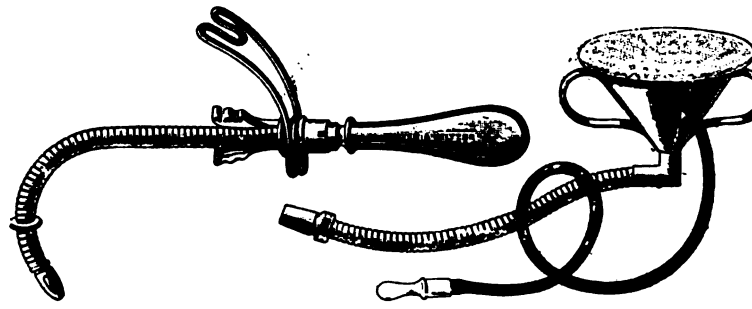

FIG. 259. KUHN'S PERORAL INTUBATION APPARATUS.

formed partly for the very reason that the condition of the patients was less favourable.

From my experience, the advantages which were originally claimed by Bond, Butlin, and others have been completely upheld; the larger operations upon the upper air-passages are easier to perform and can be more thoroughly completed; and it is very possible that the after-results may be improved by the greater facility which is thus afforded. I would strongly urge laryngotomy in all large operations of this region; the tube should be removed early, and the wound should not be sutured.

In this connexion it is necessary to refer to *Kuhn's peroral intubation method,* and the *Intratracheal ether apparatus* devised by Gask and Boyle,[1] which are also of great value in these cases and do away with the necessity for laryngotomy.

W. G. Howarth, who has had considerable experience of Kuhn's method, informs me that he has used it successfully for major operations on the base of the tongue, the tonsil, pharynx, nasal part of the pharynx, and thyreoid gland. In no instance was there the slightest anxiety

[1] *Lancet,* November 30, 1912, p. 1520.

that blood or secretion was entering into the air-passages. Even when the tube remained in position for two hours there were no ill-effects beyond slight hoarseness and irritability of the larynx.

Kuhn's apparatus consists of a flexible metal tube with a blunt conical end (Fig. 259). There are three lateral holes and a small collar close to the tip of the tube. The upper end is of solid construction and has two metal plates upon which the teeth may be closed. A funnel and tube can be attached for administration of the anæsthetic as with laryngotomy (Fig. 258). An auscultation tube connected with the funnel enables the anæsthetist to listen to the breathing. For youths a tube 11½ cm. in length and 9 mm. in diameter is useful and for adults one of

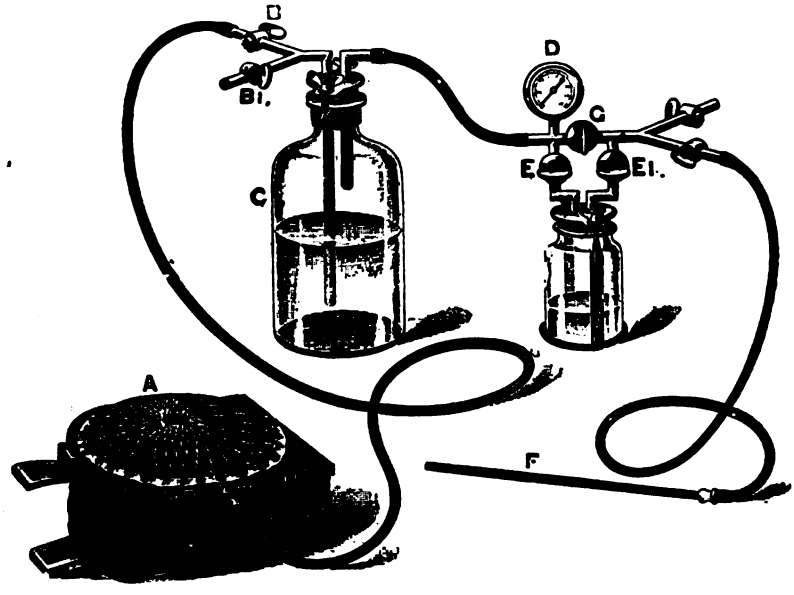

FIG. 260. INTRATRACHEAL ETHER APPARATUS OF BOYLE AND GASK.

13 cm. by 10 mm. A solid mandarin fits inside the tube and can be bent to the requisite curve. The method of introduction is similar to that of intubation, and to facilitate the operation cocaine may be applied to the upper opening of the larynx. The mandarin is withdrawn as soon as the end of the tube has entered the subglottic space. After intubation, gauze plugs should be inserted into the pharynx as with laryngotomy.

The apparatus of Gask and Boyle (Fig. 260) is mainly intended for intrathoracic operations, but is also of service in some operations on the upper air-passages. With this instrument air laden with ether can be pumped into the trachea, and it is claimed that when once the catheter is inserted there is a perfect form of artificial respiration, for the lungs can be aerated at will.

CHAPTER III

OPERATIONS UPON THE TRACHEA

TRACHEOTOMY

THERE is evidence to show that this operation was known to the ancients, and that it has been practised during at least two thousand years, chiefly for the treatment of foreign bodies in the air-passages. From the sixteenth century to the present time it has been frequently performed, and the discovery of diphtheria in 1881 by Bretonneau opened up a new field for the operation.

It is uncertain when tubes were introduced in the after-treatment of tracheotomy, but Dr. George Martin, in 1730, was the first to describe a double tube which allowed of the removal of the inner part for purposes of cleaning. The movable collar was invented by Luer, and the angular tube now generally used is associated with the name of R. W. Parker, to whose research we owe many of the recent improvements in connexion with this operation.

Indications. Obstruction to respiration is the most important, and must be distinguished carefully from the dyspnœa which is due to pulmonary affections, disease of the heart, or organic lesions in other parts of the body. Laryngeal obstruction may be due to—

(i) *Diphtheria.* The extent to which diphtheritic obstruction has to be taken into account is shown by the following table:

TABLE SHOWING THE NUMBER OF CASES ADMITTED TO THE FEVER HOSPITALS OF LONDON (M.A.B.) DURING THE YEARS 1902–12, INCLUSIVE [1]

Year.	*All Forms of Diphtheria.*			*Laryngeal Cases.*			*Tracheotomy Cases.*		
	Cases.	*Deaths.*	*Mortality per cent.*	*Cases.*	*Deaths.*	*Mortality per cent.*	*Cases.*	*Deaths.*	*Mortality per cent.*
1902	6,839	741	10.8	639	134	20.9	264	86	32.5
1903	5,422	504	9.3	560	102	18.2	223	67	30.0
1904	4,639	464	10.0	659	116	17.6	247	79	32.0
1905	4,224	346	8.2	706	116	16.4	255	72	28.2
1906	4,937	444	9.0	702	127	18.1	275	101	36.7
1907	5,674	544	9.6	981	169	17.2	432	129	29.9
1908	5,247	507	9.6	861	149	17.3	359	101	28.1
1909	4,668	429	9.2	910	154	16.9	368	121	32.9
1910	3,567	281	7.9	668	86	12.9	242	55	22.7
1911	4,730	429	9.0	862	135	15.6	317	95	29.9
1912	4,905	331	6.7				261	64	24.5
Total	54,852	5,020	9.1	7,548	1,288	17.1	3,243	970	29.9

[1] *Metropolitan Asylums Board's Ann. Rep., Med. Supplement,* 1902–12. I am

An examination of the above figures shows that in recent epidemics 14% of the cases developed symptoms of laryngeal affection; that about 43% of these laryngeal cases were treated by tracheotomy (in some cases preceded by intubation); and that the mortality in all the cases of tracheotomy was 29.9%. Tracheotomy in diphtheria, therefore, must still be regarded as a serious operation.

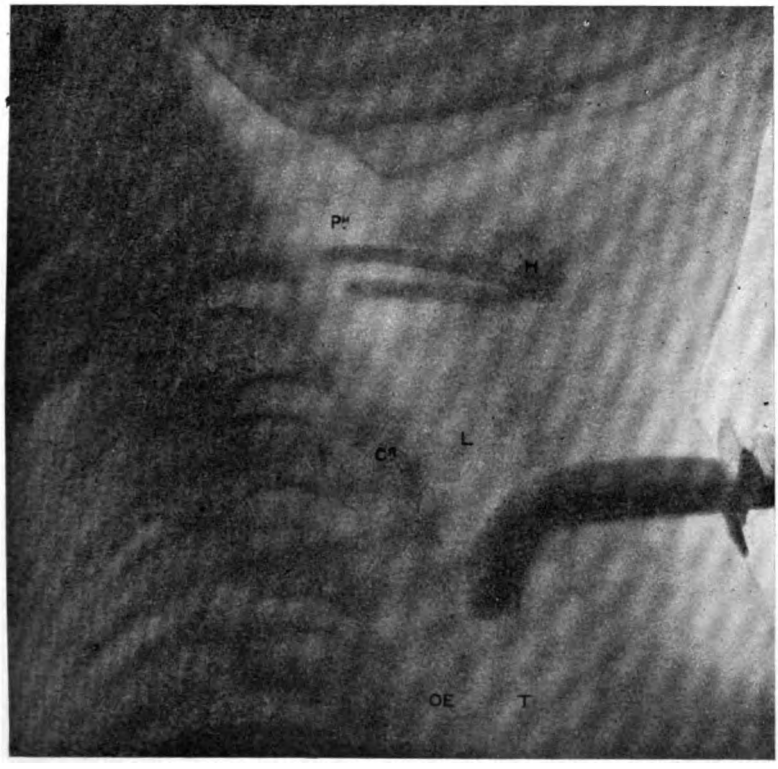

FIG. 261. SKIAGRAM SHOWING AN ANGULAR TRACHEOTOMY TUBE IN THE TRACHEA. H, Body of hyoid; PH, Pharynx; CR, Posterior place of cricoid; L, Larynx; OE, Œsophagus; T, Trachea.

The operation is required chiefly during the early years of life, namely, from one to six (see table on p. 582). Although the larynx cannot be inspected in children, it is easy to determine whether mechanical obstruction is present; for inspiration is noisy and accompanied by stridor, the voice is lost or reduced to a whisper, and attempts to cough are frequent. The alæ nasi are dilated, the extra muscles of respiration are called into action, and laryngeal excursion is seen. On examining the

indebted to Dr. F. M. Turner for assisting me in the preparation of the tables given on pages 556, 582, 589, and 590.

chest, recession is evident; and during inspiration the supraclavicular fossæ, the intercostal spaces, and the epigastrium are all indrawn. The amount of recession depends more upon the muscles of the chest than upon dyspnœa, and is marked in weakly children. When dyspnœa becomes urgent the restlessness increases, and this is an important indication that an operation is required. In very serious cases the face is drawn, livid, or extremely pale; respiration is deficient, and the chest expansion feeble. An examination of the lungs shows the air-entry to be imperfect; the bases are dull to percussion, and all sounds absent. The action of the heart is feeble, rapid, or intermittent; no nourishment can be swallowed. It is always difficult to determine how much of this collapse is due to toxin; but by relieving the obstruction the most distressing feature of the disease is removed, better aeration of the blood is obtained, and the heart is relieved from strain. The operation also drains the trachea, and the amount of poison absorbed is thus diminished. There is abundant evidence to show that the best results are obtained by early operation, especially in young children, in whom the larynx is comparatively small. It should be remembered that dyspnœa is often worse at night, and that at any moment there may be spasm.

(ii) *Infectious diseases,* such as (*a*) secondary diphtheria, by no means uncommon in the fever hospitals of London: in the five years 1902 to 1906, thirty cases are recorded, with sixteen deaths (53%), a very high mortality; (*b*) scarlet fever or measles, which provided 118 cases in which tracheotomy was performed, with eighty-seven deaths (74.3% mortality); (*c*) erysipelas, small-pox, typhoid fever, influenza, and whooping-cough, which occasionally cause dyspnœa, calling for tracheotomy.

(iii) *Acute laryngitis* (other forms) in which œdema supervenes as the result of septic infection, or of the inhalation of steam, boiling water, or irritating chemicals, or as the result of trauma with or without fracture of the cartilages, or in the course of renal or heart disease. Brandy in excess, and certain drugs such as iodide of potassium, may also cause œdema of the larynx, and two cases are recorded by Fournier where death occurred before tracheotomy could be performed, as the result of taking iodides.

For conditions such as these tracheotomy is better than intubation, and, as the swelling may extend into the trachea, the high operation is not advised. Although the operation should not be undertaken until other treatment has been tried, it is well to remember that collapse of the lung, broncho-pneumonia, and complications, are likely to arise when the obstruction is allowed to persist.

(iv) *Syphilis.* In the tertiary stages of either acquired or congenital

syphilis (rare) the larynx may be affected, and in long-standing cases of over ten years, when the mucosa is much thickened, there is a danger of obstruction. Even when energetic antisyphilitic treatment has been advised the disease may become acute. Tracheotomy may be necessary for the relief of (*a*) œdema, likely to occur suddenly with necrosis, perichondritis, or the breaking down of gummata; (*b*) fibrous stenosis, which may cause a gradual increase of dyspnœa or become suddenly acute from spasm or œdema (iodides?); (*c*) adhesions, whether simple bands or webs; or (*d*) fixation of the vocal folds in the median line, resulting from inflammation of the laryngeal joints or from paralysis of the abductor muscles.

(v) *Tubercle.* This rarely causes true laryngeal obstruction, excepting in those acute cases where subglottic œdema, abscess, or sequestrum is present. Tracheotomy was at one time used in certain cases in order to give complete rest to the larynx, but this has been abandoned as unsatisfactory; it should not be performed unless there is urgent laryngeal obstruction, since 'it has many and grave disadvantages. It materially diminishes the efficiency of the cough, the secretion from the lungs is apt to accumulate in the bronchi and alveoli, and set up miliary tuberculosis. Again, the patient can often ill withstand even this slight operation; his power of speaking is diminished or lost and his mental anxiety is increased. Not rarely, also, the tracheotomy wound becomes infected with tubercle. For these reasons tracheotomy should never be performed in phthisis except for severe dyspnœa' (Lack [1]).

(vi) *Certain nervous diseases,* such as abductor paralysis. Urgent dyspnœa may occur in (*a*) advanced bilateral abductor paralysis, or (*b*) unilateral abductor paralysis associated with pressure upon the trachea by tumours. In the bilateral form it is difficult to determine when to operate; but the danger of suffocation, increased during the night, makes it necessary to overrule the objections of the patient. Tracheotomy (or intubation) may be performed merely as a temporary relief where the paralysis results from diphtheria, syphilis, toxic neuritis, &c.; in more serious cases the tube must be worn permanently, unless total recurrent paralysis supervenes (as it may do, though rarely in tabes) accompanied by cadaveric position of the cords and the restoration of free breathing. This latter condition can be induced by total division of both recurrent nerves, but the operation, which has been performed on one or two occasions, has not been attended with satisfactory results. In cases of long duration the tube may be plugged during the day, or a valve may be added to the canula, so that the patient can speak by expiration through the larynx.

[1] Cheyne and Burghard, *Manual of Surg. Treat.*, 1901, Pt. v, p. 449.

(vii) *Tracheal compression* by tumours of the neck or mediastinum, of the thyreoid or thymus, or by aneurysm, or by tuberculous bronchial glands. In these conditions inspiration and expiration are equally affected, and, if the obstruction is low down, a long canula (such as König's, Kocher's, or Salzer's) will be required in order to relieve the dyspnœa. The pressure of such tubes may cause ulceration of the wall of the trachea, and hæmorrhage may occur. This danger is especially to be feared when an aortic aneurysm presses upon the trachea (see p. 581).

Tracheotomy should, therefore, be reserved for extreme cases, where it is impossible to remove the cause of the obstruction: on the other hand, dyspnœa caused by tumours of the neck which are removable (*e. g.* thyreoid tumours) should be relieved by radical operation without tracheotomy.

(viii) *Congenital laryngeal stridor*, glottic spasm, laryngismus stridulus, epilepsy, congenital webs and diseases of the crico-arytænoid joint such as ankylosis (true or false) or luxation. In these cases tracheotomy is rarely necessary, but when the operation is advisably undertaken the dyspnœa may require a permanent tracheotomy tube or prolonged intubation unless a radical removal of the disease can be effected.

(ix) *Cut-throat.* Tracheotomy is advised as a preliminary to further plastic operations in all cases where any part of the air-passages has been opened, in order to avoid the danger of suffocation and to prevent hæmorrhage into the trachea.

(x) *Fracture* of either the hyoid, thyreoid, or cricoid cartilage, that of the thyreoid being the most common, and of the cricoid the most serious. These fractures are always associated with hæmorrhage and œdema of the mucous membrane, sometimes with emphysema; and the swelling thus caused within the larynx may be so great that tracheotomy or laryngotomy becomes urgently necessary for the relief of dyspnœa. Theoretically it is advisable to expose the fracture, so that it may be sutured or wired in its proper position, but, even in those instances where this is attempted, it is advisable to retain the tracheotomy tube for a few days until all swelling has subsided.

(xi) *Sudden dyspnœa during surgical operation,* due to—

(*a*) Mechanical obstruction to respiration, such as is caused by impaction of foreign bodies within the larynx (tooth-plates, teeth, blood, pus, vomited food, &c.), by faulty position of the head or falling backwards of the tongue, by a swollen condition of the larynx, by tumours or abscesses (retropharyngeal) which obstruct the air-way, by cicatricial contraction of the pharynx or larynx, by paralysis of the vocal cords, or by spasm of the muscles of the jaws so often associated with a similar

condition of the glottis and auxiliary muscles of respiration. In a case reported by Boyle, a well-nourished muscular man was anæsthetized for the operation of internal urethrotomy; considerable difficulty was encountered with his breathing, and only towards the end of the operation was it discovered that he had well-marked stenosis of the upper opening of the larynx.

The entrance into the larynx of vomited food or blood is certainly dangerous, and may occur during the simplest operations even when properly performed, as, for instance, during removal of tonsils or adenoids. It is more likely to occur if the patient has not been prepared for an anæsthetic or if the latter be badly administered, if the laryngeal reflex be lost, if the patient be in a bad position or suddenly moves, or if the surgeon allows too much blood to collect in the pharynx.

(*b*) Failure of respiration from an overdose of chloroform or other anæsthetic. To remedy such conditions it is essential that the air should be expelled from the chest as rapidly as possible. Artificial respiration can only be successful when the air passes freely both into and out of the lungs: in rare instances there may be so much difficulty in maintaining a free passage that tracheotomy should be performed.

(xii) *Multiple papillomata of the larynx.* Here tracheotomy is required for the relief of dyspnœa and as a preliminary to other operations. It has also been suggested as a method of curing the papillomata by giving rest to the larynx. After the performance of tracheotomy the congestion is relieved and the growths decrease in size; in some cases they completely disappear, but the treatment is uncertain and not to be recommended (see p. 522).

(xiii) *Malignant disease of the pharynx or larynx which is too advanced for other forms of treatment.* Palliative tracheotomy may be employed in order to relieve dyspnœa or as a means of giving rest to the larynx. It is most commonly used for cases of extrinsic carcinoma of the larynx: thus C. Jackson reported twenty-nine such cases, in twenty-one of which he advised palliative tracheotomy and in only eight laryngectomy. Of the former, tracheotomy was actually performed in nine, but none of the patients lived for more than thirteen months. It seems doubtful whether tracheotomy has any marked effect in retarding the course of malignant disease, though it sometimes gives relief.

(xiv) *Foreign bodies in the air-passages.* It makes no difference what views are held as to the advisability of tracheotomy in the treatment of these cases. The fact remains that the first essential is the safety of the patient, and, if the dyspnœa is urgent, relief must be afforded. When a foreign substance has been inhaled the surgeon must always be prepared for tracheotomy, and it is not advisable for him

to leave the patient, even for a short interval, without proper supervision. In addition, the operation has been advocated as the proper treatment for all cases of foreign bodies in the lower air-passages: nevertheless, removal by Killian's method gives far better results (see p. 606).

(xv) *As a preliminary to operations upon the upper air-passages.* tracheotomy is rarely necessary, its place having been taken by infra-thyreoid laryngotomy and intubation methods: it is, however, often performed before undertaking the larger operations upon the larynx (see p. 527).

Anatomy. The length of the trachea of an adult is about 4½ inches, of which 2½ inches lie above the level of the sternum; the cervical portion, which consists of eight or more rings, extends from the cricoid cartilage above to the suprasternal notch below. In order to determine the upper limit of the trachea it is advisable to palpate the following structures, which lie in the middle line, from above downwards: namely, the hyoid bone with its greater cornua, the thyreoid cartilage which forms the greatest prominence on the front of the neck, and the cricoid cartilage; in this manner it is possible to detect whether there is any deflexion of the trachea from the median line as the result of a tumour lying in one side of the neck.

The anterior border of the sterno-mastoid muscle on each side is also an important landmark; the two muscles approach each other as they descend to their attachments to the sterno-clavicular joints, thus forming an angle the position of which corresponds to the notch in the manubrium sterni. By drawing a line transversely across the cricoid cartilage to the anterior borders of the sterno-mastoid muscles, a triangular space is marked off which may be described as the tracheotomy triangle (Fig. 256).

Beneath the skin and superficial fascia lie the two anterior jugular veins; these run from above downwards, to communicate with a branch which crosses the median line of the neck, commonly in the lower part of the tracheotomy triangle, and there is an interval between them which is, in most cases, sufficiently large to prevent their being injured by a central incision. The pretracheal muscles, namely, the sterno-hyoids and sterno-thyreoids, are closer together; but the interval can be recognized by the greater thickness of the deep fascia which passes between them. When the latter is incised, these muscles can be separated, and the trachea is exposed, together with the structures that lie on its anterior aspect. These are the following:—

(*a*) *The isthmus of the thyreoid gland*, which varies greatly in size. It may be either a thin band with few vessels of importance, covering

the second, third, and fourth tracheal rings; or hypertrophied and vascular, extending higher in the neck even to the front of the cricoid or thyreoid cartilage. This condition also results when a pyramidal lobe is present.

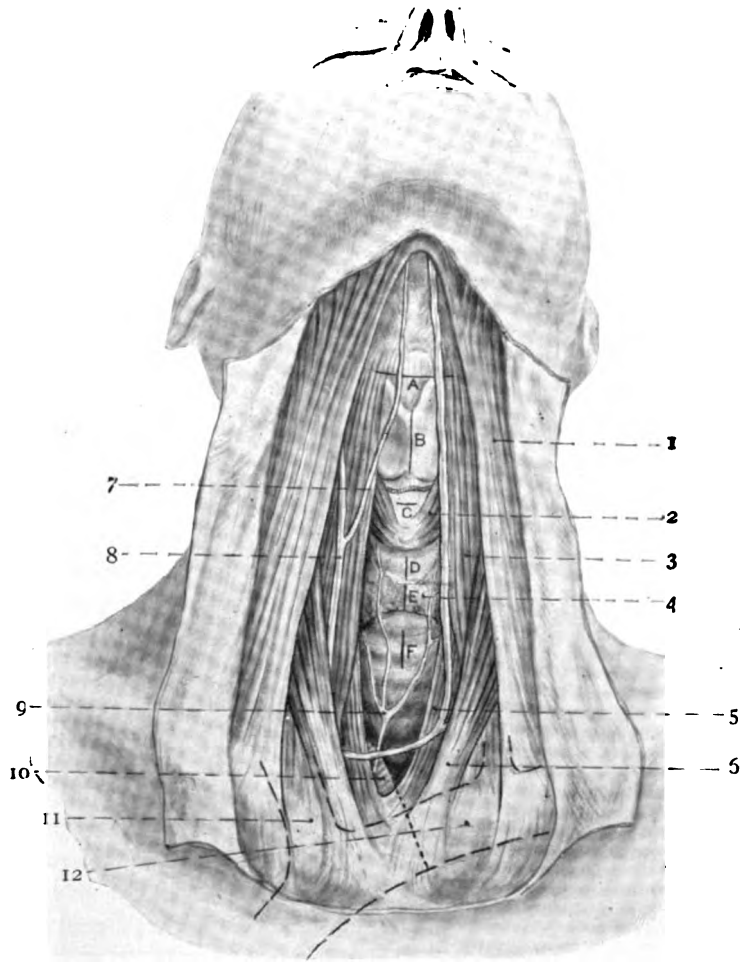

FIG. 262. ANATOMY OF THE LARYNX AND TRACHEA AND THE POSITION OF INCISIONS FOR THE OPERATIONS IN THIS REGION. A, Subhyoid pharyngotomy; B, Thyrotomy; C, Infrathyreoid laryngotomy; D, 'High' tracheotomy; E, 'Median' tracheotomy; F, 'Low' tracheotomy; 1, Platysma; 2, Crico-thyreoid muscle; 3, Sterno-hyoid muscle; 4, Isthmus of thyreoid gland; 5, Sterno-thyreoid muscle; 6, Sterno-mastoid muscle; 7, Crico-thyreoid artery; 8, Anterior jugular vein; 9, Inferior thyreoid vein; 10, Innominate artery; 11, Right innominate vein; 12, Left innominate vein.

(*b*) *The pretracheal fascia,* which encloses the isthmus of the thyreoid gland and, when traced upwards, finds attachment to the anterior aspect of the cricoid cartilage, thus forming the suspensory ligament of the isthmus. Passing downwards it covers the anterior surface of the trachea, and, though somewhat indefinite, can easily be traced behind the sternum as far as the pericardium, with which it blends. This is a point of great practical importance in determining the extension of inflammation into the mediastinum.

(*c*) *Veins.* Small transverse branches of the superior thyreoid veins run upon the upper border of the isthmus between the layers of the fascia which surround this structure. The inferior thyreoid veins, larger in size, run from the lower border of the isthmus vertically downwards in front of the trachea to communicate with the left innominate; in their upper part they may consist of several small veins which join together to form two main branches, of which the left may lie directly in the middle line; small communicating branches of these veins run transversely across the lower border of the isthmus. The left innominate vein crosses the front of the trachea somewhat obliquely, and may lie at least half an inch above the jugular (suprasternal) notch.

(*d*) *Arteries.* The crico-thyreoid artery runs transversely across the crico-thyreoid space, being placed in front of the suspensory ligament, and gives off numerous branches, which enter and supply the interior of the larynx, as well as small descending branches which run to the isthmus of the thyreoid gland. A small branch of the inferior thyreoid artery is also constantly found behind the isthmus, and in rare instances a thyreoidea ima branch of the innominate, varying greatly in size, may pass upwards in front of the trachea.

In young children the same relations are found, but with certain differences. Owing to the larynx being relatively high in the early years of life, the length of the cervical portion of the trachea is almost 2 inches when the head is extended, and the bifurcation is considerably higher than in the adult; further, the trachea is more movable and is smaller in diameter. The laryngeal cartilages are difficult to distinguish, but a mass composed of the thyreoid and cricoid cartilages can always be felt, and its position determined by careful inspection. It is very important to remember that, even when the head is extended, the cricoid cartilage lies rather less than 2 inches above the upper margin of the sternum. In very young children it is common to find two transverse creases in the skin, of which the upper usually lies over the upper border of the thyreoid and the lower over the cricoid cartilage. The lower crease thus assists in determining the upper limit of the trachea.

The anterior jugular veins in young children are comparatively

large; the infrahyoid muscles are less defined and more difficult to recognize; and the isthmus of the thyreoid gland is very broad, appears to be part of the lateral lobes, and occupies a higher position in the neck, often passing in front of the crico-tracheal membrane as well as the first and second tracheal rings. The inferior thyreoid veins are larger, more numerous, and more difficult to separate; the left innominate vein is somewhat higher in the neck; the thymus gland, which gradually decreases in size with the increase of age, may extend into the neck, in front of the trachea, and may even reach as high as the isthmus of the thyreoid; the fasciæ are softer and less definite, and the fascia which covers the trachea is easily stripped from its surface.

TRACHEOTOMY IN DIPHTHERIA

Operation. As local anæsthetics are of little practical value in the case of children, the surgeon must decide whether a general anæsthetic shall be used; for any nervousness on his part increases the danger of death upon the table. A general anæsthetic is not necessary, but undoubtedly has certain advantages: the operation is easier and can be performed more rapidly; the patient is more likely to fall asleep; and any vomiting that occurs is beneficial rather than harmful. On the other hand, children suffering from diphtheria are apt to die suddenly under chloroform; and it should never be administered when there is any sign of heart failure, when obstruction is very marked, when cyanosis is present, or when the patient is prostrate. The danger has probably been exaggerated, and depends more upon the experience of the anæsthetist than upon the actual disease; in my opinion it is, as a rule, safer to employ a small quantity of chloroform, which should be given on the operating table after everything has been prepared. The child should be allowed to choose its own position, generally curled up on one side, and the administration must be slow. By observing these precautions it usually happens that the child becomes quiet, and that with the loss of consciousness the breathing improves; the child can then be placed in the proper position, and the more difficult part of the operation can be completed before restlessness returns.

The instruments required are: a small scalpel, scissors, two dissecting forceps, three or more fine-pointed pressure forceps, two double hook retractors, one blunt hook, an aneurysm needle, and a suitable dilator for the wound; some form of aspiration apparatus may also, in rare instances, be necessary (Fig. 273). Three or four tracheotomy tubes such as described by Parker, and a small tube containing sterilized catgut, which is eminently suitable for the tying of vessels, and for that pur-

pose preferable to silk, should also be in readiness. All the instruments should be kept together in a metal case, as well for private as for hospital practice, so as to be ready in case of emergency. They should be boiled for at least twenty minutes both before and after each operation, and should be laid out separately upon a dry sterilized towel in the position selected by the surgeon.

Tracheotomy tubes may be made of silver, rubber, vulcanite, celluloid, or a gum-elastic material, but most surgeons prefer a silver tube in the early stages of treatment. An angular form should be used, for 'with the ordinary quarter-circle tube, the lower extremity tends to impinge on the anterior wall of the trachea, and this is attended with many incon-

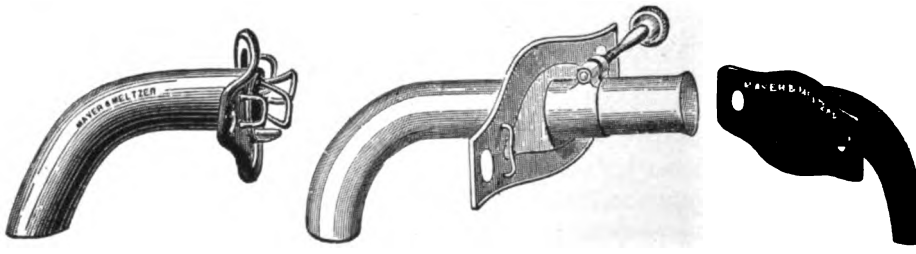

A B C

FIG. 263. TUBES FOR TRACHEOTOMY. A, Parker's; B, Durham's; C, Baker's rubber tube.

veniences and even with grave risks' (Parker[1]). A movable shield is equally important, and this should be flush with the neck in order to avoid the possibility of its being removed by the patient. Further, the tube should consist of two parts—an outer tube to which the shield is attached, and an inner tube which projects slightly beyond the outer and can be removed for purposes of cleaning. To encourage breathing through the larynx, a window may be added in the upper part of the tubes. Parker's tube, which meets all the above requirements, is the one most commonly used in England. When longer tubes are necessary, either Durham's or Stewart's is recommended: in these, the position of the shield can be altered, and the length of the tube arranged, to suit the patient. In cases of long duration the use of rubber tubes such as Morrant Baker's is indicated. An introducer is rarely necessary except for rubber or long tubes. As taper and bivalve tubes are liable to injure the trachea, their use is not advised. The tube chosen should fit loosely, and should project far enough into the trachea to be secure from slipping out during coughing or struggling. Short tubes are preferable, and the wider the tube the easier the breathing and the better the drainage.

[1] *Tracheotomy in Laryngeal Diphtheria*, 2nd ed., p. 42.

The approximate diameter of the trachea varies at different ages, and the size of tube suitable in each case varies chiefly according to the trachea, but partly also according to the fatness of the neck. The accompanying table indicates the appropriate dimensions.

TABLE SHOWING SIZE OF TRACHEA AND OF TUBE REQUIRED AT DIFFERENT AGES.

Age.	*Approximate diameter of trachea.*	*Approximate diameter of tube.*	*Number of tube.*	
			Parker's.	*Durham's.*
6 months	4 mm.	4 mm.	16	—
1½–2 years	6–8 mm.	7 mm.	20	1
2–4 years	8–10 mm.	8 mm.	24	2
4–10 years	10–12 mm.	9 mm.	28	3
10–20 years	12–19 mm.	10 mm.	30	4

Tracheotomy, even under favourable circumstances, is attended by *many difficulties;* the urgency of the case, the restlessness of the patient, the movements of the larynx, the frequent absence of a proper operating table and equipment, the importance of a good light, of sensible assistants, of a trained nurse, and, above all, of a calm disposition, make this one of the most anxious and difficult operations in surgery, yet there is no medical man who may not be called upon to perform it.

It is important to make the best possible preparations. A table of suitable height can usually be improvised and placed in a good light. If the operation be at night, gas lamps or candles can be used, and the illuminant should be placed in a definite position rather than held by the parents. The child should be wrapped in a large towel in order to control the movements of the arms, body, and legs, and should then be placed upon the table; it is advisable to leave him in ignorance of the operation, whatever his age, until the last moment. The skin of the neck should be rapidly washed or sponged with ether, and the head extended over a small pillow or rolled towel. The operation must never be commenced until the proper position is obtained; on the other hand, extension of the head should not be too great for fear of increasing the dyspnœa. Three assistants are preferred—one to hold the head firmly in the middle line so that the point of the chin is exactly in line with the jugular notch (this is probably the anæsthetist), a second to hold the body at the opposite end of the table, and a third to assist the surgeon with sponges or retractors. It should be the duty of the last named to prevent any membrane or pus from being coughed over the principals after the trachea has been opened.

There are four varieties of the operation, *viz.:*

1. *Crico-tracheotomy* (with division of the cricoid cartilage).
2. *High tracheotomy* (involving section of the trachea above the isthmus of the thyreoid gland).
3. *Low tracheotomy* (section of trachea below the isthmus of the thyreoid gland).
4. *Median tracheotomy* (section of trachea through the isthmus of the thyreoid gland).

Crico-tracheotomy is an easy operation owing to the superficial position of this portion of the air-passage, but is inadvisable for the following reasons:

(1) The larynx being narrower than the trachea, a smaller tube is required; (2) the swelling of the mucosa often extends downwards and causes constriction of this region; (3) the tube is not well tolerated; (4) pressure ulcers, necrosis of the cricoid, and granulations are frequent complications; and (5) retained tube is more common than with other operations, this really being the most important consideration. The comparative value of the remaining operations is largely a matter of opinion.

It is not uncommonly stated that tracheotomy is better done by touch than by sight: the object to be achieved is to find the trachea, and there are two methods of doing this. The first is the *deliberate method*, suitable for patients in good condition when there is no urgent dyspnœa: it can be performed entirely by sight, and the greater the experience of the surgeon the fewer his difficulties. In such cases skilful technique is of far greater value than haste. The high operation is preferred, because the trachea is more superficial, less movable, and easier to find; it has less complicated relations, the blood-vessels are less numerous, the fasciæ are not so loose, the tube is easier to fit and unlikely to slip out, healing of the wound is more rapid, and complications seldom occur. In cases where the isthmus is very broad or highly placed, so that the upper parts of the trachea and cricoid are covered, a median operation is recommended. Low tracheotomy is rarely necessary.

The second is the *rapid method*, to be applied in cases of emergency. Turner, of the South Eastern Hospital, strongly advocates such an operation without an anæsthetic. The incision made is from ½–⅝ of an inch in length, this being repeated without attention to the bleeding until the trachea is reached. The latter is opened in the usual manner. The tip of the finger is placed in the wound in order to control the hæmorrhage, and as a guide to the dilators. When these have been introduced, the child is at once drawn beyond the end of the table so that the head hangs downwards. The bleeding usually ceases in a few moments, though

in some cases the tube is inserted to control it. The advantages claimed for this method are that the operation is quicker, and that no distinction between 'high' and 'low' is required. The wound is smaller, there is less danger of sepsis, and the eventual scar is hardly visible; no hooks or retractors are used, so that the trachea cannot be displaced. If the wound be in the middle line it is impossible to miss the trachea. This operation is performed entirely by touch, and the bleeding is not considered. Its adoption may be necessary to save the patient's life, but in the hands of an inexperienced surgeon the operation is attended with great difficulties.

High tracheotomy. The incision must be exactly in the middle line; this can be accomplished easily if the surgeon keeps in mind two important landmarks, namely, the point of the chin, and the jugular notch. To determine the upper end of the incision, a point is chosen midway between the anterior borders of the sterno-mastoid muscles at the level of the cricoid cartilage. The thyreoid cartilages being steadied between the fingers and thumb of the left hand, a bold incision is made from the upper point, 1½ inches in length, extending in a young child almost to the jugular notch. A long incision is generally preferable, and, when the neck is fat, should commence over the middle of the thyreoid cartilage. The skin and superficial fascia are divided between the two anterior jugular veins and any bleeding is controlled. The incision is repeated so as to divide the deep fascia lying between the sterno-hyoid muscles close to one another in the upper part of the incision, and these are separated with the knife. It is now advisable to pause and to seize the bleeding-points, allowing the pressure forceps to fall on both sides of the wound to act as retractors. The infrahyoid muscles are separated by at least an inch, and, if retractors are necessary, care must be taken that the muscles alone are included and that the retraction is equal on the two sides. If there has been no 'tailing' of the wound the following structures are then exposed from above downwards: the lower border of the thyreoid cartilage, and the front of the cricoid, both easily seen or felt; and a vascular mass, namely, the isthmus of the thyreoid gland, covered by fascia and completely concealing the trachea. The landmark that is required at this stage is the cricoid arch; this should be found, and a small transverse incision should be made along its lower border to divide the suspensory ligament; the handle of the scalpel or a blunt hook is introduced beneath the pretracheal fascia, and the isthmus dragged downwards into the lower portion of the wound, an operation which can be accomplished easily if done without hesitation. The upper rings of the trachea are now exposed; and, unless the superficial veins have been divided, there should be no bleeding. The trachea

should not be opened until it has been exposed completely and all bleeding has been arrested. It is unnecessary to ligature the vessels at this stage unless the forceps have been so placed as to interfere with the part of the trachea chosen for section, or an artery of considerable size is encountered; in the latter instance there is a danger of subsequent hæmorrhage if the ligature is applied close to the tube. While the trachea is being opened, it is necessary to overcome the movements of the larynx by grasping the cricoid with the finger and thumb of the left hand. The scalpel should be gently stabbed into the middle of the trachea to ensure puncturing the mucous membrane as well as the outer wall, and the opening should be quickly enlarged in an upward direction until three rings have been divided, preferably the first, second, and third. It is imperative that this incision should be in the median line, should not be too small, and should only pass through the anterior tracheal wall: if force be used there is danger of puncturing the œsophagus, or even of striking the bodies of the vertebræ.

At the moment when the trachea is opened there is a sudden rush of air out of the lungs. This is reassuring to the surgeon, and at this point the dilator should be introduced and the anæsthetic abandoned. Temporary cessation of breathing is common after the first inspiration, but the great improvement in colour shows that there is no cause for alarm; with the return of consciousness the child begins to cough, and this has two results, partly clearing the tubes of mucus, pus, or membrane, and partly promoting deeper inspiration and better expansion of the lungs. Cyanosis is thus speedily removed, unless membrane is abundant; and even where this is the case it is advisable to encourage coughing in order to dislodge the membrane, which can be grasped with forceps or caught with a sponge as it appears in the wound. The use of a feather or a soft rubber catheter for irritation of the trachea to promote coughing should be abandoned, as such instruments often displace the membrane downwards. As soon as breathing is regular and the cough allayed, the vessels can be ligatured.

A tube of suitable size having next been selected, the opening in the trachea is widely dilated and the point of the canula quickly inserted into position, the outer tube alone being used, with tapes for tying attached. Unless the tube 'sits' well without tilting, different sizes should be tried until the breathing becomes easy, a sure sign that the lower opening of the canula is pointing in the right direction. The tapes are tied firmly on the right side of the neck, after which the inner tube is introduced and fixed in position.

The wound remains to be treated. Various methods have been recommended to guard against infection: the use of antiseptic watery

solutions, such as perchloride of mercury, chloride of zinc, carbolic acid, and perchloride of iron, is dangerous; insufflation of powders, on the other hand, such as orthoform, aristol, and the like, is certainly effective in keeping the wound clean, and is better than the employment of an oil emulsion; suturing the wound is unnecessary and is not recommended. A dry antiseptic gauze is applied to the wound and kept in position by the pressure of the shield. Lastly, a thin covering of gauze is placed over the front of the neck, and the patient returned to bed.

Low tracheotomy. The incision should be rather longer than in the 'high' operation and should reach almost to the jugular notch. The fasciæ, anterior jugular veins, and infrahyoid muscles are treated as before, and there must be no 'tailing' of the wound. The landmark required is the isthmus of the thyreoid gland, and its lower border must be determined and dragged upwards by a blunt hook. It is important to remember that the lower part of the trachea lies deeper in the neck and is more difficult to expose owing to the blood-vessels that lie anterior to it; the thymus gland, also, may extend upwards and require to be retracted. Whereas in high tracheotomy practically the whole operation is best done by clean cutting, in the lower operation this is more dangerous, and the deep dissection must be performed partly with forceps or blunt director; if an artery be divided or venous bleeding occurs, it should be controlled immediately. No attempt should be made to perform this operation rapidly owing to the relations of the parts; nor should the trachea be opened before its rings are exposed thoroughly, as complications may arise after imperfect division of the pretracheal fascia. In the opening of the trachea and the further stages, the operation is similar to high tracheotomy.

Median tracheotomy. The child being placed in the required position as before, an incision is made, from the lower border of the thyreoid cartilage almost to the sternum, through the skin and superficial fascia. With a series of cuts, exactly in the line of the original incision, the fascia lying between the pretracheal muscles is divided; the bleeding-points are seized with pressure forceps, and retractors are introduced to expose the isthmus. The isthmus itself is treated in one of two ways: in urgent cases it is boldly divided by one or two cuts of the knife; but if time can be spared, a threaded aneurysm needle may be passed under it, first on one side and then on the other, after which the needle is withdrawn, and the two ligatures can be tied so as to leave between them a space of one-third of an inch in which a cut can be made without hæmorrhage. The tracheal rings are thus exposed and can be divided as before.

Accidents. The accidents that occur are less numerous than might be expected when it is considered how often this operation is

performed by those who are quite unpractised in surgery; many of them are the direct result of inexperience or arise because the operator becomes confused. If the patient be in a bad position, or if a wrong incision be made, the trachea is difficult to find, and it is better to expose the thyreoid cartilage and prolong the incision downwards until the windpipe has been discovered.

Hæmorrhage, however, is the chief difficulty, and is sometimes unavoidable; it may be arterial or venous. The arteries of this region are generally small, being branches of the superior or inferior thyreoids, and this accounts for the fact that severe arterial bleeding is rare. Nevertheless, the smaller vessels may at times be very troublesome: for instance, the crico-thyreoid artery or one of its branches may be divided, in which case the cut ends will retract and will be difficult to seize: and if the trachea has been opened, blood may continue to enter in sufficient quantity to cause troublesome coughing. Abnormal arteries, such as the thyreoidea ima, are not of great practical importance.

Venous hæmorrhage is far more common, and, taking into account the anatomical relations of the veins, and their great size (increased by cyanosis) in children, it seems remarkable that bleeding is so seldom fatal; in desperate cases a very small amount of blood is sufficient to cause suffocation. Venous bleeding will stop only when respiration becomes free, and this is not possible so long as blood is being sucked into the air-passages. Every effort should be made, therefore, to prevent blood from passing into the trachea, either by hanging the head over the end of the table as soon as the dilators have been introduced, or by introducing a canula against which the walls of the trachea can be compressed.

Failure to breathe, after an opening has been made, is due to either obstruction or collapse, and requires rapid treatment. The trachea must be widely dilated, and forceps used to remove any membrane which presents itself in the wound; the assistant must then slowly compress the ribs two or three times to empty the chest and encourage respiration. If consciousness returns, the patient begins to cough and mucus or membrane is expelled from the air-passages. On the other hand, it is useless to continue artificial respiration if the obstruction is not relieved; aspiration must be employed if special instruments are at hand. The fact that a number of surgeons have lost their lives as the result of sucking through a catheter in the attempt to save the child is sufficient to condemn this practice; but good results have been obtained by passing a catheter low down into the trachea and blowing through it with a syringe or even with the mouth. As soon as the trachea has been emptied by one of these methods, artificial respiration

should be continued, and collapse treated by injections of strychnine, brandy, or ether. No attempt should be made to introduce a canula until the breathing is restored. As Turner remarks: 'Heart failure during operation generally recovers with artificial respiration, and twelve hours later the condition is indistinguishable from that of a case who has not so closely approached death. The real remedy against such an accident is never to postpone operation until the heart is exhausted.'

After-treatment. Although this is a subject which has produced a great deal of discussion, there is a widespread impression among the younger members of the profession that it is of little importance. Much has been said about the dangers of interference, and any suggestion put forward has been criticised by those who have had large experience, with the result that confusion is prevalent. As a matter of fact, the subject is one of the greatest importance, for there is no operation in surgery in which the after-treatment can be neglected. Care should be exercised in choosing a nurse who has special knowledge of children and of the after-treatment of tracheotomy. Great discretion is required in the management of such cases, and there is little doubt that harm may result where too much attention is shown. At many of the hospitals a special nurse is appointed for attendance on the more desperate cases only. The main duty of the nurse is to watch the child, for any difficulty in breathing requires immediate attention. It is necessary that she should understand the proper management of the tube; she must see that the inner tube never becomes clogged, and if the tube slips out of the trachea it must be reintroduced or a dilator inserted; she must also be responsible for the feeding of the child. The difficulties that arise during the first few days after operation call for much tact and experience.

It is unnecessary to enter here into the discussion about food, stimulants, or general treatment, except to point out that swallowing may be very difficult. The food must be nourishing, fluid being in most cases preferred; occasional sips of water should be administered, to find out whether coughing is produced, in which case nasal feeding can be advised without hesitation. A short rubber catheter should be passed through the nose at regular intervals according to the nature of the case. As a general rule a small quantity of nourishment should be given every two hours, studying, as far as possible, the likes and dislikes of the patient. By the observance of these principles the child soon becomes tolerant, and proper nourishment can be administered, thus removing one of the great difficulties of after-treatment.

The atmosphere of the room. The value of steam for producing warmth and moisture is undoubted; the amount required depends on the case. The main object to be kept in view is to encourage secretion

from the mucous membranes, and so to prevent the formation of crusts. When secretion is scanty a large amount of moisture is required, and vice versa; also, when much pus is present, extra moisture is of value to prevent it from becoming dried and to allow it to be expectorated. The value of disinfectants is doubtful, but on general principles it may be said that the more septic the secretion, the greater the indication for their use: tincture of benzoin, oil of eucalyptus, and thymol act as sedatives, carbolic acid, creosote, and numerous other drugs are useful disinfectants; soda and potash, recommended by R. W. Parker, tend to liquefy the exudations. Steam, however, is more important than all these, and should be advised as being likely to encourage the quicker healing of the wound: even in catarrhal conditions improvement is more rapid when this practice is adhered to.

The most important point in the after-treatment, however, as far as the surgeon is concerned, is to prevent recurrence of the obstruction. Obstruction is most often due to the blocking of the inner tube by secretions, a condition easy to recognize from the symptoms which are produced. The inner tube should be removed, thoroughly cleaned, and reintroduced. This usually suffices to allow the child a period of quiet breathing, and sleep may be obtained. To keep the tube free it is very necessary to repeat the removal at regular intervals. In those cases where the secretion is tenacious, the tube constantly becomes blocked, but it is better to remove it again than to allow a feather to be passed. Nothing is gained by attempting to hurry the separation of crusts, and the passage of a feather tends to force downward far more than can be extracted, and so to increase the danger of broncho-pneumonia. If dyspnœa continues after removal of the inner tube, a spray should be used, or a small amount of fluid should be dropped into the trachea to moisten the secretions.

Changing the outer tube rarely presents any difficulty because the tissues of the neck soon become matted together, a funnel being thus produced along which the canula is introduced with ease. A new tube should be prepared before removal of the old, and dilators should be at hand for use if the child is frightened, struggles, or coughs; the canula should be introduced quickly and without hesitation, sufficient force being employed to overcome any obstruction. Unless the original opening in the trachea was too small, it should be possible to introduce a tube equal in size to that which was removed. Frequent changing of the outer tube should be avoided.

The time for removing the outer tube. In every case of diphtheria there is a certain amount of catarrh, with swelling of the mucosa, increased secretion, and some difficulty of breathing. In addition, the

habit of breathing through a canula is difficult to alter; the child shows an aversion to breathing through the natural air-passages, and is often frightened or bad-tempered. As soon as the secretion becomes small in amount and serous rather than purulent in consistence, an attempt should be made to discard the tube: the canula should not be retained a day longer than is necessary, the usual period varying from five to fifteen days. Various methods may be adopted:

1. If the outer tube be provided with a window, the tip of the finger can be placed on the opening to compel the child to breathe through the larynx; breathing may be difficult, but by this means an indication can be obtained as to whether it is advisable to persist.

2. If the above method be successful, the tube may be removed. A small pad of gauze is placed over the wound and the child further encouraged to breathe through the larynx. Expiration is generally easier than inspiration, and older children should be encouraged to blow out a candle or to sound a whistle, this process being continued so long as the child can endure it, but not to the stage of exhaustion. It is often possible to remove the tube at the first attempt.

3. The canula may be plugged with a cork which the nurse removes when necessary: it is often possible to replace the plug while the child is asleep without his becoming conscious of the fact, thus showing that the dyspnœa is largely mental.

4. In some children breathing is easy so long as the tube is simply plugged and is not removed; in such cases the canula can be replaced by a shield and a plug which does not pass into the trachea. This may completely deceive the child.

5. The silver tube can be changed for one of rubber, and this can be shortened daily until nothing remains but the shield.

If these various methods have been tried with no success it is probable that the case is abnormal, but before this can be conceded it is necessary to repeat that, in the large majority of cases, the difficulty of removing the tube is due not so much to definite stenosis of the larynx as to the bad habit acquired by the patient.

Complications arising after tracheotomy and preventing removal of the tube:

1. *Wound infection.* This rarely occurs at the present time, and diphtheritic wounds are seldom seen. Some inflammation of the wound is natural under the conditions, and may be associated with œdema of the surrounding tissues; this generally yields to antiseptic treatment in a few days. In very weakly children suffering from a virulent form of disease the healing of the wound may be slow, and septic conditions are apt to arise ending in cellulitis of the neck or even typical erysipelas.

Owing to the disposition of the fasciæ there is a tendency for the infection to spread in a downward direction, and for mediastinal inflammation or suppuration to occur: this appears to be more common after low tracheotomy. The prognosis in such cases is not good, and every endeavour should be made to prevent the possibility of their occurrence by absolute cleanliness at the operation and by suitable after-treatment of the wounds.

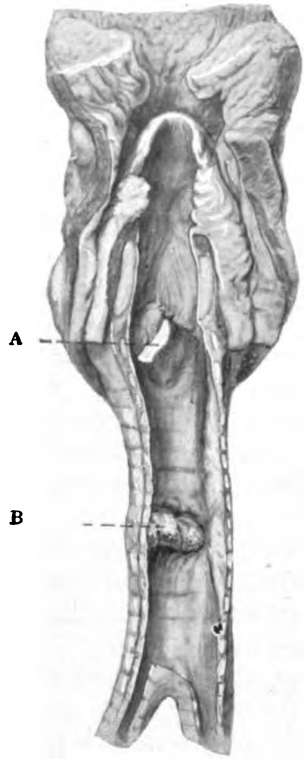

FIG. 264. TRACHEA SHOWING ULCERATION CAUSED BY A BADLY-FITTING TUBE. A, Tracheotomy opening; B, Ulcer caused by the end of the tube. (*From Specimen No.* 1659a *in the Museum of St. Bartholomew's Hospital.*)

2. *Septic conditions* of the trachea are less common since the introduction of antitoxin, but occur in cases where false membrane is abundant. There may be swelling of the mucosa, or copious discharge which persists for long periods.

3. *Ulceration* may be due to sepsis or to pressure from a badly-fitting tube, especially when the latter has been worn for a protracted period (Fig. 264). It may cause perforation and localised abscess either in front of the trachea or in the neighbourhood of the œsophagus, and may result in a communication with the latter. In the region of the cricoid, ulcers are liable to cause necrosis. The signs of such ulceration are: continuance of purulent discharge, discoloration of the tube, bleeding from the wound, and, above all, difficulty in removing the tube.

At the first indication of ulceration the cause of irritation should be removed. It is advisable to discard a metal in favour of a rubber tube, or, if possible, to remove the tube altogether. Strenuous efforts must then be made to disinfect the trachea by the insufflation of antiseptics, either as powders or in solution. The healing of such ulcers is very slow, and granulations are apt to form resulting in obstruction and preventing removal of the tube. In later stages contraction of fibrous tissue causes stenosis; this is more common in the neighbourhood of the cricoid, especially when the latter has been divided at the time of the operation.

4. *Granulations.* The possible presence of granulations must always

be borne in mind. I believe this condition is far less common than is generally supposed, and that in many cases the granulations are entirely limited to the neighbourhood of the wound, where they can be seen. It is doubtful whether they are responsible for the dyspnœa which occurs. Great ingenuity and patience are required for the treatment of this condition. The wound must be kept scrupulously clean and all source of irritation removed. A rubber canula should be substituted in place of a metal one; if it were possible it would be advisable to discard the tube altogether, but as yet no form of dilator has been devised which will take the place of the canula. If the granulations be large they should be removed either with a sharp spoon or with suitable forceps, the area having been anæsthetized previously by a small quantity of the novocaine and adrenalin mixture. When small, the use of silver nitrate is preferable. It may be necessary to repeat this after a few days, and as soon as seems advisable a further attempt should be made to dispense with the tube. At this stage time must be allowed for the various tissues to regain their normal condition. Should this treatment prove unsuccessful, a thorough investigation must be made under chloroform. The wound is enlarged as far upwards as the cricoid, bleeding being arrested with the mixture just described. By throwing a strong light into the wound, the condition of the mucous membrane can be inspected and granulations removed. If there be no granulations in the trachea, a tube speculum can be passed through the mouth to ascertain the condition of the larynx (see p. 600). Such a method of procedure is preferable to the passage of probes, forceps, sponges, and other articles through the larynx, in the hope that any obstruction may be removed. If ulceration or necrosis of cartilage be discovered, it is impossible to relieve the condition by surgical means without prolonged treatment with tubes and the constant use of antiseptics. Under these conditions it is advisable to consider the removal of the tracheotomy tube in favour of intubation. In the hands of many foreign authorities the use of intubation tubes covered with gelatine, in which antiseptic is introduced, has been attended with such conspicuous success that further attempts should be made in this country; there is little doubt that, as our knowledge of the treatment of such wounds improves, better results are daily attained. Whatever treatment is considered, it is important first of all that the actual cause should be distinguished. This is now possible owing to the great advances made in methods of examining the larynx.

5. *Stenosis* of the larynx or trachea occurs in old-standing cases, as the result of ulceration, after some cases of crico-tracheotomy, and especially where a tube has been worn for a very protracted period. Breathing through a tube, if continued for a long time, interferes with

the natural growth of the air-passage above it. The child grows, but the larynx remains stationary. This condition is aggravated by the fact that some inflammation is constantly present, especially in the neighbourhood of the wound, so that the tissue becomes fibrous and hard. The fibrous tissue contracts and stenosis is caused. According to von Bruns, Kohl,[1] and others, constrictions of the trachea may in rare instances result from some kinking of its wall. Such conditions as a bulging of the posterior wall due to the approximation of the posterior ends of the cartilage secondary to the spreading of the anterior portions, inversion of the tracheal margins from too small an incision, overlapping of the tracheal wound, and cicatricial union between the thyreoid and cricoid, must be exceedingly rare. Here, again, a definite diagnosis can always be made by proper investigation, but treatment is more difficult. Dilatation must be attempted by either continuous or intermittent methods. If preferred, a short piece of rubber tubing can be passed upwards from the tracheotomy wound into the larynx and kept in place for several hours by two silk sutures, one passing out of the tracheal wound, the other out of the mouth; or a stenosis canula can be inserted with some form of hollow plug which passes upwards into the larynx (Fig. 266). The question whether the tracheotomy wound should be kept patent is difficult to answer. When stenosis is extreme there is no alternative, and the open wound allows of the constant passage of graduated bougies, which is more easily accomplished from below than from above. If treatment be persistent the prospect of a good result is not unfavourable, and there is every reason to believe that in the future the number of cases which require a permanent tracheotomy tube will be reduced to a minimum.

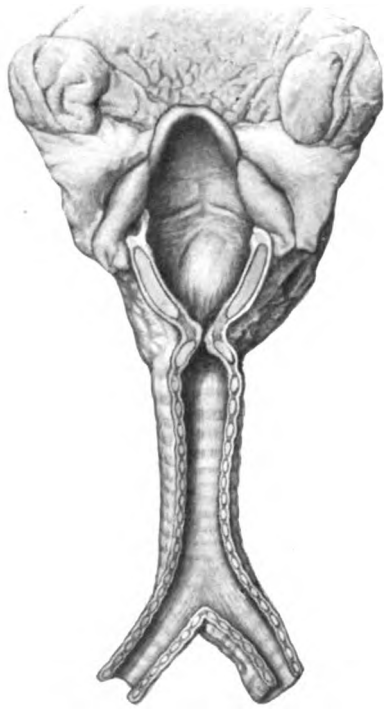

FIG. 265. STENOSIS FOLLOWING TRACHEOTOMY. (*From Specimen No.* 1659d *in the Museum of St. Bartholomew's Hospital.*)

[1] Bergmann, E. von, *Sys. Pract. Surg.*, vol. ii, p. 270.

6. *Paralysis.* In the larynx there may be paralysis of the sensory or of the motor nerves. In the former case food may enter into the trachea and cause troublesome coughing and possibly 'Schluck-pneumonie.' When the motor nerves are affected, the paralysis is commonly abductor and may be unilateral or bilateral, the latter associated with inspiratory dyspnœa. 'Complete paralysis of the recurrent nerve may also occur, but is nearly always confined to one side' (C. A. Parker[1]). Such paralyses may last from a few days to several months, and are very troublesome when associated with the passage of food into the trachea; when severe, nourishment should consist of fluids which can be administered by a nasal tube.

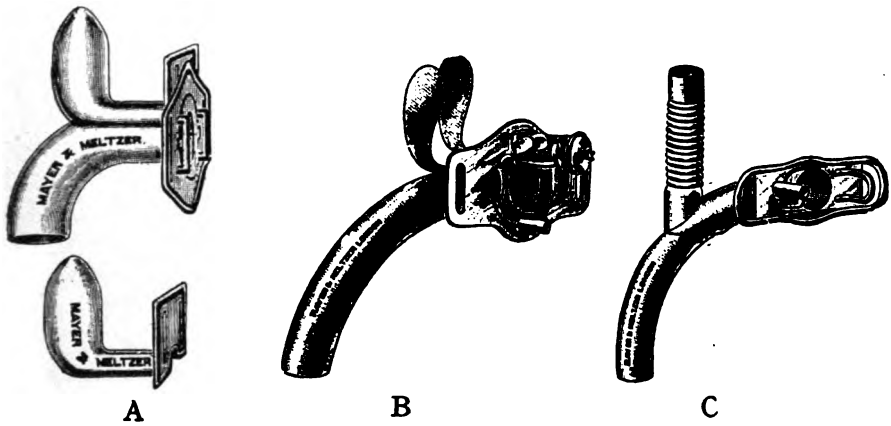

FIG. 266. TUBES USED IN THE TREATMENT OF STENOSIS OF THE LARYNX. A, Lack's; B, Störk's; C, Schimmelbusch's.

Further complications arising during the after-treatment of tracheotomy:

7. *Broncho-pneumonia.* This occurs in the worst forms, and is accompanied by high temperature with definite signs in the lungs. The absence of septic discharge, the restlessness of the patient, and the rapidity of the breathing (in many instances accompanied by 'recession' not caused by obstruction in the tube) make the condition easy to recognize. There is no satisfactory treatment for septic broncho-pneumonia which has already developed, but it may be prevented. Within recent years it has become less common. This is due to better technique in the operation, and to careful attention during the after-treatment. The habit of passing feathers into the trachea has been abandoned with advantage to the patient. When possible the child should be removed from septic influences which are liable to infect the throat, for the

[1] *Nose and Throat,* 1906, p. 94.

occurrence of tonsilitis as a sequel to tracheotomy is always to be feared in wards containing septic cases.

8. *Emphysema* may occur in the neighbourhood of the wound, or in rare cases may be extensive and involve the whole of the face, neck, and chest. Campneys[1] was the first writer to call attention to this complication of tracheotomy. After a large number of observations and experiments, he was of opinion that emphysema of the anterior mediastinum occurs in a certain proportion of tracheotomies and is of frequent occurrence in cases that are fatal; that it may be associated with pneumothorax; and that the conditions which favour its production are a low division of the deep cervical fasciæ in the neighbourhood of the sternum, combined with obstruction of the air-passages and strong inspiratory efforts; artificial respiration, especially if improperly performed; and want of skill on the part of the operator; further, that the dangerous period of the operation is between the division of the deep cervical fascia and the efficient introduction of the tube. To this may be added those cases in which the tube slips out of the trachea into the cellular tissue above the sternum and thus causes more or less obstruction to breathing. It seems probable that the air is sucked into the cellular tissues beneath the pretracheal fascia, rather from the outside than from the trachea, and that with forced expansion of the chest it finds its way beneath the fascia into the mediastinum.

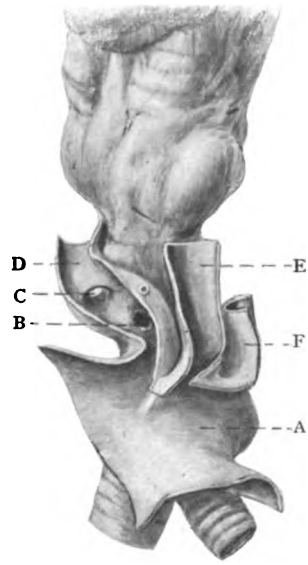

FIG. 267. TRACHEA SHOWING ULCERATION INTO THE INNOMINATE ARTERY AFTER TRACHEOTOMY. (*From Specimen No.* 1622a *in the Museum of St. Bartholomew's Hospital.*) A, Aorta; B, Ulcer; C, Right subclavian; D, Right common carotid; E, Left common carotid; F, Left subclavian.

9. *Hæmorrhage* may occur as the result of slipping of a ligature during an attack of vomiting or struggling after the operation: it is usually venous and requires nothing but passing notice. Secondary hæmorrhage may result from ulceration into one of the larger arteries or veins. Kocher[2] states that 'the number of cases recorded is now about eighty-seven, of which fifty-six are associated with the innominate

[1] *Trans. Med. Chirurg. Soc.*, vol. lxv. p. 85; vol. lxvii, p. 102.
[2] *Chirurg. Operat.*, 1907, p. 631.

artery. Unfortunately it is not known how often in these cases inferior tracheotomy had been performed. Low tracheotomy was performed in my case because an excision of the larynx for cancer had been undertaken. Doubtless the danger of these fatal complications is much greater with inferior tracheotomy owing to the pressure of the canula.' Von Bruns[1] also agrees that 'the vast majority of fatal hæmorrhages were in cases of inferior tracheotomy. Of thirty-six cases in which the source of hæmorrhage was given, twenty-eight were traced to the innominate vein, two to the right carotid, and one each to the superior thyreoid, the left innominate, the right jugular and the left jugular.' Bleeding is also recorded in cases of aneurysm of the aorta, in which tracheotomy has been performed, as the result of erosion of the tracheal wall and the bursting of the sac. Further, troublesome oozing may take place from the mucous membrane of the trachea when this is inflamed, or when granulations are present, or when there is much sloughing of tissues, and especially after a metal tube has been worn for a considerable period. Hæmorrhage from an enlarged thyreoid isthmus is also described. When due consideration is given to the septic condition of the wounds and the close relation of large vessels, it is surprising to find that hæmorrhage proves seldom fatal.

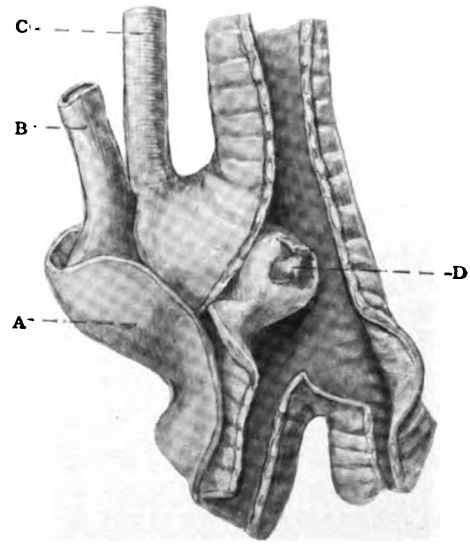

FIG. 268. ANEURYSM OF THE AORTA PERFORATING THE TRACHEA. (*From Specimen No.* 1500 *in the Museum of St. Bartholomew's Hospital.*) A, Aorta; B, Left subclavian; C, Left common carotid; D, Ulcer in sac of the aneurysm.

10. *Cardiac paralysis* may also complicate tracheotomy. When supervening in the acute stages of the disease, the patient becomes prostrate and vomiting is persistent, while the heart gradually fails. In other cases death occurs suddenly and unexpectedly, in mild as well as in severe disease; this may happen at any period, during the first days or later, during convalescence. Heart failure is more common in diphtheria than in any other infectious disease which is met with in this country.

[1] Bergmann, E. von, *Sys. Pract. Surg.*, vol. ii, p. 265.

Prognosis. It may be said that all cases of laryngitis caused by diphtheria are of a serious nature, and especially those which require tracheotomy (see Table, p. 556). The mortality amongst tracheotomized patients during eleven years was 29.9%, and the variations in each separate year were slight. Such results are far from satisfactory, but it must be remembered that in pre-antitoxin days less than 30% recovered after tracheotomy (Goodall [1]). The use of antitoxin, first suggested by Behring, is undoubtedly responsible for this remarkable decrease in the mortality. The sooner the serum is injected the better the prognosis with tracheotomy. A large dose should be given, 8,000 to 20,000 units, irrespective of age, and the dose may be repeated on the second day if required. Improvement generally commences between twelve and twenty-four hours after injection; the swelling of the mucosa subsides, and secretion is diminished; false membrane is not so copious, and rarely extends to the trachea and bronchi; crusts become less adherent, and are expelled by the patient. In this manner the whole area of the disease becomes clean, and there is less absorption of toxins. It is now generally agreed that serum should be used in all suspicious cases, and some authorities inject at once not only the patient, but also other children living in the same house. It is hoped by early injection to avoid the necessity for tracheotomy.

The age of the patient is very important, as the following table shows:

TABLE SHOWING TOTAL DIPHTHERIA TRACHEOTOMIES PERFORMED AT THE FEVER HOSPITALS IN LONDON DURING 1902–12, INCLUDING THOSE IN WHICH INTUBATION WAS PREVIOUSLY PERFORMED AND THOSE IN WHICH NO ANTITOXIN WAS USED.

Age.	*Times.*	*Deaths.*	*Percentage of Deaths.*
Under 1	154	100	64.8
1–2	648	282	43.5
2–3	680	208	30.6
3–4	603	136	22.5
4–5	504	107	21.2
5–6	330	51	15.4
6–7	185	46	24.8
7–8	58	13	22.4
8–9	23	6	26.1
9–10	21	5	23.8
Over 10	35	14	40.0
Total	3,241	968	29.8

[1] *Brit. Med. Journ.*, 1899, vol. i, p. 199, 'On the Value of the Treatment of Diphtheria by Antitoxin.'

From these figures it is apparent—(1) that children less than one year of age rarely recover after tracheotomy; this is especially true of diphtheria, although in other forms of laryngeal obstruction cases of recovery have been reported in children of six months; (2) that in the early years of life tracheotomy is most commonly needed, especially between the ages of one and five years; (3) that the death-rate gradually decreases between the ages of one and six years, after which there is a rise.

In explanation of these facts it appears probable that after five years of age the larynx and trachea are increased in size, so that obstruction is only met with where there is a large amount of membrane, namely, in the worst cases; in patients over ten, the age which marks the change to the adult type of larynx, the air-passages become so large that obstruction seldom occurs even when much membrane is present; dyspnœa, in these cases, points to extension of the disease to the smaller tubes, and tracheotomy is unable to give the same relief.

In considering the prognosis, not only must the symptoms peculiar to the case be taken into account (as, for instance, the pulse, temperature, respiration, and general condition), but also any complications that arise. It must be borne in mind that tracheotomy does not cure, although it can relieve, the patient; that nearly one-third of the cases die; that the disease, and not the operation, is responsible for most of the deaths. Moreover, the amount of toxæmia depends upon the virulence of the infection, which is variable in different epidemics; upon the area of mucous membrane infected; and upon the constitution of the patient. In so-called hæmorrhagic diphtheria the result is always fatal.

The effect on after-life. It was stated by Landouzy at the Berlin Tuberculosis Congress in 1899 that, judging by the rarity of the scar, few tracheotomized children reach adult life, but inquiries in Germany showed that this was incorrect. H. W. L. Barlow, in reviewing the literature of the subject, concludes that 'in the large majority of cases the cure is permanent and complete.' In cases where a tracheotomy tube has been retained for a long period, however, complications are liable to arise; these include stenosis of the larynx or trachea, bronchitis, pneumonia, and possibly tuberculosis (see p. 523).

TRACHEOTOMY IN CONDITIONS OTHER THAN DIPHTHERIA

The indications for tracheotomy in conditions other than diphtheria have already been described. Although local anæsthetics are of little practical value in children, their use is much preferred where adults are concerned. The three drugs most commonly used at the present time are eucaine, cocaine, and novocaine, and of these novocaine is unquestion-

ably to be preferred for subcutaneous injection as being less toxic, less irritant to the tissues, and at least as efficient in producing anæsthesia. Whichever drug is chosen, a small quantity of chloride of sodium should be added in order to make the solution isotonic with the blood serum, and thus to render it practically non-irritant. Many surgeons add adrenalin to contract the vessels in the injected area and so to prevent the drug from being absorbed into the general circulation: owing to the large size of the vessels and their proximity to the heart this is important, but it must also be remembered that with strong solutions there is great contraction of vessels, and that when the effects have disappeared there is a slight danger of recurrent hæmorrhage. Semon has drawn attention to this danger in connexion with operations upon the larynx, and after minor operations in other regions of the body it is not uncommon to find a small hæmatoma which necessitates reopening the wound.

In order to ensure the full effects of local anæsthesia with the least possible disadvantage, the drug should be used in weak solution, and the injection should be made at least a quarter of an hour before the operation is commenced. It is only necessary to prick the skin at one point, namely, at the upper end of the proposed incision; a small quantity of the fluid should be expelled, after which the needle may be withdrawn. After a short interval it is possible to reinsert the needle (or a larger one if preferred) and to push it deeper, until the whole length of the incision has been injected, without distress to the patient.

The following solution will be found effective:—

'Novocaine, 4% solution	℥ x—1.3%
Sodium chloride, 4% solution . . .	℥ vj—0.8%
Adrenalin, 1–1,000	℥ j—0.003%
Distilled water to	℥ xxx

'These local anæsthetics are all, more or less, rapidly decomposed and rendered inactive in the presence of even traces of an alkali or alkaline carbonate. If boiling is resorted to in order to sterilize the syringe, great care must be taken that no soda is present.'—LANG.

Moreover, the finished solution cannot be boiled without decomposing the adrenalin, and it is customary therefore to add thymol or ol. Gaultherii (0.1%), which keeps the solution antiseptic without being irritant.

The operation, which is often required in adults, must be carried out upon the lines already described. The enlargement of the thyreoid and cricoid cartilages, the small amount of fat, the small size of the thyreoid isthmus and of the pretracheal vessels after puberty, make the trachea easy to find. Difficulties, however, arise and are determined by the

urgency of the case and the nature of the disease. Thus, with inflammation, the neck may be so swollen that the trachea is many inches from the surface; with tumours the trachea may be displaced, or the obstruction may be in the thorax. Under such conditions it is important to note the probable position of the trachea before the operation is commenced, and to be prepared for serious hæmorrhage.

The after-treatment also corresponds to that which is adopted in diphtheria. It is important to keep the tube clean and to prevent it from irritating the trachea. The time for removal of the canula varies according to the condition. Thus, when tracheotomy is performed for a foreign body, the tube may be removed as soon as the object has been extracted; on the other hand, when treating stenosis of the larynx it may be necessary to advise permanent wearing of the canula.

Complications are less common than with tracheotomy for diphtheria. Under favourable conditions there is little danger of pneumonia unless the wound becomes infected, as may happen when the operation is undertaken for the relief of septic inflammations.

Although tracheotomy is in itself a slight operation, it should be reserved for cases that demand it. The mortality of the operation under favourable conditions is probably very small; on the other hand, in acute septic conditions and in patients suffering from bronchitis there are grave dangers of complications.

TRACHEO-FISSURE AND RESECTION OF THE TRACHEA

Although these operations are very rarely performed, advance has been made in their technique during recent years.

Indications. (i) *Tumours of the trachea.* These are uncommon. Thiesen[1] in 1906 collected from the literature 135 cases, of which 89 were innocent and 46 malignant. The majority of the former were papilloma (25), fibroma (24), enchondroma (17), and intratracheal struma (10). Of the latter, carcinoma (28) was more common than sarcoma (18). More than half of these tumours were situated high up in the trachea. These cases were collected from a period covering seventy-five years, which proves that they are extremely rare as compared with tumours of the larynx.

(ii) *Stenosis due to previous inflammation.* Stenosis may be caused by diphtheria or other fevers, syphilis, the presence of a foreign body, or the inhalation of corrosive acids or chemical fumes. Such cases are generally treated by endotracheal methods (see p. 598).

(iii) *Cut-throat, or injury.* An operation may be necessary after

[1] *Trans. Amer. Laryng. Assoc.*, 1906, p. 264, 'Tumours of the Trachea.'

crushing or bullet wounds, or, in later stages, owing to the development of stenosis.

The diagnosis of these conditions is now comparatively easy, and with the help of direct laryngoscopy and X-ray photography the exact condition can, in many cases, be determined. In some instances the tumour may be removed by endotracheal operation, especially if the growth is innocent.

Tracheo-fissure is more reliable, and should always be performed when there is any suspicion of malignancy. The preliminary stages are similar to those of tracheotomy. A section of the trachea is first made in the region of the tumour, and the opening is enlarged so that the growth can be thoroughly explored; this can be better accomplished when the trachea is illuminated by a good electric lamp, in some instances a Killian's tube being required. When possible, a tampon canula is inserted into the lower part of the trachea. When the growth is low down, the patient is placed in the Trendelenburg position in order to prevent the inspiration of blood. Should the diagnosis be uncertain, a portion of the tumour can be excised and a frozen section made. If proved to be innocent, the growth can then be freely excised with scissors or galvano-cautery. The bleeding is arrested, and the tracheotomy tube is retained for several days. The after-treatment must be conducted on lines similar to those laid down for laryngectomy, the patient being turned on the face in order to prevent pneumonia. 'Up to the present time about two dozen operations of this sort have been reported. The author has removed in this manner four intratracheal thyreoids with permanent result' (von Bruns).[1]

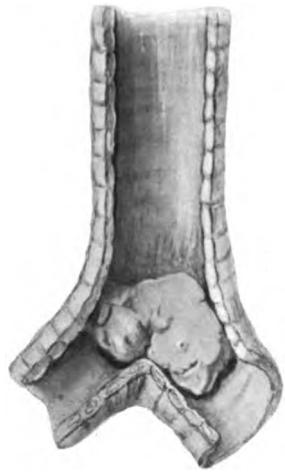

FIG. 269. SARCOMA OF THE TRACHEA. (*From Specimen No.* 1658a *in the Museum of St. Bartholomew's Hospital.*)

Resection. If the tumour be malignant, the surgeon must first decide whether its removal is practicable or whether palliative tracheotomy is preferable. In the former case the trachea is isolated laterally and divided transversely well below the growth. Whenever possible the lower end is then brought outwards and temporarily attached to the lower part of the incision above the sternum. The resection of the trachea is then carried out, so that the growth is freely removed, care being taken to preserve the recurrent nerves. 'Where the section of the trachea

[1] Bergmann, E. von, *Sys. Pract. Surg.*, vol. ii, p. 249.

to be removed is limited to 4 centimetres or less, the two ends can generally be approximated and united, restoring the calibre of the tube and normal mouth respiration' (Brewer).[1] This is accomplished by numerous catgut sutures, some of which include the entire thickness of the tube. The muscles can be approximated so as to cover the incision, and the wound can be drained freely. On the other hand, the lower end of the trachea may be permanently fixed in the wound as described under laryngectomy (see p. 536). Von Bruns has removed a cancer on the posterior wall of the trachea with six tracheal rings, thus giving the patient six years of life. He remarks: 'Operative treatment in tumours of the trachea shows brilliant results. Untreated the condition leads to death from suffocation. In seven cases operated upon by me, the results were all favourable.'

[1] *Keen's Surgery*, 1908, p. 510.

CHAPTER IV

INTUBATION OF THE LARYNX

INTUBATION, or 'tubage,' was first recommended by Loiseau and Bouchut in France; in 1880 attention was drawn to the subject by Sir W. Macewen in England, and soon afterwards O'Dwyer[1] of New York published articles which resulted in its being extensively tried in America; since that time it has continued to be popular in that country for the treatment of laryngeal diphtheria. 'The good results which American physicians have secured by intubation may be explained, perhaps, by the circumstance that according to their reports diphtheria takes a milder form in America' (Tillmanns).[2] Intubation has been extensively used in Europe, especially in Germany, but never to the same extent as tracheotomy, and in England it has been practised at only a small number of hospitals; thus, of the nine M.A.B. fever hospitals in London only four used it regularly during 1906–11, and none of them so often as tracheotomy.

Intubation versus Tracheotomy in Diphtheria. Since the introduction of the newer method of treatment in 1880 the subject has been widely discussed in America, on the continent of Europe, and in England. There is no evidence to show that treatment with antitoxin has been beneficial to one operation more than to the other.

The *advantages* claimed for intubation are—

1. No anæsthetic is required.
2. Consent of friends is easily obtained.
3. No cutting: great rapidity.
4. No wound to heal.
5. Tube worn more easily than the tracheotomy tube.
6. Breathing through natural passages, so that warmth and moisture are added to the air.
7. Its earlier performance.
8. Its better results in children under five.
9. Recovery is quicker.

[1] *New York Med. Journ.*, 1885, vol. xlii, p. 145.
[2] *Text-Book of Surgery*, 1900, vol. ii, p. 625.

The practical *disadvantages* are:

1. Quite unsuitable except at special hospitals, as great dexterity and constant practice are necessary.

2. Respiration is interfered with during introduction, so that celerity is indispensable, accidents are frequent, and failure is common.

3. Tube may be coughed up (28%, Goodall[1]), blocked (12%, Goodall), and does not provide good drainage for secretions.

4. Swallowing difficult.

5. Complications common: Broncho-pneumonia, ulceration, cicatrization.

6. After-treatment difficult and constant watching required.

7. Necessity for secondary tracheotomy (29.6%), which has a greater mortality (death in 45%, see table below).

8. Retained tube.

In considering the above it is the obvious duty of the surgeon to advise what he considers the better operation for the case, and this must depend largely upon the amount of his experience; the argument that the operation is superior because it can be previously practised on the cadaver is a bad one, and implies a failure to realize the many difficulties which will be encountered in the selection of cases, the operation itself, and its after-management.

I am strongly of opinion that the operation ought not to be tried indiscriminately by those who have no knowledge of these difficulties. In the hands of an expert it is a justifiable method of treatment which is suitable for selected cases, and it is one which can be used early; tracheotomy, on the other hand, is naturally delayed, or used for serious cases and those which have not derived relief from intubation.

Although intubation has received extensive trial, the published results show great variations and do not prove that intubation is superior to tracheotomy, but rather the reverse.

TABLE SHOWING DETAILS OF CASES DURING 1906–1911 AT THE M.A.B. HOSPITALS WHERE INTUBATION IS FAVOURED.

	Intubation only.			*Both operations.*			*Tracheotomy only*			*Total operations.*		
	Cases.	*Deaths.*	%	*Cases.*	*Deaths.*	%	*Cases.*	*Deaths.*	%	*Cases.*	*Deaths.*	%
tern, 1906–11	158	8	5.1	85	37	43.5	102	43	42.1	345	88	25.5
stern, 1906–7	25	7	28.0	10	4	40.0	126	41	32.6	161	52	32.3
k, 1906–10	78	22	28.2	28	13	46.5	19	12	63.2	125	47	37.6
ok, 1907–11	54	9	16.7	10	6	60.0	59	25	42.4	123	40	32.5
al	315	46	14.6	133	60	45.0	306	121	39.5	754	227	30.1

[1] *Edin. Med. Journ.*, 1902, p. 235, 'Observations on Intubation of the Larynx'.

Certain points in the table deserve attention:

1. In cases treated by intubation only, the results are excellent, namely, death in 14.6%, Dr. Goodall of the Eastern Hospital having a mortality of only 5.1% in one hundred and fifty-eight operations.

2. In cases where tracheotomy was afterwards performed the mortality is high, i.e. 45%.

3. Where tracheotomy was the sole operation the mortality is also high, i.e. 39.5%.

4. The total operations at these hospitals taken together show a higher mortality than appears in the table below.

As regards the first three points, the facts are the same as in any published statistics dealing with the relative advantages of the two operations. I wish to emphasize that the results obtained by intubation depend very largely upon the selection of the cases; and I agree with Turner and Cuff that, in order to arrive at any conclusion in the matter, it is necessary to compare the total results of those hospitals where intubation is favoured with those of the hospitals where tracheotomy is chiefly employed.

TABLE SHOWING COMPARATIVE RESULTS AT 'INTUBATION' AND 'TRACHEOTOMY' HOSPITALS

	Four 'Intubation' Hospitals.			*Seven 'Tracheotomy' Hospitals.*			*Total Cases.*		
	Cases.	*Deaths.*	*Mortality per cent.*	*Cases.*	*Deaths.*	*Mortality per cent.*	*Cases.*	*Deaths.*	*Mortality per cent.*
1902	76	23	30.2	222	71	32.0	298	94	31.5
[1] 1903									
1904	156	47	30.1	173	47	27.1	329	94	28.5
1905	157	46	29.3	184	40	21.7	341	86	25.2
1906	166	58	34.9	188	51	27.1	354	109	30.8
1907	252	71	28.2	242	66	27.3	494	137	27.7
1908	78	22	28.2	318	87	27.3	396	109	27.5
1909	81	21	25.9	329	102	31.0	410	123	30.0
1910	69	15	21.7	218	46	21.1	287	61	21.2
1911	108	29	26.8	265	70	26.4	373	99	26.5
Total	1,143[2]	332	29.0	2,139[3]	580	27.1	3,282	912	27.8

From these figures it will be seen that the total result for five years is a mortality of 27.1% as against 29%, in favour of tracheotomy. This serves, in my opinion, to strengthen the position of those hospitals which rely upon tracheotomy. Upon a comparison of this sort it would certainly appear that the results of intubation, at any rate in England,

[1] No return. [2] Of these more than 877 were intubations.
[3] Of these 25 or more were intubations.

are not so good as has been stated. I am aware that this opinion is not shared by many authorities and that Stack[1] writes, 'taking everything into consideration, my impression is that under the most favourable conditions of operating, nursing, &c., the mortality is almost halved by doing intubation as a routine instead of tracheotomy.'

It has been claimed that intubation gives better results in children under five. This question has been worked out by H. W. L. Barlow,[2] who concludes that 'the younger the child, the longer will it require the tube, and the more frequently, therefore, has the latter to be inserted,' and 'from the mortality alone, there is no indication that one operation is better suited for certain age periods than another, but since secondary tracheotomy appears to be rarest at three years old and the intubation fatality is least between four and six years, it follows that children from three to six are best adapted for intubation.'

Conclusions. Intubation is justifiable for diphtheria of a mild type if sufficient experience can be obtained and if the after-treatment can be personally carried out. The success of the operation depends largely upon a proper selection of the cases; in other words, it is not suitable for the worst types of this disease. It should never be performed upon a patient in whose case the question of tracheotomy does not arise.

In my opinion it is not a good operation for those general hospitals where there is constant change among the resident officers; it seems probable that it will remain the treatment of a small number of physicians who have frequent opportunities of practising their art.

Indications. (i) *In diphtheria,* intubation is justifiable when the disease is of a mild type without great toxæmia, where early diagnosis has been made, and antitoxin has been administered. It is not recommended when there is great pharyngeal inflammation, or in cases with bronchitis or pneumonia, or when the patient is prostrate, nor for severe obstruction caused by excessive swelling or false membrane in the larynx or trachea. In the last-mentioned condition intubation is difficult to perform, and the patient may be choked by false membrane which has been pushed down: intubation should be abandoned in favour of tracheotomy when immediate relief is not obtained.

(ii) *In other forms of septic laryngitis* there is evidence to show that with intubation the mortality is higher than with tracheotomy; in œdematous laryngitis, such as follows the inhalation of steam, every effort should be made to prevent laryngeal obstruction by other forms of treatment, for intubation is difficult to perform owing to the swollen condition of the tissues; moreover, injuries are common, and there

[1] Allbutt and Rolleston, *Sys. of Med.*, 1905, vol. i, p. 1025.
[2] *Metropol. Asylums Board's Ann. Rep., Med. Supplem.*, 1904, p. 319.

is a danger that the upper opening of the tube will become obstructed. Again, the tube may be expelled by coughing, and the child suffocated without relief.

(iii) *In chronic stenosis,* intubation is now extensively employed. Fibrous contraction such as follows some cases of thyrotomy, or syphilis and other inflammatory diseases, can be treated successfully by this

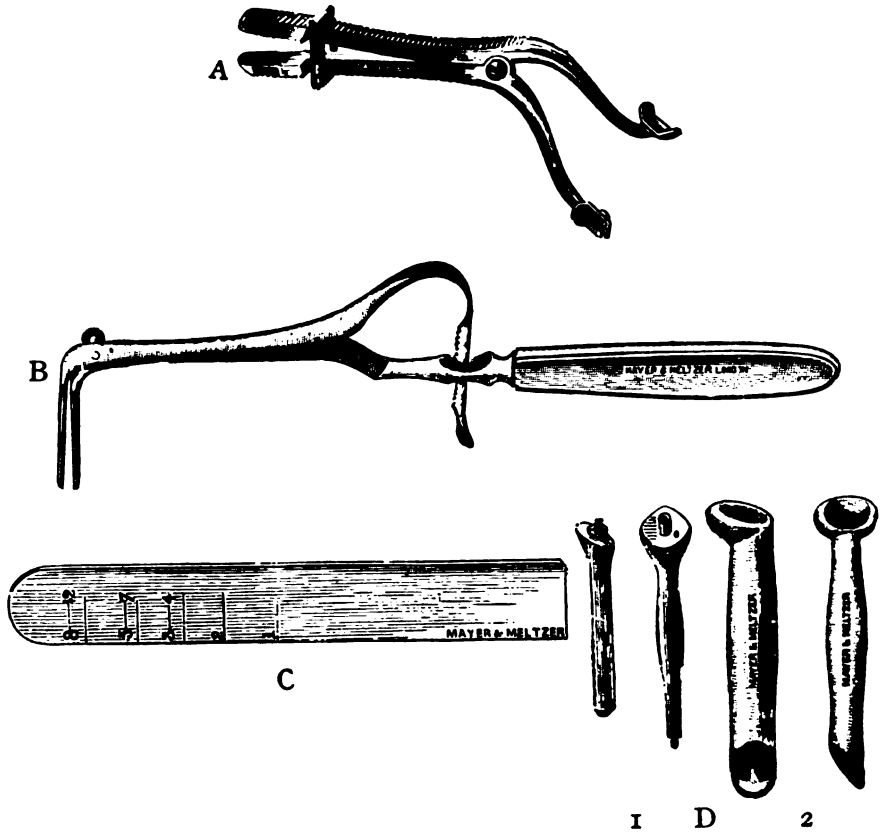

FIG. 270. INSTRUMENTS FOR INTUBATION OF THE LARYNX. A, Gag (O'Dwyer's); B, Forceps for intubation and extubation (Thorner's); C, Gauge; D, Tubes: 1, O'Dwyer's; 2, Thorner's.

method. Short light tubes, of vulcanite or similar material, are inserted and retained in position for long periods, three months or longer; with the pressure so exerted the amount of fibrous tissue appears to be diminished, and the lumen of the larynx is dilated.

Operation (in diphtheria). The apparatus required consists of a gag for opening the mouth, a set of tubes with a gauge showing the

size for each age, an instrument for intubation and extubation, and equipment for tracheotomy.

The tubes recommended by O'Dwyer are of gilded bronze, but other materials such as vulcanite or hard rubber are sometimes used. The tubes have undergone frequent modifications and those designed by Bayeux are shorter, lighter, and a great improvement (Goodall). In Thorner's type (Fig. 270) the lower end has been cut off at an angle, so that it may pass more easily between the vocal folds; the intubator and extubator have been replaced by a single pair of beaked forceps with a ratchet attached to the handles, so that, when the beaks are separated, the tube is gripped firmly and cannot be disengaged until the trigger of the ratchet has been pulled; with these forceps the tube is not obstructed while it is being taken in and out of the larynx, and there is less need for hurry; further, the top of the tube has a funnel-shaped opening 'which greatly facilitates the introduction of the beaks when the tube is in the larynx, inasmuch as it allows the beak to glide from any point of the rim almost automatically into the opening, and what this means can be appreciated by those who have had experience with the old extractor' (Kyle.).[1]

No preparation of the patient is required, but a blanket must be wrapped round the arms, body, and legs to control the struggling. Two assistants are required, one to hold the patient, the other to steady his head and manipulate a gag. The upright position is preferred by many surgeons because the patient is less frightened, and the breathing is easier; but the child may be laid upon a table, with the head slightly extended and exactly in the middle line of the body, or the head may be allowed to hang over the end of the table and the tube passed from behind, in a manner similar to that used for direct laryngoscopy. No anæsthetic is necessary. The first assistant or nurse should sit on a low chair with the child on his knees, holding him so that he directly faces the surgeon; a second assistant stands behind with a gag in his hand. A tube of suitable size, with a thread attached, and mounted on the introducer, is taken in the right hand; the assistant introduces the gag, opens the mouth to the fullest extent, and steadies the head with his two hands; the surgeon now passes the left index-finger over the back of the tongue, so that the tip of it passes behind and below the epiglottis until the cricoid is felt; this is the most important landmark, and as soon as it is located the finger is drawn upwards and forwards in order to hook up the epiglottis, and the introducer and tube are rapidly passed over it; the method of introduction being that used for all laryngeal instruments. As soon as the end of the tube is level with the end

[1] *Diseases of the Nose and Throat*, 1907, p. 726.

of the finger, the handle of the introducer is raised so as to throw the point as far forward as possible; the instrument is then bodily lowered, so as to drive the tube downwards through the larynx until it rests firmly and securely against the ventricular folds, which prevent further passage of the collar; the tube is now held in place with the left index-finger until the introducer is removed. The whole operation in experienced hands should take from three to five seconds only, and must be performed without force.

If the tube has been properly introduced, it is usual for the child to begin coughing, and this may continue for a short time, accompanied by noisy and rattling inspiration; the cough gradually disappears and breathing becomes easy. The tube causes temporary aphonia, which may persist for a few days after its removal, but is otherwise well tolerated; the patient is not conscious of the presence of the canula unless it becomes blocked.

The operation is simple in the hands of those who are accustomed to the use of laryngeal instruments; in a normal larynx there is no difficulty in introducing a tube, but in diphtheria the parts are inflamed and obstruction is present. Children are often intolerant or frightened; they are liable to retch or choke during introduction, but the latter can sometimes be accomplished by waiting for an inspiratory effort; if the struggling is very troublesome a small quantity of chloroform (cocaine in adults) may be given with safety.

Difficulties of the operation. The difficulty of passing the tube over the base of the tongue can be avoided by pulling the tongue downwards and forwards and passing the introducer through the mouth with the hand to the left of the patient's face and rotating downwards when the point is in the pharynx. Failure to find the opening of the larynx is often due to not keeping the instrument exactly in the middle line. The tube may be too large (even when it corresponds to the age of the child) owing to swelling either in the larynx or in the subglottic region; in such a case a smaller tube must be tried, and it is essential that no force should be used to drive the tube into place, or dangerous complications may arise. Even a smaller tube may not be passed on the first occasion, and the surgeon has to decide whether he will try the same tube again or one that is smaller; the latter may not be suitable for the age. The tube may be too small, and this may be recognized by the ease with which it passes; as a result, the first strong cough expels it out of the larynx, and another must be introduced. A tube of correct size may be in the larynx without relieving the dyspnœa; this may be due to one of the following causes: (*a*) some membrane may have been pushed in front of the tube, an event which is evidenced

by the noisy and difficult respiration, and which requires that the tube shall be withdrawn with the thread and again introduced, after an interval; (*b*) the tube itself may become blocked with membrane, with the result that it is at once coughed out; or (*c*) the child may be asphyxiated so that tracheotomy becomes a necessity. This last is a point that must always be remembered: intubation should never be performed unless everything has been prepared for opening the trachea. The tube may pass into the œsophagus in spite of all care, and this may increase the dyspnœa by pressing upon the posterior part of the larynx, in which case it must be withdrawn by the thread and a further attempt made. It has frequently happened that the tube with its thread has passed down the œsophagus into the stomach, an accident which ought to be avoided. No serious consequences are likely to occur, as the tube will be passed per rectum, or in rare instances vomited.

The question arises as to how many attempts should be made before intubation is abandoned. This varies in each case and depends upon the amount of distress caused by the previous attempts. With each further trial the child becomes more and more restless, and if the third attempt fails, it is better to desist, or to allow at least an interval of half an hour. When the dyspnœa becomes urgent there must be no hesitation, and either the tube must be reintroduced or tracheotomy performed; both operations are difficult under these circumstances, and the surgeon should choose the method of which he has the greater experience.

It is very important to remember that tracheotomy is required in nearly a third of the cases at one stage or another; at the M.A.B. fever hospitals of London during 1902–6 there were 429 cases of intubation for diphtheria, and of these 117 required tracheotomy later, i.e. 27.2%. As Goodall says: 'Every case that was intubated four or more times came to tracheotomy. I therefore lay down the rule that if three insertions, each of several hours' duration, fail to cure the laryngeal obstruction, tracheotomy should be performed. Frequent expulsion of the tube by coughing a few minutes after its insertion is also an indication for tracheotomy.'

After-treatment. A case of intubation requires more personal attention than one of tracheotomy. It is essential that the doctor should remain within easy call, as the tube may be blocked or coughed out at any moment. This danger is not so great as it appears; when the tube is coughed out there is no immediate asphyxia, and a fatal result is uncommon; an interval of at least twenty minutes usually occurs before the dyspnœa becomes urgent, in which time the doctor can be called; it may even happen that the tube is not required again,

and that the obstruction has disappeared. When the tube becomes blocked, the state is more serious; in most cases it will be coughed out of the larynx, but if the child is very weak or the tube very firmly fixed, the obstruction must be at once relieved. It is for this reason that some surgeons prefer to leave a thread attached so that the nurse can extract the tube, but the latter has a disadvantage, namely, that the child may pull the tube out. This can be prevented by tying up the hands of the child while the tube is being worn, but even then the child may bite the string; the general practice, therefore, is to remove the thread, and the tube is then expressed by lateral pressure on the sides of the trachea, or by passing the finger below and behind the larynx and so pushing out the tube. The method is termed 'enucleation,'[1] and where it fails the extubator must be used. A nurse must be chosen who has had previous experience of intubation; she must understand the symptoms which necessitate interference with the tube, and the feeding of the child. Swallowing is often difficult, and liquids tend to pass through the canula into the trachea; the patient chokes and may cough up the tube. The danger of pneumonia is also increased. To overcome the dysphagia the patient should be made to suck uphill through a tube, or semi-solids may be tried: in other cases nasal or rectal feeding can be ordered: temporary removal of the tube has also been recommended for purposes of feeding, but vomiting often occurs with reintroduction immediately after a meal. In very troublesome cases there is distinct danger in repeated intubation; tracheotomy should be performed if the child is becoming exhausted from want of nourishment.

Changing the tube. O'Dwyer recommends that the tube should be retained for forty-eight hours without change, after which it should be removed once a day: it must, however, be remembered that while the tube is retained coughing is greatly impeded, so that septic material collects in the trachea and is liable to cause pneumonia.

Extubation by the thread and by enucleation has already been mentioned, but these methods are not applicable in every case. Extubation is difficult to perform, especially if respiration is obstructed and the patient struggling; whenever necessary, chloroform should be given. The preparation required is similar to that for intubation; a table and tracheotomy instruments are made ready; the upright position is preferred, and two assistants are required to hold the child and the gag: expanding forceps are introduced as if intubation were being done, and the tube is grasped securely and rapidly extracted, the whole operation being carried out as quickly as possible and without any suggestion of

[1] For a description of this method see *Metropol. Asylums Board's Ann. Rep. Med. Supplem.*, 1898, p. 187.

force. In experienced hands no danger is to be feared, but if two or three attempts are unsuccessful, tracheotomy should be performed. The time for removal of the tube varies from a few hours to four or five days in favourable cases. The main object is to dispense with the tube as soon as possible, and to err on the side of too early removal even in spite of the fact that reintroduction may be necessary.

Complications may occur, but there is no evidence that they are more numerous than with tracheotomy. Injury to the larynx is liable to result, especially from inexperience of the method, and this may be followed by hæmorrhage, emphysema, or abscess. In rare instances a false passage has been made, generally through the sinus of the larynx: pressure ulcers may form, there may be necrosis of the cartilage, peritracheal abscess, or cicatricial contraction; or, as with tracheotomy, subglottic swelling may persist and granulations may be formed. When urgent dyspnœa follows the removal of the tube, one of these conditions must be suspected. O'Dwyer maintains that the cause of persistent stenosis following intubation in laryngeal diphtheria can be summed up in a single word—'traumatism,' but 'paralysis of the vocal folds may possibly furnish an occasional exception to this rule' (Jacobson).[1]

'*Retained tube,*' which is the term applied to cases of more than five days' duration, is certainly more common after injury, but does not occur more frequently than with tracheotomy; many cases have been reported where intubation tubes were used for long periods with ultimate recovery, but the method is uncertain unless the exact condition of the larynx can be determined (see p. 518).

Pneumonia. It has been shown that large numbers of bacilli are present in the lungs, where they may cause inflammation quite apart from any operation; in laryngeal cases the danger is increased owing to the obstruction which causes deficient aeration of, and improper expectoration from, the lung. Where tracheotomy is performed the dyspnœa is relieved and the expectoration easy; with intubation, on the other hand, there is no stage of apnœa after introduction, which seems to indicate that the air does not pass so easily through the smaller tube; coughing is more difficult and the amount of expectoration less: mucus, pus, or membrane in small pieces, can all be expelled through the tube, but not so freely as through the larger canula, and are more likely to be swallowed. For these reasons it would appear that pneumonia is less to be feared after tracheotomy; there is, however, considerable difference of opinion on this point, and statistics have not proved of great value.

[1] *Operations of Surgery*, 5th ed., vol. i, p. 640.

CHAPTER V

TRACHEOSCOPY AND BRONCHOSCOPY

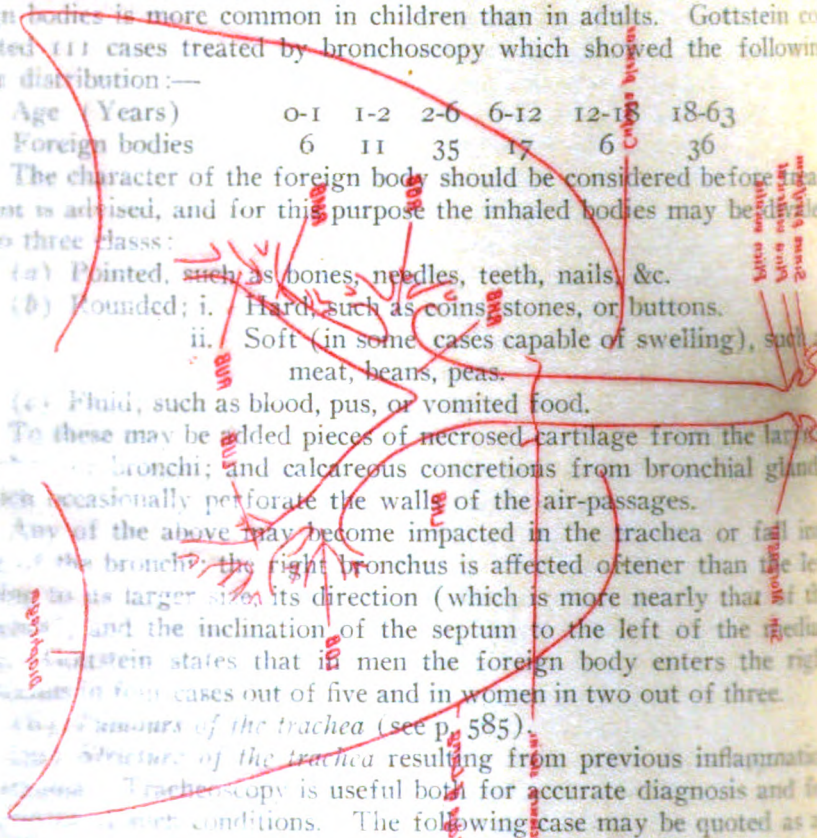

Indications. (i) *Foreign bodies.* Accidental inhalation of foreign bodies is more common in children than in adults. Gottstein collected 111 cases treated by bronchoscopy which showed the following age distribution:—

Age (Years)	0-1	1-2	2-6	6-12	12-18	18-63
Foreign bodies	6	11	35	17	6	36

The character of the foreign body should be considered before treatment is advised, and for this purpose the inhaled bodies may be divided into three classs:

(a) Pointed, such as bones, needles, teeth, nails, &c.

(b) Rounded; i. Hard, such as coins, stones, or buttons.

ii. Soft (in some cases capable of swelling), such as meat, beans, peas.

(c) Fluid, such as blood, pus, or vomited food.

To these may be added pieces of necrosed cartilage from the larynx, [illegible] bronchi; and calcareous concretions from bronchial glands, which occasionally perforate the walls of the air-passages.

Any of the above may become impacted in the trachea or fall into one of the bronchi; the right bronchus is affected oftener than the left [illegible] its larger size, its direction (which is more nearly that of the [illegible]), and the inclination of the septum to the left of the median [illegible]. Gottstein states that in men the foreign body enters the right [illegible] in four cases out of five and in women in two out of three.

(ii) *Tumours of the trachea* (see p. 585).

(iii) *Stricture of the trachea* resulting from previous inflammation [illegible]. Tracheoscopy is useful both for accurate diagnosis and for [illegible] such conditions. The following case may be quoted as an [illegible]. A boy of 17 was admitted to my hospital on account of [illegible] by obstruction in the lower air-passages. The chest [illegible] skiagram taken, the latter showing a definite shadow [illegible] the bifurcation of the trachea. This was possibly an [illegible] which pressed upon the trachea. I decided to give the [illegible] perform tracheoscopy. On passing the tube [illegible] the trachea at the level of the jugular notch [illegible] large probe completely blocked its

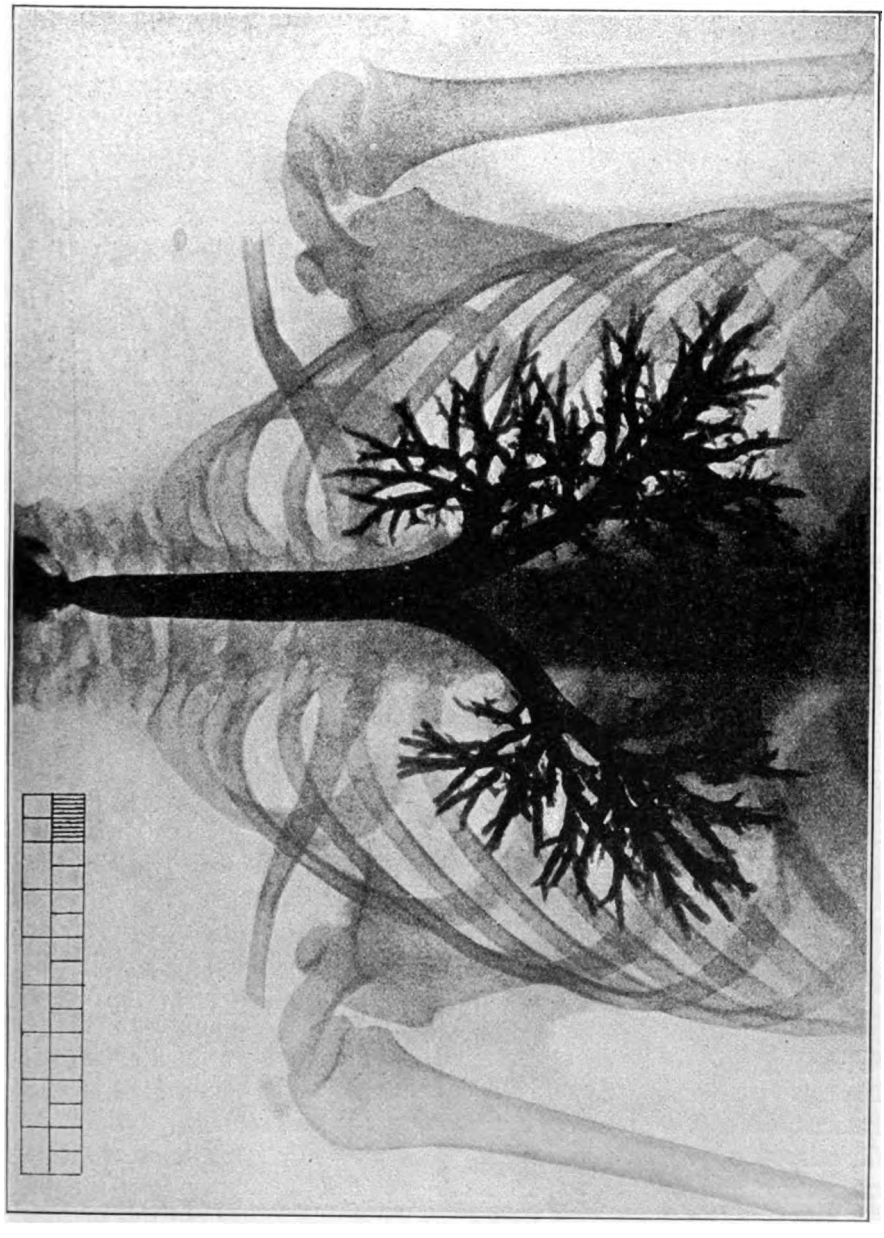

FIG. 271. SKIAGRAM OF NORMAL BRONCHIAL TREE (from Bruenings' *Atlas of Bronchoscopy, Œsophagoscopy, and Tracheoscopy*, by W. G. Howarth, 1912).

CHAPTER V

TRACHEOSCOPY AND BRONCHOSCOPY

Indications. (i) *Foreign bodies.* Accidental inhalation of foreign bodies is more common in children than in adults. Gottstein collected 111 cases treated by bronchoscopy which showed the following age distribution:—

Age (Years)	0-1	1-2	2-6	6-12	12-18	18-63
Foreign bodies	6	11	35	17	6	36

The character of the foreign body should be considered before treatment is advised, and for this purpose the inhaled bodies may be divided into three classs:

(*a*) Pointed, such as bones, needles, teeth, nails, &c.

(*b*) Rounded; i. Hard, such as coins, stones, or buttons.

ii. Soft (in some cases capable of swelling), such as meat, beans, peas.

(*c*) Fluid; such as blood, pus, or vomited food.

To these may be added pieces of necrosed cartilage from the larynx, trachea, or bronchi; and calcareous concretions from bronchial glands, which occasionally perforate the walls of the air-passages.

Any of the above may become impacted in the trachea or fall into one of the bronchi: the right bronchus is affected oftener than the left owing to its larger size, its direction (which is more nearly that of the trachea), and the inclination of the septum to the left of the median line. Gottstein states that in men the foreign body enters the right bronchus in four cases out of five and in women in two out of three.

(ii) *Tumours of the trachea* (see p. 585).

(iii) *Stricture of the trachea* resulting from previous inflammation or trauma. Tracheoscopy is useful both for accurate diagnosis and for treatment of such conditions. The following case may be quoted as an illustration: A boy of 17 was admitted to my hospital on account of dyspnœa, caused by obstruction in the lower air-passages. The chest was examined and a skiagram taken, the latter showing a definite shadow in the position of the bifurcation of the trachea. This was possibly an enlarged gland which pressed upon the trachea. I decided to give the boy an anæsthetic and perform tracheoscopy. On passing the tube a stricture was found in the trachea at the level of the jugular notch, which was so small that a large probe completely blocked its lumen,

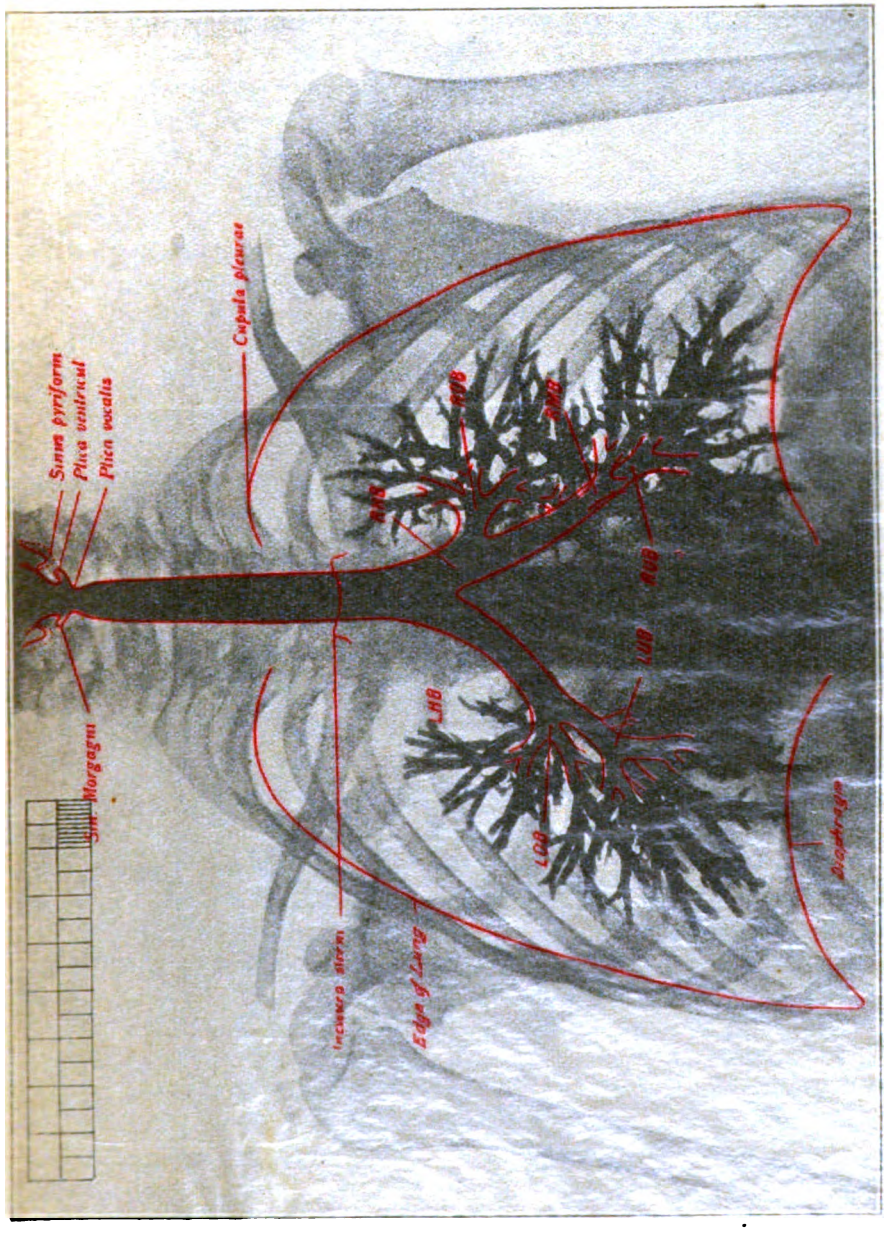

FIG. 271. SKIAGRAM OF NORMAL BRONCHIAL TREE (from Braenings' *Atlas of Bronchoscopy, Œsophagoscopy and Tracheoscopy* by W. G. Howarth, 1912).



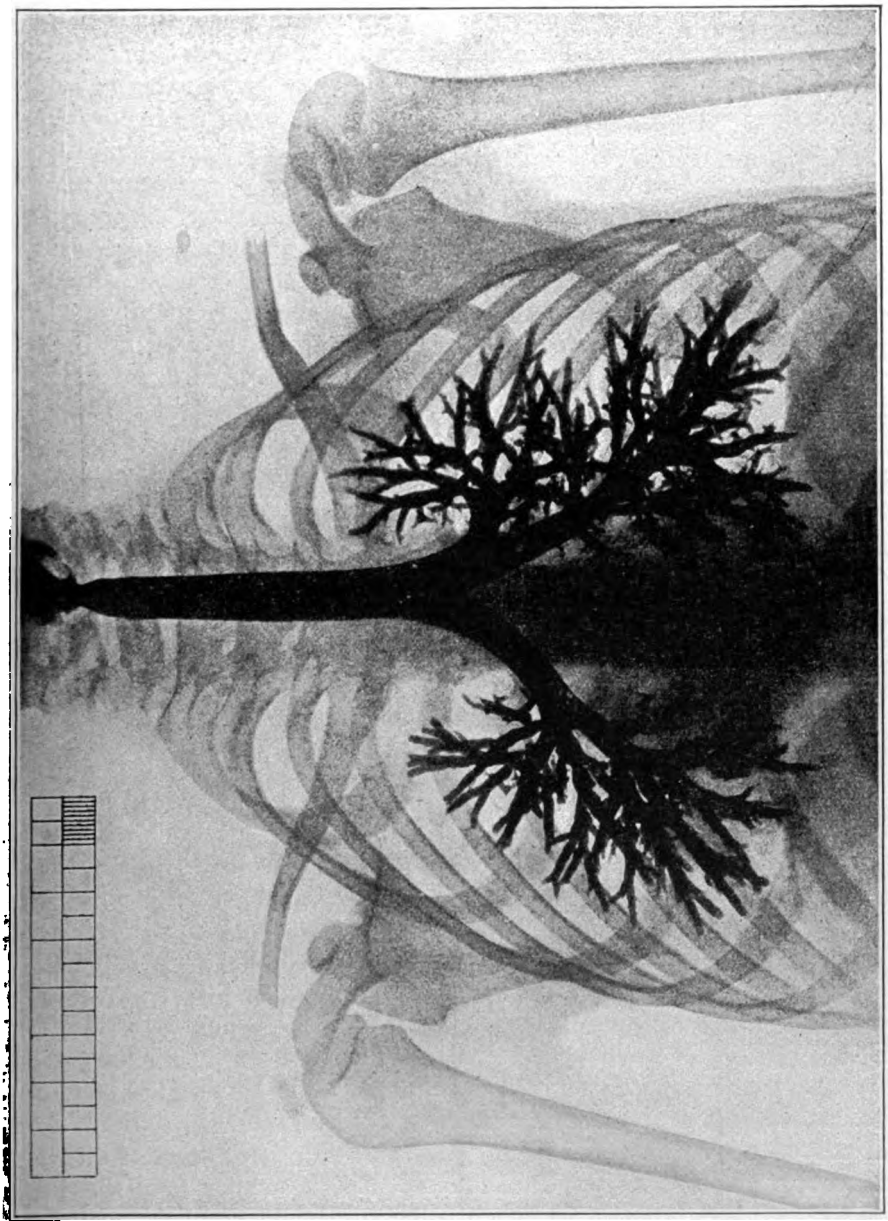

FIG. 271. SKIAGRAM OF NORMAL BRONCHIAL TREE (from Bruenings' *Atlas of Bronchoscopy, Œsophagoscopy, and Tracheoscopy*, by W. G. Howarth, 1912).

thus causing cessation of breathing. Under the condition it was impossible to dilate the stricture by endotracheal methods. The trachea was therefore exposed, but appeared to be normal. An opening was made into it above the stricture, and it was then seen that the latter was caused by a thickening of the anterior and lateral walls, involving two rings of the trachea and apparently of inflammatory nature. As no history of inflammation had been obtained the tissue was examined microscopically, and this confirmed the diagnosis. Division of the stricture completely relieved the dyspnœa, and after a few days the wound was allowed to heal. Three months later there was some return of the dyspnœa, and tracheoscopy was again performed. The stricture had to some extent returned, but was easily dilated through the tube, and two months later there had been no further dyspnœa. By the passage of bougies through a bronchoscope a stricture of the bronchus has been relieved in a similar manner.

(iv) *For diagnostic purposes* alone, to determine the cause of pressure upon the air-passages; as in tumours of the mediastinum, aneurysm, and the like.

The instruments required correspond in the main to those used for direct laryngoscopy (see p. 519). The special instruments include (*a*) bronchoscopes, which are long circular tubes of dimensions suitable to the patient:

LENGTH AND SIZE OF TUBE REQUIRED IN UPPER BRONCHOSCOPY (Killian)

	Adults.	*Children.*
Length	30–40 cm.	20–30 cm.
Diameter	9–14 mm.	5–7 mm.

These should be marked externally in centimetres, measured from the distal end of the tube, and should be provided with a lateral window to allow of free breathing through the opposite bronchus when the tube is introduced into the one which is obstructed; of the various forms in use, the sliding tube of Bruenings appears to me superior; (*b*) instruments for extraction, including forceps and hooks according to the nature of the body to be removed; (*c*) aspirator for removal of mucus, and sponge-holders, the length of the bronchoscope.

Operations (see also p. 520). As regards the anæsthetic, chloroform is preferable in children, but in adults cocaine may suffice. The operations are best performed in a room which can be made dark.

Tracheoscopy. The preliminary stages are similar to those of direct laryngoscopy. If the larynx be found normal, a smaller tube can be passed through the tube-spatula between the vocal folds, and the spatula can then be divided and removed in separate halves. In Bruenings' instrument the inner tubes are so constructed that they can be pushed

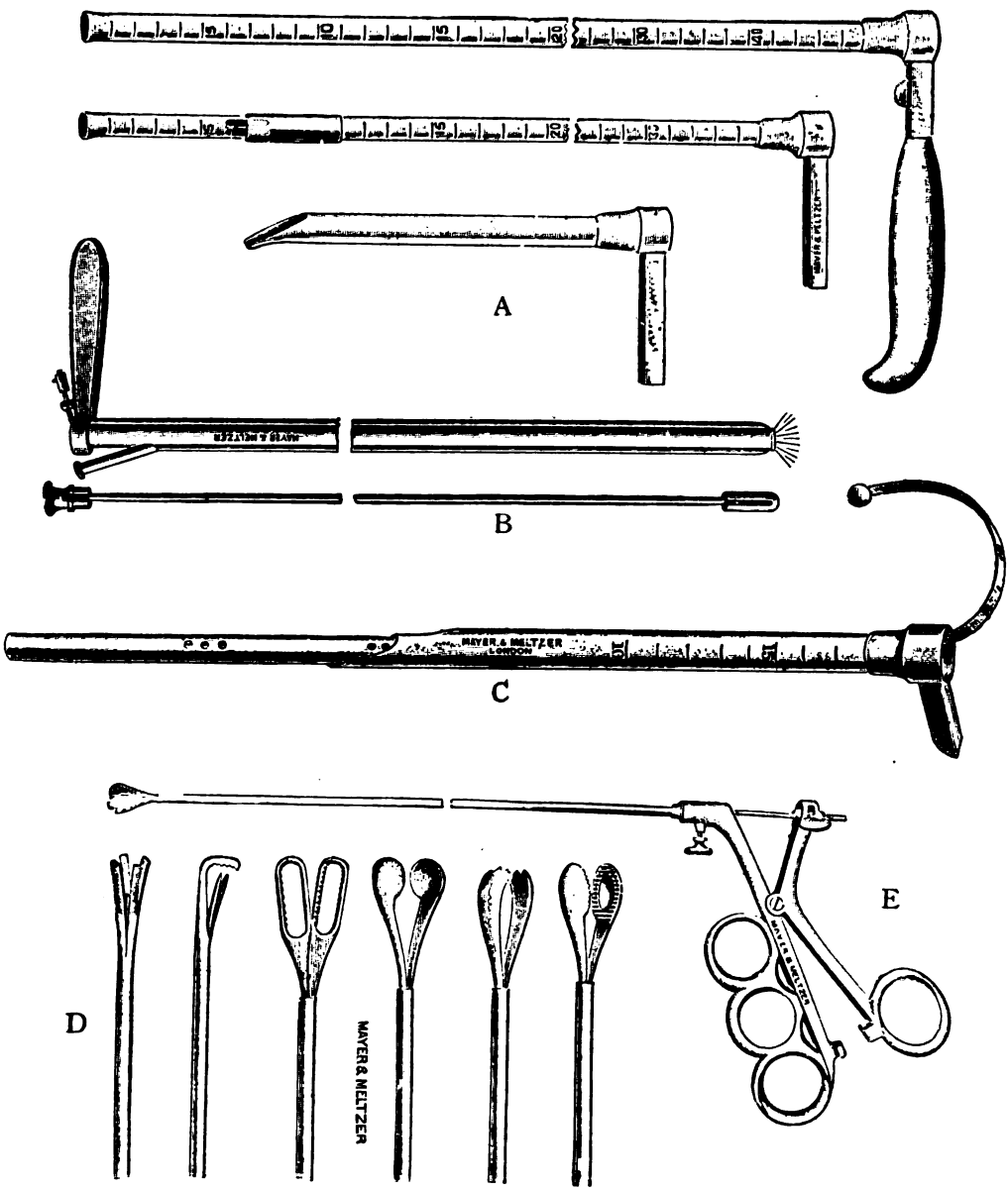

FIG. 272. INSTRUMENTS FOR BRONCHOSCOPY. Bronchoscopes: A, Killian's; B, Jackson's; C, Bruenings'. D, Instruments for extraction. E, Handle (Watson Williams's).

through the outer tube and made to project like a telescope to any desired distance. In this way the subglottic region and trachea can be explored.

Upper bronchoscopy. From the statistics of Kahler it appears that upper bronchoscopy has become more popular since 1909 than lower bronchoscopy. In the former operation the tubes are passed through the mouth, and the inner one is projected until the bifurcation of the trachea is visible. In order to avoid injury to the tissues, the operation should be performed entirely by sight and with great care, for cases have been recorded where tracheotomy was needed for the relief of dyspnœa caused by œdema of the larynx which had followed traumatism.

The tube having been passed, cocaine (10%) is applied to the bifurcation of the trachea, and mucus is removed by sponging or by an aspirator. If the secretion be excessive, the foot of the table should be raised so that the mucus drains away from the part to be explored.

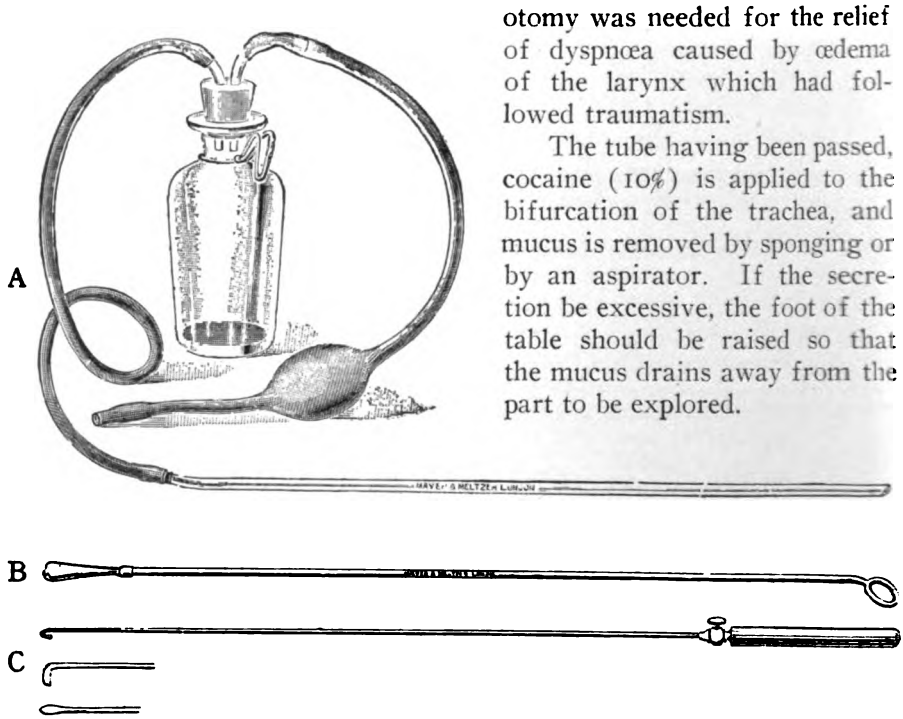

FIG. 273. INSTRUMENTS FOR BRONCHOSCOPY.
A, Aspirator for mucus; B, Sponge-holder; C, Hooks.

It is the duty of the anæsthetist or some competent assistant to note that normal respiration is maintained, and the necessity for tracheotomy or artificial respiration must always be borne in mind. Bruenings advises inhalations of oxygen during the operation and claims that this renders tracheotomy unnecessary in many instances, allows examinations in patients suffering from dyspnœa without tracheotomy, and avoids the danger of hurried tracheotomy.

If the operator be experienced, upper bronchoscopy can be performed

without endangering the patient's life even in the case of a young child. A baby of eight months has been successfully treated by this method.

Lower bronchoscopy. Preliminary tracheotomy (median or low) having been performed, a wide tube is introduced into the bronchus through the wound in the trachea. This method has the following advantages: It is easier to perform, and the surgeon requires less experience of technique; the tube, being wider, is more readily illuminated; there is little danger of asphyxia; in passing the tube no organisms are introduced from the mouth, and there is less danger of pneumonia. If these advantages are weighed, it becomes apparent that the lower operation is preferable for surgeons without experience. It is also advisable in children under five for removal of foreign bodies which are difficult or dangerous to extract. In all cases with urgent dyspnœa preliminary tracheotomy is practically essential.

By a combination of the above methods the diagnosis of foreign bodies can be positively determined in the majority of cases. As Killian said as early as 1902: 'We have now reached a position in which, in many cases at least, one can not only obtain a positive result but with confidence can assert that the foreign body is not present.' More recently Bruenings has collected more than 600 cases in which successful extractions have been reported. As Kahler [1] rightly says, 'the publication of simple uncomplicated cases of foreign body has already gradually lost all interest.'

As soon as the foreign body is clearly seen, a pair of forceps is selected and introduced through the tube. The object is grasped and drawn through the tube, if this be possible, or the tube and forceps may be withdrawn together from the trachea. If the foreign substance be broken the operation can be repeated until all of it has been removed. If the patient becomes collapsed it may be necessary to postpone the continuation of the treatment until the following day. A second attempt is often successful when the first has proved a failure.

Bronchoscopy is comparatively easy to perform—(*a*) when the foreign body lies in the trachea or main bronchus; (*b*) when the foreign body has been accurately located; or (*c*) when the operation can be performed early, before inflammation has supervened. In the rare instances where the body lies in one of the secondary or tertiary bronchi, or has penetrated the substance of the lung, the difficulties are much increased, and in such conditions the question of the advisability of lower bronchoscopy should be considered.

Complications seldom occur after removal of foreign bodies by these methods if the surgeon is careful to avoid injury when passing the

[1] *Report of Third Internat. Laryngo-rhinological Congress,* Berlin, 1911.

FIG. 274. UPPER BRONCHOSCOPY WITH THE PATIENT IN THE DORSAL POSITION.

FIG. 275. LOWER BRONCHOSCOPY WITH THE PATIENT IN THE DORSAL POSITION.

tubes. There may be temporary hoarseness owing to congestion of the mucous membrane. Ingals has reported two cases in which death occurred soon after the operation, with symptoms like those of delayed poisoning from an anæsthetic, and has raised the question whether it is advisable to use cocaine or atropin in these operations. Delavan, on the other hand, suggests that injury to the pneumogastrics may account for such collapse. As stated above, the combination of chloroform and cocaine does not appear to be dangerous if used with discretion.

Results. Removal of foreign bodies by bronchoscopy gives far better results than the older methods of treatment such as tracheotomy, bronchotomy, and thyrotomy. With the last-named operations more than one-third of the cases have been fatal: while, on the other hand, taking the 164 cases[1] collected by Killian in 1907, it is found that in 159 (leaving out 5 with unknown result) only 21 (or 13%) died, viz. 2 from cocaine; 2 because it was impossible to remove the object on account of bronchial stenosis; 1 from suffocation in spite of upper and lower bronchoscopy; and the remaining 16 of pulmonary complications —5 with the foreign body in the lung, and the others in spite of its removal. Upper bronchoscopy was fully successful in 54 cases, and lower bronchoscopy in 63. The result of the remaining 21 operations is not stated.

Speaking of his own cases, Killian writes: 'My own statistics give perhaps a better judgment for the future of cases of foreign bodies in the deeper air-passages than the general, since I have gradually acquired a larger experience and more practice. Nevertheless, I have the impression that in many cases my technic has not reached the highest mark, and I hope to obtain better results in the future.' This impression has already been realized, for Kahler has recently collected a series of 291 cases during 1909 and 1910 with a mortality of only 9.6%, and in no single case could death be attributed to bronchoscopy.

To Killian, of Berlin, is due the chief credit for having introduced a safe method of treatment, the value of which is generally recognized in England.

[1] *Trans. Amer. Laryng. and Otol. Soc.*, 1907, p. 80, 'The Treatment of Foreign Bodies in the Respiratory Tract and Esophagus.'

SECTION VI

OPERATIONS UPON THE NOSE AND ITS ACCESSORY CAVITIES

BY

SIR STCLAIR THOMSON, M.D., F.R.C.P. (Lond.), F.R.C.S. (Eng.)

Professor of Laryngology and Physician for Diseases of the Throat, King's College Hospital, London

CHAPTER I

GENERAL CONSIDERATIONS IN REGARD TO OPERATIONS ON THE NOSE AND NASO-PHARYNX

An intimate knowledge of the surgical anatomy of the nose is an important factor in successful treatment. It is sufficient to recall the close relations of the nasal chambers and their accessory sinuses with the cavities of the orbit and the cranium, and to remember that the shape and size of these air-spaces may vary considerably within physiological limits.

The arrangements of the vascular, lymph, and nervous supplies, and their connexion with neighbouring parts and the body generally, have also to be kept in mind.

In planning and carrying out operative procedures it is also well to keep in mind the important physiological functions of the nose.

Disease in the nose involves both medical and surgical treatment. The general progress of surgery, improved technique, local anæsthesia, and the control of hæmorrhage we now possess, have all tended to replace local medication by surgical measures. But in many affections of the nose—such as syphilis, or diphtheria—surgical relief is quite secondary to medical treatment. In any case the surgeon cannot dispense with a knowledge of suitable topical applications and the principles on which they are founded.

SOURCES OF ILLUMINATION

A good source of illumination is the first necessity for satisfactory operations on the upper air-passages. The natural sources at our disposal are sunlight and diffuse daylight. They have the great advantage of not altering the natural colours of the parts examined. Reflected sunlight forms a perfect illuminant, if we are careful not to bring the rays to an exact focus on the mucous membrane, as this might produce a burn.

Diffuse daylight is too feeble for the examination of the cavities of the nose and larynx, but it can be used for inspecting the mouth, pharynx, and ear. Direct daylight is particularly serviceable for examining suspicious rashes or patches in the mouth and pharynx, and eruptions on the skin.

Some form of artificial light is indispensable. That furnished by an ordinary paraffin lamp or a gas flame is sufficient for examination. The

flame should have its flat side towards the observer, and be enclosed in a glass chimney, without a globe or shade. If neither of these lights be available, an ordinary candle, or, better still, three candles tied together, will suffice.

For use in the study a paraffin reading-lamp or a gas standard is equally suitable. The latter is rendered more effective by the adoption of an Argand burner or a Welsbach mantle. The oxy-hydrogen limelight is the most perfect of artificial illuminants, but it is bulky and expensive.



FIG. 276. LARYNGOSCOPE LAMP.

The most convenient light is that given by a 32 or 50 candle-power electric light in a frosted globe, and with the filament waved. The Nernst electric burner gives increased brilliancy.

The electric light has the further advantage that it is unnecessary to maintain it constantly vertical. When enclosed in a bull's-eye, the lamp can be rotated so as to direct the pencil of light-rays either upwards or downwards, as well as from side to side.

Whichever light is employed the rays can be concentrated and rendered more powerful by enclosing it in a dark chimney with a bull's-eye condenser. The light must also be provided with some arrangement by which it can be raised and lowered (Fig. 276). For operating Clar's electric light is useful (Fig. 277).

In all these methods the light is reflected, but the direct rays of the electric light can be used in a small lamp fixed on the forehead, and fed from an accumulator or direct from the street current through a suitable resistance. It is better than reflected light in operations on the nose and

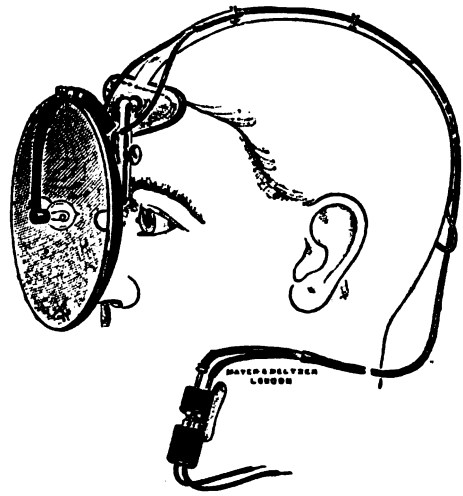

FIG. 277. CLAR'S ELECTRIC LIGHT.

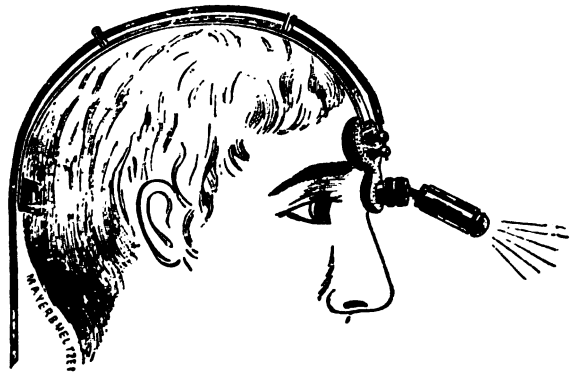

FIG. 278. FRONTAL SEARCH-LIGHT.

throat, and the portable accumulator and the frontal photophore (Fig. 278) are convenient for use in the patient's own home.

The lamp should be placed on a stand or table so that the light is on a level with the patient's ear, and 3 or 4 inches distant from it. In Continental schools it is customary to place the light on the patient's right hand. In this country the lamp is usually placed close to the patient's left ear, i.e. on the observer's right hand. As practitioners will

often be called to see patients who are confined to a bed which can only be approached from one side, it is desirable that they should accustom themselves to work equally well with the light on either side, and the frontal mirror over either eye.

LOCAL ANÆSTHESIA

Cocaine. It is often desirable to secure a slight degree of local anæsthesia to facilitate complete exploration of the nose. Many operations can be carried out by rendering the nasal mucosa absolutely insensitive with cocaine.

Applied in the nose cocaine is (*a*) an anæsthetic, (*b*) a powerful vaso-constrictor, and, consequently, it (*c*) produces local anæmia. Hence cocaine is of great value in nasal surgery, not only because it renders the mucous membrane insensitive, but also because it retracts the tissues and reduces the hæmorrhage.

Methods of use. A small area can be anæsthetized by placing a few crystals of hydrochlorate of cocaine on the required spot, where the mucus will dissolve it *in situ*. A 2 to 5% solution may be sprayed into narrow nostrils, to facilitate examination. It is a better plan to moisten pledgets of cotton-wool or ribbon gauze with a 10% solution, and place them in direct contact with the part to be operated on. The addition of a little suprarenal extract will not only facilitate examination and treatment of its hæmostatic action, but, for the same reason, will tend to prevent the cocaine being absorbed and producing its toxic effects.

For the more complete anæsthesia required for operation the following plan is advised. Equal parts of a 20% solution of cocaine and the standard 1–1,000 extract of suprarenal gland are mixed together. Short strips of 1-inch wide ribbon gauze are moistened with this solution and laid flat in close contact with the nasal area to be operated on. They are left in place for at least half an hour, and even at the end of one hour local anæsthesia will only be more marked. While the final preparations are being made for operation a fresh layer of moistened gauze may be applied. Finally, if there should still remain the slightest degree of sensation over the spot to be treated, a few cocaine crystals will render it quite numb.

Submucous injection of cocaine. Great caution is necessary in making intracellular injections of cocaine, as the drug is intensely toxic in this form, but, fortunately, only a small dose is required. It is a good plan never to exceed 1 centigramme (1/6 grain) of the salt. As the hæmostatic effect of suprarenal gland extract is required at the same time, the two are combined: 1/6 grain of cocaine, 2 drops of adrenalin, 1/6 grain of sodium chloride, and 1/50 grain of morphine are dissolved

in 60 minims or more of sterilized water, and slowly injected below the mucosa. At least 20 minutes must elapse to secure full effects.

This submucous injection of cocaine and adrenalin should not be employed with a general anæsthetic. Owing to disregard of this warning several deaths have been recorded. Within two or three seconds of the injection the anæsthetized patient becomes pallid, respirations are rapid and shallow, the pulse is hurried, small, and irregular, and death may occur within a few minutes. Such a catastrophe is best averted by artificial respiration and the usual remedies against cocaine poisoning and cardiac failure. But it is still wiser to avoid such an unnecessary risk altogether. For many years I have employed the method above described for the surface application of adrenalin and cocaine in combination with a general anæsthetic. It has always been completely satisfactory and has never once caused any anxiety.

Substitutes for cocaine. For submucous injection it is better to substitute eucaine or novocaine. Eucaine can be kept in a ready and portable form in small glass ampoules in the dose of 1/6 grain with 1/2000 grain of adrenalin, and tablets are sold containing 1 centigramme (1/6 grain) of either of these drugs in combination with adrenalin and chloride of sodium. One of these tablets is dissolved in 60 minims or more of water and boiled. It is reported that as much as 1 grain of novocaine may be injected at one sitting, but I prefer to keep to the limit of 1/6 grain, and have always been able to obtain complete local anæsthesia with it.

Eucaine is much less toxic than cocaine, and novocaine is said to be still safer. They act just as well for submucous injection, but, applied to the mucous surface, the anæsthesia is not so complete, and the vasoconstrictor effect is less. Still, for susceptible subjects, either is to be preferred to the more toxic cocaine.

LOCAL ISCHÆMIA

Adrenalin. The delicate manipulations of intranasal surgery have been greatly facilitated by the employment of the extract of the suprarenal gland under various names—adrenalin, adrenine, adrin, perinephrin, adnephrin, epinephrin, suprarenalin, suprarenin, epirenin, paranephrin, renaglandin, hemesine, hæmostasine, vasoconstrictine, renostypticin, &c. These liquids are generally of the strength of 1 in 1,000, and can be used undiluted on mucous surfaces. But they can be diluted with normal saline solution, solutions of cocaine, or other drugs. If kept in well-stoppered, tinted glass bottles the solution can be preserved for many weeks. The solid extract is useful for those who only employ it occasionally, and in this form it is conveniently made up with cocaine,

eucaine, or novocaine, so that solutions of the desired strength are prepared as required.

Applied to a mucous surface adrenalin produces a local ischæmia by contracting the blood-vessels, so that the surface becomes pale and shrunken. At least 20 minutes are required to secure this effect and it is only more marked at the end of an hour. An extensive operation, such as submucous resection of the septum, can then be performed without the loss of more than a trifling amount of blood in most cases. The vasoconstrictor action is followed by a stage of dilatation, disposing to secondary hæmorrhage, which, according to some authorities, may be 'violent and sometimes serious.'[1] I have been fortunate in not meeting with this occurrence. Its possibility can generally be guarded against, and need never prevent the employment of the drug when indicated.

Adrenalin has no anæsthetic power, but its constricting action lessens the tendency of cocaine to be deeply absorbed, increases the latter's local effect, and allows of a weaker solution being employed.

Another secondary result is the very irritating rhinitis which is sometimes induced. It passes off in 24 to 48 hours.

Uses. The addition of a small quantity of adrenalin to a cocaine solution mitigates the toxic action of the latter, and its use appears to check tendency to collapse, either from shock or chloroform, during serious operations on the nasal cavities. Its chief use is to check hæmorrhage and allow us to perform practically bloodless operations in the nose.

Methods. Adrenalin is employed as described for cocaine. Disappointment in the result obtained is nearly always due to neglect in recognizing that its full effect cannot be obtained in less than 20 to 60 minutes.

BLEEDING AND ITS CONTROL

Bleeding in the nose cannot be controlled as easily and directly as in the operations of general surgery, and there is always the risk of blood passing into the lower air-passages.

Causation. Hæmorrhage is apt to be not only more free, but also more serious, in young children and in patients over 60. The tendency is increased with menstruation or pregnancy, and hæmophilia is to be particularly looked for. In the nose the vascular conchæ (turbinals) bleed freely; a small varicose vessel on the septum is the commonest source of epistaxis—often very copious. Many vascular growths are met with, and malignant ones are apt to bleed profusely.

Secondary hæmorrhage may occur between the third and eighth day, when clots or crusts become detached.

[1] C. A. Parker, *Diseases of the Nose and Throat,* London, 1906.

The prevention of local hæmorrhage. The patient should be prepared more carefully than usual for an operation. Hæmophilia should be inquired after, and if there is any suspicion of it lactate of calcium is administered for three days beforehand, in doses of 15 to 30 grains twice a day. If the patient be an undoubted hæmophiliac, an operation should be avoided if possible. It is well to suspend the use of alcohol and tobacco for at least three days beforehand. Many risks are avoided if the operation can be carried out in the home or hospital where the patient has slept, and if he can remain there afterwards.

The arrest of local hæmorrhage. The preliminary use of adrenalin will diminish bleeding in many cases (see p. 613). When it does occur, unless the hæmorrhage is serious, it is well not to be too precipitate in efforts to arrest it. Such attempts, by stimulating the patient, detaching blood-clots, or exciting reflexes, may even maintain it. The clothing should be loose, the operating room should be well aired and cool, and iced water should always be at hand. If freely sluiced over the face, behind the ears, and round the neck, cold water has such a remarkable reflex vasoconstrictor action that it alone is sufficient to arrest hæmorrhage in the majority of operations on the nose and throat. Its stimulating effect on the respiration and circulation is always agreeable to the patient, and may be very valuable when he is under a general anæsthetic.

If operated upon under a local anæsthetic, the patient's head should be inclined forwards, so that the blood can drip from the nose. The first formed clots may be expelled, but then he should avoid sniffing, sneezing, or coughing, and sit with the head forward and the nostrils completely closed with his thumb and forefinger. Five to ten minutes in this position will arrest the bleeding in most cases of epistaxis. A slight oozing of blood may be allowed to go on for a few hours in certain cases. If the bleeding persists, ice should be applied externally and held in the mouth, the nose may be syringed with very cold or with very warm salt and water (℥i to the pint), and the horizontal position assumed.

If this fails, a pledget of cotton-wool is dipped in peroxide of hydrogen solution (10 vols. ℈) and introduced into the bleeding nostril, the orifice of which is then closed by the surgeon's thumb. This may be repeated more than once, the patient lying on his side, face downwards, and pinching both nostrils. If a galvano-cautery be available, and the bleeding comes from a limited and visible point, it can be sealed with a touch of the cautery point.

If these methods fail, plugging must be resorted to. With the nasal speculum and good illumination, the bleeding area is cleansed with cocaine and adrenalin and a strip of 1-inch ribbon gauze is carefully packed on to the spot, the end being left just within the vestibule, so

that the patient can remove it for himself at the end of 12 or 24 hours. It is better to use a single strip of gauze, instead of cotton-wool, as portions of the latter might be detached and left behind. If there be fear of the gauze strip becoming adherent, it can be well smeared with plain sterilized vaseline. Dry ribbon gauze, impregnated with adrenalin, can also be employed.

If the bleeding comes from far back in the nose, or from the post-nasal space, it may become necessary to plug the latter cavity. A sterilized sponge, about the size of a Tangerine orange, is squeezed very dry and tied round its centre with a piece of tape or stout silk ligature, leaving two free ends of about 12 inches in length. A soft rubber catheter is passed along the floor of the nose till it appears below the soft palate, when the end is seized with forceps and drawn through the mouth. To this end one of the tapes is made fast, so that when the catheter is withdrawn from the nose, the sponge is pulled up into the post-nasal space; the other end hangs out of the mouth. The two tapes are tied together over the upper lip. The anterior part of the nostril can then be packed with gauze, if necessary. If the patient be under chloroform, one tape can be dispensed with; the soft palate is simply held forward with the forefinger of one hand, while the other passes the compressed sponge up into the naso-pharyngeal space.

Plugs in the nose should be avoided. They are painful, interfere with repair, prevent drainage, and may be followed by septic troubles in the nose, accessory sinuses, middle ear, or cranial cavity. Bleeding often recurs on their removal. In any case they should not be left unchanged for more than 24 or, at the most, 48 hours. Removal is facilitated by soaking them well with peroxide of hydrogen, and detaching them slowly and gently. Ligature of the external carotid may be necessary in extreme cases.[1]

THE PROTECTION OF THE LOWER AIR-PASSAGES FROM THE DESCENT OF BLOOD

When operated upon under local anæsthesia the patient is able to prevent blood descending from the nose or throat into the larynx or trachea. In this he is assisted by throwing the head forwards.

When the patient is under a general anæsthetic other measures must be taken to guard against the descent of blood into the windpipe and lungs. The most important is to see that the anæsthesia is never so deep as to abolish the swallowing or coughing reflexes. Fortunately these are amongst the last to go, yet in many cases it is well to let the patient come partly round, so as to expel blood and mucus by coughing. If the

[1] Chevalier Jackson, *Transactions American Laryngological Association*, 1907.

frontal sinus is being operated upon, the nose is carefully packed beforehand. When the ethmoidal labyrinth is being cleared, or the sphenoidal sinus opened, a sponge may be placed in the post-nasal space as described above until the operation is completed. During the operation upon the maxillary sinus through the canine fossa, a sponge placed between the last molar teeth and the cheek on the same side, and frequently renewed, will keep any blood from entering the pharynx. In operations upon the naso-pharynx, it is a wise precaution, when much bleeding is anticipated, to perform a preliminary temporary laryngotomy and plug the pharynx with a sponge (see p. 550). The trachea and lungs can also be protected from blood invasion during operation by employing Kuhn's intubation tampon (Fig. 259). This is on the principle of O'Dwyer's intubation tube. A hollow intubation tube is firmly fitted in the larynx; from its upper end a flexible tube is led outside the mouth: through this the patient breathes and the general anæsthetic is administered, while no blood can descend through it, nor through the larynx, to the lower air-passages.

In many proceedings security is attained by rolling the patient well over to one side, so that the blood runs out of the corner of the mouth, or collects in the cheek, from which it can be sponged. A good deal of blood is also swallowed. This may be vomited as consciousness returns; if not, an aperient should be given within 24 hours to prevent gastro-intestinal sepsis.

The descent of blood into the trachea and lungs, if sudden and copious, may cause immediate asphyxia; or, if less abundant, it may cause septic pneumonia. When it occurs, the anæsthesia should be stopped, and the patient rolled well over on to his face or inverted, until the breathing is quite unobstructed. After all nose and throat operations it is a wise precaution for the patient to be kept on his side, the head on a low pillow, and face downwards, while the body is arranged in the gynæcological position.

SHOCK

Shock, particularly in operations on the nose, is apt to be marked in young children and in elderly persons. It is for this reason that we try to avoid the removal of adenoids in patients under 3 years of age, or of polypi in those over 60; and that in all cases we endeavour to operate as rapidly as possible.

This possibility of shock is guarded against and treated in the usual way. The local application of cocaine and adrenalin—even in patients under a general anæsthetic—helps to avoid it,[1] and anæsthesia should

[1] G. W. Crile, *Journal Amer. Med. Assoc.*, June 17, 1905.

never be too deep or prolonged. When operating under local anæsthesia it is sometimes wiser not to attempt too much at one sitting, e.g. to treat only one side of the nose at a time. In certain conditions, and when a general anæsthetic is employed, it may be safer to try and complete treatment at one operation.

SEPSIS AND OTHER COMPLICATIONS

Deaths have been recorded after the simple use of the galvano-cautery, or the removal of nasal polypi, and of course are more to be feared after major operations, such as the radical cure of sinus suppurations.

Septic infection from nasal operations may spread to the accessory sinuses, meninges, ear, eye, tonsils, glands, gastro-intestinal tract, bronchi, and lungs. From the nasal part of the pharynx, the ears and the lower food and air tracts are chiefly threatened. The orbit may be invaded in operations on the ethmoid; the external muscles of the eye may be injured in the frontal sinus operation; and optic atrophy may be due to plugging of the ophthalmic vein.

While these accidents may sometimes be directly due to operation, it is well to remember that in treating such septic conditions as are entailed by nasal suppuration, the complications may only be precipitated by traumatism and may also be purely coincident. It is not to be forgotten that latent infection—of influenza, erysipelas, measles, scarlatina, diphtheria, or other disease—may develop immediately after an operation upon the nose or throat, and until its true character is recognized the operation is often unjustly blamed. Septic infection, in these necessarily exposed wounds of the air-passages, may be traced to insanitary surroundings.

ASEPSIS

The field of operation in rhinology can never be rendered completely sterile, and in many cases is particularly septic. Wounds through the mucous membrane cannot be protected with dressings in the usual way; so that the local methods of repair require particular study.

In the nose, when there is no suppuration, it is safer to make no attempt to purify the cavity, beyond cleansing the vibrissæ and vestibules. The Schneiderian membrane will not tolerate any antiseptic lotion of such a strength as to be effective, and weaker solutions only interfere with the action of the cilia, the protective power of the mucus, and other defensive arrangements of the nose. If pus, scabs, or foreign bodies exist in the nose, it should be well washed with a simple tepid alkaline solution.

But every care should be taken to purify the surgeon's hands, sterilize all instruments, and see that no contamination takes place during the operation. This is assisted by having the patient's head surrounded by a carbolized towel, and his face, moustache, and beard well washed, for the surgeon's hands and instruments come in frequent contact with these parts.

AFTER-TREATMENT

After all intranasal operations everything should be avoided which interferes with the drainage, ventilation, and natural repair of the region. Protective dressings cannot be employed, and we have in most cases to aim at healing under a blood-clot. Tags of semi-detached tissue and loose clots of blood are removed, but otherwise the parts are disturbed as little as possible. For the first two or three days the nose may be left alone, and if there be no bleeding the patient is encouraged to breathe through it. When there is much formation of thick mucus, or blood-clots or sloughs are loosening, a tepid alkaline lotion can be used. The pain of stiffness or dryness in the nose is relieved by an ointment or an oily spray.

Adhesions are apt to form between the septum and the lateral wall when opposing surfaces are injured by the galvano-cautery. They may occur in narrow cavities after cutting operations. If an adhesion be seen to be threatening in the first few days, it should be broken down with a probe, and strips of gauze or plates of white celluloid introduced daily until healing takes place. If it forms later, it is wiser to wait until the fleshy bridge becomes less vascular and contracts, when it may be divided with a knife or the galvano-cautery at a white heat, and the opposing surfaces are then kept apart as described.

All post-operative conditions in the nose and throat will heal more rapidly and pleasantly if the patient be freely exposed, day and night, to abundance of fresh air; and while fatigue is generally to be avoided, the sooner the patient is out of bed and in the fresh air, the better for him. Our inability to operate under aseptic conditions should make us more careful to raise the resistance of the individual by general care, and to protect him from external dangers.

CLEANSING THE NOSE

The simplest and safest method of cleansing the nose is by blowing it,—one nostril at a time. Sometimes it is required to hawk any discharge backwards and expel it through the mouth.

Watery lotions are frequently required to assist in cleansing the nose. Strong antiseptics and astringents must be avoided. All nose

lotions should be alkaline, and isotonic with the blood plasma. These requirements are met by prescribing one or more alkalis (bicarbonate of soda, borax, salt, &c.), in the strength of about 5 grains to the ounce. They may be rendered more pleasant by the addition of white sugar or glycerine. The addition of a small amount of some mild antiseptic —menthol, thymol, oil of eucalyptus, carbolic, sanitas, listerine, &c.— may give a pleasant flavour. But all antiseptics have a slight irritant action which is disagreeable if there be an intact mucosa, although they may be more helpful in certain cases of ulceration or intranasal sepsis. When the Schneiderian membrane is more or less damaged, when there are foreign bodies, sloughs, necrosis, &c., in the nasal chambers, these or similar antiseptics can be employed, though always with an alkaline basis.

All nose lotions should be employed tepid. They may be sniffed, irrigated, sprayed, or syringed into the nostrils. Crusts, scabs, and sloughs may have to be removed from the nose with forceps, after its sensitiveness has been deadened with cocaine; peroxide of hydrogen will help to detach them.

AFTER-RESULTS

Incomplete operation may be unsatisfactory in many ways. Thus, nasal obstruction may be unrelieved: foci of suppuration may be left in the accessory sinuses: portions of adenoid growth or tonsils left behind may continue to give trouble: malignant growths may not be extirpated freely enough. On the other hand, operations may fail to relieve, or even produce a worse state of affairs, if too much tissue be sacrificed. This is important as regards the nose, owing to the important respiratory and defensive function of its mucous membrane. It is a good rule to injure the inferior turbinal as little as possible, otherwise a condition of crusting rhinitis may be set up, with secondary atrophy in the pharynx and larynx.[1]

Much judgment is required in adapting the suitable operation to each case. While in some instances one or more small interventions are all that is required, in another a well-planned and more extensive operation may be indicated. In any case, the advice of Semon should be kept in mind, viz. that the magnitude of an operation should not exceed the gravity of the symptoms calling for relief.

[1] W. H. Stewart, *Proc. Laryngol. Soc. Lond.*, March 5, 1898, p. 57.

CHAPTER II

OPERATIONS FOR INJURIES, DEFORMITIES, FOREIGN BODIES, AND RHINOLITHS: OPERATIONS UPON THE CONCHÆ (TURBINALS): OPERATIONS IN SYPHILIS AND LUPUS

OPERATIONS FOR INJURIES TO THE NOSE

THE external injuries of the nose belong to general surgery. It might be well to recollect that the fleshy end of the nose may be completely detached, and yet, if carefully and promptly replaced, perfect union will occur.[1]

FRACTURES OF THE NASAL BONES AND SEPTUM

Setting a recent fracture. One or both nasal bones may be displaced, causing a flat bridge with a sharp ridge on either side.

In the septum fracture generally takes place in the quadrilateral cartilage, or displacement occurs at its junction with the vomer or maxilla. It may be accompanied by a hæmatoma (see p. 653), and the occurrence of epistaxis shows that it is really a compound fracture. Care should therefore be taken not to infect the wound in the nose, and the patient should be warned on the subject.

The application of cocaine and adrenalin may allow of careful inspection of the septum. But, as the exact condition of things is masked by swelling, it is nearly always advisable to administer a general anæsthetic. Crepitus can rarely be made out. A hæmatoma is dealt with as directed (see p. 653). If there be any displacement of the septum—and it generally takes place towards the side on which there is already some convexity or depression of the nasal bones—the parts should be raised into place by manipulation with the little finger in the nostril. A flat-bladed forceps, like those of Adams, may be used. One blade in each nostril will straighten the septum and, at the same time, raise the whole nose into place. Small pencils of sterilized cotton-wool, smeared with vaseline (see p. 650), are then carefully packed up into the roof of the nose and kept there by Meyer's vulcanite tube (Fig. 279). They are changed every 24 or 48 hours for a week or so. The vomer is rarely fractured, although much callus is often thrown out in the displacements which occur between it and the cartilage.

[1] J. M. Renton, *Brit. Med. Journ.*, December 16, 1905.

Recent cases require no splints. In fact, if the displacement be promptly reduced—under general anæsthesia—the restored parts will generally maintain their position.

FIG. 279. MEYER'S HOLLOW VULCANITE NASAL SPLINT.

Elevating an old fracture. In neglected cases it may be necessary to re-fracture the nasal bones, and when these are replaced an external splint may be necessary. This can be made of plaster of Paris; or the outside of the nose may be covered with a piece of heavy adhesive plaster, and outside that a shield of tin, copper, or, preferably, aluminium.[1]

Fracture of the ethmoid is, fortunately, rare. When it occurs it is apt to run into the cribriform plate, and be associated with the escape of cerebro-spinal fluid and other indications of fracture of the anterior fossa of the skull.

OPERATIONS FOR CONGENITAL OCCLUSION OF THE NOSTRILS

Operation for congenital occlusion of the anterior opening. *If the web obstructing the nostril be thin and membranous*, and of low vitality, a simple and effective method is to destroy it with the galvano-cautery. It is best to spread the treatment over several sittings, so as to diminish the local reaction. The application of cocaine may not be sufficient to numb the pain, as the tissue of the obstructing web is more allied to skin than to mucous membrane. It should therefore be punctured quickly in two or three places, with a sharp cautery point raised nearly to a white heat. If the patient be nervous it may be well to administer nitrous oxide gas.

After the operation the nasal orifice is kept distended until healing has taken place by wearing Meyer's vulcanite tube in it or short lengths of full-sized rubber drainage-tube, well smeared with boric, aristol, zinc, or similar ointment. These simple nasal dilators are changed once or twice daily, and the nostril is well cleansed on each occasion.

If the web obstructing the anterior naris be more fleshy in character (and it is more apt to be of this nature when it is incomplete), it may be necessary to remove it with a knife. So as to leave as much epithelial tissue as possible, and avoid retraction, the operation is done as follows, under local or general anæsthesia: A narrow, sharp-pointed instrument, such as a Graefe's or other ophthalmic knife, is used to puncture the web from before backwards, and it is then made to sweep round the obstruct-

[1] T. A. de Blois, *Trans. Amer. Laryn. Association*, 1900, p. 12.

ing diaphragm, while gradually cutting its way towards the central lumen. The tongue of skin thus formed can be used as a graft to cover most of the raw surface. The restored anterior naris is kept patent, as already described, till healing takes place.

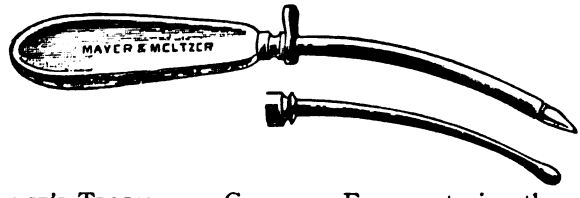

FIG. 280. KRAUSE'S TROCAR AND CANULA. For puncturing the maxillary sinus from the nose.

In some cases the following operation has been shown to be easy and effective: An incision is made at the junction of the web with the septum, keeping close to the latter and passing straight down to the floor of the nose. On the outer side a similar incision is made, but



FIG. 281. NASAL PUNCH-FORCEPS.

sloping somewhat outwards. The flap formed between these two incisions is not cut off, but is bent backwards and fastened to the floor of the nose by a single horsehair stitch.[1]

Operation for congenital occlusion of the choanæ. If the obstruction be not freely and completely removed it tends to re-form.

[1] G. K. Grimmer, *Proc. Royal Soc. of Med.* (*Laryngol. Section*), April, 1908.

A general anæsthetic is required. Unless the operator is ambidextrous he will find it most convenient to stand on the patient's left hand, and to introduce his own left forefinger into the post-nasal space. This enables him to guide any straight, sharp instrument, such as an antrum drill (Fig. 318), Krause's trocar (Fig. 280), or a surgical bradawl, from the front of the nose until it presses against and breaks through the obstructing diaphragm in two or more points. If preferred, an electric trephine can be used, and often pressure with the tip of a pair of nasal punch-forceps will be sufficient. The latter, either straight or tip-tilted (Fig. 281), are then inserted through the nostril, and, still guided by the left forefinger in the post-nasal space, are employed to clip away all the obstruction. To prevent any possibility of this reforming it is recommended by some surgeons that a small piece should

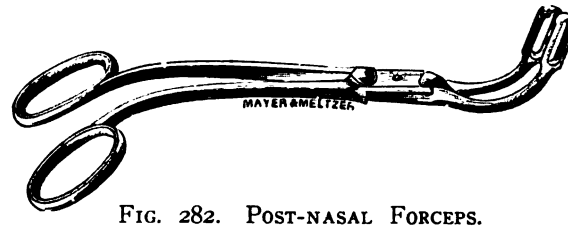

FIG. 282. POST-NASAL FORCEPS.

be nipped out of the posterior margin of the bony septum. This can be done with the beaked punch-forceps of Grünwald (Fig. 281), passed through the nose, or with a pair of Loewenberg's post-nasal forceps (Fig. 282) introduced through the mouth. In either case their action is controlled and directed by the operator's left forefinger in the post-nasal space.

No special after-treatment is required. The patient should be ordered a tepid alkaline nose lotion, and should be encouraged to make use of the nasal air-way and acquire the habit of blowing the nose.

REMOVAL OF FOREIGN BODIES FROM THE NOSE

It might be helpful to remember that foreign bodies not only enter the nasal cavities (1) through the anterior nares, but also (2) through the choanæ, or (3) by penetration through the walls. They may also arise (4) *in situ,* as in the case of sequestra and rhinoliths. The last group will be considered separately.

A foreign body, if small, may form the centre of a rhinolith.

Operation. Great care and gentleness are required in the removal of foreign bodies from the nose. The extraction should never be attempted blindly, or forcibly, or hurriedly. A little delay to make neces-

sary arrangements does no harm. If a child will not submit to examination it is much better to employ a general anæsthetic so as to complete examination and, if found necessary, extraction at the one sitting. If the nose be not well illuminated and opened with a nasal speculum, groping about in the dark will only do further damage and result in disappointment.

In adults removal can generally be carried on under cocaine. The nostril is cleaned with cotton-wool, and if the extremity of the probe used for detecting the presence of a foreign body be curved to a right angle, it will also serve for gently levering or displacing it forwards. With a small pair of nasal dressing forceps (Fig. 283) it can generally be firmly seized and gently extracted, care being taken not to include any

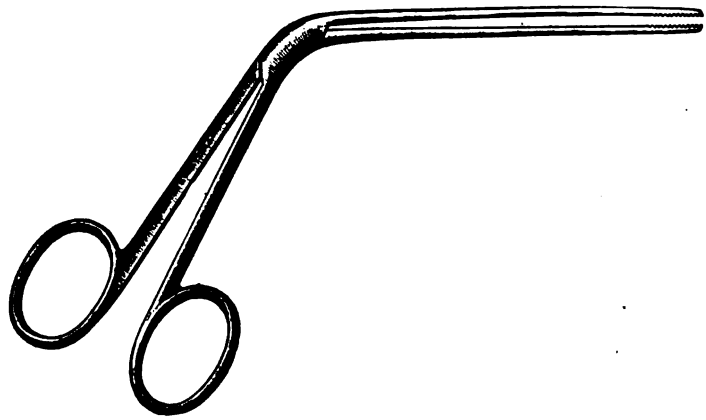

FIG. 283. NASAL DRESSING FORCEPS.

of the mucosa, nor to drag the foreign body out regardless of the sinuosities of the cavity. Lister's ear hook is a most useful instrument. Sometimes a nasal snare will help to extract the substance or to tilt or drag it into a better position.

Unless coated with solid accretions there is never any need to break up a foreign body; anything small enough to slip into the nose is small enough to be extracted entire. If it should be found impossible to remove the body through the anterior nares, it may be pushed backwards into the post-nasal space, where the forefinger of the left hand is in readiness to prevent its falling into the gullet or larynx.

The usual warm alkaline lotion may be used to clear the nose, but liquid should never be forcibly injected into the nostril with the idea of thus expelling the foreign body. If the lotion be sent up the nasal chamber on the same side it will only drive the intruding substance farther in; if injected on the opposite side there is risk of otitis media.

In the case of small children it is sometimes recommended that a piece of muslin should be placed over the mouth, and that the practitioner should then apply his lips to those of the patient and by blowing forcibly through the mouth drive out the foreign body by the blast of air from the post-nasal space. Or the same principle may be applied by insufflating the air from a Politzer's bag through the opposite nostril. Both plans are alarming and seldom effective.

The *after-treatment* consists of some simple cleansing lotion and soothing ointment.

REMOVAL OF RHINOLITHS (NASAL CALCULI, OR CONCRETIONS IN THE NOSE)

These concretions are almost unknown in children, in whom foreign bodies are met with most frequently. A general anæsthetic is, therefore, not so often required, otherwise the remarks on the removal of foreign bodies will be found to apply to the extraction of calculi. With the help of cocaine and good illumination they can easily be removed with a strabismus hook, Lister's ear hook, or a pair of fine probe-pointed nasal forceps with serrated extremities. In some cases where the calculus has sent prolongations into the recesses of the meatus, it might first be necessary to crush it. In that event a general anæsthetic may be required.

The *after-treatment* consists in simple cleansing measures. Subsequent syringing of the nose should be done from the opposite side.

OPERATIONS UPON THE CONCHÆ (TURBINALS)

Indications. In many cases of hypertrophic rhinitis it is necessary to remove portions of redundant conchal tissue. It is never desirable—and it can only rarely be necessary—to remove the whole of the inferior concha. 'Turbinotomy,' or amputation of the whole inferior concha, was recognized as an operation some years ago. But it was never generally accepted, as it was always realized that the highly important physiological functions of the lower concha could not be spared. Improved technique, particularly in being able to correct deformities of the septum without the sacrifice of any mucous membrane (see p. 643), now enables us to rectify nasal stenosis with the sacrifice of much less turbinal tissue.

The middle concha is not of so much importance in the physiology of the nose, and the whole of this body is not infrequently removed. This may be done not only because it is diseased, but even a healthy middle concha may require amputation in order to approach the accessory sinuses or diseases in the deeper regions of the nose. Part of the

healthy inferior concha may also require removal—as in the radical operation on the maxillary sinus.

As these operations will be referred to frequently later on, and as their performance enters into different groups of operation, they will be described first.

OPERATIONS UPON THE INFERIOR CONCHA

Amputation of the anterior end. Indications. The amputation may be required:

(i) On account of polypoid degeneration of the anterior extremity of the concha.

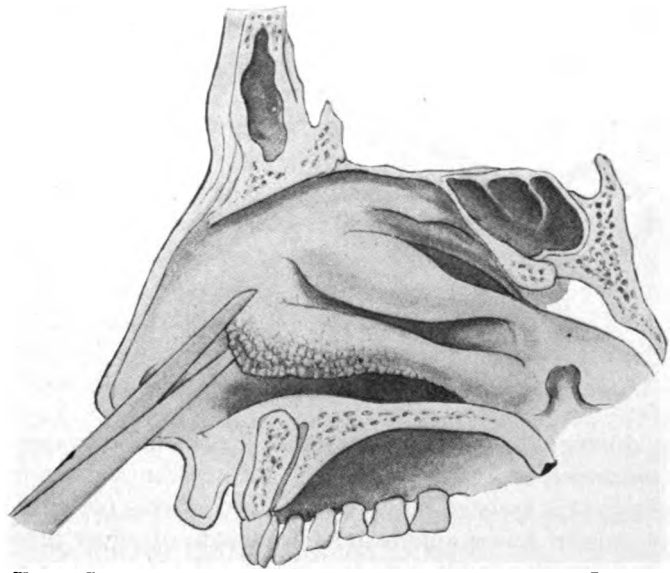

FIG. 284. FIRST STEP IN REMOVING THE ANTERIOR END OF THE INFERIOR CONCHA, WHICH IS SEEN TO HAVE UNDERGONE POLYPOID DEGENERATION.

(ii) To allow of access to the antro-nasal wall (see p. 673).

(iii) To avoid operation on the septum by relieving nasal stenosis.

Operation. The local application of cocaine and adrenalin (see p. 613) is sufficient.

Anæsthesia. With the patient sitting upright in a chair, and the nostril well illuminated, a pair of nasal scissors (such as Heymann's, Walsham's, or Beckmann's) are made to grasp as much of the anterior extremity as it is desired to remove, generally the anterior third (Fig. 284). The scissors are pressed very firmly against the lateral nasal wall, so as to divide the base of the concha as close as possible to its attachment. If the scissors slip off the bone it should be divided with Grün-

wald's punch-forceps. The semi-detached extremity is then surrounded with a nasal snare, carrying a No. 5 piano wire, and cut through (Fig. 286).

It is well not to seize and twist off the anterior extremity, as this might lead to the ripping out of a larger portion than was intended. Besides, it might cause fracture of the base of the remaining piece of the inferior concha, and this might become displaced inwards so as to block the air-way more than ever.

After-treatment. It is well to check the hæmorrhage without the use of plugging. Some antiseptic powder—europhen, xeroform, formidine, aristol, &c.—if lightly insufflated over the wounded area, will assist in the formation of a protective scab. This should not be disturbed for

FIG. 285. NASAL SCISSORS.

some days, during which the nose is made comfortable by some menthol and boric ointment, or a paroleine spray. When the scab begins to break down its removal is assisted by warm alkaline lotions (see p. 619). The stump may require a few applications of nitrate of silver or other silver salt. There is no danger in this operation. Healing, as in other intranasal operations, takes from three to six weeks.

Amputation of the lower margin. Indications. This is not infrequently necessary when there is a general hypertrophy—as in the compensatory hypertrophy of septal sclerosis (Fig. 305)—or when the whole lower and lateral margin is occupied by papillary hypertrophies (Fig. 284).

Operation. The operation can be carried out under the local application of cocaine and adrenalin, but is frequently performed as part of some other operation under general anæsthesia.

The steps have to be varied according to the degree and extent of the hypertrophic tissue requiring removal. When this is principally along the lower border of the concha it can be removed with one cut of a stout pair of nasal scissors (Fig. 285). Under good illumination

a blade is insinuated along the concavity, while the other passes between the convexity and the septum. Care should be taken that the direction of the scissors is parallel to the axis of the concha, and that the cut embraces only that portion of the lower area to be removed. The severed portion should be quickly seized with a pair of punch-forceps and lifted out, or the patient, if only under local anæsthesia, may be requested to blow it forward into a tray. Otherwise it is apt to become obscured in the outpouring of blood, and, if the patient is unconscious, to be sucked backwards out of sight. If, as not infrequently happens, the lower margin remains attached at its posterior extremity, a wire snare is threaded along over it so as to cut this through. When the papillary hypertrophy is more diffuse it is apt to be concealed in the concavity of the concha. From this hiding-place it can be partially dislodged with a probe and then cut off with a snare.

The after-treatment is similar to that for removal of the anterior end.

Removal of the posterior end. **Indications.** The posterior extremity of the inferior concha is very subject to a moriform hypertrophy, and some delicacy and skill are required in removing it.

Operation. The interior of the nose on the affected side should be treated with a weak solution of cocaine and adrenalin. The most disagreeable part of the operation is the introduction of the operator's finger into the post-nasal space. Hence the fauces should be freely sprayed with a 5% solution of cocaine. This will deaden painful sensation, but it will not prevent the discomfort nor the nausea often induced.

It is well to avoid as much as possible the direct application of cocaine or adrenalin to the moriform hypertrophy itself, for it is an extremely vascular growth, and if much contracted it is more difficult to ensnare.

The operation may also be carried out under a general anæsthetic, when one is given for other surgical measures in the nose. In that case it is best to defer the removal of the moriform hypertrophy until the end —practically until the patient is commencing to recover consciousness— on account of the sharp hæmorrhage which is apt to accompany it.

The chief difficulty of the operation lies in the fact that the part to be operated on cannot be kept in view, either directly or indirectly, and that therefore success depends a good deal on delicacy of touch.

A nasal snare—such as that of Blake, Krause, or Badgerow—is threaded with No. 5 piano wire, and a loop left out a little larger than sufficient to grasp the growth. This loop is then bent over smartly towards the side to be operated on, and a slight kink is given to it. The loop is then slightly withdrawn within the barrel, and this again

brings it into a straight line. If now the snare be passed along the floor of the nose until the end of it is opposite the posterior extremity of the concha, and if the looped wire be slightly projected from the barrel, the loop will tend to curve outwards to the side on which it was kinked. In this way it will be felt to surround the moriform growth, which can then be cut off.

It must be confessed that this is not always successful, that there is no means of making sure that the snare is applied to the root of the growth, and that once the bleeding is started posterior rhinoscopy fails

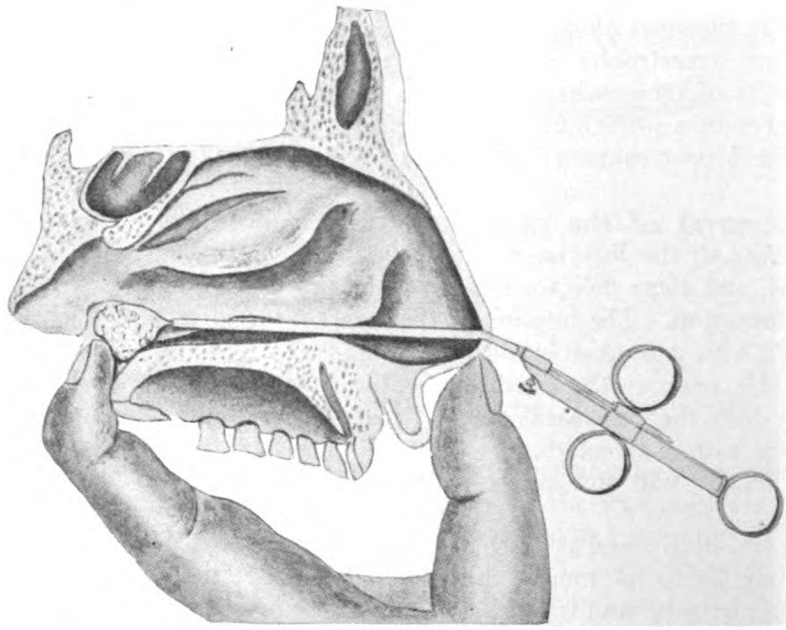

FIG. 286. AMPUTATION OF THE POSTERIOR END OF THE INFERIOR CONCHA.

to reveal if any of it still remains. It is better, therefore, to introduce the purified forefinger of the left hand into the post-nasal space, so as to define the growth and guide the loop of the snare over it. The nail of the same finger then keeps the wire close to the base of the hypertrophy, while the loop is drawn home (Fig. 286). The patient may then be relieved of the discomfort of the operator's finger in his throat, and may be given time to clear away the collected mucus. A little delay is advantageous, as it allows coagulation to take place in the large veins of the moriform growth. Some surgeons recommend that once the growth is strangled the snare should be left *in situ* for 10 or more minutes. This is irksome and unnecessary, and bleeding is seldom excessive

if the snare be not employed for cutting off the hypertrophy, but is used as follows: Once the loop is drawn firmly home so as to embrace the growth tightly, a few minutes' rest is given. Then, steadying the patient's head with the now disengaged left hand, the snare is plucked from the nose with a quick movement. This brings away the mulberry hypertrophy in its grasp, and frequently a strip of mucosa from the lower margin of the concha. No bone is removed in this operation. The bleeding may be very sharp at first, but generally ceases under the usual measures (see p. 614). Occasionally it is extremely troublesome, and as the bleeding surface overhangs the post-nasal space the only local pressure which is available is that of a post-nasal plug.

After-treatment. As secondary hæmorrhage is apt to be met with, the patient should be advised to leave his nose alone, neither blowing nor clearing it, nor using any cleansing measures for 48 hours. After that time he can employ the usual warm alkaline nose lotion. He should be warned against the habit of hawking backwards, as this would tend to a recurrence of the hypertrophy.

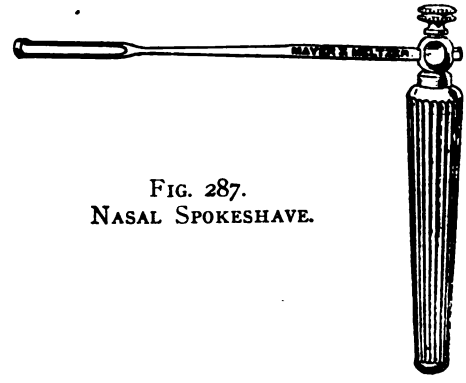

FIG. 287.
NASAL SPOKESHAVE.

Prognosis. Great relief can generally be promised within a few days. There is no danger in the operation. The hæmorrhage may be troublesome, especially in men. The precautions described in the previous chapter are well worth observing (see p. 614).

Complete turbinotomy. Indications. As already remarked, it must be extremely rare for this operation to be required. Papillary hypertrophy chiefly attacks the lower and posterior parts of the concha, and these can be removed as described above, so that if the entrance of the nostril is made free by anterior turbinectomy, there will still be left a sufficient area of functionally active mucosa. If, however, almost the entire inferior concha be degenerated, or if it be replaced by malignant growth, it can be removed in the following way:—

Operation. Anæsthesia may be local or general. If no other operative procedure be required at the same time, the anæsthesia of nitrous oxide gas or chloride of ethyl will be long enough. Owing to the vascularity of the part, adrenalin should be applied for at least 30 minutes beforehand.

Removal of the concha is easily and quickly carried out with Carmalt

Jones's or Moure's spokeshave (Fig. 287). This is introduced, passed as far as the posterior extremity of the concha, and the edge is guided in place with the operator's left forefinger in the post-nasal space. With a sharp pull the spokeshave is then drawn forwards and the detached body can be lifted out with a pair of punch-forceps. Owing to the slope of the attached border it is seldom that the whole of the turbinal is removed. Those who are skilled in the use of this instrument can manipulate it so as to leave a good part of the attached margin of the concha, and the spokeshave can be used instead of the scissors for removal of the inferior margin. But its action is apt to be uncertain, and as it may unexpectedly rip out more than was intended, it is seldom employed nowadays.

After-treatment. After the removal of such a large portion of secreting surface the nasal secretion may dry into adhering crusts and scabs for some weeks—possibly for six or even eight. The scabs should be softened by the use of ointment or oily sprays, and removed by the free use of warm alkaline lotions. The even healing of the granulating surface requires watching; its progress should be inspected from time to time, as the surface may require touching with a weak nitrate of silver solution.

OPERATIONS UPON THE MIDDLE CONCHA

Indications. Amputation of the anterior end may be required for (1) simple hypertrophy, (2) cyst or empyema in the anterior extremity, (3) to gain access to the ostia of the various accessory sinuses, (4) as a first step to uncover the ethmoidal cells, and (5) as a first step in removal of ethmoidal polypi.

Operation. Local anæsthesia with cocaine and adrenalin is sufficient and the operation can be carried out with the patient sitting in the examination chair. It frequently forms part of some other intranasal operation which is performed under a general anæsthetic, but the preliminary application of cocaine and adrenalin should still be carried out (see p. 614). If the pieces of gauze soaked in the cocaine-adrenalin mixture be carefully tucked up on each side of the head of the concha, the part to be removed is generally well exposed. With a pair of Grünwald's punch-forceps (Fig. 281) or Panzer's scissors (Fig. 285), the anterior attachment to the lateral wall is cut through (Fig. 288) so as to free the end, around which a cold wire snare can be passed and the extremity removed (Fig. 289). In cases where it is difficult to introduce the punch-forceps under the attachment of the middle concha the blades may be applied to the lower margin, about half an inch from the anterior ex-

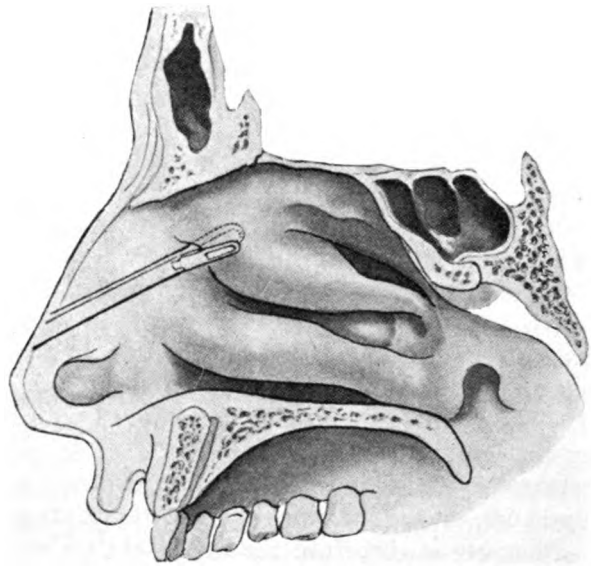

FIG. 288. FIRST STEP IN THE REMOVAL OF THE ANTERIOR END OF THE MIDDLE CONCHA.

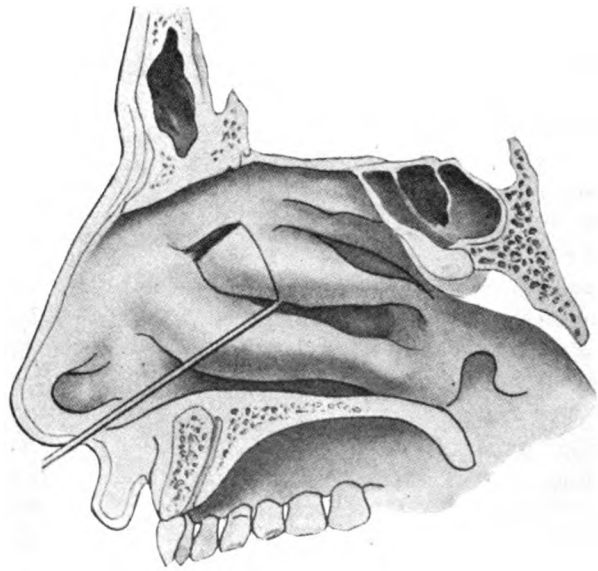

FIG. 289. SECOND STEP IN THE REMOVAL OF THE ANTERIOR END OF THE MIDDLE CONCHA.

tremity so as to bite out a wedge. Into this the loop of the wire snare is inserted and the head of the concha can easily be snared off.

The snare is generally recommended as being safer than the punch-forceps. There is certainly a risk attending any slip in manipulating the latter in this region, more so, indeed, than in the deeper ethmoidal regions, for in the anterior part of the nasal roof the cerebral floor dips down lower than it does posteriorly, and the nasal fossa in the anterior part of the middle meatus is very narrow, so that if the forceps slipped they might impinge on the cribriform plate.

But when the middle concha is softened and broken down by disease it is as safe, and it is certainly more convenient, to take out a wedge from its centre, as directed above, and then with a pair of Grünwald's or Luc's forceps to twist out not only the anterior extremity, but also the posterior half. The latter part can also be removed with a spokeshave, as directed for the inferior concha (see p. 631).

After-treatment. There is not the same tendency to crusting as occurs after operation on the inferior concha. Hæmorrhage is also less troublesome. Plugging is therefore the less likely to be required, and should always be avoided if possible, since it would interfere with drainage from the various accessory sinuses, and this operation is frequently required when their contents are particularly septic. The best plan is to leave the nose severely alone for 48 hours, and then to clear it gradually with the help of warm alkaline lotions.

OPERATIONS FOR THE RESULTS OF SYPHILIS

Sequestrotomy. The discovery of a syphilitic sequestrum always calls for active treatment.

Operation. If the sequestrum be not loose we must wait until it is movable. Its detachment will be expedited by mercurial inunctions or injections, and suitable local cleansing and disinfecting measures. As soon as any movement can be detected in the dead mass we can proceed, under cocaine, to detach it. Various forms of polypus forceps and bone-pliers may be required, and the necrosed bone has to be raised from its bed by a variety of lever and to-and-fro movements. Several sittings may be necessary, but this is inevitable, as any violent measures are soon arrested by hæmorrhage. When the necrosed bone has been mobilized it may be too large for extraction through the nares; such a mass as the greater part of the body of the sphenoid has sometimes necrosed *en bloc*. In such cases the dead bone must be broken up *in situ* and then removed piecemeal through either the anterior or posterior orifices. Very rarely Rouge's operation may be required (see p. 662).

Operations for post-syphilitic adhesions of the velum. So long as there is an adequate passage for nasal respiration it is best to leave any slight degree of stenosis alone. When there is complete atresia, and when mouth-breathing, deafness, or other consequences develop, some effort at relief should be made.

Operation. Under chloroform, and with the hanging head, W. G. Spencer[1] separates the soft palate from its adhesion to the posterior pharyngeal wall, draws it forwards, and fixes it by two silk sutures to the muco-periosteum of the hard palate. Tilley carries out the same principle by threading the soft palate on both sides with strong silver wire and anchoring it to the incisor teeth. The wires cut out in 10 to 14 days, but by this time considerable healing will have taken place over the raw surfaces from which the adhesions had been separated.[2]

After freeing the soft palate, H. B. Robinson prevents it from again uniting by the following method: 'A piece of lead plate is cut the full breadth of the nasal part of the pharynx and bent so that one arm rests on the dorsal surface of the soft palate, and the lower one on the buccal surface, the cut margin being received between the plates and opposed to the bend, and so kept away from the pharyngeal wall. The piece of lead is kept in place by silk threads attached to the four corners, two passing forward through the nostrils and two through the mouth. The lead plate is not removed for a fortnight.[3]

Whatever method is employed to enlarge the stricture, dilatation must be kept up for some time by the frequent passage of the forefinger, a palate hook, or a dilatable bag.

Results. Stenosis of the passage from the nasal part of the pharynx to the oral part of the pharynx, caused by syphilitic adhesions between the soft palate and the posterior pharyngeal wall, is one of the most difficult affections in this neighbourhood to operate on with satisfactory results. The cause of disappointment lies in the low vitality of specific scars and their well-known tendency to contract.

Surgical measures are sometimes required for the damage left by syphilis during the healing process.

The saddle-back deformity of the external nose is best corrected by subcutaneous injection of paraffin.

Perforations in the hard or soft palate may require operation to close them.

[1] *Proc. Laryngol. Soc. London,* vol. v, November, 1897, p. 4.
[2] Ibid., vol. x, March 6, 1903, p. 81.
[3] Ibid., vol. xiv, June, 1907, p. 106.

OPERATIONS FOR TUBERCULOSIS

Tuberculosis only occurs in the nose in the mitigated form of lupus. Surgical interference is frequently called for, generally in the form of curettage or the application of caustics.

The most satisfactory caustic is the galvano-cautery point, applied under cocaine, and at repeated sittings.

Curettage is required in more advanced cases. Chloroform is always required. Not only should all soft and diseased tissue be scraped away with a Volkmann's spoon, but the curettage should be carried on vigorously until a healthy and resistant area has been reached. It is rare for too much tissue to be removed, whereas recurrences are only too frequent.

CHAPTER III

OPERATIONS UPON THE NASAL SEPTUM

OPERATIONS FOR DEFORMITIES

REMOVAL OF SPURS

Indications. A spur or ledge, uncomplicated with deviation of the septum, occasionally requires removal. It will generally be found in the lower meatus, at the junction of the quadrilateral cartilage and ethmoid with the superior maxillary crest and vomer.

Operation. The operation can be carried out painlessly and bloodlessly under cocaine and adrenalin. The galvano-cautery, trephine, and

FIG. 290. CRESSWELL BARBER'S NASAL SAW.

spokeshave should be avoided. An incision is made from behind forwards along the summit of the projection, and the muco-perichondrium is turned upwards and downwards. (For particulars as to reflecting these flaps see p. 645). A straight, fairly stout nasal saw (Fig. 290) is inserted below the projection, and, while the patient's head is steadied with the left hand, the saw is carried inwards and upwards with short, swift movements. During the first of these the cutting edge should be directed obliquely towards the opposite nostril so that the saw gets a good bite into the base of the spur. Otherwise, if simply directed vertically the resistance it meets with is likely to send it obliquely outwards, and the obstruction will be imperfectly removed. This defect will be the more apparent later on, when some heaping up of scar tissue is sure to take place over any trace of projection. In other words, in order to remove a spur flush with its base it is necessary to cut deeper than the base. At the same time it is important to avoid button-holing the septum by cutting into the opposite nostril.

When the spur lies close along the floor of the nose it may be necessary to direct the saw from above downwards. The result is not so satisfactory, and the removal may have to be completed by seizing and

twisting off the semi-detached spur with a pair of polypus forceps, or stripping it forwards with a spokeshave.

After-treatment. The reflected flaps of muco-perichondrium are replaced and maintained in position for 48 hours with plugs of cotton-wool. Subsequently a warm alkaline nasal lotion and a little ointment may be required.

Perforating the septum. It will be seen that if a spur is associated with a convexity of the septum to the same side it will be very difficult to remove the projecting obstruction adequately without cutting into the concave side of the septum, and so producing a perforation. Some surgeons even recommend that this should be done intentionally, and maintain that the resulting perforation seldom gives any trouble. This may be true in some cases, and the result is sometimes fairly good. But we have more completely satisfactory methods at our disposal: the perforation method does not relieve the majority of cases, and it interferes with the subsequent performance of more perfect operation. It can therefore only be approved of when the surgeon has not acquired the technique of the submucous resection operation (see p. 643).

Operation. When it has been decided to produce a perforation it is carried out with the nasal saw, as described for the removal of spurs (see p. 637). The saw is introduced so as to embrace as much as possible of the projection.

After-treatment. The drying and scabbing of discharge along the margin of the perforation is apt to give trouble for some weeks. This inconvenience is the more marked the nearer the perforation approaches to the anterior nares. It must be met by careful and repeated cleansing and lubrication of the nasal chambers. Any scabs should be carefully softened with hydrogen peroxide, lifted off the edge of the perforation, and any underlying ulceration treated with applications of nitrate of silver, argyrol, &c.

OPERATIONS FOR SIMPLE DEVIATION

It is very rare to find a deviation of the nasal septum without some accompanying spur or ledge. It is still more rare to meet with a deviation which is entirely limited to the cartilaginous septum; there is nearly always some bony formation in the deformity, contributed by the nasal spine of the maxilla, the vomer, or the perpendicular plate of the ethmoid, or by all three. Hence the limited field of application for the various operations which have been designed for 'straightening the cartilaginous septum.' In the few cases where the deformity is almost entirely cartilaginous these operations are only partially successful in overcoming its resiliency. They will therefore be only briefly considered.

Gleason-Watson operation. For a thorough performance this operation requires a general anæsthetic. The scheme of the operation is to make a U-shaped incision around the convexity, leaving it attached above. The flap of cartilage is then pushed through the U-shaped opening into the concave side. As its bevelled edge is larger than the button-hole in the septum it will be to some extent prevented from slipping backwards (Fig. 291). This tendency may also be combated by an attempt to snap through the base of the flap of cartilage, and by careful packing of the formerly obstructed nostril. The operation is performed with a nasal saw, carried from below upwards, and maintained carefully in the antero-posterior axis of the septum.

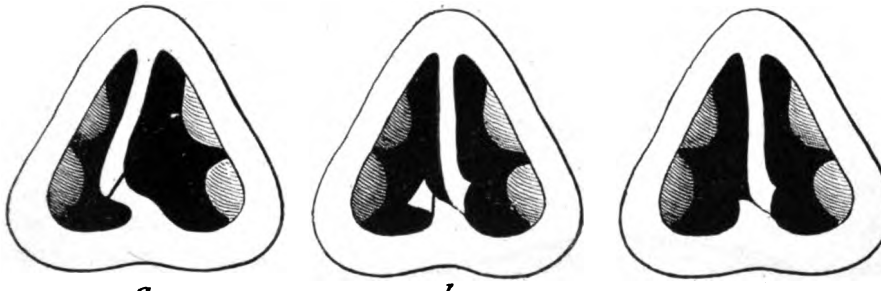

FIG. 291. THE GLEASON-WATSON OPERATION FOR DEFORMITY OF THE SEPTUM. *a* shows the incision made from the stenosed nostril, and below the convexity; *b* represents the septum as pushed into the free nostril; and *c* shows the result after subsequent removal of the spur.

Asch's operation. The resiliency of a deviated cartilaginous septum is more completely overcome by this method of operating. It requires a general anæsthetic.

By means of appropriate cutting scissors (Fig. 292) a cruciform incision is made over the summit of the convexity of the deviation, so that we have four triangular flaps meeting at the point of greatest stenosis. By means of the finger introduced into the obstructed nostril, or suitable septal forceps, these four flaps are snapped across at their bases so as to overcome their tendency to spring back.

Into the formerly obstructed nostril is introduced a Meyer's vulcanite hollow splint (Fig. 279), a Lake's rubber splint (Fig. 293), or a gauze packing. This should be retained for 48 hours. Afterwards it will require daily changing and cleansing, possibly for several weeks. In the opposite nostril a lighter support will serve to keep the ends of the fragments *in situ*.

Moure's operation. According to its author this operation can be

carried out under local anæsthesia, but it is generally advisable to employ some such general anæsthetic as nitrous oxide or chloride of ethyl. By means of suitable scissors one incision is made through the septum

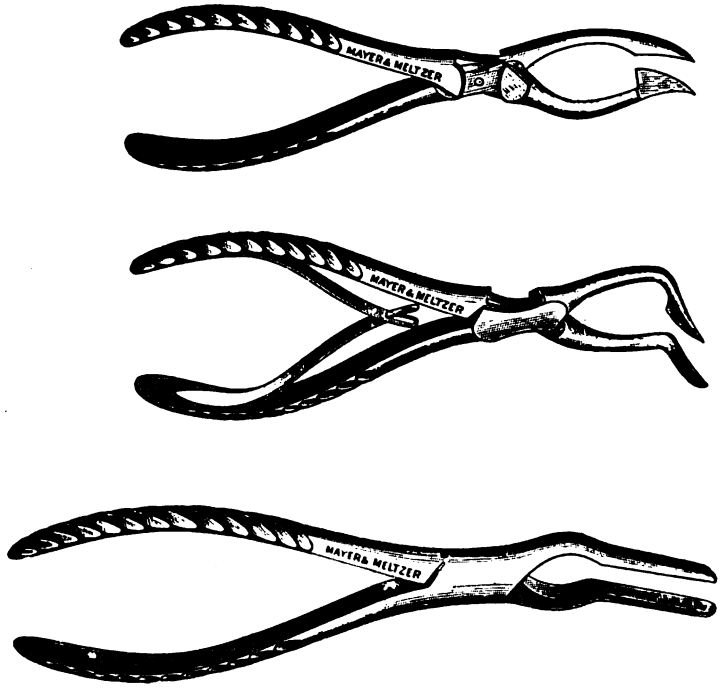

FIG. 292. ASCH'S CUTTING SCISSORS. Employed in the operation upon the septum.

parallel to the bridge of the nose and above the prominence of the deviation, and by another parallel to the floor of the nose the septum is divided below the deviation. This is now only fixed at its anterior and posterior extremities, but has been rendered more movable from side to side. By means of a specially designed dilator and splint the septum can be moulded into a good position, and maintained there until healing takes place.

FIG. 293. LAKE'S RUBBER SPLINT.

The conditions in which any of these operations can prove suitable are rarely met with. In the worst forms of stenosis from septal deformity they are useless. At the best they can never completely remove it. In one of them a perforation is made on purpose, and in the others it not infrequently is produced unintentionally. The objections to

a perforation have been described (see p. 638). Hæmorrhage, shock, and prolonged and painful after-treatment are important drawbacks. A dry scabby condition of the septum may be produced, and the patient may complain more of this than of his previous nasal stenosis; indeed, he may find that the stenosis is unrelieved and that a constant source of irritation has been added to it.

The perforation operation should only be employed when the patient is in circumstances where a complete submucous resection cannot be carried out. The Gleason-Watson operation is unsuitable where the deviation reaches high up. It should be avoided if it is seen that the perforation will have to be brought close forward to the anterior nares.

Another objection is that any of these operations, particularly the production of a perforation, will greatly increase the difficulties and diminish the benefits of the subsequent complementary operations which are only too often required.

Asch's operation is easily carried out, and may be practised by those who have not mastered the technique of submucous resection (see p. 643). Moure's operation is easily and quickly performed, and where a well-marked deviation of the anterior part of the cartilaginous septum is met with, it will give considerable relief.

OPERATION FOR COMBINED BONY AND CARTILAGINOUS DEFORMITY

Submucous Resection (Window operation)

This is the most perfect operation we at present possess for the cure of deformities of the nasal septum. It has largely supplanted those already outlined; it is suitable for the most extreme degree of deformity; and it will secure complete relief to the symptoms produced, whether they consist of stenosis of the air-way, obstruction to discharge, or reflex effects.

The design of the operation is to excise all obstructing cartilage and bone, with any projecting spurs or ledges, while preserving intact the mucous membrane on each side. It has been brought to its present degree of perfection chiefly by the work of Killian and Freer.[1]

Indications. The special indications of this operation would appear to be:—

1. Cases where it is desirable to establish normal nasal respiration and remove mouth-breathing, with its numerous consequences.

2. Correction of the disfigurement caused by the lower end of the quadrilateral cartilage projecting into one nostril.

[1] For bibliography and more detailed description, see StClair Thomson, *Med.-Chir. Trans.*, vol. lxxxix, 1906; *Lancet*, July, 1906; and *Brit. Med. Journ.*, vol. ii, 1906.

3. Cure of headaches or reflex neuroses of nasal origin.
4. The relief and treatment of Eustachian catarrh.
5. Facility for treating nasal polypi and affections of the accessory sinuses.

Objections to the operation. (*a*) That the excision of a large part of the septum may lead to flattening or deformity of the nose. This objection is groundless. A strip of septal cartilage is always left above, beneath the crest of the nose. Falling in of the bridge of the nose could only be consequent on entire removal of this 'bowsprit' of cartilage, or from its destruction through the wound becoming septic. No deformity has occurred in my hands in over 200 operations. On the contrary, the appearance of the nose is generally much improved.

(*b*) That the operation entails greater risks from any subsequent blows on the nose. This objection has been met by the experience of Otto Freer in four cases where severe blows, causing epistaxis and occurring even within a week of operation, did not result in any damage to the fleshy septum, nor to the external appearance of the nose.[1]

(*c*) That the operation is long and tedious. The duration of the operation depends on the nature of the case, the skill of the surgeon, and the difficulties met with—chiefly in the way of hæmorrhage. A simple deviation of the cartilaginous septum can be removed by this method in 10 to 20 minutes. Many beginners are apt to be content with such a partial removal. More time is required in completely removing bony deformities. Many cases take 30 minutes, and none need exceed an hour when once the necessary dexterity has been acquired. More time is taken up if fresh applications of cocaine or adrenalin have to be made, if bleeding be troublesome, and if one of the flaps should be punctured.

(*d*) That the operation requires special skill. This is a real objection to the popularization of the operation. It does not seem probable that it can ever pass out of the hands of those who are kept in daily practice in rhinological technique.[2]

(*e*) That the operation is unsuitable for children. Owing to the small size of the nasal chambers the operation presents greater technical difficulties before the age of sixteen. My own practice formerly was to await this age, and Killian used to advise that children under twelve were not fit subjects. But Freer held that the operation is proper for children at all ages, although with them the deformity tends to recur unless every vestige of it has been removed. Killian has now adopted this view, and

[1] *Annals of Otology, Rhinology, and Laryngology*, June, 1905.

[2] 'As all operators who know it will confess, the Fensterresektion of the septum belongs to the most extremely difficult intranasal operations.' Zarniko. *Die Krankheiten der Nase*, 1905, p. 300.

agrees that the operation may be performed on children even as young as four years of age.[1]

Advantages of the operation. These may be summarized as follows:—

1. A general anæsthetic is not inevitable.
2. Hæmorrhage gives no trouble.
3. Absence of pain and shock.
4. No reaction. The post-operative temperature seldom rises above 99° F.
5. Absence of sepsis, with its possible extension to ears, sinuses, or cranial cavity.
6. No splints are required, and no plugs after the first 48 hours.
7. Rapid healing, without crust formation.
8. No risk of troublesome adhesions.
9. Short after-treatment.
10. Speedy establishment of nasal respiration.
11. Suitability for every variety of deformity of cartilage or bone in the septum which may require treatment.
12. No ciliated epithelium is sacrificed.
13. Accuracy of result can be depended on; the prognosis is, therefore, the more definite.
14. If the external appearance of the nose be altered at all, it is in the way of improvement.

It will be seen that the above advantages cancel most of the drawbacks which were formerly so annoying in nasal surgery.

Contra-indications. 1. Elderly people are so accustomed to their nasal obstruction, and its secondary consequences are generally so fully established, that the benefits would be much less marked than earlier in life.

2. Serious or progressive organic disease. This does not apply to quiescent or arrested tuberculosis.
3. Active syphilis.
4. Lupus.
5. The operation should be postponed if the patient shows any symptoms of influenza, or of acute or infectious catarrh.

Operation. Submucous resection can be completely carried out under local anæsthesia, as described on p. 612. Killian and others secure local anæsthesia by submucous injection of cocaine and adrenalin (see p. 612), but I have found this method alarming to the patient, apt to produce disagreeable palpitation, and not superior to the method of superficial application already described, particularly if sufficient time is

[1] *Beiträge zur Anatomie, &c. des Ohres, der Nase, und des Halses*, Hefte 1–4, 1908.

allowed for the mixture to act, and if a few cocaine crystals are allowed to dissolve over the site of incision some minutes before starting it.

In nervous subjects it is better to administer chloroform, not so much because of any pain they suffer, but because of the mental strain they are apt to feel in watching the various manipulations.



FIG. 294. BAYONET KNIFE.

Position. The operation is best done with the patient horizontal on an operating table, with the head and shoulders well raised. His nose is then almost on a level with the eye of the surgeon, who is armed with a frontal search-light or Clar's mirror (see p. 611), although he can also operate successfully with an ordinary forehead reflector.

The incision. This can be made with a narrow scalpel, but a much shorter instrument mounted on a bayonet handle cutting all round the point will be found more satisfactory (Fig. 294). The incision is made from the side of the convexity, just anterior to it, and generally about half a centimetre behind the junction of the skin and mucous membrane (Fig. 295). It is started high up in the attic of the nose, and carried downwards to the floor. Sometimes it curves a little backwards below, but it is quite unnecessary to convert it into an L-incision by a second cut backwards. The incision, in its whole extent, divides the mucous membrane and cartilage at one cut, but without puncturing or wounding the mucosa of the opposite (concave) side. In doing this the operator's forefinger in the opposite nostril serves as a useful guide (Fig. 296). In those cases where the lower free end of the

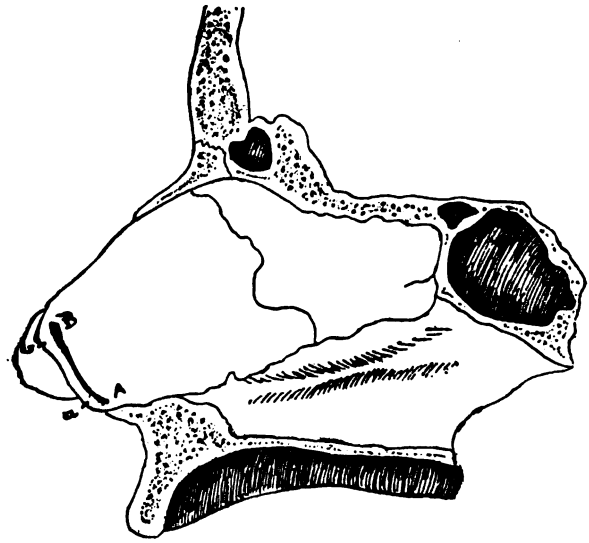

FIG. 295. INCISION FOR SUBMUCOUS RESECTION OF THE SEPTUM. The incision is made, on the convex side, from B to A. If the free end of the quadrilateral cartilage is displaced from behind the cutaneous part of the septum, and presents in one nostril, then the incision is made from *b* to *a*.

quadrilateral cartilage is displaced from behind the cutaneous part of the septum into one nostril—commonly but erroneously described as 'dislocation of the septum'—the incision is made directly over the exposed extremity (Fig. 295).

Raising the convex flap. With a small sharp elevator the muco-perichondrium is raised along the posterior edge of the incision. Great care must be taken not to pass the raspatory between the mucous membrane and the closely adhering perichondrium. The dead white, slightly roughened surface of the bare cartilage should be distinctly visible, and should not be coated with any soft, smooth, or pinkish perichondrium. Once the flap is well started a dull-edged detacher (Fig. 297) will readily undermine it by sweeping movements gradually advancing upwards and backwards. If possible the limits of the convexity should be passed, but it is well not to attempt to go round sharp projections, as it is there that perforations are apt to take place. It is easier at a later stage to strip the flap off crests or spurs.

FIG. 296. MAKING THE INCISION FROM THE CONVEX SIDE IN SUBMUCOUS RESECTION OF THE SEPTUM. The forefinger of the left hand acts as a guard in the opposite nostril.

Incision through the cartilage. If the cartilage has not already been completely cut through at the first incision it is now divided in the same extent as the cut in the muco-perichondrium, great care being taken not to button-hole the mucosa of the concavity.

FIG. 297. DULL-EDGED DETACHER.

Raising the concave flap. The sharp elevator, followed by the dull-edged detacher, is introduced from the incision on the convex side. The muco-perichondrium of the concavity is now raised in the same way and

with the same precautions already used on the convexity, the sharp elevator and then the dull-edged detacher being introduced through the incision in the obstructed orifice, and manœuvred between the cartilage and the concave flap without puncturing the latter (Fig. 298).

Excision of the deviated cartilage. A long Killian's nasal speculum (Fig. 341), or the long Thudichum's speculum I have had made, is now introduced through the obstructed nostril, one blade being inserted on each side of the now denuded septum (Fig. 299). It is easy to see if the

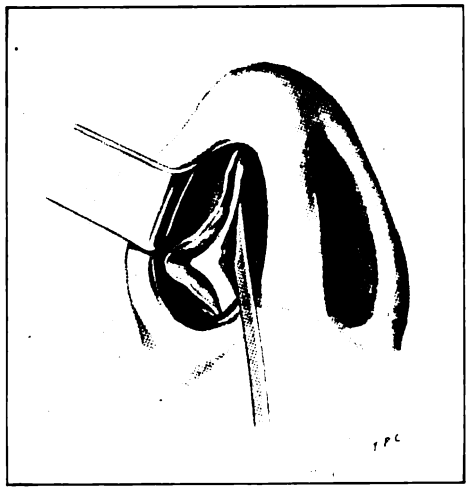

FIG. 298. DENUDATION OF THE SEPTUM IN SUBMUCOUS RESECTION. The muco-perichondrium has been raised from the convex side of the septum, and the cartilage has been cut through (from A to B in Fig. 295). The dull-edged detacher is shown separating the mucous membrane from the concavity of the deflexion.

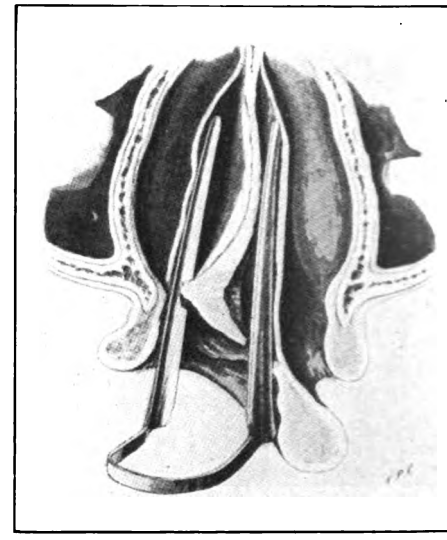

FIG. 299. COMPLETE DENUDATION OF THE DEVIATED SEPTUM. Semi-diagrammatic drawing of a transverse section of the nose, viewed from above. The deviated septum has been divided in front, and its muco-perichondrium has been stripped up on each side. The nasal speculum is introduced through the convex nostril, and a blade is inserted on each side of the septum, between it and its mucous covering.

mucous membrane has been sufficiently stripped off. If not, it can be carried further with a few sweeps of the raspatory. Ballenger's swivel septum knife[1] (Fig. 300) is then placed astride the anterior cut surface of the cartilage, pushed upwards and backwards below the roof of the nose until it comes in contact with the ethmoid, then downwards and

[1] *The Laryngoscope*, vol. xv, June, 1905, No. 5, p. 417.

backwards to the angle between the ethmoid and the vomer, and, finally, pulled forwards along the upper margin of the vomer (Fig. 301). The excised cartilage is thus removed *en bloc,* and may measure an inch by one and a half inches.

The empty pocket between the two separated and flaccid mucous membranes is wiped out and the two fleshy curtains are allowed to fall to-



FIG. 300. BALLENGER'S SWIVEL SEPTUM KNIFE.

gether. With a nasal speculum each nasal chamber is next carefully inspected to see that the thoroughfare is completely restored. As a rule deeper obstructions, formerly invisible, will come into view, and the mucosæ are again separated with a long nasal speculum and more of the septum is shaved off with Ballenger's knife or clipped away with Grünwald's punch-forceps, which also serve to remove portions of the vomer and of the perpendicular plate of the ethmoid.

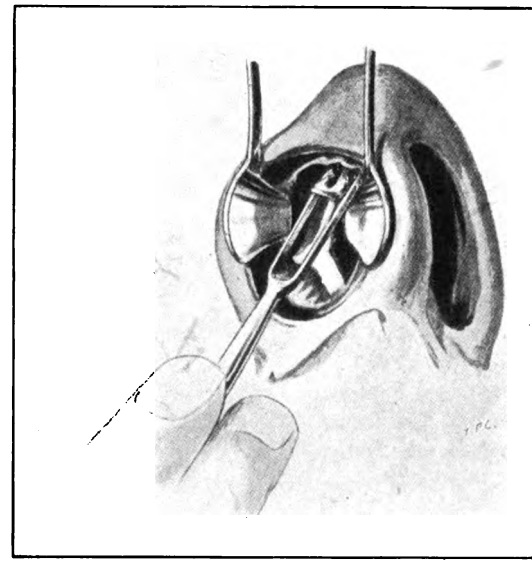

FIG. 301. THE METHOD OF EMPLOYING BALLENGER'S SWIVEL SEPTUM KNIFE. The knife is shown cutting out the cartilaginous deviation.

Excision of bony spurs and ledges. It has been pointed out that it is extremely rare to find a deviation limited entirely to the cartilaginous septum. I have never yet met a case in which it was not desirable to remove some of the bony septum.

When the deformity of the septum is principally composed of bone, the operation is started as already described. It is then easier to lay bare any thickening or deviation of the nasal process of the superior maxilla, or of the chondro-vomerine suture—the usual sites of bony obstructions. When the main mass of deviated cartilage has been cut out with Ballenger's knife free access is obtained from above to these deformities, and

the fleshy muco-perichondrium can be peeled off on each side with much less risk of a tear or puncture. Still, much care is required in working round sharp corners, and, when the spurs lie low, the flaps frequently require to be reflected right down to the floor of the nose. Once well exposed, the maxillary spine is attacked with strong punch-forceps or chisel and hammer, and as pieces of it are prised up they are twisted off with forceps. Once the obstructing maxillary spine is cleared away it is easier to deal with any vomerine deformity.

A great deal of the success of an operation depends on the complete removal of these spurs and ledges, and as they may have to be followed back nearly to the choanæ, this part of the operation may be the most difficult, as it is the most necessary (Figs. 302–4).

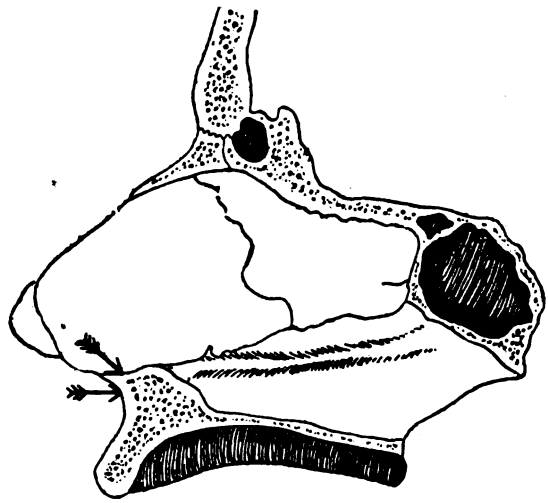

FIG. 302. SUBMUCOUS RESECTION OF THE SEPTUM. The arrows indicate the points where the chisel may be applied when exostosis of the nasal maxillary spine requires removal.

The pocket between the two flaps is again carefully wiped free of blood-clot and chips of bone and cartilage, and when the two mucous membranes are allowed to fall together they should hang perfectly plumb in the middle line and allow of an uninterrupted view through each nasal chamber, right back to the post-nasal space.

For the last two years I have not tried to remove the chips of bone and cartilage. On the contrary, I have not only studiously left them between the two flaps, but I have carefully preserved larger pieces of cartilage in this wise. During the resection, instead of lifting out each portion as it was broken off or detached, I have pushed it upwards or backwards between the flaps until I was satisfied that the obstructing septum had been sufficiently removed. These detached portions were then drawn forwards, divided into smaller portions if necessary, and then, like a piece of mosaic work, were roughly fitted together to form a vertical chondro-osseous plate between the two fleshy flaps. I think it safer to let them lie, till required, between the warm flap and bathed by blood and serum, than to take them outside the body and keep them in

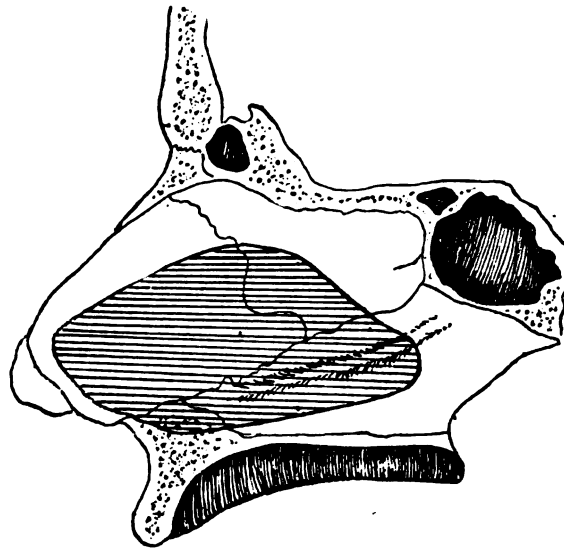

FIG. 303. SUBMUCOUS RESECTION OF THE SEPTUM. The shaded area indicates the extent of the bony and cartilaginous septum usually requiring removal.

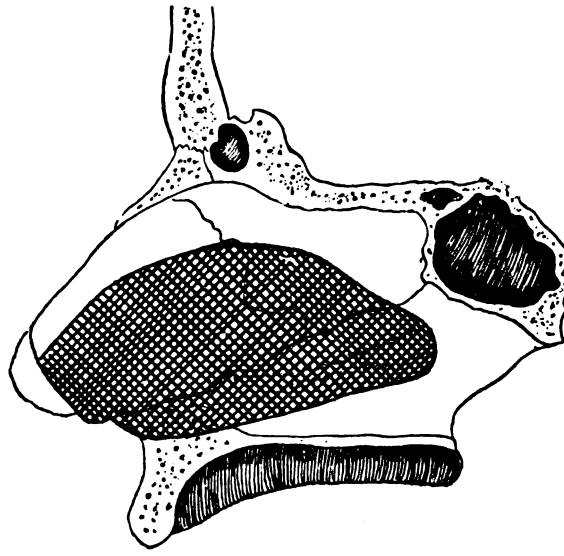

FIG. 304. SUBMUCOUS RESECTION OF THE SEPTUM. The shaded portion indicates the extent of cartilage and bone removed in marked deformity, when the free end of the quadrilateral cartilage projects into one nostril.

warm saline solution. The result is that no trouble has ever arisen; not a single piece of cartilage in any case has sloughed away; healing has been as rapid, and has always resulted in an absolutely firm and rigid septum. It is a great gain to be rid of the 'flapping septum' which one has seen too often in the past.

Stitches. With a small Trélat's needle the incision is closed with one or two catgut stitches.

Dressing. Formerly I plugged the nose with plain sterilized cotton-wool, tightly rolled into pencils and well smeared with sterilized vaseline. Others employ iodoform or bismuth gauze. For some time past I have been well satisfied with rubber sponge—the same material as that used for making rubber toilet sponges. This is cut into pieces about as thick as a pencil, some 3 inches in length, and boiled. These are carefully packed into each nostril. The nose should not be tightly plugged, the object being to keep the two mucous membranes in apposition, but at the same time entirely to occlude nasal respiration.

After-treatment. The patient remains quiet for the rest of the day. Ice may be given to suck and an iced cloth laid across the bridge of the nose. At the end of 48 hours the plugs are removed and will be found to come away very easily. The patient should be warned against blowing his nose, but may suck blood-stained mucus backwards and hawk it out through the mouth. Any discomfort may be soothed by spraying the nostrils with liquid vaseline, or introducing a piece of menthol and boric ointment into each nostril morning and evening.

The relief to the former state of nasal obstruction may at once be appreciable. If there be any local reaction it may take 3 or 4 days for the obstruction to subside. In 7 to 10 days the patient begins to enjoy the benefit of the operation, but it is only after 3 weeks that the full advantage of it is established.

Complementary operations. As a rule the formerly patent nostril is found after this operation to be the more obstructed of the two. The reason of this is readily explained by a reference to Fig. 305. The now redundant hypertrophy in the formerly good nasal chamber is removed—according to its degree and extent—by one of the methods described on p. 627.

From long disuse marked alar collapse may interfere with the good results of the operation.

Difficulties. *Insufficient illumination* is a difficulty that can easily be provided against by using a frontal photophore or Clar's mirror (see p. 611).

Hæmorrhage presents no difficulty if patients are prepared as directed (see p. 614), unless one happens unexpectedly on a patient with a hæmo-

philic tendency. In one such case I had no trouble at the time of operation, but bleeding gave great annoyance for a fortnight afterwards.

The incision I have described has always proved sufficient. In some cases this straight incision is unintentionally converted into an **L**-shaped one, when the flap is torn over a sharp low-lying spur. Beginners may find it easier to start with an **L**-shaped incision, but it is unnecessary and does not leave so small and clean a wound.

The perichondrium should be raised with great care, for it is more easy than one would think to leave it adhering to the septum, while separating only the mucous membrane.

Previous operations always increase the difficulties of the proceeding. The old-fashioned ' shaving off ' of spurs often removed the entire thickness of the cartilage at one part, without perforating the concave mucosa. The submucous resection (window operation) is not infrequently not

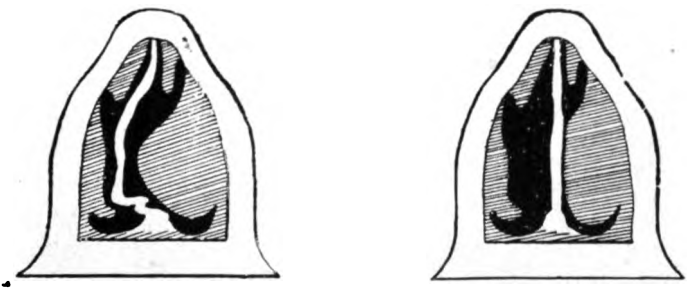

FIG. 305. SEMI-DIAGRAMMATIC TRANSVERSE SECTION OF THE NOSE. Shows the compensatory hypertrophy of the inferior concha in the unobstructed nostril. Part of this frequently requires removal after the septum has been straightened.

carried far enough. In either of these circumstances we are confronted with the great difficulty of trying to separate the two muco-perichondria —now closely united to one another.

OPERATION FOR PERFORATION OF THE NASAL SEPTUM

When a perforation of the nasal septum is situated at some distance within the nasal orifice it seldom gives any trouble. A perforation may also be situated close to the anterior openings without even making its presence known. But in some cases—no matter what the original cause of the perforation—constant annoyance is given to the patient by the crusting and bleeding which take place along its margin. When these crusts have been carefully removed inspection will show that the cause of the trouble is the projecting free edge of the cartilage which prevents the edges of mucous membrane from each nostril from closing over it.

When this circular edge is healed over smoothly, secretions cease to adhere to it, and the patient is not troubled by the annoying crust formation.

This desirable condition can be brought about in crusting perforations by means of the following operation designed by Goldstein.[1] After preparation with cocaine and adrenalin (see p. 612), the muco-perichondrium is reflected on each side along the whole circumference of the perforation for a distance of about a quarter of an inch from the free margin. Over the greater part of the circumference this can be done with Freer's sharp elevator, or with the small sharp elevator employed

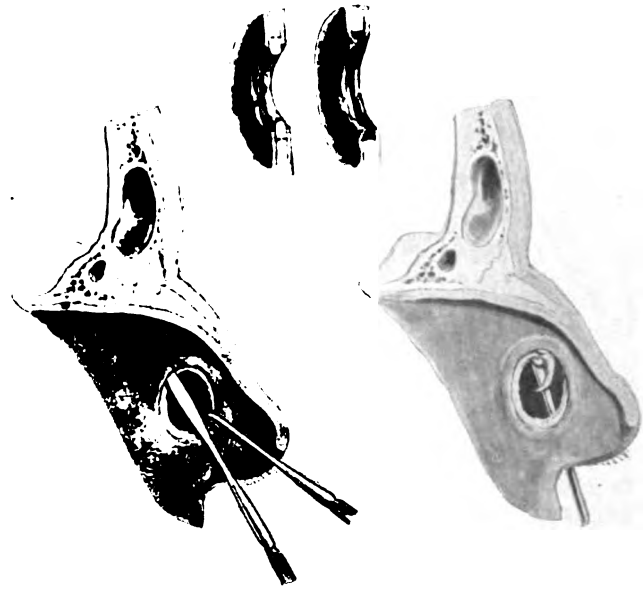

FIG. 306. OPERATION FOR PERFORATION OF THE SEPTUM. The muco-perichondrium is reflected for some distance round the opening so as to allow of the projecting rim of cartilage being removed. The exposed edge is then covered over by the mucous surfaces falling together.

in submucous resection of the septum. In dissecting the anterior part of the circumference the same kind of elevator can be used, but with the operating edge bent forward at an acute angle (Fig. 306). A slit in the elevated mucous membrane, posterior to the perforation, will relieve tension. With a Ballenger's single-tine swivel septum knife a rim of cartilage is then cut away around the perforation, so that the two mucous surfaces from opposite nostrils can come in contact and overlap the circular

[1] *The Laryngoscope*, 1906, xvi, p. 879.

edge of cartilage. This smooth surface will prevent any further sticking and crusting of discharge. It is kept *in situ* for 48 hours by vaselined cotton-wool plugs, similar to those used in the submucous resection of the septum (p. 648).

OPERATION FOR ABSCESS

A free incision is made into it, under cocaine or nitrous oxide anæsthesia. A horizontal cut should extend right across the swelling, and as low in it as possible, to prevent the pocketing of pus. It is sufficient to make it on one side, as the pus from the other side can be pressed across through the defect in the cartilage. Any loose fragments of cartilage should be probed for and removed. The lips of the incision are kept apart by loosely tucking in a small piece of ribbon gauze. This promotes drainage of the lower part, and is changed daily. Afterwards healing takes place under simple cleansing measures.

OPERATION FOR HÆMATOMA

If the hæmatoma be small and not in a suppurating nose, evaporating lotions are applied externally and the swelling is left alone, being carefully inspected daily for early symptoms of suppuration. If the swelling be large and tense, it is safer to incise it freely as described above for abscess of the septum.

CHAPTER IV

OPERATIONS FOR REMOVAL OF NASAL GROWTHS THROUGH THE NOSTRILS: OPERATIONS FOR OBTAINING DIRECT ACCESS TO THE NASAL CAVITIES AND NASO-PHARYNX

OPERATIONS FOR REMOVAL OF NASAL GROWTHS THROUGH THE NOSTRILS

REMOVAL BY SNARE

Indications. Operation with the snare is indicated in cases of simple mucous polypi, if only a few polypi are present, and no sinus suppuration is suspected. It is a suitable method for the removal of papilloma, fibroma, and bleeding polypus of the septum. The snare is also

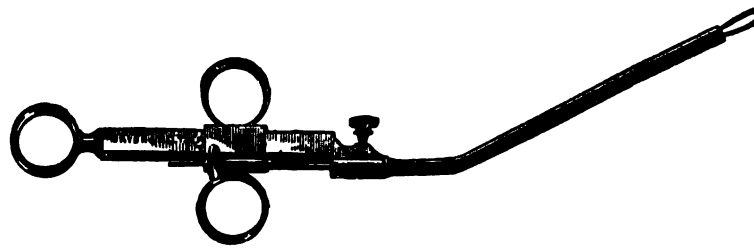

FIG. 307. NASAL SNARE.

serviceable in the removal of enchondroma, osteoma, and growths, if of limited size, after they have been detached from their bases or broken up with a chisel or bone-forceps.

Instruments. The surgeon will employ the pattern of snare to which he is accustomed. The simpler models, such as those of Krause or some modification of Blake's instrument, such as that of Badgerow, when threaded with No. 5 piano-wire will be found sufficient in most cases (Fig. 307). For tougher growths, or those with a thicker pedicle, the snare of Lack can be recommended. It is threaded with heavier wire, and by a screw arranged in the handle the loop can be slowly and steadily contracted.

Operation. The nose is carefully prepared with cocaine and adrenalin (see p. 612), remembering that any growth or polypus is itself

insensitive. The anterior part of the nasal cavity, and particularly the septum, should be thoroughly anæsthetized.

Under good illumination the snare is introduced with the loop vertical, and passed alongside the growth,—between it and the septum or to the outer side, as space permits. It is then swept round a half-circle, so as to bring any tumour within the loop, and by a to-and-fro movement the snare is worked upwards towards its base. The attachment of the ordinary mucous polypus is generally in the region of the middle meatus. The wire loop is thus threaded on to the growth or polypus. The loop is now steadily tightened until it is felt that the pedicle is grasped,—it is seldom visible. By a quick movement of avulsion the tumour is then torn from its attachment. This will bring away some of the œdematous tissue on the distal side of the loop, and there will be less tendency to recurrence than if the root were simply cut across. With the removal of a first polypus others come into view and they must be treated in the same manner. The number which can be removed at one sitting will depend on how well the patient is able to bear the manipulations and how much bleeding there is. If both nostrils be affected it is well to treat them on alternate weeks.

When the growth slips, or is pushed backwards, it can be brought forward into the field of operation by asking the patient to blow down the nose, with the opposite nostril closed. Or the presenting part of a polypus may be seized with a pair of toothed catch-forceps and the wire loop slipped over this.

If the growth be hanging backwards, and presents in the post-nasal space, as it often does when it originates from the mucosa of the maxillary antrum, it may be necessary for the surgeon to introduce his left forefinger behind the palate,—as described on p. 630 (compare Fig. 286),—so as to steady the growth and at the same time slip the wire loop around it. If there be no space for the latter manipulation, the left forefinger is used to steady the mass while a pair of polypus forceps is guided along the floor of the nose until the growth can be seized between the blades so as to tear it from its attachment and pull it out through the anterior nares.

After-treatment. The bleeding will generally cease spontaneously, assisted by cold ablutions to the face, or pinching the end of the nose until a clot forms (see p. 614). If bleeding persists, a piece of gauze, moistened with peroxide of hydrogen, should be packed in lightly and removed as soon as the patient can lie down quietly. It is best to avoid the use of any plug. It was to plugging that Luc attributed the loss of a patient from meningitis consequent on the removal of a polypus.[1]

[1] *Revue hebd. de Laryn.*, 1903, xxiv, Nr. 46, November 14, p. 597.

If the entrance to the nose be tender, it may be smeared with a little menthol and boric ointment; ice-cold cloths may be kept across the bridge of the nose; and pain or sensitiveness can be relieved by a few doses of phenacetin or some similar anti-neuralgic.

Insufflations of antiseptic power are useless, and the nasal cavity should be left alone for 24 or 48 hours. A nose lotion should then be used two or three times a day, until the local condition is again inspected at the end of a week.

Any attempt to destroy the roots of polypi by the galvano-cautery is useless and dangerous.

REMOVAL BY FORCEPS AND CURETTES

Indications. This operation is indicated in all cases of recurring polypi and extensive caries of the ethmoid, but the plan of operation is also suitable for the removal of some cases of papilloma, fibroma, enchondroma, or osteoma.

It can also be employed in certain cases of malignant disease in the nose. When the growth appears to be limited to the nasal fossæ, and particularly in cases of sarcoma, the above operation may be indicated. Even when glands are present this may still be the preferable operation, as glands can be removed at a separate sitting.

Possibly a better method of deciding the case of malignant intra-nasal disease suitable for this operation will be founded on the discovery of the original attachment of the growth. If located towards the front of the nose in the anterior part of the middle meatus, removal can be carried out on the lines described.

Contra-indications. If there be any cerebral symptoms suggesting that intracranial inflammation has taken place already, the patient should be carefully examined before operation is embarked on. It is unsuitable for debilitated and elderly subjects. In patients over 60 with recurrent polypi it is wiser to secure relief by a series of small operations under cocaine.

Many neoplasms and inflammatory hypertrophies, such as mucous polypi, can be removed satisfactorily *per vias naturales* by the method to be described. Naturally the details will vary with the situation and extent of the disease to be removed. The following description applies particularly to growths or hypertrophies springing from the ethmoidal region:—

Operation under cocaine. The nose is carefully prepared with adrenalin and cocaine, the strips of moistened ribbon gauze being care-

fully tucked in between the septum and the ethmoidal region, as well as between this latter and the outer wall. The inferior concha and the front of the nasal cavity should be similarly prepared, so as to diminish vascularity, retract the healthy tissue, and thus increase the space for operating in, while lessening the risk of wounding the septum and so causing adhesions. At least one hour should be given for the solution to act. The operation is done with the patient sitting upright in the ordinary examination chair, with the body craned forward somewhat, and the head supported and held in focus by an assistant. Ready to the surgeon's hand should be some lengths—about a yard—of 1-inch to 2-inch ribbon gauze, and a vessel of warm sterilized water into

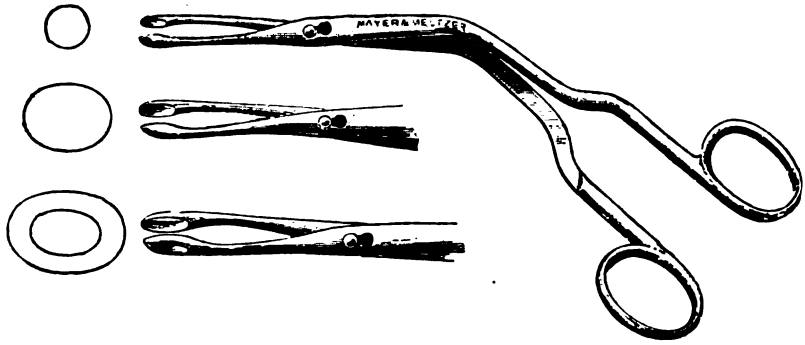

FIG. 308. LUC'S NASAL FORCEPS.

which it is easy to shake off the growths as they are removed with the forceps.

If the middle concha has not already been removed it may have to be amputated, as described on p. 632. In many cases of ethmoidal caries it is easily removed with nasal forceps.

The instrument I recommend is Luc's forceps[1] (Fig. 308), supplemented by Grünwald's punch-forceps (Fig. 281). The former are introduced vertically, so that one blade passes between the ethmoid and the septum and the other passes under cover of the middle concha. By insinuating them carefully, and gradually working them upwards and outwards, a large mass of tissue or carious ethmoid can be grasped, twisted off, and shaken from the forceps into the vessel of water. Before any marked flow of blood has taken place it will be possible to make a second or third introduction of the forceps, and seize the successive masses of growth which come into view. When the bleeding obscures the field of operation one of the strips of gauze can be picked up quickly

[1] *La Tribune Médicale*, 1905.

in the forceps and used for plugging that side of the nose, while a similar operation is carried out in the opposite nasal chamber, if it is affected.

Hæmorrhage may require the plug being left *in situ* for a few minutes, so as to get a clear view of the depths of the nose. This is better secured if the ends of the gauze strips are first soaked in either adrenalin or a 10% solution of hydrogen peroxide. In this way the main mass of the ethmoid can be completely cleared away, the posterior ethmoidal cells opened up, and the front wall of the sphenoidal sinus broken down. Not infrequently the surgeon finds afterwards that this latter cavity has been quite inadvertently, though successfully, opened.

Operation under general anæsthesia. Under a general anæsthetic this operation can be even more satisfactorily carried out, but the surgeon has to keep well in view the anatomical relations of the parts, and the altered relationship to the horizontal position compared with what he is more accustomed to with the patient sitting in the examination chair. When chloroform is employed the interior of the nose is prepared in the same way beforehand with adrenalin and cocaine; the patient is placed horizontal on an operating table with his head and shoulders slightly raised; the post-nasal space is plugged with a sponge (see p. 616); and the tongue is drawn forward with a clip (Fig. 309) so that the administration of the anæsthetic through the mouth is quite uninterrupted. This method allows the surgeon to operate deliberately, generally with the hæmorrhage under easy control, the field of operation well illuminated, and no anxiety in regard to the anæsthetic.

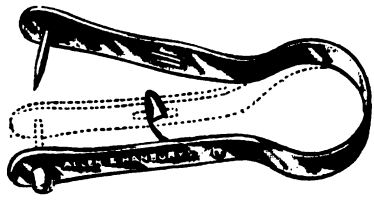

FIG. 309. TONGUE CLIP. Keeps the tongue drawn forwards to allow of general anæsthesia, when the post-nasal space is plugged..

The removal of polypoid ethmoid can thus be completely carried out. With this method I have removed at one sitting a mass of diseased ethmoid which weighed four ounces.[1] It also permits the introduction of the operator's little finger to some distance, so as to detect polypoid or carious surfaces.

With a ring-knife any irregular spicules or projections can be smoothed down. The ring-knife—or a Volkmann's spoon—is carefully introduced behind a mass of growth, and then pulled briskly out through the nose while hugging its outer wall. The nasal roof should be diligently respected.

When the operation has been completed the post-nasal plug is removed, and it is well to pass the forefinger of the left hand well up into

[1] *Proc. Laryn. Soc. Lond.*, 1907, xiv, p. 106.

the posterior choanæ to detect and push forwards any masses of growth which may have been driven backwards.

Hæmorrhage generally ceases with the usual remedies (see p. 615). It is better to avoid all plugs.

Dangers and complications. This operation in careless or inexperienced hands is not free from risks. The chief danger is from injury to the cribriform plate, as any damage in this area, occurring in the septic conditions which generally call for operation, is generally followed by fatal meningitis.

In addition to the usual precautions, particular attention should be paid while manœuvring in the anterior part of the space between the septum and the outer nasal wall. Here the punch-forceps are not directed backwards against the main mass of the sphenoid, but, as the head has to be extended in order to approach the anterior area, they follow an obliquely upward direction which brings them into dangerous proximity with the floor of the cranial fossa—which dips down lower in front than it does posteriorly. Great care, therefore, is taken to avoid any thrusting or boring movements with the forceps. They are first made to press outwards as much as possible the opposing walls of this narrow region, so that polypoid masses can fall between the blades under good inspection.

Occasionally the lamina papyracea (os planum) is perforated, resulting in emphysema of the eyelids or an ecchymosis like a 'black eye.' An orbital abscess may follow (Lack).

METHODS OF OBTAINING DIRECT ACCESS TO THE NASAL CAVITIES AND THE NASAL PART OF THE PHARYNX

LATERAL RHINOTOMY, OR MOURE'S OPERATION

Direct inspection and treatment of the deeper regions of the nose, the naso-pharynx, the ethmoidal labyrinth, and the neighbouring area of the maxillary sinus, is well secured by the following operation, which has been fully described by Moure of Bordeaux.[1]

Indications. This operation is particularly suitable for malignant growths originating in the upper or inner walls of the maxillary sinus, the ethmoidal labyrinth, the deeper regions of the nose, the nasal part of the pharynx, or the sphenoid. It might be required for very vascular naso-pharyngeal fibromata with extensive prolongations. It is very suitable for necrosis—generally syphilitic—of the sphenoid when threatening the base of the brain.

[1] Moure, *Revue hebdomadaire de Laryngologie*, October 4, 1902; Duverger, ibid., September 2, 1905.

For malignant growths in the regions mentioned, this route is particularly suitable, if, of course, the limitation of the growth and the absence of secondary infection justify intervention. The large space formed by throwing the nose and maxillary sinus into one cavity gives a freer field than removal of the maxilla, without the disfigurement and tendency to recurrence so apt to be associated with this latter operation, since it seldom includes removal of the ethmoid, which is the usual seat of origin of the disease. In Moure's operation the functions of the eye, and of the nerves and muscles of the face, are not interfered with, nor are there those difficulties with phonation and deglutition which are left by removal of the maxilla.

FIG. 310. INCISIONS FOR LATERAL RHINOTOMY (MOURE'S OPERATION).

The interior of the nose is prepared with adrenalin and cocaine (see p. 612), chloroform is administered, and a sponge is packed into the naso-pharynx (see p. 616).

Operation. An incision is made from the medial extremity of the eyebrow, along the side of the nose, until it enters the lower margin of the nasal orifice. A second incision, starting from the same spot above, is next carried round the lower margin of the orbit and outwards as far as the zygomatic eminence (Fig. 310).

The lobule of the nose is then detached, so that the fleshy parts of the nose can be thrown over to the opposite side, while a triangular flap is turned downwards and outwards. With a raspatory the nasal process of the frontal bone, the nasal bone, the frontal process of the maxilla, and the canine fossa are next exposed. The lacrimal sac is carefully defined and retracted. A chisel is first driven through the maxilla, close to its junction with the zygomatic (malar) bone, but avoiding the infra-orbital nerve, and the section is carried downwards across the canine fossa until it reaches the alveolar border (Fig. 311). From the lower extremity of this incision—which of course enters the maxillary sinus—the bone which separates it from the piriform fossa is broken

through with stout forceps. In this way the nasal wall of the maxillary sinus is detached close to the floor of the nose, and can be removed together with the inferior concha. The nasal bone itself is next removed, together with part of the lacrimal bone and the nasal process of the frontal. Finally the middle concha and lateral mass of the ethmoid are removed with punch-forceps (Grünwald's or Luc's), Volkmann's sharp spoons, or a ring-knife.

A gouge, or Killian's eye protector (Fig. 337), is then slipped inwards and downwards at the upper part of this opening until it comes in

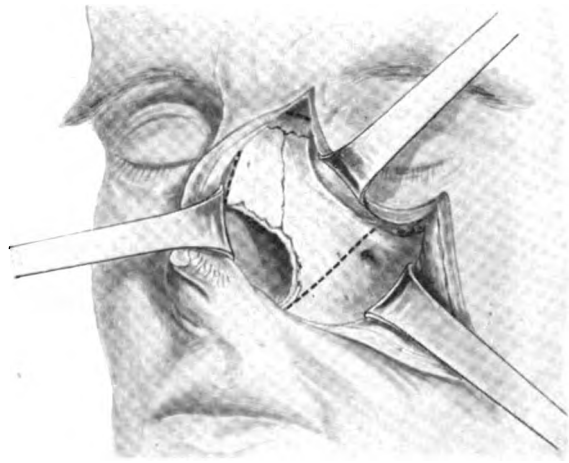

FIG. 311. THE AREA OF BONE REMOVED IN LATERAL RHINOTOMY. The flaps have been retracted, and the dotted lines show where the bones are chiselled through.

contact with the body of the sphenoid. An assistant holds it closely parallel to the cribriform plate, where it acts as a protector. With a large sharp spoon, acting from above downwards and forwards, the ethmoidal labyrinth can be cleared away with any tumour which may have infiltrated it. The lamina papyracea, if not already destroyed, can be removed, so as to obtain access to the orbit. Direct approach is given to the sphenoidal sinus. The septum can be readily resected, but an endeavour should always be made to preserve a strip of cartilage under the bridge of the nose to prevent any external deformity (see p. 649).

It is needless to say that great care must be taken while working close to the cribriform plate.

A malignant tumour can then be removed with forceps, sharp spoons, and the fingers, any prolongations being followed into the nasal part of the pharynx, the maxillary sinus, the sphenoidal sinus, the lateral mass of the ethmoid, or even into the pterygo-maxillary fossa. Success largely depends on the care with which this curettage is carried out. It may be followed by the application of caustics or Paquelin's cautery.

Bleeding is generally abundant at first. It can be controlled with tampons and the use of hydrogen peroxide. When the whole of the

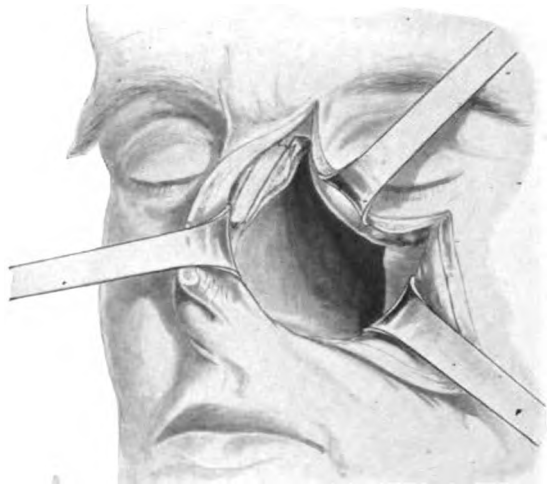

FIG. 312. LATERAL RHINOTOMY. The side of the nose has been removed, and direct access obtained to the upper and deeper nasal regions.

malignant growth has been removed, hæmorrhage generally stops spontaneously. Firm packing of the wound is therefore unnecessary and is best avoided. The large cavity is filled with one long strip of 1-inch ribbon gauze, which is left projecting from the nostril, and the skin incisions are carefully brought together with silkworm-gut sutures. Healing takes place by first intention. There may be a little flattening of the side of the nose, but there is no disfigurement, and a few months afterwards it is difficult to detect any trace of the operation. The strip of gauze is removed in 24 to 48 hours, and simple intranasal cleansing measures are then instituted (see p. 619).

ROUGE'S OPERATION (SUBLABIAL RHINOTOMY)

No special instruments are required for this operation. Full illumination—with a Clar's mirror or frontal search-light (see p. 611)—is particularly necessary.

In addition to the usual preparations, the mouth, teeth, and gums should be purified as much as possible beforehand.

General anæsthesia, preferably with chloroform, is required.

Indications. With the progress of rhinology the occasions for invading the nasal chambers otherwise than by the natural orifices have steadily diminished. Rouge's operation was formerly employed in dealing with deformities of the septum, in the treatment of ozæna, in lupus of the nose, for the removal of simple mucous polypi, in operations on naso-pharyngeal fibromata, or as a simple method of exploration. In all these circumstances it is now uncalled for, as we are possessed of simpler, safer, and more effective methods.

In more modern times it has been advocated as a route of approach to the accessory cavities of the nose by some authors, but this proposition has not met with general support.

The chief indications for Rouge's operation are as follows:—

1. Very large sequestra. The majority of syphilitic sequestra can be removed through the natural orifice. In some cases they can be broken up after being mobilized and then removed through the nostrils. If still impossible of extraction Rouge's operation is indicated.

2. Osteomata are sometimes too large to be extracted through the natural orifice, and as they are much too hard to break up *in situ,* this operation is clearly indicated.

3. Malignant growths.

Operation. Standing behind the head of the patient, an assistant seizes the extremities of the upper lip between the forefinger and thumb of each hand, so as to turn it up against the nostrils and present its mucous surface. A small packet of loose gauze is placed at each corner of the mouth, to be handy for stanching any bleeding. An incision is then made across the gum, a little below the gingivo-labial fold, from the first upper molar on one side to the other (Fig. 313). This is carried right down to the bone.

With a raspatory the soft parts can be easily and rapidly separated up, so as to bring the orifice of each nasal chamber into view. With a pair of scissors curved on the flat the cartilage of the septum is next detached from the nasal maxillary spine, or the latter can be detached with a chisel and hammer (Fig. 314). The assistant is now able to pull the everted lip with the fleshy parts of the nose further up on to the

face, fully exposing the piriform orifice of the nasal chambers, with part of the anterior wall of the maxilla exposed on each side.

The conditions met with are then dealt with as required. Hæmorrhage gives little trouble, and can generally be checked by pressure with strips of gauze, possibly supplemented by the use of peroxide of

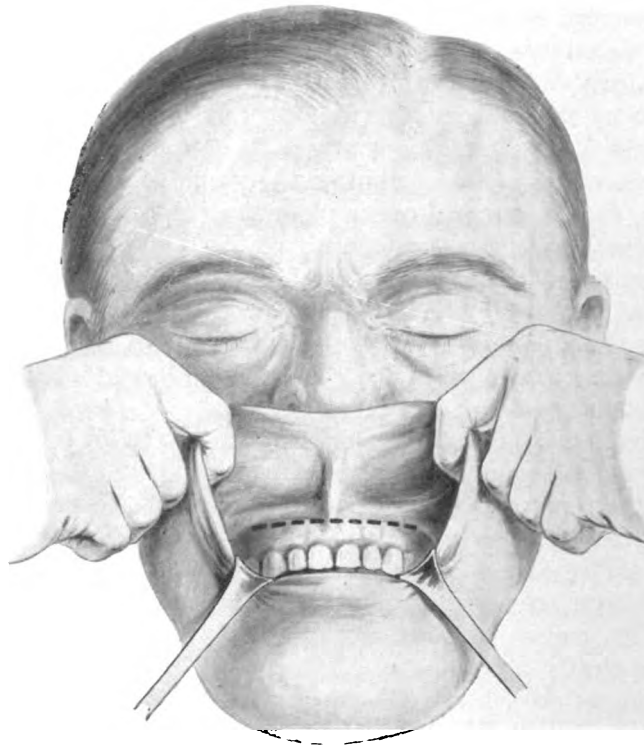

FIG. 313. ROUGE'S OPERATION. *First stage.* The upper lip is everted and retracted by an assistant standing behind the patient's head. The dotted line indicates the line of incision.

hydrogen. When the operation has been completed the everted lip is turned down, and falls into place, where it can be secured by a few catgut sutures.

After-treatment. Two pads of cotton-wool over the upper lip, to right and left of the nasal openings, will give relief and secure healing of the wound by first intention. The mouth should be kept as clean as possible, and cleansing measures to the nasal chambers will be required in proportion to the amount of destruction of its self-cleansing mucous membrane.

Advantages. This operation has several advantages:—

(*a*) It is not difficult of execution, and can be carried out with a scalpel and a raspatory.

(*b*) It gives a free access to the floor of the nose and the anterior part of the nasal fossæ. The vestibule, the natural orifice of the nose, only measures 20 millimetres by 7 to 8 millimetres. Rouge's operation ex-

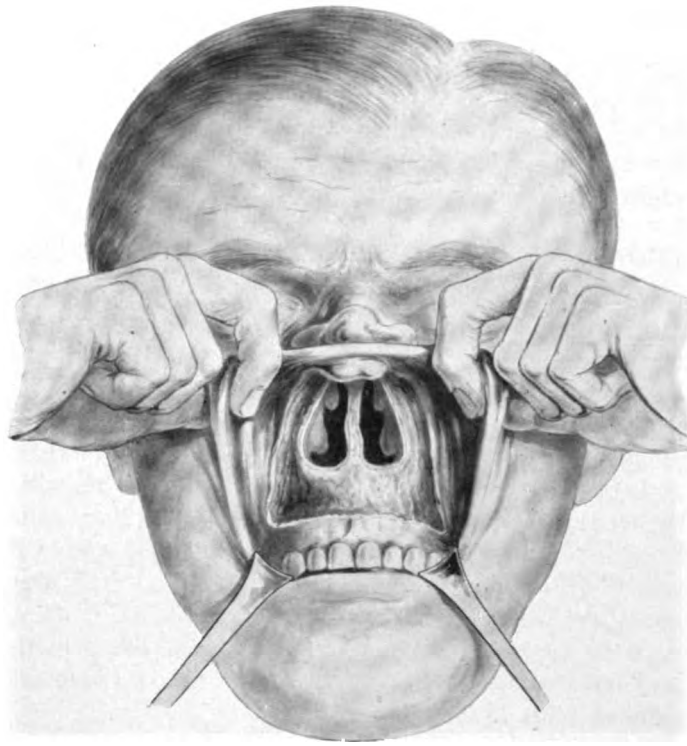

FIG. 314. ROUGE'S OPERATION. *Second stage.* The soft parts are retracted.

poses an orifice measuring 3½ centimetres by 2 centimetres. The posterior margin of the septum, instead of being 8 centimetres distant from the outside, is now brought within a reach of 5 centimetres. The floor of the nose lies on a lower level than that of the vestibular entrance, and is wider some distance in than it is at the orifice. By means of this operation the whole floor comes into clear view, and the exit from the nasal chambers becomes the widest part of the nose.

(*c*) The bones of the face are not interfered with, and the amount of traumatism is slight.

(*d*) Bleeding, which is so apt to be troublesome in operations through the skin of the face, is less and is easily controlled.

(*e*) The patient can be assured that there will not only be no disfigurement, but not even the slightest scar on the face.

(*f*) The operation can be repeated without any disfiguring scars. In operations upon the nose through the face the cicatrix becomes more marked with each intervention.

COMBINATION OF MOURE'S AND ROUGE'S OPERATIONS

The two methods above described can be combined if necessary. This would be called for particularly in growths so large that they could not be attacked through the narrow vestibule of the nose, and for those in which the attachment is evidently in the ethmoidal region. This combination might be called for in any large innocent or malignant growth.

EXTENSION OF ROUGE'S OPERATION TO ALLOW OF ACCESS TO THE MAXILLARY ANTRUM

When the growth involves both the nasal cavity and the maxillary sinus Rouge's operation can be extended so as to form part of the Caldwell-Luc operation (see p. 672).

The latter operation is modified as suggested by Denker (Fig. 327), i.e. the opening through the canine fossa is extended forwards until the nasal cavity is opened through the piriform opening. This will give free access to the large cavity formed by throwing the maxillary sinus and the nasal chamber on the same side into one easily inspected space (Fig. 327). Hæmorrhage gives no cause for anxiety, there is no disfigurement, the original root of the implantation can be eradicated, and, if necessary, the operation can be repeated, without difficulty. If the growth extends upwards and inwards to the ethmoidal region this infra-labial opening can be combined with Moure's operation.

Indications. This operation is suitable for any form of growth invading both the maxillary sinus and nasal cavities, and is therefore generally called for in malignant growths.

OTHER METHODS

The other methods for obtaining access to the nasal cavity through the face—described as the methods of Hippocrates, Syme, Dupuytren, Langenbeck, Lawrence, Ollier, &c.—are now only of historical interest. They all leave a scar on the face; bleeding is troublesome; they do not give a greatly enlarged field; and most of them do not bring the seat of disease any closer. With the advances made by rhinology the necessity for intervention through the face has become more infrequent.

CHAPTER V

OPERATIONS UPON THE ACCESSORY NASAL SINUSES

OPERATIONS UPON THE MAXILLARY SINUS

CATHETERIZING THE MAXILLARY SINUS

It is rarely possible to enter the maxillary sinus through its natural ostium. The attempt may be made after the local use of cocaine and adrenalin (Fig. 315).

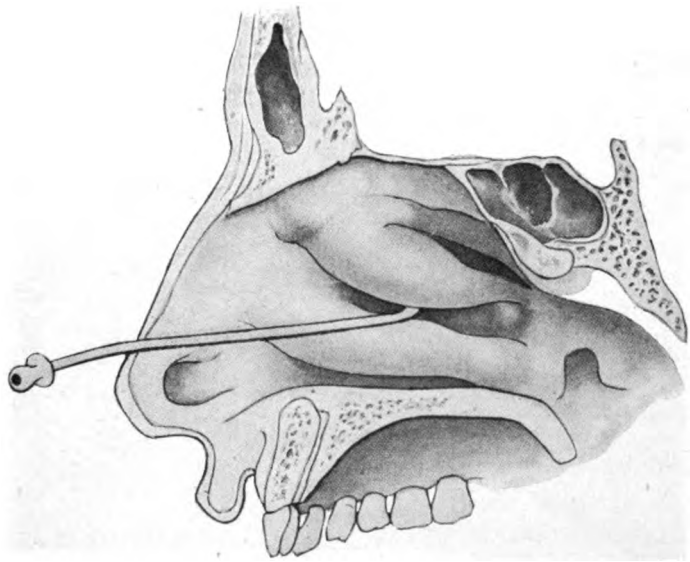

Fig. 315. Catheterizing the Maxillary Sinus.

PUNCTURING THE MAXILLARY SINUS FROM THE NOSE

Indications. It is chiefly employed as a diagnostic test. As a curative measure it is seldom successful except in comparatively recent infection. If the case be uncomplicated by suppuration in other cavities, if the teeth in the upper jaw on the same side be intact, and if the patient be anxious to avoid more severe measures and be willing to undergo the discomfort of a daily puncture, lavage has been reported as successful when repeated 27 times, even in a case with a history of 17 years' dura-

tion. But under the circumstances just mentioned it is wiser to recommend the establishment of a communication through the nose with the maxillary sinus (see p. 677).

Operation. This is done under local anæsthesia from the inferior meatus. One pledget of cotton-wool, soaked in cocaine and adrenalin, is carefully tucked under the inferior concha on the affected side, and another is applied to the septum. At the end of 20 minutes a straight



FIG. 316. LICHTWITZ'S AND MORITZ SCHMIDT'S MAXILLARY SINUS NEEDLES.

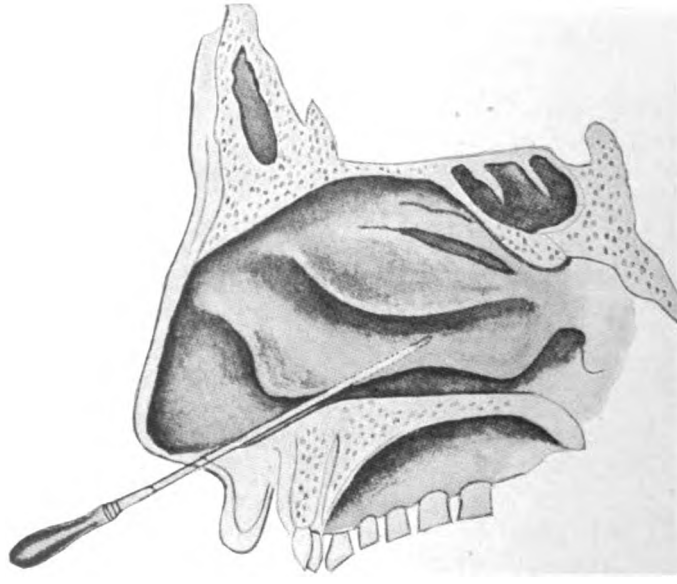

FIG. 317. PUNCHING THE MAXILLARY SINUS. The dotted part represents the portion of the exploring needle which passes under cover of the inferior concha.

Lichtwitz's or curved Moritz Schmidt's (Fig. 316) hollow needle is passed under the inferior concha and introduced upwards and laterally as near as possible to the centre of its attachment. The handle of the needle is tilted against the cartilaginous septum, while the point is directed towards the zygomatic eminence. When it is felt to encounter the thin, membranous part of the nasal wall of the maxillary sinus it is easily thrust through (Fig. 317).

While the nasal cavity is kept under inspection, air is blown through the needle from a Politzer bag, and any secretion can be observed escaping from under the centre of the middle concha. This douche of air is then followed by an irrigation of warm normal saline solution. In an acute case this lavage can be repeated daily until the symptoms of tension are relieved, or until the secretion begins to escape spontanously.[1]

Puncturing the maxillary sinus from the middle meatus incurs a greater risk of striking the orbit and is not so likely to reveal a small amount of thick secretion on the floor of the cavity.

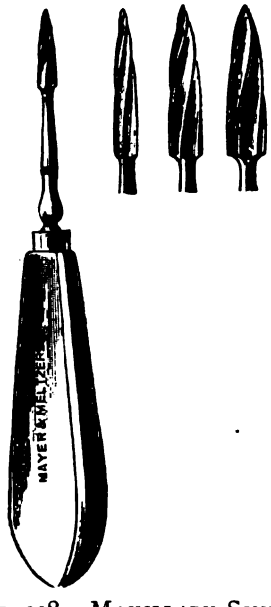

FIG. 318. MAXILLARY SINUS DRILLS.

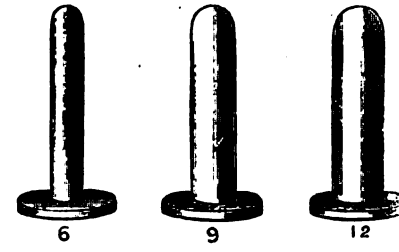

FIG. 319. SOLID RUBBER OBTURATORS. Used in alveolar drainage of the maxillary sinus.



FIG. 320. MAXILLARY SINUS NOZZLE.

PUNCTURING THE MAXILLARY SINUS FROM THE ALVEOLAR MARGIN

This is one of the oldest methods of drainage. It is less frequently employed nowadays, partly because carious teeth and empty sockets are not so commonly met with, and partly because the results have not proved very satisfactory.

Indications. The operation is useful as a diagnostic or palliative measure. In cases of unilateral multi-sinusitis, if a suitable tooth socket be available, the alveolar operation serves both to determine the condition of the maxillary sinus and to establish drainage, while the other cavities

[1] Logan Turner, *Edinburgh Medical Journal*, August, 1906, p. 152.

are being investigated or treated. In patients who are too old or feeble to endure more radical measures, or who decline them, the obturator may be left in indefinitely. In that case, if the neighbouring teeth be intact, a solid gold plug should be fitted to the denture bearing the false first molar. During the night this is exchanged for the soft rubber plug. If several teeth be missing it is more comfortable to have the obturator and denture separate—the latter being made with a setting to receive the flange.

An anæsthetic should always be given. Nitrous oxide gas or chloride of ethyl is generally recommended for this short operation, but in cases that present any difficulty it is better to follow the nitrous oxide with ether, or the chloride of ethyl with chloroform.

Operation. The most suitable tooth socket is that of the first molar, but if this be not available, that of the second bicuspid or second molar may be employed. If a tooth in one of those situations be carious, or be suspected as the cause of the sinusitis, its extraction and the drilling of the alveolus may be carried out under the same anæsthetic. The patient can be recumbent on an operating table or lying back in a dentist's chair. A small maxillary sinus drill (Fig. 318) is grasped in the hand as a bradawl is held, with the forefinger lying along it to within 1 to 1½ inches from the end, where it acts as a stop to prevent the instrument from plunging too deeply into the sinus. The drill is held vertically against the alveolar border, and with a few quick, rotatory thrusts is pushed into the cavity. The inner of the tooth sockets is selected. If required, the hole can be enlarged by a similar instrument of a larger bore. A plug, which fits firmly into the opening, is introduced, and nothing further is required for that day. A solid vulcanite obturator is recommended. It should be left *in situ* for two or three days, when it is removed to allow of the cavity being syringed through, and is then replaced by a solid, soft rubber plug, of a somewhat smaller diameter (Fig. 319). The vulcanite obturator is better for establishing the canal; if removed too soon it may be difficult

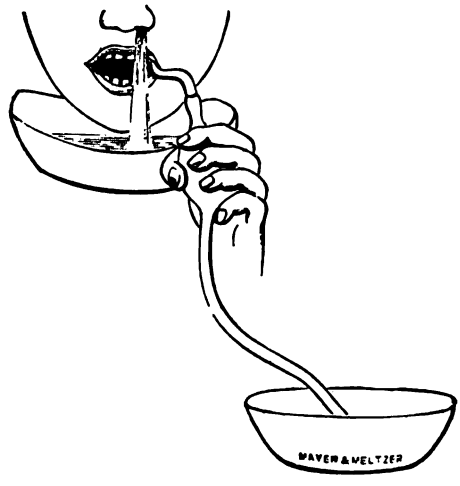

FIG. 321. WASHING OUT THE MAXILLARY SINUS FROM AN ALVEOLAR OPENING.

to replace it, and manipulation may set up severe neuralgia. A small size—No. 6 or 7—is quite sufficient.

At the end of two or three days lavage of the cavity is gradually instituted. A pint of warm sterile normal saline solution is sent through the cavity by a Higginson's syringe, fitted with a suitable nozzle (Fig. 320). As the stream issues from the nose it is received in a black vulcanite tray, which readily demonstrates the colour, quality, and quantity of secretion in the sinus (Fig. 321). When the pint of liquid is finished, air is blown through, so as to leave the sinus as dry as possible. The patient should be advised to replace the rubber obturator, properly cleaned and purified, as soon as possible. If this be neglected—for even as short a time as five minutes—the soft tissues may obstruct the channel so as to render the reintroduction painful and perhaps impossible. Another useful warning is not to wear a plug so long as to allow of the flanges being worn away, and so risk the penetration of the rubber tube into the cavity.

The syringing should at first be daily, even twice a day if necessary, and then gradually diminished in frequency, until after the lapse of a week it is found that the maxillary sinus is quite free of any pus or flocculent mucus. By changing the obturator daily the patient can readily tell whether a washing out is required. When three to six months have passed without any trace of secretion, the empyema may be considered cured. This is the more likely if a formerly obscure sinus becomes translucent, and if the patient passes through a 'cold' without suppuration beginning in it again. A trifling amount of discharge is sometimes kept up by the mere presence of the obturator.

If the saline solution fails to arrest the discharge permanently, I have rarely found that any other lotion is more effective. Strong antiseptic solutions are too irritating; milder ones, like boric lotion, permanganate of potash, weak mercurial lotions, &c., are without effect. If the discharge remains thick and offensive, peroxide of hydrogen may be added to the salt solution in the proportion of 2 vols. %. As an astringent, sulphate or chloride of zinc may be tried, in the proportion of 1 grain to the ounce; or the cavity may occasionally be washed out with a 2% solution of argyrol or nitrate of silver, or a solution of 1 drachm of tincture of iodine in a pint of sterilized water.

In cases where a cure has been obtained, the obturator is first discontinued during the night and is then exchanged for one of smaller size. The opening in nearly all cases will close spontaneously. Occasionally the track may be stimulated with nitrate of silver, pure carbolic acid, or a small curette.

Results. This method of treatment is only curative in uncomplicated cases limited strictly to the maxillary sinus. If all suppuration

has not disappeared before the end of three months, a complete cure is not to be expected by persevering longer.

OPERATION THROUGH THE CANINE FOSSA ONLY

Desault's operation. Previously to the introduction of the Caldwell-Luc operation it was customary to make an opening into the maxillary sinus from the canine fossa, and to curette, drain, pack, and carry out all subsequent treatment through the buccal orifice. The reinfection of the cavity from the mouth was, of course, inevitable: the treatment was prolonged and unpleasant: and the results were so unsatisfactory that the method has now been abandoned in favour of one or other of the operations to be described.

FIG. 322. THE INCISION IN THE CALDWELL-LUC OPERATION UPON THE MAXILLARY SINUS.

THE CALDWELL-LUC RADICAL OPERATION

Indications. This is the favourite operation in well-marked chronic empyema of the maxillary sinus.

The mouth, teeth, and gums are purified as thoroughly as possible. The face, with any moustache or beard, should also be well cleansed. The nose on the affected side is prepared with cocaine and adrenalin (see p. 612).

On the Continent this operation is sometimes carried out under local anæsthesia, but chloroform is generally employed. When the patient is unconscious, a sponge is packed in the post-nasal space (see p. 616), the tongue is drawn forward with a tongue clip (Fig. 309), and the chloroform administered from a Junker's apparatus.

Operation. The surgeon, armed as usual with a forehead electric search-light or Clar's mirror (Figs. 277, 278), stands on the affected side. In addition to the post-nasal sponge, another is inserted far back

between the molars on the side to be operated. This cheek sponge prevents any blood from running down into the pharynx and requires changing frequently.

The cheek being well retracted by an assistant, an incision is made half a centimetre below the gingivo-labial fold, extending from the first molar to the canine tooth (Fig. 322). It is carried down to the bone, so that the muco-periosteum can quickly be separated upwards, exposing the canine fossa. With hammer and chisel a circular piece of the wall is then cut through, measuring about half an inch across, and the opening is enlarged with bone-forceps or burr sufficiently to admit the surgeon's little finger.

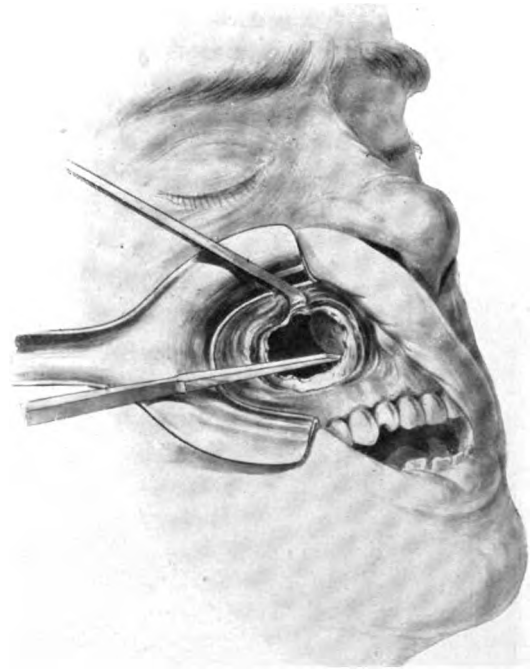

FIG. 323. THE CALDWELL-LUC OPERATION UPON THE MAXILLARY SINUS. Breaking through the nasal wall of the maxillary sinus below the level of attachment of the interior turbinal. The opening has been purposely represented coming too far forward in order to include the view of the nasal wall of the maxillary sinus.

The first opening of the sinus is frequently accompanied by free bleeding. This soon ceases, particularly if the cavity is packed for a little while with a strip of 2-inch ribbon gauze. During the operation, pieces of this gauze, 1 to 1½ yards long, prove very useful in checking any oozing and allowing a clear inspection of the walls of the sinus. They may be dipped in adrenalin, or, if the bleeding is sharp, in a 10% solution of peroxide of hydrogen, and left in place for a few minutes, while iced water is freely applied to the face and neck. As soon as the bony wall has been removed, the diseased mucous membrane presents in the opening in irregular, polypoid, bluish-greyish

masses, bathed in pus which may be highly fœtid. The diseased mucous membrane should be carefully plucked out of the cavity with a pair of Grünwald's forceps, supplemented by the use of a small ring curette, and guided by the eye and the touch of the operator's little finger. Some surgeons recommend that the whole mucous lining of the sinus be carefully and completely removed, and the walls scraped down until they are white and bare. Unless the whole mucosa is diseased, this hardly seems necessary, particularly if a free opening be made into the nose. Polypoid masses and degenerate mucous membrane are chiefly met with on the floor of the antrum (in the crevices between the cusps of the teeth), on the medial wall in the neighbourhood of the ethmoid, and in the recess in the zygomatic region, and it is to these areas that attention should be directed.

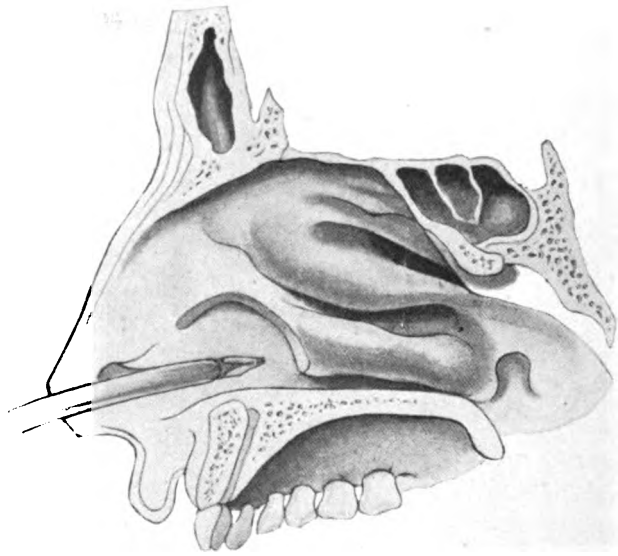

FIG. 324. OPENING THE MAXILLARY SINUS FROM THE NOSE. This is done with a Krause's trocar and canula, after removal of the anterior end of the inferior concha.

The next step is the making of a free communication with the nose. If the inferior concha is hypertrophied on the affected side, or comes so low as to obstruct any access to the nasal wall of the maxillary sinus, its anterior extremity should first be removed (see p. 627 and Fig. 284). It is better to have done this a few weeks previously under cocaine. The nasal wall of the maxillary sinus lying below the attachment of the inferior concha is next attacked with a chisel, hammer, and punch-forceps (Fig. 325). This can be done from the side of the maxillary sinus, but I have always found it useful to break it through first from the nose with Krause's curved trocar and canula. When the end of this makes its appearance in the sinus, it forms a useful landmark (Fig. 324).

This nasal opening of the maxillary sinus should be made as large as possible, particular care being taken to bring it well forward and to

smooth down the remains of the ridge separating the nose from the sinus. The opening should allow of the surgeon's little finger passing freely from the maxillary sinus into the floor of the nose, and vice versa (Fig. 323).

Whenever the ethmoid is diseased, as it often is in maxillary sinusitis, that part of it which bounds the medial antral walls should be punched away. The middle concha, in that case, will probably have been already removed.

Some surgeons recommend that the infected corners of the maxillary sinus be now wiped out with a solution of chloride of zinc (40 grains to ℥j), and the cavity packed with a strip of gauze which is led out through the nostril, whence it is removed at the end of 24 to 48 hours. The use

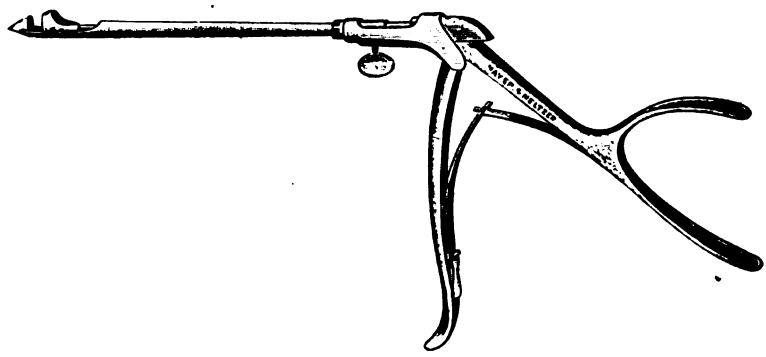

FIG. 325. OSTRONE'S PUNCH-FORCEPS. Used in breaking down the lower nasal wall of the maxillary sinus in a forward direction.

of this irritant seems inadvisable. The sinus may be syringed out with warm saline solution, and temporarily packed with a long strip of iodoform gauze, while the operation is being completed. The wound in the cheek can be closed with a couple of catgut sutures; but if there has been no destruction of the bony alveolus, this is unnecessary: the soft parts will fall into natural and complete apposition. The post-nasal sponge is removed, the iodoform ribbon gauze is withdrawn through the nostril, and the patient is put back to bed with the affected side uppermost.

After-treatment. A large pad of cotton-wool, bound firmly to the cheek over the region of the canine fossa, will relieve pain and help to keep the edges of the wound together. Nourishment should be fluid for the first three days, and taken from a feeding-cup from the opposite corner of the mouth. As a rule, there is no reaction, and the temperature seldom rises above 100° F. A little puffiness below the orbit will soon subside, and pain is relieved by a few doses of phenacetin, aspirin,

pyramidon, or some similar anti-neuralgic. The patient is frequently up and out in a few days.

As a rule, the less the local after-treatment the better. The nose may require to be cleansed with the usual alkaline lotion (see p. 619). If secretion hangs about the nasal opening of the maxillary sinus, or collects in the cavity, the latter should be washed out once or twice daily until it ceases. A short length (4½ in.), but large bore, silver Eustachian catheter is passed from the nose into the maxillary sinus, and a pint of warm saline solution is sent through it with a Higginson's syringe. The patient soon learns to do this for himself, and it may have to be continued for a few weeks. If the discharge persists, the cavity may be painted over with a solution of nitrate of silver, or a strip of ribbon gauze can be moistened with argyrol solution (25%) and passed through the antro-nasal opening into the sinus, where it is left for a few hours.

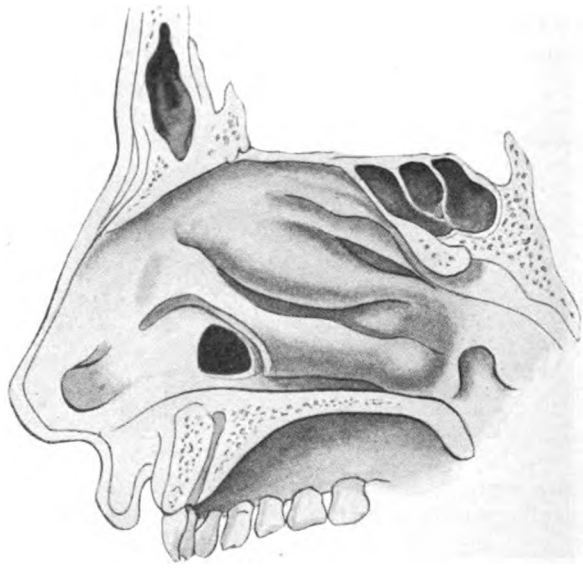

FIG. 326. THE OPENING INTO THE MAXILLARY SINUS FROM THE INFERIOR MEATUS OF THE NOSE. The anterior extremity of the inferior concha has been amputated. The opening can be extended backwards, level with the floor of the nose, and under cover of the inferior concha.

Results. In cases of chronic empyema of the maxillary sinus this operation is very successful. Failure may be due to overlooking stumps of teeth within the cavity, and from leaving detached pieces of the carious wall within it. If the pyogenic polypoid mucous membrane be not carefully removed, suppuration may persist. The corner which is difficult to reach is the acute anterior one. At the same time, an unnecessary denudation of the cavity will delay healing, and the scar tissue which more or less occupies the sinus will then tend to be irregular and dry, instead of being smooth and moist. Removal of too much of the inferior concha is apt to induce a scabby condition.

But persistence of nasal suppuration after this operation is generally found to be due to overlooked disease in some other sinus. The ethmoid is so frequently affected that it should always be carefully explored, and treated either before or at the time of the operation upon the maxillary sinus. Any suspicious-looking cells can be cleared away under cocaine during convalescence. Suppuration in the frontal sinus will have generally been excluded beforehand. It is perhaps more common for reinfection from the sphenoidal sinus to be overlooked.

FIG. 327. DENKER'S OPERATION. This is an operation for gaining access to the maxillary sinus and the lower part of the nasal cavity on the same side. The incision through the mucous membrane, and the steps of the operation, are a combination of the operations of Rouge and Caldwell-Luc.

Dangers. Operation upon this sinus is generally regarded as quite free from the risk of cerebral infection. This undeniably is so, when the empyema of the maxillary sinus is uncomplicated by suppuration in other cavities, but the operation is not free from risk if they are also infected. An operation upon one maxillary sinus has been known, even in the most skilful hands, to cause death by meningitis or diffuse septic osteomyelitis of the cranium. Post-mortem examinations show that this disaster was due to infection spreading upwards from an infected ethmoid, frontal, or sphenoidal sinus, when local resistance had been diminished, or the virulence of the organisms has been increased by the surgical traumatism of the maxillary sinus.

Such risks are best avoided by determining the condition of all the sinuses before commencing treatment of nasal suppuration. If a tooth socket be available, the maxillary sinus should first be drained through it,

so as to diminish the septic intensity of the affection; or, if there are no defective teeth, the nasal wall of the maxillary sinus should be punctured and a course of lavage carried out (p. 667). The ethmoid region, if diseased, is next treated (see p. 656). The sphenoidal orifice should be enlarged if that cavity be diseased, and the frontal sinus, if suppurating, should be operated on before the maxillary. If no tooth socket be available, both frontal and maxillary sinuses can be operated upon at the same sitting. Plugs are best avoided; communication should be made as free as possible; stitches need not be employed; and everything should be done to avoid retention and secure free drainage.

Modification. In the above operation the region which generally requires to be denuded of mucous membrane is the rough floor—the irregular surface lying over the cusps of the teeth. The ridge of the nasal opening of the maxillary sinus is a situation in which secretion is apt to lodge and dry into scabs. To overcome this drawback it has been suggested by Bönninghaus that the muco-perichondrium of the outer part of the nasal floor and the interior surface of the nasal wall of the maxillary sinus should be carefully preserved in the form of a flap which is then laid down over this bare area, and fixed there by a stitch and packing.

Another drawback of the Caldwell-Luc operation is that, although inspection and treatment of the greater part of the maxillary sinus is secured, still there are two corners which are not well exposed. They are both on the floor of the sinus, the round posterior corner and the narrow acute corner in front. The nasal wall of the maxillary sinus corresponding to these two situations is not removed, and hence the corners are apt to escape inspection at the time of the operation and free drainage afterwards.

To avoid this Denker has proposed that the opening in the canine fossa should be carried forward into the nose, and the opening in the nasal wall of the maxillary sinus extended forwards to meet it. This allows of much more complete inspection and treatment of the sinus cavity, and abolishes the anterior angle. The flap of muco-perichondrium proposed by Bönninghaus can also be much more easily manipulated. It is said that there is no fear of disfigurement from the cheek falling in (Fig. 327).

DRAINAGE THROUGH THE NASAL WALL ONLY

It was long ago proposed by John Hunter, and later by Mikulicz and Krause, that an opening should be made into the maxillary sinus from the nose. This operation has latterly been developed by Claoué and Rethi, and now has many supporters.

Operation. On the Continent it is frequently carried out under

local anæsthesia, but chloroform is generally required. If the inferior concha comes down close to the floor of the nose, the anterior third or half should be removed (see p. 603 and Fig. 284). The nasal wall of the maxillary sinus lying below the attachment of the inferior concha is then broken through with chisel and hammer, or a Krause's trocar (Fig. 280), and the opening enlarged with punch-forceps (Fig. 281). For the anterior margin of the opening—the one most difficult to remove—special forceps which cut forwards have been designed (Fig. 325).

The opening is large enough to allow the introduction of curettes and of the application of treatment from the nose. The patient soon learns to wash out the sinus for himself, with a silver Eustachian catheter and Higginson's syringe, as after the Caldwell-Luc operation.

Results. The advantages claimed for this operation are that it is simple, quicker, and as effective as the one with the opening from the canine fossa. But, of course, it does not allow any inspection, and only a partial removal, of the diseased contents of the sinus.

Still the results obtained are so satisfactory,[1] that it seems advisable to try it in the majority of cases as a necessary first step, even if the Caldwell-Luc operation has to be completed later. But where the case has a long history; marked obscurity on transillumination; a foreign body in the sinus; or where the *Streptococcus pyogenes* is the virulent organism, or where the streptococcus is associated with the presence of squamous epithelium and lymphocytes,[2] it adds little to the gravity or complexity of the procedure if the canine fossa be opened at the same time, the diseased cavity inspected, and everything completed under the one anæsthesia.

OPERATIONS UPON THE FRONTAL SINUS

CATHETERIZING AND WASHING OUT THE FRONTAL SINUS

Indications. This method is indicated—

(i) As a first step in diagnosis and treatment.

(ii) To diminish the risk of retention and decrease virulence in those patients where an external operation is not indicated or is declined.

(iii) It is rarely required for acute frontal sinusitis, although it might be used in acute exacerbation of a chronic suppuration.

Operation. It is very seldom that it is possible to sound a frontal sinus, unless the anterior ethmoidal cells have been broken down by

[1] C. A. Parker, *Brit. Med. Journ.*, October 10, 1908, p. 1099.

[2] Logan Turner, ibid., p. 1096.

disease. When this has occurred—or when the anterior extremity of the middle concha has been removed, as described on p. 632—the anterior region of the middle meatus is well anæsthetized. Under good illumination a thin silver canula is then introduced until it reaches the middle meatus with its beak lying below and in front of the bulla ethmoidalis. By depressing the hand the point of the instrument is then directed upwards, forwards, and slightly outwards, until it slips into the frontal cavity (Fig. 328). No force should be employed. The end of the catheter is bent to suit the conditions met with. A bead of pus exuding from the hiatus semilunaris will often serve as a useful guide. If there be any uncertainty as to the catheter having entered the frontal sinus, its exact situation can be determined by the Röntgen rays (Figs. 329, 330).

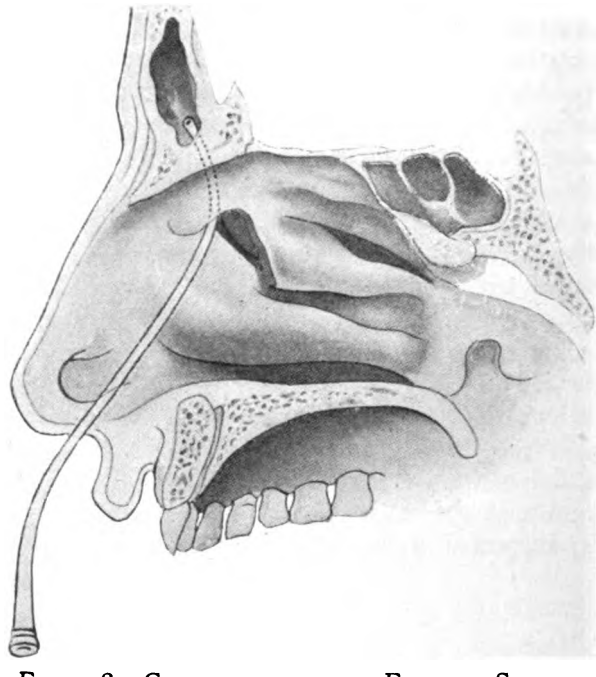

FIG. 328. CATHETERIZING THE FRONTAL SINUS.
The anterior end of the middle concha has been removed.

A Politzer's inflation bag is now connected with the end of the frontal canula, and the air is blown through it. This will be heard gurgling through the sinus, and if the anterior region of the middle meatus is at the same time kept under observation, thick mucus or pus will be seen to be driven out by it. The Politzer's bag is then replaced by a syringe, and a pint of warm sterile normal saline solution (℥j to Oj) is sent into the sinus, and as it returns is received in a black vulcanite tray. The latter readily shows up the presence of any flakes of mucus or pellets of pus. If successful, the above proceeding can be repeated twice daily.

When the cavity can be catheterized from the nose it should be washed out daily with liquids similar to those indicated for suppuration in the maxillary sinus (see p. 671).

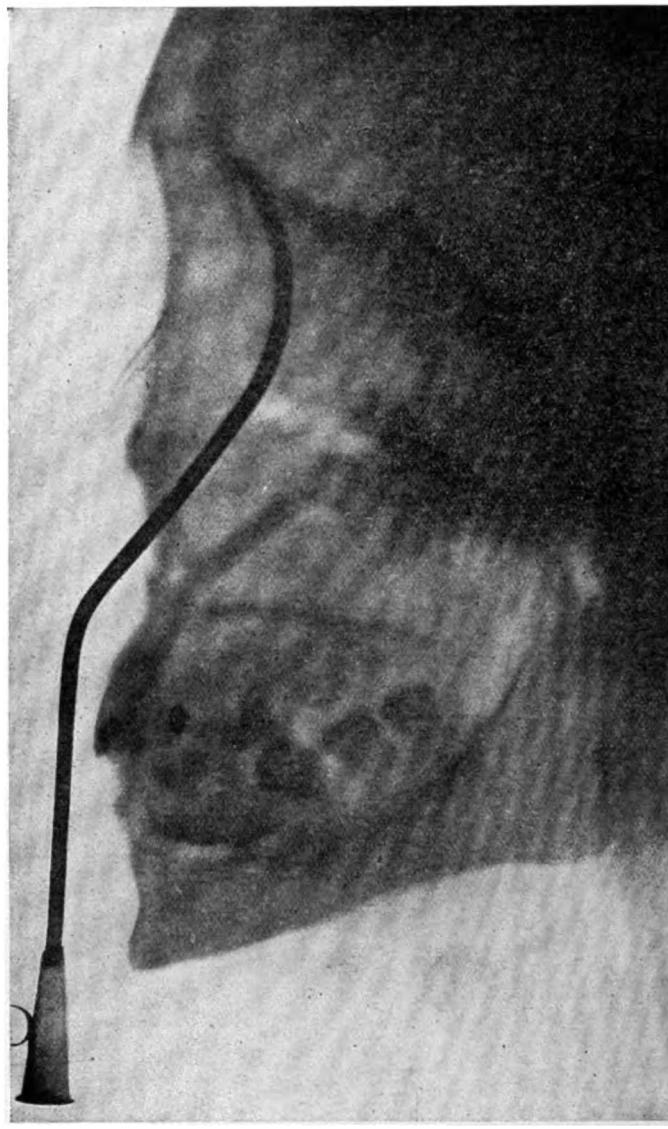

FIG. 329. RADIOGRAPH TO SHOW THE VALUE OF THE RÖNTGEN RAYS. The canula might be thought to have entered the frontal sinus, whereas the X-rays show that its point has only penetrated an ethmoidal cell. Compare with the following figure.

Results. I am very doubtful if a permanent cure is ever effected by this treatment in a case of established chronic suppuration. In a case in which I was certain that the suppuration was not of more than four

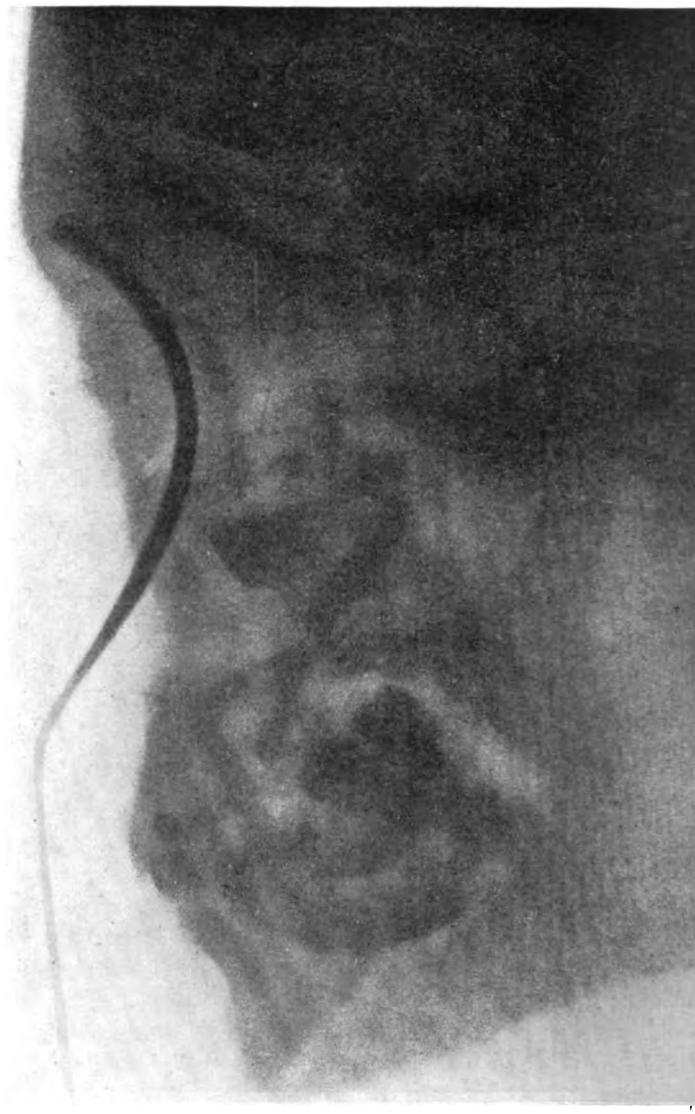

FIG. 330. RADIOGRAPH SHOWING CANULA IN THE FRONTAL SINUS.

months' duration intranasal treatment was a failure, although carried out most carefully on 44 successive days.[1]

[1] *Proc. Royal Soc. Med.*, 1907, December.

The cause is very apparent whenever these sinuses come to be opened; the cavity itself is generally stuffed with fungating mucosa, and the fronto-ethmoidal cells—where the lavage never penetrates—are affected in the same way.

OPENING THE FRONTAL SINUS IN ACUTE SUPPURATION

It is rare for this to be necessary. The contents of the cavity generally make their way through the natural ostium, before any of the bony walls give way. Still, the posterior (cerebral) wall may yield, giving rise to meningitis or cerebral abscess. The treatment of this complication is given on p. 690. The orbital wall may be penetrated, with the formation of an orbital abscess which should be evacuated. It is most uncommon of all for the anterior wall to give way. When this does occur the abscess should be opened through an incision designed on the principle given later on for chronic empyema (see p. 693).

KILLIAN'S OPERATION

At the present time the Killian operation is the one most generally employed.

Indications. The indications for this operation are thus given by Killian himself:—

1. Failure of other operations.
2. Presence of fistula or abscess, or indications of necrosis.
3. Symptoms of intracranial complications.
4. When in a case of chronic purulent frontal sinusitis there is pain and fever with a fœtid discharge.
5. Persistent headache, particularly when associated with discomfort in the region of the eye, and not relieved by intranasal treatment.
6. When this discharge from the sinus remains foul, in spite of repeated irrigations.
7. When recurring groups of polypi are produced by the suppuration in the frontal and ethmoidal cells.
8. When a simple purulent discharge is not relieved by careful intranasal treatment, and the patient desires permanent relief by radical operation.

A radiograph is taken and is an extremely useful help to indicate the size and extent of the frontal sinus, and to prepare the surgeon for meeting with troublesome orbito-ethmoidal cells.

As the ethmoid is diseased in nearly all cases it should be cleared away at previous sittings, under cocaine or chloroform (see p. 656). Even when healthy, the anterior extremity of the middle concha should be amputated (see p. 632). If the antrum be also suppurating and a

suitable tooth socket be available, the alveolus will have been drilled at one of these preliminary treatments. If the sphenoidal sinus be suppurating, its orifice will have been enlarged.

One hour before the operation the strips of ribbon gauze, soaked in adrenalin with the addition of 5% cocaine, are carefully laid all over the mucous membrane of the nose on the affected side. The face, moustache, and beard are well purified. When the patient is under chloroform three pencils of tightly rolled cotton-wool are introduced into the nose; one along the middle meatus, a second in front of the

FIG. 331. KILLIAN'S OPERATION UPON THE FRONTAL SINUS. Shows the skin incision, with the transverse scratches made to ensure correct coaptation of the flaps.

inferior concha upwards towards the bridge of the nose, and the third in the inferior meatus. The first two pledgets are useful afterwards for anatomical definition, and the third keeps them in place. A sponge is inserted in the post-nasal space (see p. 616).

Operation. There is no advantage in shaving off the eyebrow. It can be thoroughly purified and helps to locate the skin incision; if removed, it takes some time to grow again, and is apt not to correspond in size with the eyebrow of the opposite side. The skin incision is first defined by scratching through the cutis with the tip of the knife. It starts at the outer end of the eyebrow, passes inwards along the very centre of the eyebrow itself, and then sweeps downwards and outwards over the side of the nose, to end on the cheek (Fig. 331). When the whole

extent has been marked out three or four cross scratches are made. The object of this is to ensure correct coaptation of the flaps, and to avoid any risk of disfigurement. Returning to the lateral extremity of the incision, it is now carried down through all the soft tissues till it meets the periosteum. The flaps are retracted a little upwards and downwards, while the free hæmorrhage is met with pressure forceps. The periosteum incisions are now carefully planned. Starting again from the outer corner the knife is drawn inwards parallel to, and slightly above, the upper margin of the supra-orbital arch; but, instead of

FIG. 332. KILLIAN'S OPERATION UPON THE FRONTAL SINUS. The thick lines indicate the incisions through the periosteum.

curving round the inner end of the orbit, in the track of the skin incision, it is kept straight along under the upper flap to end over the glabella. The periosteum can now be reflected from the front of the sinus, and pushed upwards with the skin on to the forehead. The lower skin flap is detached and retracted downwards, until the medial third of the supra-orbital arch is defined. The periosteal covering is next cut through by carrying the knife along the lower border, but instead of passing inwards parallel to the first periosteal incision this second one sweeps down on to the side of the nose, in the track formed by the skin incision (Fig. 332).

The periosteum is carefully peeled off the nasal process of the maxilla, and turned down from the medial third of the supra-orbital arch, ex-

posing a triangular area of bone. The periosteum must be carefully preserved over the inner part, to avoid the risk of necrosis of the arch, which is converted into a bridge, the 'Killian bridge,' by the opening in bone below and above it.

The upper flap of soft parts, with the periosteum, is well retracted up on to the forehead. The radiograph will have given an idea of the extent to which the front wall of the sinus must be laid bare. With a chisel and hammer the sinus is opened at its medial extremity. A good plan is to employ Killian's triangular curved chisel (Fig. 334) and to

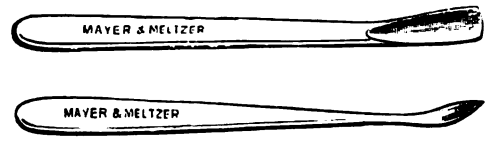

FIG. 333. PERIOSTEAL ELEVATORS.

cut a trench in the bone along the upper margin of the bridge. This trench is gradually deepened at the inner end until the sinus is entered. The entry is generally announced by the bulging upwards of the blue, polypoid, pyogenic membrane into which the thin white delicate mucosa of the cavity has been converted. The anterior wall is now completely removed with hammer, chisel, and forceps. Those of Lombard, Horsley, Hajek (Fig. 336), Jansen, Citelli (Fig. 335), or similar models

FIG. 334. KILLIAN'S TRIANGULAR CURVED CHISEL.

enable us to bevel down the margins of the cavity carefully as it slopes up on to the forehead.

The pyogenic membrane is now carefully plucked away with a pair of Grünwald's forceps. I never find it necessary to curette the cavity, which must always be a risky proceeding. Small pledgets of ribbon-gauze, if gently rubbed along the surface and into the corners, will detach every scrap of diseased mucosa.

The septum separating the two frontal sinuses may be found to be defective. The opening through the eyebrow on one side may open into a cavity which communicates only with the nasal cavity of the opposite side—one sinus being very large and extending far beyond the median line, while the other is quite small. Or only one frontal cavity may be present. An extensive acquaintance with the surgical anatomy of the region is required to prepare the surgeon for encountering these

and other irregularities, and the systematic use of radiography will prevent him from being taken by surprise.

The next step is to make the opening below the bridge. The exposed surface of the nasal process of the maxilla is cut through with the triangular chisel. The opening is enlarged with bone-forceps until free access is obtained to the anterior ethmoidal cells. The pledgets of cotton-

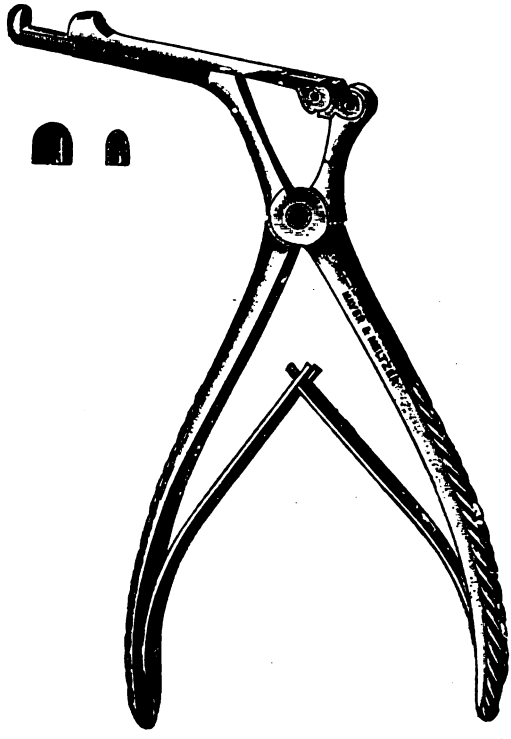

FIG. 335. CITELLI'S BONE-FORCEPS.

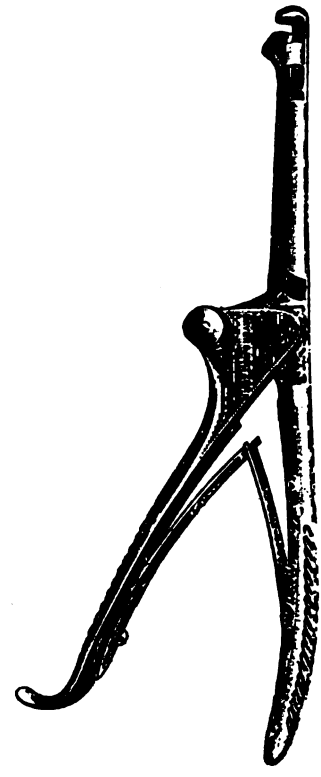

FIG. 336. HAJEK'S BONE-FORCEPS.

wool placed in the nose at the beginning of the operation now come in to help as guides. The periosteum is further elevated from the lacrimal bone above its groove, from the orbital plate of the ethmoid as far back as the anterior ethmoidal vessels, and from the orbital plate of the frontal bone below the bridge and extending outwards to the trochlear attachment and the supra-orbital notch. During this proceeding the contents of the orbit are protected from pressure by several folds of gauze, and are carefully retracted outwards by Killian's protector. The area of bone which can now be clipped away comprises parts of the

lacrimal, of the lamina papyracea, and of the floor of the frontal sinus. The whole of the floor of the sinus must be removed, either from above the bridge or from below. If this cannot be done without anxiety as regards the attachment of the pulley of the superior oblique, it is better to risk this than to leave pus-secreting pockets of orbito-ethmoidal cells

FIG. 337. KILLIAN'S OPERATION UPON THE FRONTAL SINUS. The periosteum has been preserved on the bridge. Above this the frontal sinus is exposed: at its inner (nasal) extremity the frontal bulla is indicated, mounting up into the cavity; at the outer extremity an arrow indicates the orifice of a fronto-orbital cell which should be opened up. The periosteum lying above the bridge has been retracted up with the soft parts on to the forehead. Below the bridge is the opening to the ethmoidal region. The curved retractor is protecting the eyeball.

cut off from drainage in the roof of the orbit. But the pulley of the superior oblique should never be divided from its attachment to the rim of the orbit. It is much safer to reflect the periosteum further laterally and downwards from the lower border of the Killian bridge. In doing this the pulley of the superior oblique is detached with it; any diplopia, most noticeable on looking downwards and outwards, is generally tempo-

rary; and as a rule it will disappear when the swelling subsides and the periosteum gets back to its anchorage (Fig. 337).

It is this part of the operation which is the most delicate, tedious, and important. It is very common to meet with irregularities. The orbital recess of the frontal sinus itself may run back in the roof of the orbit nearly as far as the foramen opticum. One or two galleries may be met with in the roof of the orbit—prolongations of orbito-ethmoidal cells—passing outwards as far as the temporal end of the eyebrow. Their presence can only be revealed after removal of the floor of the frontal sinus proper, and in this way two or three bony dissepiments may have to be removed before the orbital fat arises, as it should do, to occupy the lower part of the exposed frontal sinus. In this part of the operation much help is obtained by the careful use of a probe, by frequently securing a field free from bleeding by pressure with adrenalin or peroxide, and by the knowledge previously gained by skiagraphy.

If the Röntgen rays have shown that the frontal sinus does not extend above the level of the bridge, or if radiography be not available and there is any uncertainty as to the extent of the cavity, this lower opening should be made first.

In the inner part of the large orifice which has been made below the bridge the deeper ethmoid cells can be treated, and the sphenoidal ostium is much nearer than when viewed from the introitus narium, so that it is easy to enlarge it and deal with the contents.

Now, as throughout the operation, great care must be taken to shield the eyeball with gauze pads and the protector. The hanging pressure forceps are apt to be pushed against the globe.

The whole area of operation is next carefully cleaned with warm normal saline solution. Any projecting corners or loose spicules of bone are removed. If any point of pus should show up it must be carefully followed to its source. The cotton-wool pledgets are removed from the nose. The pressure forceps are twisted off, and any vessels that require it are ligatured. A strip of ribbon-gauze is loosely packed in the lower part of the enlarged fronto-ethmoidal space, and the end is led down to the nasal orifice. The flaps are brought together, and care is taken that the reflected periosteum is pulled back with them. Formerly Killian in the majority of cases used to sew up the whole wound at once. He now agrees that it is safer to leave the lateral angle with a small drainage-tube running inwards and downwards to the area of the fronto-ethmoidal cells. The inner part of the incision in the eyebrow, and all the part lying below the bridge, can be closed. Killian employs aluminium-bronze wire, and a metal suture seems preferable, as the contamination of the wound edges makes stitch abscess not uncommon.

Secondary suture—on the second or third day—is reserved by Killian for cases when (1) the history or appearance of the mucosa indicates a recent exacerbation, (2) there is a history of erysipelas, (3) the pus is very fœtid. (4) there is any history of a tendency to wound complications, or (5) there is marked invasion of the diploë in the frontal bone.

Double cyanide gauze, wrung out of boric lotion and covered with a good supporting pad of cotton-wool, is then put on. But when there is any question of intracranial complication, when the pus is fœtid or there is any necrosis, and when the surgeon is forced to operate during an acute exacerbation, it is better to apply warm boric fomentations and leave the upper and lateral supra-orbital part of the incision freely open.

After-treatment. The patient is put to bed on the sound side, so as to assist drainage. He is advised not to blow the nose, but to hawk as much of the secretion as possible backwards and then expectorate it. The gauze drain is removed from the nose at the end of twenty-four hours, and is not renewed. The drainage-tube at the temporal end of the incision is changed at the end of forty-eight hours, and afterwards is removed and cleansed daily. The dressing is also changed daily, after the first forty-eight hours, so as to keep a careful watch for any retention. On the fifth day the sutures can be removed, and soon afterwards the dressing can be discontinued and the eye left uncovered. Intranasal treatment should be avoided for a while. But after two or three weeks the granulating surface behind the bridge is painted occasionally with a 2 to 3% solution of nitrate of silver. Any crusts are removed after soaking with peroxide of hydrogen.

Complications and dangers. The operation is not free from danger. Latent cerebral trouble connected with the sinus may be roused into activity by the local traumatism, however skilfully effected. The shock, or the lowered local resistance, may stimulate a latent infection in neighbouring sinuses, and also weaken the lines of defence protecting the cranial cavity.

In 1905 Logan Turner collected the record of twenty-four deaths which had occurred after operation on the frontal sinus.[1] This number has been exceeded by the fatalities since published and the much greater number which have never been recorded.[2] The chief dangers are (1) a spreading septic osteomyelitis, (2) meningitis, and (3) abscess in the frontal cerebral lobe.

Infection of the bone is indicated chiefly by a puffy, tender swelling on the forehead or temple, adjoining the upper flap. There may be

[1] Logan Turner, *Edinburgh Medical Journal*, 1905, March.

[2] *Die Komplikationen der Stirnhöhlenentzündungen*, von P. H. Gerber, Berlin: S. Karger, 1908.

little or no rise of temperature, and little complaint on the part of the patient. But no time should be lost in laying the wound freely open, searching for any shut-off focus of pus, and applying hot boric fomentations diligently. Once infection is established in the bone it may be impossible to stay its progress, even by the most thorough removal of diseased tissue; but the effort should be made.[1]

Meningitis is an equally dangerous complication. It may arise without direct injury to the cerebral wall of the sinus. If, during removal, the anterior end of the middle concha be damaged too high up, the lymph channels around the olfactory nerve may be opened so freely that infection spreads along them to the meninges. Or the cerebral wall may sometimes be broken through without a serious result, if the dura mater be left intact behind it. But if there be any damage done to the wall in the neighbourhood of the crista galli or cribriform plate, the dura mater is almost inevitably injured at the same time, and a rapid and fatal meningitis may be expected. The infection is generally streptococcal, and surgery is powerless to stop its progress.

Abscess in the frontal cerebral lobe may arise from operation on the frontal sinus. In my experience it is more apt to occur independently of interference with the sinus, to remain latent, and then to be simply roused into activity by the local traumatism. The symptoms are, unfortunately, very vague. Rise of temperature, headache, irritability, drowsiness, and optic neuritis may be present. On the occurrence of these symptoms the sinus should be freely reopened, and the posterior (cerebral) wall carefully inspected for any necrosing area. In any case it should be removed and the frontal lobe explored in all directions.[2]

These dangerous complications, in many cases, were no doubt due to a failure to recognize that the complicated group of ethmoidal cells were involved in all cases of chronic frontal suppuration, and that previous to the introduction of the Killian operation our operative methods were very apt to dam up suppuration in dangerous corners. Finally, it was only when rhinologists first began to investigate frontal sinusitis that it was recognized what a dangerous region this is. To be convinced of this it is only necessary to compare the anxiety inspired by our regard for the cerebral wall of the frontal sinus with the calmness with which we regard an opening into the middle fossa, or through the dura mater, in mastoid operations.

[1] H. Tilley, *Lancet*, 1899, August 19, p. 534, and *Edinburgh Medical Journal*, 1905, March, in paper of Logan Turner's. Dan McKenzie, *Journal of Laryngology*, 1913.

[2] A successful case is reported, *Proc. Roy. Soc. of Med., Lond.*, 1908, June meeting, by L. V. Cargill, William Turner, and the writer.

We are not yet in possession of definite evidence in regard to the proportionate number of deaths which are due directly or indirectly to pus in the frontal sinus. Some observers hold that more deaths have occurred from operation than from neglected cases. Molinié has followed the history of fifteen private patients with frontal sinusitis, and not operated on, for ten years. Only one has died, and that was from another cause.[1] In any case we may still accept Lermoyez's dictum: 'Avoir une sinusite chronique est chose moins grave qu'on ne croit: opérer une sinusite frontale est chose plus sérieuse qu'on ne le dit.'[2]

Doubtless the dangers have been diminished since the more general adoption of the Killian operation, but accidents may occur in the most skilful hands. This must be kept in mind when drawing up the indications for interference.

Results. In uncomplicated cases, successfully operated on, the results are most satisfactory. The preservation of the Killian bridge quite prevents any really unpleasant disfigurement. The depression which may form above it is proportionate to the size and depth of the cavity. No man need decline the operation on account of the scar left. In women we are able, with the help of a radiograph, to form an idea beforehand as to the degree of depression which may be left. This, if required, can be remedied by the injection of paraffin, but, fortunately, the frontal sinus in women is not, as a rule, so deep as in men.

As regards cessation of purulent discharge the result will depend on the extent of the sinus, the presence of complicated orbito-ethmoidal cells, and the skill of the operator. If the ethmoidal labyrinth has not been completely dealt with, one or two cells may continue to secrete. It may be wiser to leave them alone. In very deep sinuses a 'dead space' between the back of the Killian bridge and the posterior (cerebral) wall of the sinus remains open, and may continue to secrete if not cicatrized over evenly.

But the secretion is no longer pent up in the fronto-ethmoidal group of cells, and the patient is relieved of headache, depression, and other symptoms of septic absorption.

THE OGSTON-LUC OPERATION

This operation was first described by Ogston,[3] but was independently conceived by Luc.[4] Its principle is to make a fairly free opening into the frontal sinus, and then establish a large communication with the

[1] *Annales des Maladies de l'Oreille*, 1905, juillet, ii, 72.
[2] Ibid., 1904, XXX. vi. 579.
[3] Ogston, *The Medical Chronicle*, 1884, December.
[4] Luc, *Société Française d'Otologie*, Paris, 1896, mai.

nasal cavity. The inner part of the supra-orbital rim is sometimes destroyed. But the operation does not provide for the treatment of orbito-ethmoidal cells, the anterior ethmoidal region and the sphenoidal wall are not exposed, and if there be a large orbital recess to the frontal sinus it cannot be satisfactorily dealt with.

Indications. But the Ogston-Luc procedure, or some modification of it, is still suitable in (1) exploratory openings of the frontal sinus, (2) when the sinus requires opening for a recent and acute infection,[1] and (3) for mucoceles and suppurating mucoceles.[2]

Operation. A general anæsthetic is required. It is not necessary to shave the eyebrow, but the surrounding skin should be well purified. A curved incision is made through the eyebrow down to the bone along the inner third of the supra-orbital ridge, reaching from the supra-orbital notch to opposite the inner canthus. In the latter direction it can be extended if the ethmoidal region is chiefly affected, and if the ethmoid only requires exposing the incision is placed lower down.

With a raspatory the soft parts are turned upwards and downwards so as to expose the anterior wall of the sinus, which is opened with chisel and hammer. A probe will indicate its depth and direction. The opening is enlarged with bone-forceps sufficiently to allow inspection of the interior of the cavity, and permit of the passage into the nose being enlarged with forceps, curettes, or burrs. The polypoid mucosa occupying the sinus and the fronto-ethmoidal cells along the passage to the nose are carefully plucked away. A drainage-tube or wick of gauze is inserted from the sinus down into the cavity of the nose, so that it can be withdrawn from the opening at the end of twenty-four hours. The drainage-tube is replaced by some surgeons. The frontal wound is sometimes closed at the time of the operation, and sometimes left open.

Results. These are variously given by different observers. Thus one author states that it will effect a cure in 85% of cases,[3] while another operated by this method in eleven cases, of which two died and not one was completely cured.[4]

The subject does not require further discussion, as most operators have now given this operation up in favour of the improvements wrought in it by Killian. Luc himself has abandoned it in favour of the Killian operation. The latter is undoubtedly to be preferred in all cases of well-established chronic purulent sinusitis with fungating mucosa and involvement of the ethmoidal cells.

[1] StClair Thomson, *The Practitioner*, 1906, July.
[2] Logan Turner, *Edinburgh Medical Journal*, 1907, November and December.
[3] Lermoyez, *Annales des Maladies de l'Oreille*, 1902, novembre.
[4] H. L. Lack, *Edinburgh Medical Journal*, 1902, June, p. 542.

KUHNT'S OPERATION

In this operation the entire anterior wall of the frontal sinus is chiselled away, so as to allow of the soft parts covering it being pressed down into the cavity until they are applied to the posterior wall. This, naturally, effects a complete obliteration of the cavity, but in order to secure it the orbital ridge has frequently to be removed to such an extent that a frog-like prominence is given to the eye, and the resulting disfigurement is very marked. Besides, this operation does not deal with the orbital recess of the sinus, or the orbito-ethmoidal cells—the most important part of the operation. In fact, the only advantage of this operation—complete obliteration of the sinus—is secured by Killian's operation, which also allows these regions to be dealt with, permits free drainage into the nose, and avoids disfigurement.

OPERATIONS UPON THE SPHENOIDAL SINUS

Surgical Anatomy. In operating on this sinus there are many anatomical and pathological points which it is desirable to remember. Only a few of them can be recalled.

The cavity is seldom absent, although it may be quite small. Its size and conformation may be irregular. Thus in one instance it may extend far out into the wing of the sphenoid, while in another it may be even smaller than a posterior ethmoidal cell invading the body of the sphenoid bone and lying above it.

While the sphenoidal sinus on one side is very small the opposite one may be so large that it comes in relation with the optic groove of the opposite side.

The anterior wall of the sphenoidal sinus can be opened with safety. The roof comes into close relation with the structures round the sella turcica. The outer wall is close to many large blood-vessels which might cause troublesome hæmorrhage if wounded. The upper outer wall may be as thin as paper.

There may be deficiencies present in the bony walls, so that, for instance, the mucous membrane of the sinus and the dura mater may be in direct contact.

The Röntgen rays give such valuable information as to the size and relations of the cavity, as well as to diseases in its cavity or walls, that a radiograph should be taken in all cases (Figs. 338 and 339).

SOUNDING AND WASHING OUT THE SPHENOIDAL SINUS

Indications. Lavage alone may be sufficient for acute or recent cases, but in chronic forms of suppuration a larger and permanently

patent ostium must be established, both to allow of more effective drainage and of treatment of the interior of the cavity.

When the interior of the nasal chamber is in a normal condition it is only possible to catheterize this cavity in a limited number of cases. The region of the middle concha and olfactory cleft is carefully prepared

FIG. 338. RADIOGRAPH OF THE SPHENOIDAL SINUS. The beak of a punch-forceps is seen in a posterior ethmoidal cell (which has been opened) and pressing against the anterior wall of the sphenoidal cavity.

with cocaine and adrenalin. A pledget soaked in the mixture is inserted between the middle concha and the septum, and pushed backwards until it reaches the anterior wall of the sinus.

A canula is then inserted in a sloping direction inwards and upwards diagonally across the plane of the middle concha until it impinges on the nasal surface of the sphenoid, in the neighbourhood of the ostium (Fig. 340). The latter is found by feeling with the tip of the catheter. The opening is never visible in health. It may lie a little external to

the direction of the olfactory cleft—about 5 millimetres from the middle line.

If this plan be not successful, the ostium sphenoidale can more certainly be discovered in the following way. A more complete and prolonged application of cocaine is carried out, particularly in the neighbour-

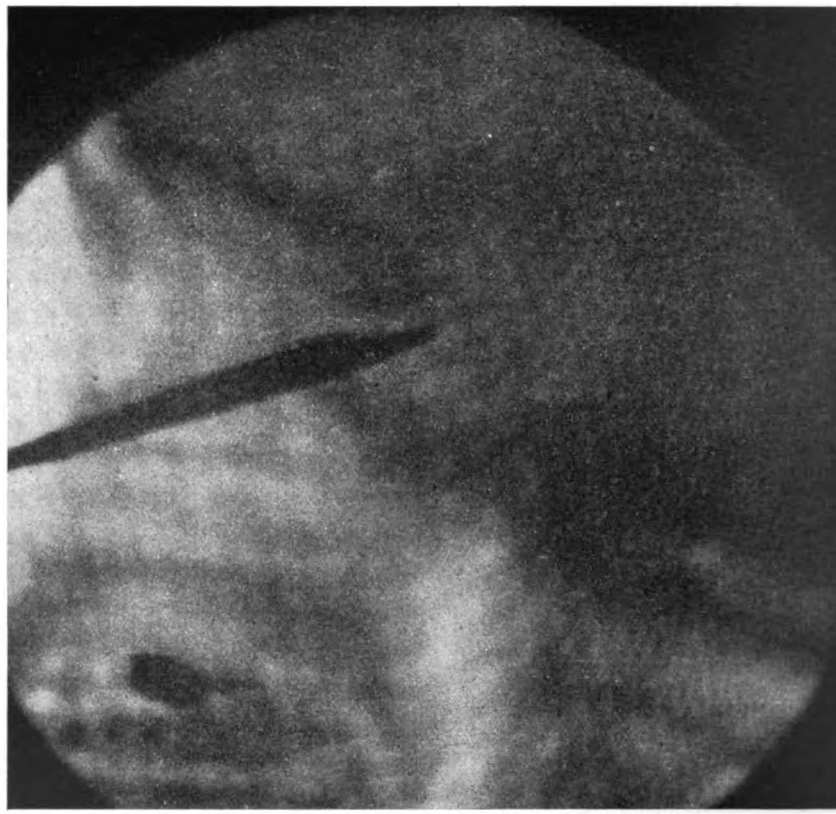

FIG. 339. RADIOGRAPH OF THE SPHENOIDAL SINUS. This is a sequel to the preceding illustration. The front wall of the sinus has been broken through, and the beak of the forceps is now shown inside the sphenoidal cavity.

hood of the olfactory cleft and the spheno-ethmoidal recess. Killian's long nasal speculum (Fig. 341), sterilized and warmed, is inserted between the middle concha and the septum. By separating the blades of the speculum the passage is dilated, so that the instrument can be slipped farther in, and so, by alternating movements of expansion and advance, the front wall of the sinus is brought into view. During this procedure the middle concha is crowded laterally, and no alarm need be caused if a slight cracking sound shows that its attachment has been fractured.

The mouth of the sphenoidal sinus is often indicated by the muco-pus oozing from it or pulsating in harmony with the pulse. If discharge be not escaping the ostium may be only a potential and not an actual orifice —like that of the meatus urinarius—and has then to be more carefully sought for and detected with a probe. If there be difficulty in finding the ostium, the front wall should not be broken through until the presence and size of the sinus has been demonstrated by means of a radiograph (Figs. 338 and 339). The sinus is washed out, as described for the frontal and maxillary cavities.

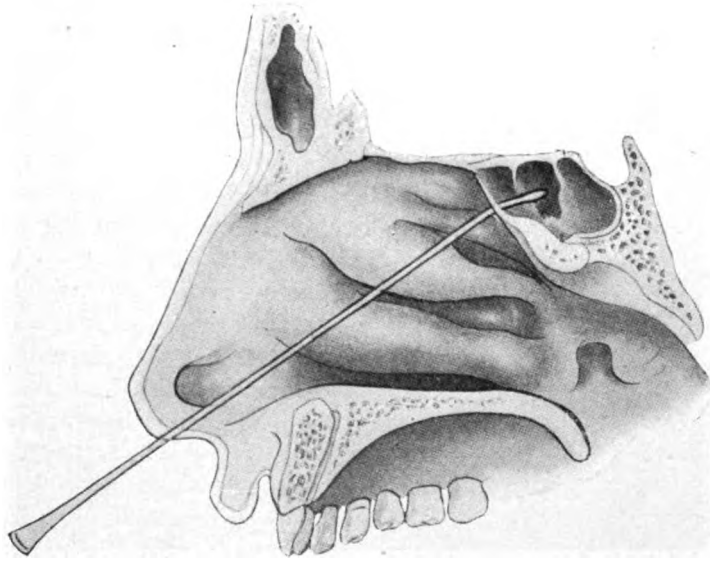

FIG. 340. CATHETERIZING THE SPHENOIDAL SINUS.

OPENING THE SPHENOIDAL SINUS

Indications. Profuse purulent post-nasal catarrh, persistent headache, orbital or ocular or intracranial symptoms, call at once for relief. Not infrequently suppuration in other cavities will not cease, even though operated on, until the sphenoidal sinus has been treated.

Operation. Unless long-standing suppuration or ozæna have produced such atrophy of the middle concha that the front wall of the sphenoidal sinus is easily inspected from the front, it will be necessary to remove the greater portion of the middle concha. If the anterior end has had the typical amputation performed (see p. 632), then the rest can be removed with the punch-forceps of Grünwald, the wire snare, or, under nitrous oxide anæsthesia, the spokeshave.

This will bring the anterior wall of the sinus with its ostium into

view. Killian's long nasal speculum (Fig. 341) may still be necessary. With the help of cocaine the ostium can then be enlarged with various instruments. Hajek's hook can be inserted into the orifice and the front wall torn away. I have not found this satisfactory. It is much simpler to insert the beak of a small Grünwald's forceps into it, or a small ring-knife, and by a series of boring and screwing motions to render the ostium patent. It is then easy to introduce a beaked Grünwald's or some such punch-forceps as those of Cordes (Fig. 343) and cut away as much of the front wall as may be required. This can be done freely in an inward and downward direction, and an opening as large as the tip of the little finger, and sufficient for drainage and treatment, is thus established.

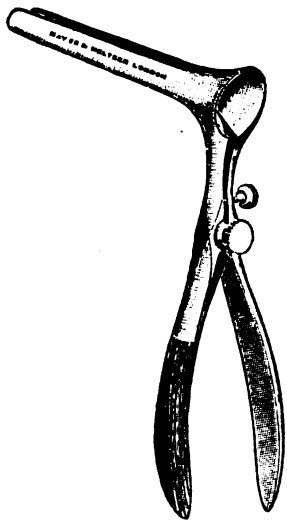

FIG. 341. KILLIAN'S LONG NASAL SPECULUM.

When describing the removal of posterior ethmoidal cells (see p. 658) it was pointed out that the tip of the forceps not uncommonly breaks through the thin portion of the anterior sphenoidal wall.

If the natural ostium sphenoidale be not visible it would be risky to make an artificial opening without first determining by radiography the presence and size of the sinus. When this has been ascertained, palpation with a pair of sinus-forceps or a Lichtwitz's trocar and canula will generally detect a thin spot where firm pressure is sufficient to penetrate into the cavity. The opening is then enlarged as described.

In all these procedures care must be taken that the instrument does not burst suddenly through the front wall with such force that it impinges on and damages the posterior wall.

The opened sinus must be dealt with according to the conditions met with. Necrosed portions of bone may require to be removed, but they rarely occur, except in syphilitic cases. Polypoid masses of mucous membrane, obscuring the opening, may be carefully lifted out with forceps or curette, so as to facilitate drainage; but it is never necessary to think of curetting the interior generally, and particular regard should be paid to the posterior wall.

After-treatment. Profuse hæmorrhage has sometimes occurred after opening the sinus. In a case of Gleitsmann's the bleeding did not take place until seven days after the operation,[1] and in one of C. R.

[1] *Transactions of the American Laryngological Association,* 1895, p. 91.

Myles's cases profuse hæmorrhage occurred on the ninth day and required ligature of the external carotid.[1] It is possible that the bleeding in such cases may come from a branch of the internal maxillary artery, or even from the cavernous sinus. It can be met by firm plugging with a long strip of 1-inch ribbon-gauze, of which the end is soaked in adrenalin or peroxide of hydrogen. Hæmorrhage is not a complication that I have ever met with, after having opened a large number of

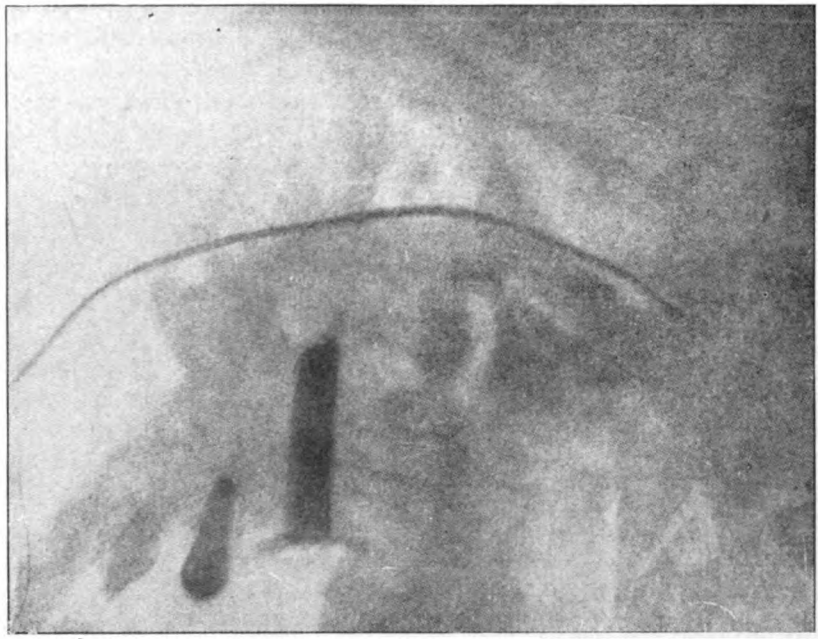

FIG. 342. RADIOGRAPH SHOWING A PROBE IN THE SPHENOIDAL SINUS. An india-rubber obturator is in the maxillary sinus.

sphenoidal cavities, and I do not think it is to be dreaded if the opening be made as directed.

The sinus is washed out with a warm normal saline solution. The addition of peroxide of hydrogen may be useful. The condition of the mucous membrane may be improved by cleansing the sinus with iodoform emulsion, or plugging it for twelve or twenty-four hours with iodoform ribbon-gauze. Any pigment can be kept in contact with the walls for some time by dipping the end of a piece of ribbon gauze into a solution of argyrol (25%) or nitrate of silver (2%) and packing it into the cavity.

[1] *Transactions of the American Laryngological Association*, 1903, p. 241.

The other end of the strip is left just within the vestibule of the nose, so that the patient can withdraw it himself.

But if a sufficient opening has been made into the cavity to allow of natural ventilation and drainage, it is well to abstain from too much local medication—particularly if there be neither polypus, necrosis, nor foreign body in the sinus, and if it be not subject to reinfection from the suppuration in the posterior ethmoidal cells. It is remarkable how, under such conditions, suppuration will cease in a sphenoidal sinus if left alone, when, if frequently treated, secretion will continue indefinitely. In my experience the sphenoidal sinus is one of the most satisfactory of the accessory sinuses to treat.[1]

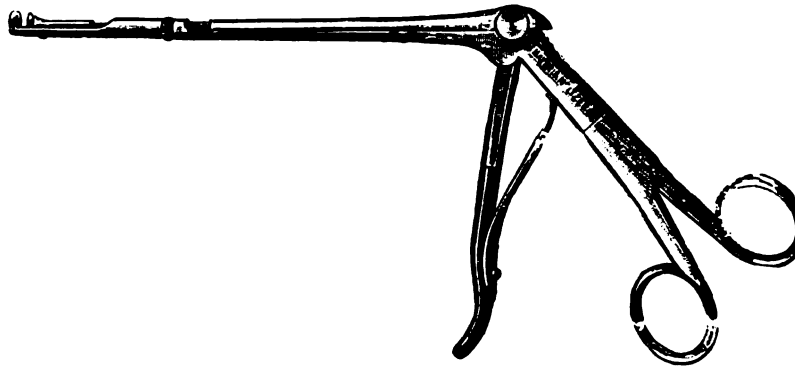

FIG. 343. SPHENOIDAL PUNCH-FORCEPS.

Other methods. The sphenoidal sinus can also be opened and treated during Killian's operation on the frontal sinus (see p. 689).

It has been proposed to approach the sphenoidal sinus by first traversing the maxillary sinus. Such a complicated route, involving extensive destruction of tissue, has no advantage over the direct and simple method described. Attempts to reach the sphenoidal sinus from the nasal part of the pharynx are not practical. This is easily seen by observing the thickness of the floor of the cavity depicted in Fig. 340.

OPERATION IN MULTIPLE SINUS SUPPURATION

Before starting treatment in a case of multi-sinusitis a complete examination should be formulated. The importance of making the differential diagnosis as complete as possible cannot be overestimated.

In initiating treatment, attention should be directed first to the

[1] *Proceed. Section of Laryn., Royal Society of Medicine,* Meeting of June, 1908; ibid., June, 1912.

ethmoidal region. The ethmoid should be attended to in all cases of suppuration in the frontal sinus. It is generally necessary, in any case, to clear it away to gain access to the sphenoidal orifice. It is well to remove it before or during operation on the maxillary sinus. The sphenoidal sinus should be catheterized, and, if infected, the orifice will require enlarging and the cavity treating. A frontal sinus should be washed out several times before deciding on a radical operation. It not uncommonly ceases to secrete after the ethmoid has been cleared.

The radical operation on the frontal sinus should not be embarked on until the ethmoid and sphenoid have been attended to. A radical frontal operation should take precedence of the maxillary, unless both cavities are operated on at the same time.

CHAPTER VI

OPERATIONS INVOLVING THE NASAL PART OF THE PHARYNX: OPERATIONS FOR RETROPHARYNGEAL ABSCESS: OPERATIONS FOR ADENOIDS

METHODS OF OBTAINING ACCESS TO THE NASAL PART OF THE PHARYNX THROUGH THE NOSE

MANY growths in the naso-pharynx, whether originating in the space or descending into it from the choanæ, can be removed by the following method.

Indications. This operation is indicated for the ordinary mucous polypus of the nose when presenting in the post-nasal space. Polypoid masses of the ethmoid may project through the posterior cavity and are removed in the same way. A naso-pharyngeal polypus (also called choanal polypus, post-nasal polypus, or benign pharyngeal polypus) is easily removed by this procedure. Innocent tumours of the post-nasal space, such as papilloma, adenoma, fibroma, and cysts, can be removed by the same method.

Under cocaine. Cocaine and adrenalin (see p. 612) should be carefully applied to the septum and conchæ, as it is the passage of the instrument from the front which is often the most painful part of the proceeding. The pharynx should be lightly sprayed with a 5% solution of cocaine so as to check reflex action.

While the patient is seated in the ordinary examination chair the surgeon stands at his left hand and introduces a looped snare (Fig. 307, p. 654) through the nostril most suitable for approaching the root of the growth. When the snare has reached the post-nasal space, the surgeon introduces the purified forefinger of the left hand through the mouth and up behind the soft palate, as in Fig. 286. Here it serves to manipulate the loop over the growth, and hold it close to the root of the pedicle while the snare is pulled home.

A few minutes should be allowed to elapse to permit the patient to recover from the unpleasant manipulation, and also to allow of coagulation of the strangulated blood-vessels. The growth should not be cut through, as it is wiser to pluck it from its attachment by a quick movement of avulsion.

The growth may come away with the snare through the nostril, or may fall into the pharynx and be expectorated.

In fairly roomy nostrils a stout polypus forceps can be used instead of the snare.

Under chloroform. In nervous subjects the same method should be carried out under a general anæsthetic, care being taken that the growth does not cause embarrassment by occluding the larynx.

Under chloroform, of course, more extensive operations can be carried out on the post-nasal space. The pedicle can be attacked with a pair of scissors with long handles, short blades, and slightly curved on the flat. These are introduced through that nostril which appears to be in most direct line with the pedicle, to act as a raspatory, and then cut through the base of the growth. In some cases an instrument such as Langenbeck's elevator (Fig. 333) will prove useful if introduced through the nostril. The growth is then removed through the mouth by a twisting movement with a strong volsella.

OPERATIONS FOR OBTAINING ACCESS TO THE NASAL PART OF THE PHARYNX THROUGH THE MOUTH

Many growths in the nasal part of the pharynx can be removed through the mouth, without preliminary operations through the face or through the hard or soft palate.

Indications. The following method of access to the nasal part of the pharynx is chiefly called for in true fibroma of the nasal part of the pharynx, otherwise called naso-pharyngeal polypus, fibroid tumour of the base of the skull, fibroid tumour of the nasal part of the pharynx, retro-maxillary polypus, or juvenile sarcoma of the nasal part of the pharynx.

It is also a plan of procedure which may be called for in any very large, innocent tumours of the nasal part of the pharynx, particularly in cases where nasal stenosis prevents access from the nostrils. It would be a suitable method in any operable cases of malignant disease of the post-nasal space.

Operation. The patient is chloroformed and placed in the position of Rose (hanging head). The mouth being propped open, and the tongue drawn forward, the tumour is explored with the forefinger, to detect and detach any secondary adhesions. A raspatory which works laterally is passed from one side of the nasal part of the pharynx to the other above the growth. A rugine which works in a sagittal plane is then introduced below the tumour and made to pass upwards behind it—the reverse movement of Gottstein's curette in the removal of adenoids (Fig. 345). This movement is facilitated by securely gripping the tumour and

dragging it forwards with a stout pair of alligator or volsella forceps. The tumour can thus be so liberated that, with some twisting movements, it can sometimes be extracted entire—often dragging down with it through the nasal part of the pharynx any prolongations thrown forward into the nose.

It is useless to attack such growths as true fibroma of the naso-pharynx with an ordinary wire snare, or such an instrument as a pair of adenoid forceps. For these firm tumours, specially powerful forceps have been designed by Doyen and Escat.

Hæmorrhage is apt to be sudden and copious, but the more rapidly and completely the growth is removed the sooner will bleeding cease—even spontaneously. After complete removal firm pressure with a marine sponge will generally check it. A post-nasal plug should be avoided, and is not usually required. Incomplete operations not only start hæmorrhage but may start septic absorption.

Modifications. (*a*) *Preliminary laryngotomy.* A preliminary laryngotomy, strongly recommended by J. W. Bond and extensively adopted by Butlin, adds nothing to the dangers of the case. It allows of the laryngeal part of the pharynx being packed, so that there is no anxiety in regard to the descent of blood into the lungs, and it permits the steady administration of the anæsthetic through the laryngotomy canula. The surgeon is thus relieved of two great anxieties, and can devote himself without embarrassment to more deliberate operation.

The laryngotomy tube can be removed as soon as the patient recovers consciousness and all hæmorrhage has ceased.

(*b*) *Division of the soft palate.* In addition to the operation of laryngotomy, the following procedure will allow of more deliberate removal.

The soft palate and uvula are carefully divided in the median line, and a silk ligature is placed through each lateral half so that they can be held forward out of the way. This gives more direct access to the post-nasal tumour, and if then found to crowd the cavity too closely to allow of manipulation, the posterior part of the hard palate can be chiselled away in the median line. At the conclusion of the operation the divided palate is carefully united in the median line.

Selection of method. In some cases operation through the mouth may have to be combined with a second operation from the front—such as the method of Moure (see p. 659) or that of Rouge (see p. 663).

Rapidity of operation is important, as, once the pedicle has been cut through, or the body of the tumour removed, the hæmorrhage tends to subside spontaneously, or is quickly controlled by packing.

The hanging-head (Rose) or the Trendelenburg position is generally ecommended.

The preliminary laryngotomy seems desirable in many cases. The division of the palate should be avoided if possible. It may not always unite, and is less likely to do so if subsequent operations are required. The soft palate is very elastic, and in some cases it can be tied out of the way by means of a soft rubber catheter passed along the floor of the nose, and out through the mouth.

Ligature of the external carotid, strongly recommended by Chevalier Jackson,[1] is not necessary unless the patient is very anæmic or weak from former hæmorrhages. It should then be only a temporary ligature.

Hæmorrhage, as already remarked, is chiefly guarded against by rapid and complete operation. The preliminary use of adrenalin and cocaine, the administration of lactate of calcium, and the other methods recommended for the prevention of bleeding (see p. 614) should be carefully attended to. But in every case preparation should be made beforehand for ligature of the external carotids and for saline infusion.

OPERATION FOR RETROPHARYNGEAL ABSCESS

Indications. The disease is serious, and when not diagnosed almost inevitably ends in death. Before the abscess bursts death may result from spasm of the glottis, laryngeal œdema, or asphyxia. The affection runs its course in 5 to 10 days, and if the abscess opens spontaneously death almost inevitably results—either from suffocation, or septic pneumonia, or cardiac failure.

Operation. When the diagnosis is settled intervention should be prompt. It is not necessary to wait for distinct fluctuation. The pus focus may be so difficult of manipulation in an infant, and the pharyngeal muscle may be so thick and indurated, that it is practically impossible, even in the later stages of retropharyngeal abscess, to detect the presence of pus by palpation.[2]

The evacuation of the abscess through the mouth was formerly looked upon as dangerous, owing to the difficulty of drainage, the fear of pus burrowing behind the œsophagus, and the risk of flooding the larynx with pus. The more difficult plan of opening it from the neck was generally recommended. The majority of cases can be opened through the mouth with perfect safety.

No general or local anæsthetic is administered, but everything necessary for an immediate tracheotomy should be ready at hand. No gag should be employed, a tongue depressor or the operator's left forefinger

[1] *The Laryngoscope*, xiv, 1904, p. 267.
[2] M. A. Goldstein, ibid., xviii, January, 1908, p. 46.

being sufficient both to keep the mouth open and act as a guide. The infant is swaddled in a shawl so as completely to control the movements of the extremities and is then laid on its side on a low pillow, and held by a trustworthy assistant. The sinus-forceps used for opening a peritonsillar abscess are thrust into the most prominent part of the swelling, and the opening enlarged by separating the blades as they are withdrawn. A slender, sharp-pointed bistoury, guarded and guided by the index-finger, may be used, instead of the forceps. The pus will pour out through the nose and mouth. The incision of the pharynx should be free, deep, and long, and directed against the posterior wall of the pharynx and as close to the median line as possible, so as to avoid any chance of wounding the internal carotid.

The surgeon may feel more security if, with the same precautions and with the patient in the same position, he first aspirates the pus cavity.

If more accustomed to it, he may also prefer to have the child flat on its back, with the head overhanging the edge of the table.

Suffocation may be so imminent when the patient is first seen that a preliminary tracheotomy is required.

The external operation, which leaves a certain scar, is reserved for some rare cases—as when the abscess is too low to be easily reached through the mouth, when the spasm of the masseters cannot be overcome, when a large pulsating vessel is noticed in front of the abscess, and when the abscess points towards the neck. It is also the suitable one for the chronic and generally tubercular form of abscess more commonly met with in older patients.[1]

The external operation is made through an incision along the posterior border of the sterno-mastoid muscle, and the dissection is carried behind the large vessels of the neck and in front of the prevertebral muscles.

After-treatment. The after-care of the patient will require consideration, since the disease is generally met with in the feeble and ill nourished.

If the abscess be opened in good time the patient is at once relieved and begins to recover rapidly.

REMOVAL OF ADENOIDS

Indications. The removal of naso-pharyngeal adenoids is not called for simply because they are accidentally discovered to be present, nor does the need of operation depend solely on the size of the growths

[1] George E. Waugh, *The Lancet,* September 29, 1906.

or the nasal obstruction they produce. Adenoids require removal whenever the symptoms attributed to them call for relief. These symptoms may be arranged in three groups, according as they are those (i) of nasal stenosis, (ii) of secondary septic infection, or (iii) of reflex effects.

(i) Amongst the first are mouth-breathing and all the numerous sequelæ, including facial, buccal, dental, and thoracic deformities. It must not be forgotten that mouth-breathing may never be present, and yet deformities of the chest or septic or reflex results can be produced by a small amount of growth in the post-nasal space.

(ii) Amongst secondary septic infections are catarrhal conditions of the auditory (Eustachian) tube and otitis media, and catarrhal infection of any part of the air-passages. Cervical glands and so-called 'glandular fever' occur in this group, as do septic gastritis and other conditions caused by the conveyance of sepsis to more distant parts.

(iii) Various reflex effects are sometimes attributable to naso-pharyngeal adenoids. Laryngismus stridulus, reflex cough, chorea, convulsions, night-terrors, enuresis nocturna, and aprosexia are some of the ailments which may justify operation on Luschka's tonsil.

As it is chiefly in children that this operation is required it is important to see that they are free from indication of infectious fevers. The operation should be postponed until any acute catarrh has subsided. If there be otorrhœa the ears should receive suitable cleansing treatment for a week or two beforehand. The condition of the teeth requires attention.

The operation is so frequently carried out in private houses that it is well to make inquiries into the health of the members of the household, recent illness, and sanitation. When possible, a large, airy room with a south aspect should be chosen.

Operation. In adults it is possible to carry out the operation under cocaine. On the Continent, particularly in hospital practice, it is often done without any anæsthetic at all. In this country general anæsthesia is almost the universal custom. Opinion is divided as to which is the safest and most suitable anæsthetic to employ.

When the removal of tonsils or other operation is not carried out at the same time, an anæsthetic of less than a minute is sufficient. In adults, and in children over 10 years of age, nitrous oxide does excellently. Younger children are apt to be alarmed by the face-piece and apparatus necessary for nitrous oxide, and this gas does not seem so suitable for them as for adults. In younger children chloride of ethyl is extensively employed on the Continent, but has not met with general favour here.

When the tonsils require removal, or any other operation on the

upper air-passages is carried out at the same time, and in young children generally, an anæsthesia allowing of more deliberation is desirable. For this, some operators employ ether,—preceded or not by nitrous oxide. But the well-known objections to pure ether in the surgery of the air-passages have caused the preference to be given to chloroform, or to one of the mixtures of chloroform and ether.

The patient should lie quite flat on the operating table, with only a low pillow or folded towel under the head. The anæsthetist, who takes charge of the gag and flexes or rotates the head as directed, stands at the end of the table. At the patient's right hand stands the surgeon, and within easy reach are his instruments, sponges, and iced water. Standing on the same side and behind him is the nurse. Her duty is to soothe the patient while passing into unconsciousness, and later on to roll him well over on to his right side as the operation finishes.

The operation can be carried out more correctly, rapidly, safely, and comfortably if the surgeon be armed with an electric forehead search-light (see p. 611). Failing this, the table should be brought close up and parallel to a window, with the patient's right hand next the light.

Surgeons differ as to the degree of anæsthesia desirable. Some like it to be quite light, so that the patient is all the time in the struggling stage and requires his hands to be controlled by the nurse. I think this is quite as dangerous as when the anæsthesia is pushed until the patient is relaxed, with the corneal reflex just abolished, and the swallowing and coughing reflexes still present.

When the anæsthetic is administered steadily, with plenty of air, a degree of unconsciousness is generally secured which will allow of an operation lasting two or three minutes without any further administration. Should the patient show signs of recovering consciousness more chloroform can be given from a Junker's apparatus.

The anæsthetist then opens the mouth with a suitable gag, such as O'Dwyer's, Doyen's, or Mason's, and maintains the patient's head exactly in the middle line of the body. Directing the electric search-light into the pharynx, the surgeon depresses the tongue with a spatula in the left hand, while with the right he holds the adenoid curette—some modification of the original Gottstein model (Fig. 344). This is best seized firmly dagger-wise (Fig. 346). It is then introduced along the tongue and slipped up into the post-nasal space. Once safely behind the soft palate and kept straight in the middle line, no harm can be done. Dropping the tongue depressor, the surgeon depresses the handle of his instrument until the beak of it is felt in contact with the posterior free margin of the septum. Pressing the cutting blade firmly and steadily along this it is swept upwards, backwards, and downwards along the

vault of the nasal part of the pharynx, while the curette revolves around an imaginary centre in its shaft (Fig. 345). As the instrument is withdrawn from the pharynx, its cage will be found to contain the adenoid growth, removed *en bloc* and generally complete (Fig. 346). Should the growth slip from the cage, or remain semi-detached from the posterior pharyngeal wall, it can be seized and lifted from the throat with a pair of post-nasal forceps (Fig. 282).

The rush of blood which now takes place is met by rolling the patient

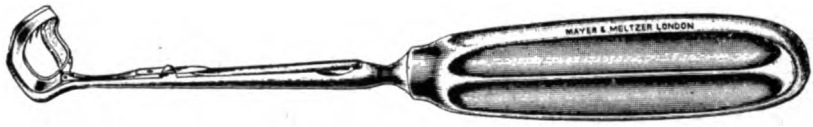

FIG. 344. ADENOID CURETTE. StClair Thomson's modification.

well over to his right side, with his face over the edge of the table, so that the blood can run into the right cheek and so out through the mouth. With the patient on his side there is no anxiety of asphyxia from descent of blood or fragments of growth into the trachea, and the surgeon can more deliberately explore the post-nasal space and, with a simple adenoid

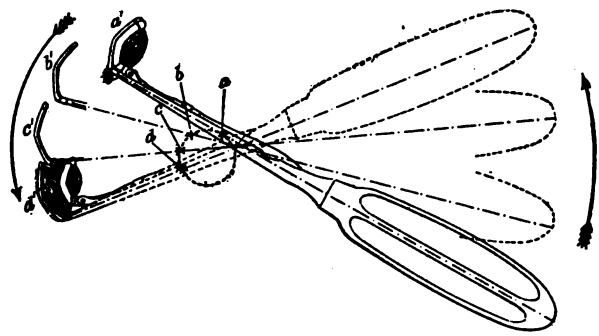

FIG. 345. THE REMOVAL OF NASO-PHARYNGEAL ADENOIDS. Semi-diagrammatic illustration to show how the curette revolves around an axis which moves from *a*, through *b* and *c*, to *d*. The growth is pressed into the fenestra of the instrument in the *a'* position, and when the sweeping movement has brought it to *d'*, it is detached and caught in the cage.

curette, remove any lateral remains of growth which may have escaped the caged curette.

Sponges are merely used to cleanse the mouth and pharynx in order to make sure that no semi-detached fragments are left behind. If present, tonsils can be conveniently removed at this stage.

Bleeding, which may be very free for a minute or two without any cause for anxiety, is promptly arrested by freely sluicing the patient's face and neck with ice-cold water.

After-treatment. The patient is put back to bed, lying well over to one side. He should not be allowed to lie on his back, or left unattended, until consciousness has returned. Collapse may occur at this time, generally as a precursor of vomiting, or blood may be vomited and then, owing to the patient's semi-conscious condition, may be drawn into the trachea.

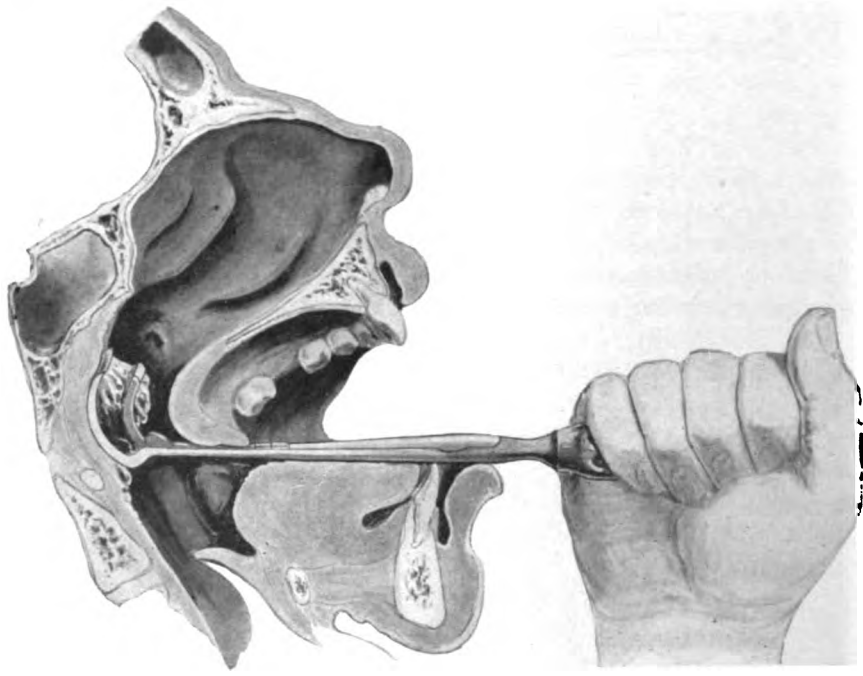

FIG. 346. REMOVAL OF NASO-PHARYNGEAL ADENOIDS. The growth is shown as partially removed from its attachment, and bulging into the cage of the instrument which opens to receive it.

Ice may be sucked. After a few hours, if there be no vomiting, barley-water, lemonade, tea, thin beef-tea, or beef jelly can be given. Milk and milky food should be avoided. An aperient should be given the same evening, as any foul breath or feverish condition is more likely to be due to blood and mucus in the stomach than to local sepsis. The mouth is kept cleansed with the tooth-brush and an alkaline wash.

It is best to avoid local treatment for the nose. At the end of a few hours the patient is encouraged to clean the nose, and if he is supplied with abundance of fresh air through freely opened windows, the wound in the post-nasal space will heal promptly without any local or general reaction. Occasionally an alkaline nose lotion is required if there has been much secondary rhinitis, or if the child be kept in vitiated air.

One day in bed is generally sufficient, and a child may be allowed out in two or three days, though fatigue should be avoided for a week. Suitable after-treatment in the way of breathing exercises, gymnastics, speech-correction, and tonics is often needed. Relief of nasal stenosis may require completion by attention to the condition of the turbinals and septum.

The operation in adults is performed under nitrous oxide. This can be carried out in exactly the same way as that already described, but some surgeons prefer to have the patient sitting up in a dentist's chair. In that case, after the removal of the mass of growth, the patient's head is thrown forward between his knees.

Difficulties and Dangers. It may be said that the operation itself, carried out with usual care and in a patient who is not a hæmophiliac, is free from danger. The chief anxiety is from the anæsthetic, and no inconsiderable number of deaths from this cause have been reported. When possible, it is well to secure the services of an expert anæsthetist who is well used to laryngological work, and accustomed to the operator's particular methods.

Hæmorrhage may be brisk, even profuse, for a few minutes, but as a rule it promptly ceases if the operation be completed, the patient well rolled to one side, the air thoroughfare left clear so as to allow free breathing and avoid congestion, and the gag removed to permit swallowing and diminish pharyngeal reflexes. The more rapidly and completely the operation is executed, the less will be the bleeding. It not infrequently originates from semi-detached fragments of growth. Even when the hæmorrhage is profuse it is better to push on and complete the removal of growth before attempting to check it. The value of free applications of ice-cold water cannot be exaggerated (see p. 614). In many cases bleeding is maintained by the surgeon's anxious efforts to stop it with sponging, pressure, or the application of styptics. The greatest danger arises in the case of hæmophiliacs. If this diathesis be undoubtedly present, the operation should be avoided. If only suspected, more care than usual should be taken in preparing the patient for operation, and lactate of calcium in 15 to 30 grain doses twice a day might be given for two or three days beforehand.

When bleeding persists it is met by keeping the patient very quiet and free from alarm, in a cool and well-ventilated room, and only lightly covered with clothes. Ice is given to suck and applied on each side of the neck, while iced cloths are applied to the face and forehead. Clots are blown out of the nose so as to permit the access of fresh cold air to the post-nasal space. With a pipette, or a pledget of cotton-wool, a few drops of adrenalin can be trickled into the nostril and allowed to run backward. If these measures fail—as they rarely do—the post-nasal space must be plugged (see p. 615). When hæmorrhage takes place after the removal of adenoids and tonsils, it will generally be found that the source of it is in the tonsillar area.

The uvula may retract strongly at the moment of introducing the curette and then get crushed against the posterior pharyngeal wall; or it may be seized by mistake with the post-nasal forceps and be torn away. The same instrument has sometimes been responsible for fracturing the posterior margin of the septum, injuring the auditory cushion, and tearing off strips of mucosa from the pharynx. These complications are avoided by using a frontal search-light, operating deliberately, and abandoning the forceps in favour of the curette. This latter instrument can be manipulated without these risks if it be first guided safely behind the uvula and then used more like a carpenter's adze than a curette. The stroke with the caged curette should be carried through in one movement and exactly in the median line of the body, but always on the posterior wall. There is no need to attempt removal of adenoid tissue on the lateral walls. This atrophies if the main mass is removed, and the lateral pharyngeal recess can be cleared out with the forefinger.

Local sepsis rarely follows if the precautions described be observed, and local douching is avoided. Any local fœtor—if not arising from the stomach—is generally traceable to some semi-detached fragment which can be removed from the posterior wall with a wire snare (Fig. 307) or a pair of forceps (Fig. 282).

Deafness, earache, and *otitis media* will sometimes follow the operation, even when the use of a nasal douche has been carefully avoided. They are best met by warm applications, disinfection of the ear with carbolic lotion (5%), and early incision of the drum under nitrous oxide gas.

Other methods of operation. Removal through the nasal chambers—the route originally used by Meyer for his ring-knife—is not to be recommended.

Treatment of the growth with the galvano-cautery, introduced through the mouth, is difficult, risky, and unsatisfactory.

The use of Loewenberg's forceps, or some modification (Fig. 282), is generally abandoned by any one who has become accustomed to the Gottstein's curette. A small pair of forceps is, however, very serviceable in quite young children in whom the post-nasal space may be so small as to prevent the manœuvring of any form of curette.

The position with the extended head over the end of the table—Rose's position—increases the congestion and hæmorrhage, and by throwing forward the cervical vertebræ makes the approach to the roof of the naso-pharynx more difficult.

INDEX

Abdomen, infection of the, in malignant disease of the breast, 103
Abscess:
cerebellar, operations for, 499, 505
symptoms of, 498
cerebral, following frontal sinus operation, 691
extra-dural, operations for, 461
hepatic, operation for, 189
intracranial, otitic, operations for, 497, 499
intramammary, operation for, 99
lacrimal, incision of, 321
mammary, acute, operations for, 99
mastoid, Bezold's, operation for, 414
subperiosteal, operation for, 414
mediastinal, operations for, 126
nasal, operation for, 653
orbital, opening of, 325
premammary, operations for, 99
pulmonary, operation for, 158
etiology of, 158
external bursting of, 159
tuberculous, operation for, 162
retromammary, operations for, 100
retropharyngeal, operation for, 705
septal, operation for, 653
subdiaphragmatic, operation for, 185
temporo-sphenoidal, opening of, 501
symptoms of, 498
thoracic, operations for, 122
trephining for, 500
tuberculous, operations for, 162
Acoustic canal, *see* Auditory canal
nerve, intracranial division of the, 458
Actinomycosis of the lungs, operation for, 166
Adenoid curette, 709
revolving around axis, semi-diagrammatic illustration of, 709
Adenoidectomy, 707
post-operative treatment, 710
Adenoids, naso-pharyngeal:
galvano-cautery in the treatment of, 712
removal of, 706
cut showing, 710
difficulties and dangers of, 711
indications for, 706
through the nasal chambers, 712
Adhesions, intratympanic, division of, 366
Adrenalin in:
aural operations, 334
indirect laryngoscopy, 515
nasal operations, 612, 613, 615
nasopharyngeal operations, 702
ophthalmic operations, 197
serous effusions, 138
Advancement of levator palpebræ muscle for ptosis, 296
ocular muscles, for squint, 275
complications of, 278
Age:
influence of, in the etiology of malignant disease of the breast, 101
in relation to operations for hypospadias, 3
for misplaced or retained testis, 38
sarcoma of the breast, 116
Air and other fluids, substitution of, for serous effusions in pleurisy, 137
Air-passages, lower, protection of, during operations, 616
upper, table showing operations upon the, 550
Alkalinity test in meningitis of otitic origin, 465
Alveolar margin, puncturing the maxillary sinus from the, 659
Amputation of anterior end of inferior concha, 627
lower margin of inferior concha, 628

Amputation of posterior end of inferior concha, 629
the penis, complete, 25
partial, 21
Anæsthesia in:
adenoidectomy, 707
aural operations, 334
laryngectomy, total, 536
laryngoscopy, direct, 520
indirect, 515
laryngotomy, infrathyreoid, 551
nasal operations, 612, 613, 615
nasopharyngeal operations, 702
operation for mammary carcinoma, 69, 89
ophthalmic operations, 196
thyrotomy, 527
tracheoscopy, 600
tracheotomy, 583
Anæsthesia, intratracheal, Meltzer-Auer, 133
turbinotomy, complete, 631
Anæsthetic solutions (Neumann's) for aural operations, 335
Anatomy of the:
anterior segment of the eye, 207
breast, surgical, 61
crystalline lens, surgical, 206
eyelids, surgical, 287
labyrinth, surgical, 449
laryngeal lymphatics, 534
larynx and trachea, cut showing, 563
mastoid area, surgical, 398
surface, 400
ocular chambers, surgical and pathological, in relation to glaucoma, 238
sphenoidal sinus, surgical, 694
trachea, surgical, 562
tympanum, surgical, 359
Aneurysm, aortic, perforating the trachea, 581
Angular spring forceps, aural, 330
tracheotomy tube in the trachea, skiagram showing, 557
Ankyloblepharon, operations for, 288
Anterior chamber of the eye:
angle of the, in chronic glaucoma, opening up, 241
in recent glaucoma, cut showing, 240
evacuation of the, 213
normal, cut showing, 239
paracentesis of the, 257
Anterior sclerotomy, 249
Anterior synechiæ, division of, 248
Antrum, maxillary, *see* Maxillary sinus
Antrum of Highmore, *see* Maxillary sinus
Aorta, aneurysm of the, perforating the trachea, cut showing, 581
Aperture, palpebral, operations upon the, 289
Aphakia, 208
Apparatus:
Boyle and Gask's intratracheal ether, 554
Brauer's, 131
for intratracheal insufflation, 134
high-pressure, indications for use of, 132, 177, 191
low-pressure, indications for use of, 129, 169, 177, 191
Kuhn's peroral intubation, 554
McKeown's, for irrigation of anterior chamber of the eye, 223
of Perthes, for post-operative treatment of empyema, 145
Sauerbruch's, 130
Aqueous, loss of, a complication of lens extraction, 226, 228
Arachnoid, exposure of the, in Haynes's operation, cut showing, 472
Argyll Robertson's operation for ectropion, 306
Arlt's operation for trichiasis, 302
Arm, lymphatic œdema of the, in carcinoma of the breast, 80, 105, 115
position of the, after operation for carcinoma of the breast, 84
Artery, innominate, ligature of the, 122
pulmonary, removal of clots from the, 181
trachea showing ulceration into, after tracheotomy, cut showing, 580
Artificial eye, 281, 283, 284, 285
Asch's cutting scissors for septal operations, 640
operation for septal deformities, 639
Asepsis in nasal operations, 618
Aspiration:
continuous, in post-operative treatment of empyema, 145

Aspiration: (*Cont.*)
in the treatment of empyema, 138
milky effusion into the chest, 157
pleural effusions, 136
Aspirator, bottle, 127, 136
for bronchoscopy, 602
for locating lung abscess, 158
needles or trochars, for exploring chest, 127
Astigmatism, a complication of glaucoma iridectomy, 246
Atresia of the external auditory canal, operations for, 354
Atropine, use of, in acute iritis, 228
in couching, 230
in direct laryngoscopy, 521
in extraction of the crystalline lens, 220
Attic, lateral wall of the, removal of the, 381
punch forceps, 381
region, polypus arising from, cut showing, 358
suppuration, and caries of the ossicles, sites of perforation in, 375
surgical anatomy of the, 359
syringing out of the, 332
Attic wall, Dench's operation upon the, 386
Auditory canal, external, operations upon the, 338
for atresia, 354
furunculosis, 338
stenosis, 352
removal of exostoses from the, 340
of foreign bodies from the, 346
polypi from the, 355
Auditory tube:
catheterization of the, 388
examination of the pharyngeal orifice of the, direct, 388
lavage of tympanum through the, 396
operations upon the, 388
Aural:
forceps, 330, 348
instrument, Burkhardt-Merian's, 339
mirror, 329
polypus, operations for, 355
probe, 356
scissors, 348
snare, Wilde's, 356
specula, 330
Avulsion, in removal of aural polypus, 355
Axenfeld's retractor for excision of the lacrimal sac, 319
Axilla, dissection of the, 62, 75, 86
Axillary glands, infection of, in carcinoma of the breast, 103, 106

Babinsky's test in cerebellar abscess, 498
Bailey's dilator for laryngotomy, 550
Baker's (Morrant) tracheotomy tube, 566
Ballance's method of skin-grafting after mastoid operation, 430
'stopper' for pushing in aural skin-graft, 432
Ballenger's swivel septum knife, 647
Bandages, ocular, 204
Barber's (Cresswell) nasal saw, 637
Barr's (Stoddart) method of placing skin-grafts after mastoid operation, 435
Baudet's method in seminal vesiculectomy, 55
Bayonet knife for submucous resection, 644
Beck's method in operation for hypospadias, 8
Beck's skin implantation in the treatment of empyema, 155
Belfield's method in vasotomy, 53
Bezold's mastoid abscess, operation for, 414
Bilton Pollard's empyema tube, 144
Bismuth paste in the treatment of empyema, 147
Bleeding in nasal operations, control of, 614
Blood-pressure test in meningitis of otitic origin, 466
Blood-supply to the eyelids, source of, 287
Bond's preliminary laryngotomy in naso-pharyngeal operations, 704
Bone-forceps, for frontal sinus operations, 687
Bönninghaus's operation upon the maxillary sinus, 678
Bottle aspirator, 127, 136
blowing into a, in post-operative treatment of empyema, 145
operation for hydrocele, 33

Bougie, eustachian, passage of the, 394
Boyle and Gask's intratracheal ether apparatus, 554
Brauer's cardiolysis, 180
Brauer's high-pressure apparatus, 131, 132
Brawny swelling of the arm, in breast carcinoma, 80, 104, 115
Breast:
abscess of the, acute, operations for, 99
anatomy of the, surgical, 61
carcinoma of the, 61
acinous, 102
acute, 110
adenopathy in, 64, 86, 102, 106, 113
arm, position of the (Cotterill), after operation, 84
atrophic scirrhus, 109
average duration of life after appearance of, 114
axillary lymphatic glands in, 66
brawny swelling of the arm in, 80, 104, 115
Cheatle's sign in, 106
choice of cases for operation for, 113
cicatrix left after complete operation for, 81
clinical classification of, 101
columnar-celled or duct, 102
death in, causes of, 114
diagnosis, 107
differential, 107
from chronic mastitis, 107
cyst, 108
fibro-adenoma, 108
gumma, 108
scarring, 109
tubercle, 108
diffuse, 102
dimpling of the skin in, 104, 105
dissemination of, 64, 102, 113
duct or columnar-celled, 111
en cuirasse, 68, 104, 113
etiology of, 101
exploratory incision in, 112
fracture of the femur in, 105
frozen sections, importance of, in diagnosis, 105, 112
fungating, treatment of, 86
Breast, carcinoma of the: (*Cont.*)
glandular implication in, 64, 86, 102, 106, 113
Halsted's operation for, 67, 87
Handley's lymphangioplasty in, 80
operation for, 65, 71
histogenesis, 63, 102
impalpable, 110
indications and contra-indications for operation, 68, 113
inoperable, treatment of, 114
local dissemination of, 64
'lump in the breast,' in, 105, 108
lymphatic obstruction in, 104
mastitis in relation to, 96
medullary or soft, 101, 109
metastases in, 63, 88, 90, 91, 102, 103, 105, 114, 125
microscopic varieties of, 102
mobile, 110
nipple, retraction of, 104, 105, 108
operative treatment, 68
anæsthetic, the, 69
choice of cases for, 113
principles of, 112
statistics of, 89
technique, 69
pachydermia, cancerous, 68, 104, 113
palliative operations in, 68
peripheral, 109
permeation and infiltration contrasted, 103
'pig-skin' or peau d'orange in, 104, 105, 106
post-operative treatment of, 84, 114
processes concerned in, 104
prognosis, 89, 114
recurrence of, in the chest-wall, 125
recurrence of, 91
Rodman's exploration of neck in mammary growths, 88
scirrhus, 101
scirrhus, atrophic, 109
skin area removed in operation for, 65
skin grafts, gutta-percha tissue covering of, 83
skin grafts, silver foil cover-

Breast, carcinoma of the: (*Cont.*)
ing of, Johns Hopkins Hospital method, 83
spheroidal-celled, 102
Stiles's method of operating, 69
supraclavicular glands, question of removing the, 87, 113
Halsted's theory concerning, 87
Meyer's theory concerning, 88
symptoms of, pathological classification of, 104
first noticed by patient, 105
treatment of, inoperable:
drug, 115
open-air, 115
radium, 115
X-rays, 114
treatment of lymphatic œdema of the arm, 115
treatment, local, of ulcerated growths, 116
treatment operative:
influence of variety on prognosis, 91
modifications of, or additions to the, 86
preparation of the patient, 68, 69
prognosis of, 89
skin incision, 69, 70, 71
statistics of, 89
technique, 69
treatment, post-operative, 84, 114
ulcerating, 86, 107, 116
unusual forms of, 109
varieties of, microscopic, 102
visceral dissemination in, 103, 105
Warren's incisions, 82, 96
cysts of the 91, 95, 108
disease of the, malignant, 101
etiology of, 101
excision of the, without opening the axilla, 91
fat transplantation in cystic disease of the, 97
fibro-adenomatous growths of the 92, 95, 108
inflammations of the, 91, 95, 99, 107
Breast, carcinoma of the: (*Cont.*)
Kanavel's plastic restoration of the, 97
lymphatic system of the, 63
male, carcinoma of the, 68, 111
malignant disease of the, 101
operations upon the, for abscess, 99
after-treatment, 84
anæsthetic, 69
complications, 89
dangers, 89
dressing of wound, 83
extensive disease in the axilla, 86
modifications, or additions, 86
mortality statistics, 89
prognosis as regards permanent recovery, 89
removal of the supraclavicular glands, 87
ulcerating or fungating, 86
parenchyma, chemical demonstration of the, 61
fibro-adenomatous growths, 91, 95, 108
for cysts, 91, 95
inflammations, 91, 95, 99
sinuses, 100
partial resection of the, 95
pathological changes in cancer of the, 63
phlegmonous inflammations of, 99
plastic restoration of the, Kanavel's technique, 97
sarcoma of the, clinical symptoms of, 116
dissemination of, 116
etiology, 116
treatment, 117
scirrhous cancer of the, Heidenhain's theory concerning epithelial changes in, 63
sinuses of the, 100
surgical anatomy of the, 61
Breast tissue, distribution of the, 61
extent of, 62
Bronchial tree, skiagram of, 599
Bronchiectasis, cavity resulting from, 161
operations for, 160
sequelæ of, 161
theories of the production of, 160
Bronchitis, chronic, exciting cause of bronchiectasis, 160

Broncho-pneumonia, a complication of thyrotomy, 532
after tracheotomy, 579
Bronchoscopes, 600
Bronchoscopy, complications of, 603
indications for, 598
instruments for, 600, 601, 602
lower, 603
lower, with patient in dorsal position (cut), 605
results of, 606
upper, 602
upper, with patient in dorsal position (cut), 604
Brudenell Carter's method for iridectomy, 238
Bruenings's bronchoscope, 600
counter-pressure method for laryngeal examination, 521
Bruns, *see* von Bruns
Bucknall's operation for hypospadias, 10
Bulb, jugular, exposure of the, 490
Buphthalmos, results of iridectomy in, 240
anterior sclerotomy in, 249
Burghard's method for vasorrhaphy, 36
method for orchido-cœlioplasty, 39
modification of Bucknall's operation for hypospadias, 13, 14
Burkhardt-Merian's aural instrument, 339
Burow's operation for entropion, 300
Burr, use of, in the removal of aural exostoses, 344
Butlin's after-treatment in thyrotomy, 532
laryngectomy operations, 545
preliminary largyngotomy in naso-pharyngeal operations, 704
tube and introducer for laryngotomy, 550
Button-holing of the iris, 221

Calcareous films, ocular, scraping, 267
Calculi, nasal, removal of, 626
Caldwell-Luc radical operation upon the maxillary sinus, 672
Caloric test of labyrinth, 445
Canal, acoustic, *see* Auditory canal
auditory, *see* Auditory canal
Canal, lacrimal, operations upon the, 314
Canaliculi, lacrimal, dilatation of the, 314
incision of the, 315
obliteration of the, 318
Canaliculus dilator, 315
knife, 315
Cancer, *see* Carcinoma
Cancer *en cuirasse*, or cancerous pachydermia, 68, 104, 113
Cancer of the breast, *see* Breast, carcinoma of the
Canine fossa, opening into the maxillary sinus from the, 672
operation through the, 672
Canthoplasty, 289
Canthorrhaphy, 289
Canthotomy, 289
Canula for laryngotomy, 551
in the frontal sinus, radiograph showing, 682
Krause's for nasal operations, 623
Capsule, of the crystalline lens, evulsion of the, 214
opening of the, in cataract extraction, 218
Capsulotomy, 211
indications and contra-indications for, 211
Carbolic acid, liquefied, in sterilization of ophthalmic instruments, 202
Carcinoma:
atrophic scirrhus, 109
columnar-celled or duct, 102
diffuse, 102
duct or columnar-celled, 111
en cuirasse, 68, 104, 113
fungating, 86
impalpable, 110
infiltration and permeation contrasted, 103
mammary, 61, 101
medullary, 101, 109
mobile, 110
of the breast, *see* Breast, carcinoma of the
of the chest-wall, 125
of the male breast, 111
of the penis, amputation for, complete, 25
partial, 21
of the seminal vesicles, treatment, operative, 52

Carcinoma: (*Cont.*)
permeation and infiltration contrasted, 103
scirrhus, 101
spheroidal-celled, 102
ulcerating, 86
varieties of, 101
Carcinomatosis, peripheral, 109
Cardiolysis (Brauer), 180
Caries of the bony walls of the thorax, operations for, 122
ossicles and attic suppuration, sites of perforation in, 375
ribs, operations for, 122
Carter's (Brudenell) method for optical iridectomy, 238
Cartilaginous deformity of the nose, operation for, 641
Castration, 38, 45, 48
Cataract:
discission in the treatment of, 208
extraction, 202
iridectomy in, 217
opening the capsule in, 218
without iridectomy, 221
needling of, 208
secondary, operation for, 211
Smith's operation for extraction, 224
Catheter, eustachian, 389
Catheterization of the auditory tube, 388
Catheterizing the frontal sinus, 679
maxillary sinus, 667
sphenoidal sinus, 697
Caulk's method in Vaso-epididymotomy, 56
Cauterization of the cornea, 264
granulations in the tympanum, 372
Cavities, nasal, *see* Nasal cavities
Cerebellar otitic abscess, opening of, 498, 505
Cerebral abscess following frontal sinus operation, 691
Cerebro-spinal fluid in meningitis of otitic origin, examination of, 464
Cervical glands, excision of, 87
Chair, Mayou's, for the localization of foreign bodies in the eye, by X-rays, 260
Chamber, anterior, *see* Anterior chamber
Chancre, penile, soft, circumcision for, 16
Cheatle's sign in carcinoma of the breast, 106
Chest exercises in post-operative treatment of empyema, 145
exploration of the, technique, 127
injuries of the, treatment, operative, 121
Chest-wall, tumours of the, removal of, 124
Cheyne's (Watson) statistics of operated cases of breast carcinoma, 89
testicle frame, 41
Chiari and Bec's method for total laryngectomy, 540
Chisel, Killian's triangular curved, for frontal sinus operations, 686
Chloroform for adenoidectomy, 708
aural operations, 334
direct laryngoscopy, 520
infrathyreoid laryngotomy, 551
nasal operations, 658
naso-pharyngeal operations, 703
operations for carcinoma of the breast, 69, 89
ophthalmic operations, 196
sequestrotomy, 635
thyrotomy, 527
tracheotomy, 565
tuberculosis of the nose (curettage of), 636
Choanæ, congenital occlusion of the, operation for, 623
Christian and Sanderson's method of anastomosing the vas, 56
Chylothorax, operations for, 157
Cicatricial ectropion, operations for, 307
Cicatrix after complete removal of mamma, 82
Circumcision, 16
after-treatment, 19
Cisterna magna, opening of the, in meningitis, cut showing, 472
Citelli's bone-forceps for frontal sinus operations, 687
Clamp, lid, 301
Clar's lamp, for aural examination, 329
Cleansing the ear, method of, 331
nose, method of, 619
Clip, tongue, use of, in nasal operations, 658
Clots, removal of, from pulmonary artery, 181
Cocaine for:
adenoidectomy, 707

Cocaine for: (*Cont.*)
aural operations, 334
laryngoscopy, direct, 520
indirect, 515
nasal operations, 612
nasopharyngeal operations, 702
ophthalmic operations, 196, 197
sterilization of, preparatory to ophthalmic operations, 201
substitutes for, in nasal operations, 613
thyrotomy, 527
tracheotomy, 583
Cochlea, removal of the, 454
'Cold method' of paraffin injection in operations upon the eye-socket, 284
Collins's (Treacher) entropion forceps, 300
Complete mastoid operation, 417
turbinotomy, 631
Concha, inferior, amputation of the anterior end of the, 627
lower margin of the, amputation of the, 628
middle, operations upon the, 632
posterior end of the, removal of the, 629
Conchæ, operations upon the, 626
Concretions, nasal, removal of, 626
Congenital glaucoma, iridectomy for, 240
occlusion of the anterior opening of the nostrils, operation for, 622
choanæ, operation upon, 623
Conical cornea, operations for, 265
Conjunctiva, expression of the, 269
follicular formations in the, removal of, 269
foreign bodies in the, removal of, 268
operations upon the, 268
pterygium of the, operation for, 268
Conjunctivoplasty, 269
Contracted eye-socket, operations for, 285
Cooper, suspensory ligaments of, 61, 64
Cord and scrotum, operations upon the, 30
Cornea, cauterization of the, 264
conical, operations for, 265
operations upon the, 264
removal of foreign bodies from the, 264
Cornea, calcareous films of the, scraping, 267
tatooing the, 267
tumours of the, removal of, 267
Cotterill's (Edward) position of arm after operation for carcinoma of the breast, 84
Couching, 230
complications of, 231
Counter-pressure method of laryngeal examination, 521
Cresswell Barber's nasal saw, 637
Crico-tracheotomy, 568
Crocodile forceps for aural operations, 348
Crystallin, of crystalline lens, 206
Crystalline lens, operations upon the, 206
surgical anatomy of the, 206
three weeks after needling, cut showing, 206
Cuneo's description of the anatomy of the laryngeal lymph vessels, 534
Curette, adenoid, 709
for the auditory tube, Pfau's, 421
Curetting of aural polypi, 358
of labyrinth, 450
of tympanic granulations, 372
Cushing's (Harvey) blood-pressure test in meningitis of otitic origin, 466
Cyclitis, a complication of couching, 231
sympathetic, after intra-ocular operations, 199
Cyst, *see* Cysts
Cystic hygroma of chest-wall, operation for, 125
Cystoid scar after iridectomy for glaucoma, 203, 204
in chronic glaucoma, Lagrange's operation for the production of, 253
Cysts:
dermoid, of the thorax, operation for, 167
diagnosis of, from carcinoma of the breast, 108
echinococcus, of the lung and thorax, operation for, 167
hydatid, of the lung and thorax, operation for, 167
of the breast, operation for, 95
tarsal, removal of, 270

Dakin's solution in the treatment of empyema, 139
Deformities, septal, operations for, 637
Deformity, septal, combined bony and cartilaginous, operation for, 641
Delstanche's ring-knife for removal of the malleus, 378
Dench's operation upon attic wall, 386
Denker's operation upon the maxillary sinus, 678
Denonvillier's operation for ectropion, 308
Dermoid cysts, of the lung, operation for, 167
cysts of the thorax, operation for, 167
patches, of the cornea, removal of, 267
Desault's operation upon the maxillary sinus, 672
Detacher, dull-edged, for nasal operations, 645
Detachment of the retina, operation for, 257
Deviation of the nasal septum, simple, operations for, 638
De Vincentiis's operation for repair of eyelids, 311
Diaphragm, operations upon the, 184
Dieffenbach's operation (modified with the use of ear cartilage) for replacing loss of eyelid, 312
Dilatation of external auditory meatus, 352
of lacrimal canaliculi, 314
Dilator, Bailey's, for laryngotomy, 550
canaliculus, 315
Diphtheria, intubation versus tracheotomy in, 588
tracheotomy in, 556, 565
mortality statistics of, 552, 582
Direct laryngoscopy, Killian's method, 517
Discission for after-cataract, 211
or needling of the lens for cataract, 208
for its removal for high myopia, 209
Drainage of the cisterna magna in meningitis of otitic origin, 470
of the internal ear in meningitis of otitic origin, 470
Drainage, through nasal wall only, in operation upon the maxillary sinus, 679
through the vertebral canal, in meningitis of otitic origin, 470
Drain, lymph, establishment of, in abnormal conditions of the eye, 255
Dressings, ocular, 204
Drills, maxillary sinus, 669
Drug treatment of carcinoma of the breast, 115
Duct carcinoma, 111
lacrimal, probing and syringing the, 316
Ducts, semicircular, *see* Semicircular ducts
Duel and Wright's blood examinations in middle-ear suppuration, 476
Duplay's classical operation for epispadias, 8, 15
Dura mater, incision through the, in meningitis, 471
Durham's tracheotomy tube, 566
Duval's method in seminal vesiculectomy, 55
(Pierre) method for removal of foreign bodies from the lung, 164
Dysdiadokokinesis, Babinsky's test in cerebellar abscess, 498

Ear:
and mastoid process, left temporal bone showing anatomy of the (cut), 399
cleansing the, 331
examination of the, 329
external, *see* Auditory canal, external
furunculosis of the, 338
internal, *see* Labyrinth, Cochlea, Semicircular ducts, and Vestibule
middle, anatomical preparation of the, 360
middle, *see also* Tympanic cavity, Ossicles, Mastoid operation, and Auditory tube
operations upon the, 329
general considerations with regard to, 333
position of the patient and surgeon, 337

Ear: (*Cont.*)
removal of foreign bodies from the, 346
suppuration, blood examinations in, 476
syringing the, 332
Echinococcus cysts of the lung and thorax, 167
Ectropion, active or cicatricial, operations for, 307
operations for, 303
passive, operations for, 304
Effusions, serous, operations for, 136
Electro-cautery operation for conical cornea, 266
in cauterization of the cornea, 265
Electrolysis in the treatment of trichiasis, 299
Electro-magnet, giant, for the extraction of steel particles from the eye, 263
small, for the extraction of steel particles from the eye, 261
operations upon the eye, 261
Electroscopes for laryngoscopy, 518
Elevation of old nasal fractures, 622
Elevators, periosteal, for operations upon the frontal sinus, 686
Elliott-Fergus operation, trephining the sclera, 250
Elliott's trephine, 250
Emphysema, surgical, operations for, 121
Empyema, chronic:
etiology, 146
operations for, 147
Beck's method (skin implantation), 155
Estlander's method, 150
Robinson's method (muscle implantation), 150
Schede's method, 150
complete unilateral, operation for, 139
double, operation for, 146
operations for, 138
resulting from dermoid cyst, 168
treatment of, apparatus used in, 136
post-operative, 144
tube, Bilton Pollard's, 144
Enchondroma of the ribs, operation for, 124
of the sternum, operation for, 124
Endolaryngeal operations, 513
Entropion, operations for, 299
Enucleation of the globe of the eye, and allied operations, 279
complications, 281
Epididymectomy, 45
Epididymitis, 50
Epiglottis, transfixing the, Horsford's instrument for, cut showing, 516
Epispadias, Duplay's operation for, 15
operation for, 14
Epithelioma of the penis, amputation for, complete, 27
Epithelium of breast parenchyma, precancerous proliferative changes in the, 63
Erythropsia, a complication of lens extraction, 229
Eserine, use of, after lens extraction, 222
in anterior sclerotomy, 249
Esmarch and Kowalzig's method in operation for hypospadias, 8
Estlander operation for chronic empyema, 150
Ether apparatus, intratracheal, 554
Ether in adenoidectomy, 708
aural operations, 334
operations for carcinoma of the breast, 69, 89
Ethyl chloride in adenoidectomy, 707
turbinotomy, complete, 631
Eucaine in aural operations, 392
nasal operations, 613
Eustachian bougie, passage of the, 394
catheter, 389
tube, *see* Auditory tube
Evacuation of the anterior chamber of the eye, 213
Evisceration of the contents of the globe of the eye, 281
of the orbit, 325
Evulsion of the lens capsule, 214
Examination of the ear, methods of, 329
of the nose, methods of, 609
Excision of aural polypus, 355
apex of conical cornea, 265
breast, 68
partial, 95
lacrimal gland, palpebral part of, 322
orbital part of, 323
sac, 318
stricture of external auditory meatus, 353
tunica vaginalis, for cure of hydrocele, 31

Exercises, chest, in post-operative treatment of empyema, 145
Exostoses, removal of, from the external auditory meatus, 340
Exploration of the chest, 127
orbit, Krönlein's, 323
Exposure of the jugular bulb, 490
jugular vein, 485
transverse sinus, 483
Expression of the conjunctiva, 269
External auditory canal, *see* Auditory canal, external
meatus, operations for stenosis of the, 352
removal of exostoses from, 340
skin-grafting through, 435
Extirpation of the labyrinth, 453
Extraction of cataract, 212
in capsule, Smith's operation, 224
foreign bodies from the conjunctiva, 268
cornea, 264
crystalline lens, 214
lens, 214
lungs, 163
ocular globe, 259
incus, 379
Extradural abscess, operation for, 461
Extra-laryngeal operations, 525
comparative results of, 540
history of, 540
Extra-ocular muscles, operations upon the, 275
Eye, anterior chamber of the, evacuation of the, 213
anterior segment of the, anatomy of the, 207
artificial, 281, 283, 284, 285, 290
bandage, 204
of the, pressure, 204
globe of the, *see* Globe, ocular
lens of the, operations upon the, 206
methods of purification of, preparatory to operation, 200, 201
operations upon the, general considerations applicable to, 195
general preliminaries to, 195
local preparation of the patient for, 199
speculum, 209
suspensory ligament of the, function of the, 207
Eyelid, attachment of the, to the epicranius muscle, 292
clamp, 301
grafting a portion of the superior rectus into the, 297
shortening the, by excision of a portion of the tarsus, Fergus's operation (modified), 291
Eyelids, œdema of the, establishment of new lymph paths for the relief of, 255
operations upon the, 287
repair of the, 299
repair of large losses of substance from the, 311
surgical anatomy of the, 287
union of the, indications for, 290
wounds of the, suture of, 287
Eye-socket, operations for the restoration of a contracted, 285
operations upon the, 284
paraffin injections into the, 284

Fat transplantation in cystic disease of the breast, 97

Femur, fracture of the, in carcinoma of the breast, 105
Fergus's operation for ectropion, 304
operation (modified) for ptosis, 291
Fibro-adenoma, diagnosis of, from carcinoma of the breast, 108
Fibro-adenomatous growths of the breast, 92, 95, 116
Films, calcareous, ocular, scraping, 267
Fistula, biliary, in relation to empyema, 146, 156
bronchial, in relation to empyema, 146, 156
test of labyrinth, 445
Fixation forceps for steadying the eye in needling the lens, 209
Flaps, inclusion of, in operations upon contracted eye-socket, 285
post-meatal skin, formation of, in mastoid operation, 426
reflection of, in the operation for carcinoma of the breast, 71, 73
transplantation of, for ectropion, 308
Fluids, in the pleural cavities, removal of, 127
Fluoroscope for locating lung abscess, 158

Föderl's method for total laryngectomy, 540
Follicles in the conjunctiva, removal of, 269
Forceps, attic, punch, 381
aural, 330
bone, *see* Bone-forceps
crocodile, for aural operations, 348
fixation, ocular, 209
Graddy's, 269
iris, 215
Luc's nasal, 657
nasal dressing, 625
nasal punch, 623
Ostrone's punch-, for operations upon the maxillary sinus, 675
Pfau's attic punch, 381
post-nasal, 624
Prince's, for advancement, 276
sphenoidal punch-, 700
Thorner's, for intubation of the larynx, 592
Treacher Collins's entropion, 300
Foreign bodies:
in relation to empyema, 157
in the bronchi, operation for, 598
conjunctiva, removal of, 268
cornea, removal of, 264
ear, removal of, 346
eye, localization of, by X-rays, 260
heart, operations for, 171, 173
larynx, operation for, 515, 517
thyrotomy for, 526
lung, incident to warfare, 164
removal of, 163
nose, removal of, 614
ocular globe, removal of, 259
trachea, tracheoscopy for, 598
Formalin and glycerine solution in the treatment of empyema, 139
Fossa, canine, *see* Canine fossa
Fractures, nasal, operations for, 621
of the nasal bones and septum, operations for, 621
Frazier's operation for intracranial division of the acoustic nerve, 459
Fricke's operation for ectropion, 309
Frontal searchlight for nasal operations, 611
Frontal sinus, catheterizing and washing out the, 679
Killian's operation upon the, 683
Kuhnt's operation upon the, 694
Frontal sinus, Ogston-Luc's operation upon the, 692
suppuration in the, operation for, 683
Frost's operation for enucleation of the eye, 283
Frozen sections, importance of, in diagnosis of cancer of the breast, 105, 112
Fuller's method in vasotomy, 54
Fungi, effect of, on the lung, 166
Furunculosis, of the ear, operations for, 338
Furunculotome, Hartmann's, 338

Gag, O'Dwyer's, for intubation of the larynx, 592
Galliard Thomas's method, in partial resection of the mamma, 95
Galvano-cautery in the treatment of adenoids, 712
perforation of the tympanic membrane, 364
Gask and Boyle's intratracheal ether apparatus, 554
Genitals, male, operations upon the, 3
Giant electro-magnet for operations upon the eye, 263
Glands, axillary, infection of, in malignant disease of the breast, 86, 103, 105, 106
inguinal, question as to the removal of, in amputation of the penis, 21, 24
lacrimal, operations upon the, 322
supraclavicular, enlargement of, in carcinoma of the breast, 87, 90, 113, 114
removal of, in operations upon the breast, 67, 87, 90, 113, 114
Glaucoma, a complication of couching, 231
lens extraction, 229
acute, a complication of operations for conical cornea, 266
chronic, Lagrange's operation for, 253
congenital, 240
establishment of new lymph paths for the relief of, 256
iridectomy, 238
Lagrange's operation for, 253
primary, 239
secondary, 240

Glaucoma, silk drains for, 256
surgical and pathological anatomy of, 238
Gleason-Watson operation for deformity of the septum, 639
Globe, ocular, enucleation of the, 279
evisceration of contents of the, 281
incisions in the, direction of, 202
operations upon the, 258
wounds in the general considerations as to making and healing of, 201
Gluck's laryngectomy operation, 538, 541
Godlee's vertical incision in empyema, 141
Gonorrhœa, acute, involving epididymis treatment, operative, 50
involving seminal vesicles, treatment, operative, 52
Graddy's forceps, 269
Grafting the superior rectus into the eyelid, 297
Granulations of the tympanum, removal of, 372
Gray's anodyne solution for aural operations, 334, 374
Greenough, Simmons, and Barney's statistics of operations for carcinoma of the breast, 90
Gruber's aural speculum, 330
Grunert's operation upon the jugular bulb, 491
Gumma, diagnosis of, from carcinoma of the breast, 108

Hæmatocele of the tunica vaginalis, castration in, 49
Hæmatoma, nasal, operation for, 653
Hæmorrhage, in breast carcinoma operations, 84, 89
bronchiectasis, 162
glaucoma iridectomy, 245
hydrocele, radical cure of, 32
nasal operations, control of, 614
sclerotomy, 252
Hajek's bone-forceps, for frontal sinus operations, 687
Halsted's operation for carcinoma of the breast, 67, 87
statistics of operations for carcinoma of the breast, 87, 89
Handley's silk drain in lymph obstruction (lymphangioplasty), 80, 115, 255
Handley's technique for total laryngectomy, 540
theory concerning dissemination of carcinoma, 64
Hands, surgeon's, sterilization of, preparatory to ophthalmic operations, 201
Harman's operation for ptosis, 293
Harmar's skiagrams of laryngeal tumours, 514
Harrington's solution, for sterilization of the skin, 69
Hartmann's furunculotome, 338
Hayes's speculum, for examination of the pharyngeal orifice of the auditory tube, 388
Haynes's operation for meningitis of otitic origin, 471
Hearing, influence of mastoid operation on, 441
tests of labyrinth, 446
Heart, operations upon the, repair of wounds by, 171
Heath's (Charles) complete mastoid operation, 426
Heidenhain's theory of epithelial changes in scirrhous cancer of the breast, 63
Hemi-laryngectomy, 533
for malignant disease, recurrence after, 544
mortality after, 544
Hepatic abscess, operation for, 189
Hernia, congenital, and undescended testis, association of, 45
inguinal, castration in, 48
of the lung, operation for, 122
Hess's operation for ptosis, 292
High-pressure operation, upon the thorax, 129, 131, 132
High tracheotomy, 569
Hook, incus, Ludewig's, 380
Zeroni's, 380
Hooks for bronchoscopy, 602
Horsford's instrument for transfixion of the epiglottis, 516
Hydatid disease of the lung and thorax, operation for, 167
Hydrocele, bottle operation for, 33
radical cure of, 30
treatment, operative, complications and results of, 32
Hygroma, cystic, of the chest-wall, operation for, 125
Hypochondriasis, sexual, in relation

to operative treatment for varicocele, 33
Hypopyon, following intra-ocular operations, 199
a complication of lens extraction, 228
Hypospadias, operations for, 3
Bucknall's operation for, 10

Illumination in aural operations, 329
nasal operations, 609
Impalpable carcinoma, 110
Impotence due to operations upon the vesicles, 55
Imray's scoop for extraction of foreign body from the ear, 349
Incision, exploratory, in carcinoma of the breast, 112
for removal of part or the whole of the breast, 92
skin, the complete operation for carcinoma of the breast, 69
the Thomas-Meyer, in operations upon the breast, 93
for exposure of the jugular vein, 485
plastic restoration of the breast, 97
submucous resection of the septum, 644
in acute suppuration of the attic, 362
the Caldwell-Luc operation upon the maxillary sinus, 673
cataract extraction, 217
orbital abscess, 325
operation for empyema, 139
vertical, 141
of the external auditory meatus, 352
the globe of the eye, 202
the lacrimal canaliculi, 315
the tympanic membrane in acute suppuration of the middle ear, 361
Wilde's post-aural, 402
Incisions, in intratympanic operations, lines of, 365
Galliard Thomas's, in operation upon the breast, 95
in Hayne's operation in otitic meningitis, 471, 472
lateral rhinotomy, 310
operations upon larynx and trachea, cut showing, 563
Incisions, skin, in post-aural operations, 405
through intratympanic adhesions, 367
Warren's, in operations upon the breast, 82, 95, 96
Incus, extraction of the, 379
hook, Ludewig's, 380
Zeroni's 380
removal of the, 375
Indirect laryngoscopy, 515
Infant, mastoid operation in the, 414
Infection of the axillary glands in carcinoma of the breast, 86, 103, 105, 106
supraclavicular glands in carcinoma of the breast, 87, 90, 107, 113, 114
Inferior concha, operations upon the, 627
Infrathyreoid laryngotomy, *see* Laryngotomy, infrathyreoid
Inguinal glands, removal of the, in amputation of the penis, 24
Injection, intrapulmonary, in tuberculous disease, 163
of paraffin into the eye-socket, after removal of the eye, 284
Injuries, nasal, operations for, 621
of the chest, operations for, 121
diaphragm, repair of, 184
great vessels, treatment of, 121
lung, treatment of, 121
thorax, operations for, 121
Insane, the use of couching in the, 230
Instruments for bronchoscopy, 601, 602
for intubation of the larynx, 592
sterilization of, preparatory to ophthalmic operations, 201
Insufflation, intratracheal, technique of, 134
Insufflator, Leduc's, 517
Intracranial complications of otitic origin, 460
division of the acoustic nerve, 458
otitic abscess, operations for, 497, 499
after mastoid operation, 501
after-treatment, 507
prognosis, 508
recurrence of symptoms of, 509
Intratracheal anæsthesia, Meltzer-Auer method of, 133

Intratracheal anæsthesia, ether apparatus, 554
insufflation, technique of, 134
Intratympanic operations, 366
adhesions, divisions of, 366
general considerations with regard to, and their results, 366
lines of incisions in, 365
Intubation apparatus, Kuhn's peroral, 554
of the larynx, 588
after-treatment of, 595
complications of, 597
difficulties of, 594
indications for, 591
instruments for, 592
technique, 592
versus tracheotomy in diphtheria, 588
tube, 'retained,' 597
Ipecacuanha in the treatment of dysenteric hepatitis, 191
Iridectomy, 235
for glaucoma, 238
prolapse of the iris, 247
for small growths of the iris, 246
glaucoma, 238
complications, 243
in cataract extraction, 217
optical, 235
Brudenell Carter's method, 238
preliminary, in lens extraction, 223
Irido-cyclitis, 199
a complication of glaucoma iridectomy, 246
chronic, a complication of lens extraction, 228
following ocular incision, 203
Iridotomy, 232
Kuhnt's method, 233
Ziegler's method, 234
Iris, anterior synechiæ of the, division of, 248
avulsion of the, a complication of lens extraction, 226
button-holing of the, 221
forceps, 215
growths of the, iridectomy for, 246
operations upon the, 232
prolapse of the, a complication of anterior sclerotomy, 249
glaucoma iridectomy, 246
iridectomy for, 247
scissors, 215
transfixion of the, 247
Iris bombé, iridectomy indicated in, 240
Iritis, acute, a complication of lens extraction, 228
Irrigation, delivery of crystalline lens by, 223
Ischæmia, local, for nasal operations, 613

Jackson's bronchoscope, 601
(Chevalier) lamp for direct laryngoscopy, 518
laryngectomy operations, 544
rectal etherization in thyrotomy, 527
Jansen's intratympanic operation, 452
Johns Hopkins Hospital method of covering skin grafts in operation for carcinoma of the breast, 83
statistics of radical operations for carcinoma of the breast, 87, 90
Joints, chronic involvement of the, vesiculotomy in the treatment of, 52
Jones's (Wharton) operation for ectropion, 308
Jugular bulb, exposure of the, 490
vein, ligature of the, 482

Kanavel's technique for plastic restoration of the breast, 97
Keratitis, striate, a complication of lens extraction, 229
Killian's apparatus for direct laryngoscopy, 518
bronchoscope, 601
nasal speculum, 698
operation upon the frontal sinus, 683
triangular curved chisel, for frontal sinus operations, 686
Knife, bayonet, for submucous resection of the septum, 644
Ballenger's swivel septum, 647
canaliculus, 315
Delstanche's ring, 378
for paracentesis tympani, 361
tenotomy, Schwartze's, 371
Kopetzky's test for meningitis of otitic origin, 465
Körner's post-meatal flaps, in mastoid operation, 427
Kowalzig's incisions in operations for hypospadias, 8

Krause's canula, for nasal operations, 623
trocar, for nasal operations, 623
Krönlein's method for exploration of the orbit, 323
Kuhn's peroral intubation apparatus, 554
Kuhnt's iridotomy operation, 223
operation (modified) for ectropion, 305
upon the frontal sinus, 694
Küster-Bergmann (Schwartze-Stacke) mastoid operation, 418

Labyrinth, caloric test, 445
curetting the, 450
extirpation of the, 453
fistula test, 445
hearing tests, 446
rotation test, 444
operations upon the, 443
methods of, 449
general considerations, 443
indications for, 447
vestibulotomy, 451
surgical anatomy of, 449
tests, Bárány's, 444
Labyrinthitis, non-suppurative, operation for, 447
spontaneous nystagmus in, 445
suppurative, operation for, 447
Lacrimal abscess, incision of, 321
apparatus, operations upon the, 314
canals, obliteration of the, operations for, 318
duct, probing the, 316
syringing the, 316
glands, operations upon the, 322
obstruction, insertion of styles for relief of, 317
operations for, 314
sac, excision of the, 318
Lack's tube for laryngeal stenosis, 579
Lagophthalmos, operation for, 305
Lagrange's operation for glaucoma, 253
Lake's (Richard) operation upon the labyrinth, 447
rubber splint, for septal operations, 640
Lamp, Clar's, for aural examination, 329
for nasal operations, 610
laryngoscope, 610
Nernst projection, 197
Lamps for direct laryngoscopy, 518
Lang's eye speculum, 200
Laryngeal lymphatics, anatomy of, 534
stenosis after tracheotomy, 577
Laryngectomy, hemi-, 533
total, 536
after-treatment, 538
Butlin's cases, 545
Chiari and Bec's method for, 540
Föderl's method for, 540
Gluck's operation, 538
Handley's technique for, 540
modifications, 538
mortality after, 544
recurrence after, 545
swallowing after, 548
technique of, 536
voice after, 546
Laryngo-fissure for the treatment of papillomata, 523
Laryngoscope lamp, 610
Laryngoscopy, direct, 517
diagnostic use of, 518
indirect, 515
Laryngotomy, instruments for, 550
infrathyreoid, 548
complications, 552
preliminary to naso-pharyngeal operations, 704
Larynx:
and trachea, anatomy of the, cuts showing, 563
examination of the, Bruening's counter-pressure method of, 521
foreign bodies in the, operation for, 515, 517
thyrotomy for, 526
intubation of the, 588
technique, 592
lymphatics of the, anatomy of the, 534
multiple papillomata of the, operation for, 517
operations upon the, 515
papillomata of the, radium in the treatment of, 524
tracheotomy for the cure of, 522
stenosis of the, thyrotomy for, 525
tubercle of the, thyrotomy for, 526
tuberculosis of the, operation for, 514, 518
tumours of the, extrinsic, 525, 526
innocent, 513
intrinsic, 525, 526

Larynx, tumours: (*Cont.*)
malignant, 513
skiagram showing, 514
thyrotomy for, 526
Lash-bearing area, transplantation of the, 302
Lateral rhinotomy, *see* Rhinotomy, lateral
Lavage of the tympanum, 396
Leduc's insufflator, 517
Lens, crystalline:
capsule, evulsion of the, 214
chemical composition of the, 206
delivery of the, in cataract extraction, 218
preventive factors in, 219
by irrigation, 223
discission of the, for cataract, 208
dislocation of the, a complication of extraction, 226
extraction of the, indications for, 214
in its capsule, 223
Smith's operation for, 224
modifications of operation for, 220
subconjunctival, 225
complications, 226
without iridectomy, 221
operations upon the, 206
for high myopia, 209
indications and contraindications for, 209
surgical anatomy of the, 206
Levator palpebræ muscle, advancement of the, for ptosis, 296
Lichwitz's and Moritz Schmidt's maxillary sinus needles, 668
Lid clamp, 301
Lid margin, suture of wounds of the, 287
Lids, operations upon the, 287
Ligament, anterior tympanic, division of, 365
Ligaments of Cooper, suspensory, 61, 64
Ligature, for removal of aural polypus, 357
of the jugular vein, 482
of the vessels in operation for carcinoma of the breast, 80
Light, frontal search-, 611
Liver, abscess of the, operations for, 189
indications, 189
Local anæsthesia, in aural operations, 334
nasal operations, 612
preparation of the patient, for operations upon the eye, 199
Lower bronchoscopy, 603
Low-pressure operation, upon the thorax, 129
Low tracheotomy, 571
Lucae's probe for massage of the malleus, 374
Luc's nasal forceps, 657
Ludewig's incus hook, 380
Lumbar puncture for meningitis of otitic origin, 464, 469
'Lump in the breast,' in carcinoma of the breast, 105
Lung, extirpation of the, for tuberculous disease, 163
foreign bodies in the, removal of, 163
hernia of the, treatment, 122
surgery, present status of, concerning removal of foreign bodies, 164
Lungs, abscess of the, operations for, 158
tuberculous, operation for, 162
actinomycosis of the, operation for, 166
cavity in, resulting from bronchiectasis, operation for, 160
dermoid cysts of the, operation for, 167
hydatid disease of the, operation for, 167
operations upon the, 158
tuberculous abscess of the, operation for, 162
tumours of the, removal of, 169
wounds of the, treatment, 121
Lymphangioplasty, in treatment of lymphatic œdema of the arm, 80, 115
œdema of the eyelids, 255
Lymphatic obstruction in breast cancer, 104
Lymphatics, infection of the, in carcinoma of the breast, 66, 67, 86, 87, 102, 103, 104, 105, 106, 107, 113, 114
intramammary, anatomy of the, 63, 64
laryngeal, anatomy of the, 534

Lymphatics, obstruction of, in breast cancer, 80, 104, 105, 115
of the breast, anatomy of the, 63
retromammary, anatomy of the, 64
Lymph paths, ocular, establishment of new, by means of subcuticular silk thread drains, 255

McKeown's apparatus for irrigation of anterior chamber of the eye, 223
method for removal of the crystalline lens, 223
Magnet electro-, operations upon the eye, 261
Male, carcinoma of the breast, in the, 111
genital organs, operations upon the, 3
Malignant disease in relation to empyema, 146, 157
of the breast, 101
tumours, thyrotomy for 525
Malleus and incus, removal of the, 375
direct massage of the, 373
Mamma, *see* Breast
Manson's (Sir Patrick) method, in opening hepatic abscess, 191
Martin's method in vaso-epididymotomy, 56
Massage, direct, of the malleus, 373
of the stapes, 374
Mastitis, chronic, diagnosis of, from carcinoma of the breast, 107
acute, diagnosis of, from acute carcinoma of the breast, 110
operations for, 91, 95, 99
diagnosis of, from mammary abscess, 110
in relation to carcinoma of the breast, 96
Mastoid abscess, Bezold's operation for, 414
area, surgical anatomy of the, 398
surface anatomy of the, 400
cells, surgical anatomy of the, 399
necrosis, operation for, 415
operation for removal of foreign bodies from the ear, 351
for subperiosteal abscess, 414
history of the, 400
in an infant, 414
post-aural incisions in, cut showing, 405
Mastoid operation, Schwartze's method, 403
skin-grafting after, 430
Wilde's incision in, 402
the complete, 416
after-treatment of, 436
closure of the wound after, 429
difficulties and dangers of, 438
methods of, 417
methods of Küster-Bergmann (Schwartze-Stacke), 418
Heath's, 426
methods of Schwartze-Stacke, 418
Stacke's method, 423
Wolf's, 422
post-meatal flaps in, use of, 426
preservation of the ossicles and tympanic membrane after, 424
results of, 440
the 'radical,' 416
process, operations upon the, 398
osteomyelitis of the, 415
Maxillary antrum, *see* Maxillary sinus
Maxillary sinus, access to the, by extension of Rouge's operation, 666
Bönninghaus's operation upon the, 678
Caldwell-Luc operation upon, 672
catheterizing the, 667
Denker's operation upon the, 678
Desault's operation upon the, 672
drainage of, through nasal wall, 678
drills, 669
needles, 668
nozzle, 669
opening the, from the nose, 674
operation through canine fossa upon, 672
operations upon the, 667
puncturing the, from the alveolar margin, 669
puncturing the, from the nose, 667
radical operation upon the, 672

Maxillary sinus, Rouge's operation extended, allowing access to, 666
washing out the, from an alveolar opening, 670
Maxwell's operation upon contracted eye-socket, 285
Mayou's chair for the localization of foreign bodies in the eye by the X-rays, 260
Mayo's (C. H.) operation for hypospadias, 8
(W. J. and C. H.) operation for vasorrhaphy, 36
silk drain in detachment of the retina, 257
glaucoma, 256
Meatus, external, *see* External auditory meatus
Median tracheotomy, 571
Mediastinum and thoracic wall, operations upon the, 121
Mediastinum, abscess of, operations for, 126
sarcoma of the, removal of, 170
tumours of the, removal of, 169, 170
Medullary or soft carcinoma, 109
Meltzer-Auer intratracheal anæsthesia, 133
Membrane, tympanic, *see* Tympanic membrane
Meningitis, otitic, 464
alkalinity test in, 465
blood-pressure test in, 466
Haynes's operation for, 471
Kopetzky's test in, 465
lumbar puncture for, 464
operations for, 464
post-operative treatment of, 468
prognosis and after-results of, 473
Mercury perchloride of, use of, preparatory to ophthalmic operations, 200
Metastases, in carcinoma of the breast, 63, 88, 90, 91, 102, 103, 105, 114, 125
Meyer's nasal splint, 622
statistics of operations on carcinoma of the breast, 90
theory concerning the removal of the supraclavicular glands, 88
Micro-organisms, cause of sepsis after ophthalmic operations, 199
Middle concha, operations upon the, 632
Middle ear, anatomical preparation of the, 360
Milligan's intratympanic syringe, 332
Mirror, aural, 329
Mobile carcinoma, 110
Mobilization of the ossicles, 373
Mortality after hemi-laryngectomy, 544
thyrotomy, 542
total laryngectomy, 544
in carcinoma of the breast, 88, 89, 114
Motais's operation for ptosis, 297
Moure's and Rouge's operations, combination of, for nasal growths, 666
operation for lateral rhinotomy, 659
septal deformities, 639
Mules's operation after evisceration of the intraocular contents, 283
Muller's retractor for excision of the lacrimal sac, 319
Multi-sinusitis, operation in, 700
Muscle implantation, Robinson, in the treatment of chronic empyema, 150
Muscles, extraocular, operations upon the, 271
Mycosis, pulmonary, 166
Myopia, discission of the lens in, 209
Myringotome, 339
Myxo-sarcoma, of the chest-wall, 125

Nares, anterior, congenital occlusion of the, operations for, 622
Nasal bones, operations for fracture of, 621
cavities, methods of obtaining direct access to the, 659
growths, removal of, 654
by forceps and curettes, 656
by snare, 654
punch-forceps, 623
saw, 637
scissors, 628
septum, abscess of the, operation for, 653
deformities of the, operations for, 637
denudation of the, 646
deviation of the, operations for, 638
hæmatoma of the, operation for, 653

Nasal bones, operations upon the, 637
Asch's method, 639
Gleason-Watson's method, 639
Moure's method, 639
perforating the, 638
perforation of the, operation for, 651
spurs of the, removal of, 637
submucous resection of the, 641
sinuses, accessory, operations upon the, 667
snare, 654
speculum, 698
splint, hollow vulcanite, 622
spokeshave, 631
syphilis, the results of, operations for, 634
Naso-pharynx, adenoids of the, removal of, 706
examination of the, 609
methods of obtaining direct access to the, 659
access to, through the mouth, 703
nose, 702
operations involving the, 702
modifications, 704
post-syphilitic adhesions of the, operations for, 635
Necrosis, mastoid, operation for, 415
of the bony walls of the thorax, operations for, 122
Needle, hollow, use of, in paracentesis of the anterior chamber of the eye, 258
Needles, maxillary sinus, 668
or trochars, aspirator, for exploring chest, 127
tattooing, 267
Needling of the crystalline lens, 208
Nernst projection lamp, 197
Nerve, acoustic, intracranial division of the, 458
Neumann's anæsthetic solutions, 335
aural syringe, 335
method of opening the vestibule, 454
subcutaneous injection for aural operations, 334
Nipple, retraction of the, in carcinoma of the breast, 104, 105, 108
Nitrous oxide for adenoidectomy, 707
complete turbinotomy, 631
in operation for nasal abscess, 653
Nose, abscess of the, operation for, 653
and accessory cavities, operations upon the, 609
cleansing the, 619
deformities of the, operations for, 637
examination of the, methods of, 609
foreign bodies in the, removal of, 624
fractures of the bones of the, operations for, 621
hæmatoma of the, operation for, 653
injuries to the, operations for, 621
operations upon the, 609
operation upon the, results of, 620
post-operative treatment, 619
rhinoliths in the, removal of, 626
semi-diagrammatic transverse section of the, 651
spurs of the, removal of, 637
syphilitic affections of the, operations for, 634
tuberculosis of the, operation for, 636
Nostrils, occlusion of the congenital, operations for, 622
Novocaine for nasal operations, 613
for endolaryngeal operations, 515
nasal operations, 613
ophthalmic operations, 197, 299
Nozzle, maxillary sinus, 669
Nystagmus, spontaneous, in labyrinthitis, 445

Obliteration of the lacrimal canaliculi, operations for, 318

Obturators, use of, in alveolar drainage of the maxillary sinus, 669
Occlusion of nostrils, congenital, operations for, 622
Ocular chambers, surgical and pathological anatomy of the, in relation to glaucoma, 238
muscles, advancement of the, for relief of squint, 275
tenotomy of the, 272
Œdema of the arm, establishment of new lymph paths for the relief of, 80, 115
eyelids, establishment of new lymph paths for the relief of, 255

O'Dwyer's gag for intubation of the larynx, 592
tubes for intubation of the larynx, 592
Ogston-Luc operation upon the frontal sinus, 692
Open-air treatment of carcinoma of the breast, 115
Opening of the lateral sinus, 478
sphenoidal sinus, 697
Operating tables, for ophthalmic operations, 198
theatres, for ophthalmic operations, 198
Operation:
Argyll Robertson's, for ectropion, 306
Arlt's, for trichiasis, 302
Asch's, upon the septum, 639
Baudet's, seminal vesiculectomy, 55
Bevan-Wolfer, orchidopexy, 42
Bezold's, for mastoid abscess, 414
Bönninghaus's, upon the maxillary sinus, 678
Bond's, infrathyreoid laryngotomy, 548
Bucknall's, for hypospadias, 10
Burghard's, for hypospadias, 13
Burghard's, orchido-cœlioplasty, 38
Burghard's vasorrhaphy, 36
Burow's, for entropion, 300
Caldwell-Luc's, upon the maxillary sinus, 672
Carter's (Brudenell), iridectomy, 238
Caulk's, vesiculectomy, 56
Chiari and Bec's, total laryngectomy, 540
Christian and Sanderson's, anastomosing the vas, 56
Denonvillier's, for ectropion, 308
Denker's, upon the maxillary sinus, 678
Desault's, upon the maxillary sinus, 672
De Vincentiis's, for ectropion, 311
Dieffenbach's, repair of large losses of substance from the eyelids, 312
Duplay's, for hypospadias, 8
Duval's, seminal vesiculectomy, 55
Elliott-Fergus, trephining the sclera, 250
Esmarch and Kowalzig's, for hypospadias, 8
Operation: (*Cont.*)
Estlander, for empyema, 150
Fergus's, for ectropion, 304
Fergus's (modified), for ptosis, 291
Föderl's, total laryngectomy, 540
Frazier's intracranial division of the acoustic nerve, 459
Fricke's, for ectropion, 309
Frost's, enucleation of the eye, 283
Fuller's, vasotomy, 54
Galliard Thomas's, partial resection of the breast, 95
Gleason-Watson, for deformity of the septum, 639
Gluck's total laryngectomy, 538, 541
Godlee's, for empyema, 141
Grunert's, upon the jugular bulb, 491
Halsted's, for carcinoma of the breast, 67, 87
Handley's, total laryngectomy, 540
Harman's, for ptosis, 293
Haynes's for meningitis of otitic origin, 471
Heath's (Charles), mastoid, complete, 426
Hess's, for ptosis, 292
Jackson's, laryngectomy, 544
Jansen's, intratympanic, 452
Jones's (Wharton), for ectropion, 308
Kanavel's plastic restoration of the breast, 97
Killian's, upon the frontal sinus, 683
Körner's, mastoid, 427
Kowalzig's, for hypospadias, 8
Krönlein's, exploration of the orbit, 323
Küster-Bergmann, mastoid, 418
Kuhnt's, for ectropion, 305
Kuhnt's, upon the frontal sinus, 694
Kuhnt's, iridotomy, 233
Lagrange's, for glaucoma, 253
Lake's (Richard), upon the labyrinth, 447
Manson's (Sir Patrick), opening hepatic abscess, 191
Martin's, vaso-epididymotomy, 56
Maxwell's, for contracted eye-socket, 285

Operation: (*Cont.*)
Mayo's (C. H.), for hpyospadias, 8
Mayo's (W. J. and C. H.) vasorrhaphy, 36
McKeown's, removal of the crystalline lens, 223
Motais's, for ptosis, 297
Moure's, upon the septum, 639
Moure's and Rouge's, for nasal growths, 666
Mules's, after evisceration of the intra-ocular contents, 283
Ogston-Luc's, upon the frontal sinus, 692
Panas's, for ptosis, 295
Panse's, mastoid, 429
Piffl's, upon the jugular bulb, 491
Politzer, division of the anterior ligament of the tympanum, 365
Richards's, extirpation of the labyrinth, 453
Robinson's, for chronic empyema, 150
Robinson's for post-syphilitic affections of the naso-pharynx, 635
Rouge's (sublabial rhinotomy), 663
Rouge's and Moure's, for nasal growths, 666
Russell's (Hamilton), for hypospadias, 8
Schede's, for chronic empyema, 150
Schwartze's, mastoid, 403
Schwartze-Stacke, mastoid, 418
Semon's, for thyrotomy, 543
Smith's, extraction of the lens in its capsule, 224
Snellen's suture, for passive ectropion, 304
Spencer's, for post-syphilitic affections of the naso-pharynx, 635
Squier's vasotomy, 53
Stacke's, mastoid, 423
Stiles's, for carcinoma of the breast, 69
Streatfeild's, for entropion, 300
Thomas's (Galliard), partial resection of the breast, 95
Thomson's (St. Clair), for septal deformities, 648
Operation: (*Cont.*)
Tilley's, for post-syphilitic adhesions of the velum, 635
Tod's, mastoid, 427
Trendelenburg's, removal of clots from the pulmonary artery, 181
Villeneuve's, seminal vesiculectomy, 55
Voelcker's, vasotomy, 54
V-Y, for ectropion, 308
Warren's, for carcinoma of the breast, 82, 95, 96
West and Scott's, vestibulotomy, 451
Wharton Jones's, for ectropion, 308
Wilde's, for removal of aural polypus, 356
Wilde's, post-aural, 402
Wolf's, complete, mastoid, 422
Wolf's, for ectropion, 311
Young's, seminal vesiculectomy, 55
Ziegler's, iridotomy, 234
Operations:
Endolaryngeal, 513
by direct laryngoscopy, 517
by indirect laryngoscopy, 515
extra-laryngeal, 525
intratympanic, 366
lines of incision in, 365
mastoid, complete, 416
ophthalmic, 195
general preliminaries to, 195
sepsis following, 199
squint, 198
for advancement of ocular muscles, 275
for ankyloblepharon, 288
atresia of external auditory meatus, 354
aural polypus, 355
carcinoma of the breast, choice of cases for, 113
principles of the, 112
ectropion, 303
entropion, repair of the eyelids, trichiasis, and ectropion, 299
epispadias, 14
extradural abscess, 461
hypospadias, 3
intracranial abscess of otitic origin, 497
lacrimal obstruction, 314
meningitis of otitic origin, 464

Operations: (*Cont.*)
nasal deformities, 637
nasal injuries, 621
obliteration of the lacrimal canals, 318
ptosis, 291
the restoration of a contracted eye-socket, 285
inclusion of flaps (Maxwell's operation), 285
skin grafting, 285
stenosis of the external meatus, 352
symblepharon, 288
transplantation of the lash-bearing area, 302
transverse sinus thrombosis of otitic origin, 474
wounds of the ocular globe, 258
upon the accessory nasal sinuses, 667
auditory (Eustachian) tube, 508
cornea and conjunctiva, 264
diaphragm, 184
ear, 327
external acoustic canal, 338
extra-ocular muscles, 271
eyelids, 287
globe of the eye, 279
heart, 171
iris, 232
jugular bulb, 490
vein, 482
labyrinth, 443
lacrimal apparatus, 314
glands, 322
larynx and trachea, 511
lens, 206
lungs, 158
male genital organs, 3
mastoid process, 398
Wilde's incision, 402
Schwartze's operation, 403
nasal septum, 637
nasal sinuses, accessory, 667
naso-pharynx, 702
nose and its accessory cavities, 609
orbit, 323
ossicles, 373
palpebral aperture, 289
penis, 3
sclera, 249
scrotum and cord, 30
socket after the removal of the eye, 284
testicle, 38
Operations: (*Cont.*)
thoracic wall and its contents, 121
trachea, 556
tympanic membrane and within the tympanum, 359
Ophthalmia, sympathetic, 199
Opium in the treatment of breast carcinoma, 115
Optical iridectomy, 235
Orbit, abscess of the, incision of, 325
evisceration of the, 325
exploration of the, 323
operations upon the, 284, 323
Orbital abscess, opening an, 325
portion of lacrimal gland, removal of, 323
Orchido-coelioplasty, 38
Orchidopexy, 38
Ossicles, caries of the, and attic suppuration, sites of perforation in, 375
massage of the, 373
mobilization of the, 373
operations upon the, 373
preservation of the, after mastoid operation, 424
removal of the, 375
surgical anatomy of the, 359
Osteomyelitis of mastoid, operation for, 415
Ostrone's punch-forceps, for operations upon the maxillary sinus, 675
Otitis, intracranial complications in, 460

Pachydermia, cancerous, 68, 104, 113
Pagenstecher's spoon, 215
Pain, indication for surgical treatment of seminal vesicles, 52
Palate, soft, *see* Soft palate
division of the, preliminary to naso-pharyngeal operations, 704
Palpebral aperture, operations upon the, 289
portion of lacrimal gland, removal of, 322
Panas's operation for ptosis, 295
Panophthalmitis, a complication of lens extraction, 227, 229
after intra-ocular operations, 199
Panse's post-meatal flaps, in mastoid operation, 429
Papillomata, laryngeal, multiple, operation for, 517

Papillomata, radium in the treatment of, 524
tracheotomy for the cure of, 522
laryngo-fissure for the treatment of, 523
Paracentesis of the anterior chamber of the eye, 257
pericardium, 178
tympani, 360
knife for, 361
Paraffin injection into eye-socket, 284
Paralysis, a complication of tracheotomy, 579
cardiac, after tracheotomy, 581
Parenchyma, chemical demonstration of breast, 61
Parker's tracheotomy tube, 566
Partial resection of the mamma, 95
Passive ectropion, operations for, 304
Penetrating wounds of the globe of the eye, operations for, 258
Penis, amputation of the, 19
complete, 25
partial, 21
difficulties and dangers, 25
operations upon the, 3
circumcision, 16
for epispadias, 14
hypospadias, 3
straightening the, 8
Perforating the septum, 638
Perforation, artificial, of the tympanic membrane, 364
of the nasal septum, operation for, 651
Pericardium, cardiolysis for adhesions of the, 180
opening of the, 178
operations upon the, 171
paracentesis of the, 178
Peripheral carcinoma, 109
Periosteal elevators, *see* Elevators, periosteal
Periosteum elevator used in operation for empyema, 140
Permeation and infiltration contrasted, 103
Perthes, apparatus of, used in post-operative treatment of empyema, 145
Pfau's attic punch forceps, 381
curette for the auditory tube, 421
Pharynx-naso, *see* Naso-pharynx
Phimosis, 16
Phlebitis, in relation to operative treatment for varicocele, 33
Pifft's operation upon the jugular bulb, 491
Pig-skin or peau d'orange, in lymphatic œdema in breast cancer, 104, 105, 106
Pipette for sucking air and fluid from beneath skin-graft after mastoid operation, 433
Plastic operations upon the eyelids, 311
orbit, 285
penis, 3
restoration of the breast, 97
Pleura, tumours of the, 125
Pleural cavities, operations upon for chronic empyema, 146
chylothorax, 157
empyema, 138
exploration of the chest for, 127
low-pressure and high-pressure, 129
serous effusions, 136
thoracoplasty, 147
removal of fluids from, 127
Pleurisy, exciting cause of bronchiectasis, 160
Plexus of Sappey, subareolar, 63
Politzer's division of anterior tympanic ligament, 365
Pollard's (Bilton) empyema tube, 144
Polypus, attic, cut showing, 358
aural, operations for, 355
naso-pharyngeal, removal of, 702, 703
Post-aural operation, *see* Mastoid operation
Posterior sclerotomy, 254
Post-meatal skin flaps, formation of, in mastoid operation, 426
Post-syphilitic affections of the nose and naso-pharynx, operations for, 634, 635
Preliminary tracheotomy, 527, 562
Preparations for eye operations, 195
Primary glaucoma, iridectomy for, 239
Prince's forceps for advancement, 276
Probe, aural, 356
Lucae's, for massage of the malleus, 374
Probing the lacrimal duct, 316
Prolapse of iris, iridectomy for, 247
Prostate, enlarged, castration in, 49
Protection of the lower air-passages during operations, 616
Protector, aural, Stacke's, 419
Pterygium, operation for, 268
Ptosis operations, 291

Pulmonary abscess, operations for, 158
actinomycosis, operations for, 166
artery, operations upon the, 171
removal of clots from the, 181
Puncture of the lateral ventricle in meningitis of otitic origin, 470
Puncturing the maxillary sinus from the alveolar margin, 669
from the nose, 667
Purification of the eye, methods of, preparatory to operation, 200
Pus, indication for surgical treatment of seminal vesicles, 52
Pyopericardium, mistaken for empyema, 179

Quinine in the treatment of amœbic abscess, 192

Radical cure of hydrocele, 30
operation upon the maxillary sinus, 672
Radiograph, *see also* Skiagram
of the sphenoidal sinus, 695, 696, 699
showing canula in the frontal sinus, 682
showing probe in the sphenoidal sinus, 699
value of, in operations upon the frontal sinus, 680
Radium treatment of carcinoma of the breast, 115
laryngeal papillomata, 524
Rectification of faulty curvature of tarsus, 300
Recurrence of malignant disease after breast operations, 90, 91, 114
hemi-laryngectomy, 544
thyrotomy, 543
total laryngectomy, 545
'Red vision,' a complication of lens extraction, 229
Removal of:
adenoids, 706
clots from the pulmonary artery, 181
cochlea, 453
eye, operations upon socket after, 284
foreign bodies from the conjunctiva, 268
cornea, 264
ear, 346
Removal of: (*Cont.*)
globe of the eye, 259
lung, 163
nose, 624
lateral wall of attic, 381
malleus and incus, 375
nasal growths, 654
ossicles, 375, 385
rhinoliths, 626
spurs from the nasal septum, 637
stapes, 385
tarsal cysts, 270
tube after tracheotomy, 574
tumours of the chest-wall, 124
lung, 169
mediastinum, 170
Resection of the septum, submucous, 641
trachea, 585
Respiration, in bronchiectasis, 162
'Retained tube,' after laryngeal intubation, 597
Retina, detachment of the, a complication of couching, 231
lens extraction, 227
the use of silk drain for the relief of, 257
Retractor, Axenfeld's, for excision of the lacrimal sac, 319
Muller's, for excision of the lacrimal sac, 319
Retropharyngeal abscess, operation for, 705
Rib, caries and necrosis of, operations for, 123
question of advisability of removal of portion of, in operation for empyema, 140
tumours of the, 124
Richards's method of extirpation of the labyrinth, 453
Ring-knife, Delstanche's, for removal of the malleus, 378
Rheumatism, indication for surgical treatment of seminal vesicles, 52
Rhinoliths, removal of, 626
Rhinotomy, combined lateral and sublabial, 666
lateral, Moure's operation, 659
sublabial, Rouge's operation for, 663
Robinson's muscle implantation for chronic empyema, 150
operation for post-syphilitic affec-

tions of the naso-pharynx, 635
Rodman's exploration of neck in growths of the breast, 88
Roentgenograms, stereoscopic, use of, in locating lung abscess, 158
Röentgen rays, *see* X-rays
Rogers's (Leonard) treatment by ipecacuanha of dysenteric hepatitis, 191
Rose's hanging head position, 703
Rotation test of labyrinth, 444
Rotter's investigations concerning dissemination in breast cancer, 67
Rouge's operation (sublabial rhinotomy), 663
Rouge's and Moure's operations, combination of, for nasal growths, 666
operation, extension of, to allow of access to the maxillary antrum, 666

Sac, lacrimal, excision of the, 318
St. Clair Thomson's adenoid curette (modification), 709
method in operations for septal deformities, 648
Sappey, subareolar plexus of, 63
Sarcoma of the breast, age in relation to, 116
clinical symptoms of, 116
etiology of, 116
traumatism in relation to, 116
of the chest-wall, operation for, 125
treatment of mammary, 117
of the mediastinum, removal of, 170
trachea, cut showing, 586
Sauerbruch's chamber, 129, 130
Saw, nasal, Cresswell Barber's, 637
Scar, cystoid, after iridectomy for glaucoma, 204
Lagrange's operation for the production of, in chronic glaucoma, cut showing, 253
Scarring, diagnosis of, from carcinoma of the breast, 109
Schede thoracoplasty for chronic empyema, 150
Schimmelbusch's tube, in laryngeal stenosis, 579
Schleich's method of subcutaneous injection for aural operations (modified), 334
Schmidt's (Moritz) maxillary sinus needle, 668
Schwartze's mastoid operation, 403
method for removal of malleus and incus, 375
seeker, 409
tenotomy knife, 371
Schwartze-Stacke mastoid operation, 418
Scirrhus of the breast, 101
Scissors, Asch's cutting, for septal operations, 640
aural, 348
iris, 215
nasal, 628
ophthalmic, testing of, 202
Sclera, operations upon the, 249
trephining the, 250
Elliott-Fergus operation, 250
Sclerectomy, 250
anterior, 249
complications, 252
in glaucoma, 239
posterior, 254
Scoop, aural, Imray's, 349
Scraping calcareous films of the cornea, 267
Scrotum and cord, operations upon the, 30
Search-light, frontal, for nasal operations, 611
Secondary cataract, operation for, 211
glaucoma, iridectomy for, 240
Seeker, aural, Schwartze's, 409
Semicircular ducts, circumscribed lesion of, operation for, 448
removal of the, 451, 453
Seminal vesicles, operations upon the, 51
Semon's thyrotomy operations, 543
Sepsis after nasal operations, 618
organisms causing, after ophthalmic operations, 199
Septum, nasal, *see* Nasal septum
perforating the, 638
Sequestrotomy, nasal, 634
Sequestrum, syphilitic, nasal, removal of, 634
Serous pleural effusions, operations for, 136
Sex, influence of, in the etiology of malignant disease of the breast, 101
Sexton's instrument for removal of

foreign bodies from the ear, 369
Sexual powers, affected by operations upon the vesicles, 55
Shaw's method of exploratory incision of the breast, 112
Shock due to operation for carcinoma of the breast, 84
in nasal operations, 617
Sideroscopes, use of, in ophthalmic operations, 260
Siebenmann's skin-grafting after mastoid operation, 401
Siegle's aural speculum, 369
Silk thread drains for the establishment of new lymph paths, in detachment of the retina, 257
in glaucoma, 256
in œdema of the eyelids, 255
Sinus, frontal, *see* Frontal sinus
sphenoidal, *see* Sphenoidal sinus
transverse, *see* Transverse sinus
suppuration, multiple, operation in, 700
Sinus, maxillary, *see* Maxillary sinus
Sinuses, nasal, accessory, operations upon the, 667
of the breast, persistent, after puerperal mastitis, operations for, 100
Siphon arrangement for withdrawal of fluid from the pleural cavity, 137
Skiagram of normal bronchial tree, 599
the sphenoidal sinus, 695, 696, 699
showing angular tracheotomy tube in trachea, 557
tumour of the larynx, 514
stereoscopic, in localizing foreign bodies in the lung, 163
Skiagraphy, value of, in frontal sinus operations, 680
laryngeal tumours, shown by Harmar, 514
Skin and muscle operation for entropion, 299
area excised in operation upon the breast, 65, 69, 83, 91
dimpling of the, in carcinoma of breast, 104, 105, 106
disinfection of, preparatory to operation for mammary carcinoma, 68, 69
excision of, in circumcision, 17
Skin flaps, post-meatal, formation of, in mastoid operation, 426
Skin-grafting after mastoid operation, 401, 430
for ectropion, 309
in the restoration of a contracted eye-socket, 285
Skin, orange-rind, in carcinoma of the breast, 105, 108
Skull, auditory region of the, topography of, cut showing, 500
Smith's operation for extraction of cataract in its capsule, 224
Snare, for removal of aural polypus, 355
Wilde's, for removal of aural polypus, 356
nasal, 654
Snellen's suture operation for passive ectropion, 304
Socket-eye, contracted, operations for the restoration of, 285
upon the, after removal of the eye, 284
Soft palate, division of the, for removal of naso-pharyngeal growths, 704
Sounding the sphenoidal sinus, 694
Specula, aural, 330
Spatulæ tube, for laryngoscopy, 518, 519
Speculum, aural, Gruber's, 330
Siegle's, 369
eye, 209
Hayes's electric for examination of the auditory tube, 388
Lang's eye, 200
nasal, Killian's, 698
Yankauer's, for examination of the naso-pharynx, 388
Spencer's operation for post-syphilitic affections of the nose, 635
Sphenoidal punch-forceps, 700
sinus, catheterizing the, 695
opening the, 697
after-treatment of, 698
operations upon the, 694
radiograph of the, 695, 696
showing probe in the, 699
sounding and washing out the, 694
surgical anatomy of, 694
Splint, Lake's rubber, for septal operations, 640
nasal, Meyer's hollow vulcanite, 622

Spokeshave, nasal, 631
Sponge-holder for bronchoscopy, 602
Spoon, Pagenstecher's, 215
Spurs, nasal, removal of, 637
Squier's method in vasotomy, 53
Squint operations, 198, 271
Stacke's aural protector, 419
mastoid operation, 423
post-meatal flaps, in mastoid operation, 429
Stapedius, tenotomy of the, 371
Stapes, massage of the, 374
removal of the, 385
Statistics of operation for breast cancer, 87, 89
Stenosis after tracheotomy, 577
laryngeal, thyrotomy for, 525, 532
of external auditory meatus, operations for, 352
Sterility, cure of, by vaso-epididymotomy, 56
Sterilization of the eye, methods of, preparatory to operation, 200
instruments, preparatory to ophthalmic operations, 201
cocaine for ophthalmic operations, 201
surgeon's hands, preparatory to ophthalmic operations, 201
Sternum, caries of the, 123, 124
tumours of the, 124
Stewart's tracheotomy tube, 566
Stiles's method of operation in carcinoma of the breast, 69
Störk's tube, use of, in laryngeal stenosis, 579
'Stopper,' aural, Ballance's, 432
Streatfeild's operation for entropion, 300
Styles, the insertion of, for relief of lacrimal obstruction, 317
Subdiaphragmatic abscess, operation for, 185
Sublabial rhinotomy, Rouge's operation, 663
Submucous injection of cocaine for nasal operations, 612
resection of the nasal septum, 641
Subperiosteal mastoid abscess, operations for, 414
Superior rectus, grafting a portion of the, into the eyelid, 297
Suppuration in frontal sinus, operation for, 683
multiple sinus, operation for, 700
Supraclavicular glands, enlargement of, in breast cancer, 87, 90, 107, 113, 114
glands, removal of, in breast cancer, 113
Surface anatomy of the mastoid area, 400
Surgical anatomy of the breast, 61
anatomy of the eyelids, 287
crystalline lens, 206
eye, anterior segment of the, cut showing, 207
eyelids, 287
labyrinth, 449
laryngeal lymphatics, 534
larynx and trachea, cut showing 563
mastoid area, 398
tympanic antrum, 398
mastoid cells, 399
mastoid process, 398
middle ear, 398
sphenoidal sinus, 694
tympanum, 359
and pathological anatomy of the eye in glaucoma, 238
emphysema, operations for, 121
toilet of the ear, 333
Sutures, Snellen's, in operation for passive ectropion, 304
of wounds of the eyelids, 287
Swallowing after total laryngectomy, 548
Symblepharon, operation for, 288
Synechiæ, anterior, division of, 248
Syphilis, nasal, operations for results of, 634
of testis, castration in, 49
Syringe, lacrimal, 316
Milligan's intratympanic, 332
Neumann's, aural, 335
Syringing the ear, for removal of foreign bodies, 346
technique of, 332
lacrimal duct, 316
out of the attic, 332

Table showing mortality after tracheotomy in diphtheria, 556, 582
tracheotomy, showing size of trachea and of tube required at different ages, 567
Tables showing comparative results of intubation and tracheotomy, 589, 590

Tagliacotian method for flap transplantation, in ectropion, 311
Tapping in the treatment of serous effusions, 138
Tarsal cartilage, division of, for entropion, 300
Tarsal cysts, removal of, 270
Tarsorrhaphy, 290
Tarsus, division of the, from anterior surface of the lid, 300
conjunctival surface of the lid, 300
faulty curvature of the, rectification of, 300
Tattooing the cornea, 267
Teeth, examination of, preliminary to operations upon the eye, 195
Temporo-sphenoidal abscess, opening of, 501
Tenotomy, 272
complications of, 274
knife, Schwartze's, 371
of the extra-ocular muscles, 272
stapedius, 371
tensor tympani, 370
Tensor tympani, tenotomy of the, 370
Test, alkalinity, in meningitis of otitic origin, 465
blood-pressure, in meningitis of otitic origin, 466
Kopetzky's in meningitis of otitic origin, 465
Testicle, frame, 41
operations upon the, 38
Testis, misplaced, castration in, 48
misplaced or retained, treatment, operative, indications for, 38
tuberculosis of, indication for epididymectomy, 45, 46
undescended, and congenital hernia, association of, 45
treatment, operative, 38
statistics of, 40
new growths of, castration for, 48
syphilis of, castration in, 49
tuberculosis of, castration in, 48
Theatre, ophthalmic, operating, 196, 198
Thiersch's skin-grafting for ectropion, 311
Thomson's (St. Clair) adenoid curette (modification), 709
method in operations for septal deformities, 648
Thomas-Meyer incision, in breast operations, 93
Thoracic walls and mediastinum, operations upon the, 121
abscess, 126
injuries, 121
surgical emphysema, 121
tumours, 124
Thoracoplasty, 147
Thoracotomy, indications for, 135
methods used in, 127
Thorax, bony walls of the, operations for caries and necrosis of the, 122
dermoid cysts of the, 167
hydatid disease of the, operation for, 167
tumours of the, removal of, 124.
Thorner's forceps for intubation of the larynx, 592
Thrombosis, in relation to operative treatment for varicocele, 33
of the lateral sinus, *see* Lateral sinus thrombosis
transverse sinus, *see* Transverse sinus thrombosis
Thyrotomy, 525, 542
after-treatment of, 532
Butlin's after-treatment in, 532
complications in, 532
cures after, 543
foreign bodies in the larynx, 526
laryngeal tubercle, 526
malignant tumours, 525
stenosis, 525
indications for, 525
mortality after, 542
recurrence after, 543
technique of, 527
Tilley's operation for post-syphilitic adhesions of the velum, 635
Tinnitus, relief of, by operation upon the labyrinth, 447
Tod's graduated Eustachian bougie, 394
post-meatal flaps, in mastoid operation, 427
Tongue-clip, use of, in nasal operations, 658
Total laryngectomy, *see* Laryngectomy, total
Trachea, anatomy of the, surgical, 562
aneurysm of the aorta perforating the, 581
operations upon the, 556
resection of the, 585
sarcoma of the, cut showing, 586
showing ulceration due to badly-fitting tube, 576

Trachea, ulceration into the innominate artery after tracheotomy, 580
Tracheo-fissure, 585
Tracheoscopy and bronchoscopy, 598
operation for, 600
indications for, 598
Tracheotomy, 556
accidents during, 571
after-treatment of, 573
complications of, 575
diphtheria, mortality table of, 582
for the cure of laryngeal papillomata, 522
high, 569
in conditions other than diphtheria, 583
indications for, 556
intubation versus in diphtheria, 588
in diphtheria, 556, 565
anæsthesia for, 565
mortality tabulated, 556
prognosis of, 582
low, 571
median, 571
preliminary to operations upon the upper air-passages, 562
stenosis after, 577
triangle, 549, 562
tubes for, 566
tube, skiagram showing use of, 557
tubes, sizes of, at different ages, 567
ulceration into the innominate artery after, 580
Tracheo-fissure, 586
and resection of the trachea, indications for, 585
Transfixion of the iris, 247
Transplantation of the lash-bearing area, 302
Transverse sinus thrombosis, exposure of sinus, 477
operations for, ligature of jugular vein, 482
opening of sinus, 478
operations for, opening of sinus, 478
operations for, 474
complications following, 494
Grunert's, 491
Pifft's, 491
difficulties and dangers of the, 494
comparison of, 494
Transverse sinus thrombosis, prognosis of, 494
exposure of jugular bulb, 490
points of primary infection, 479
Traumatism, influence of, in the etiology of malignant disease of the breast, 101
in relation to sarcoma of the breast, 116
Trendelenburg's operation for removal of clots from the pulmonary artery, 181
Trephine, Elliott's, 250
Trephining for cerebellar abscess, 500
temporo-sphenoidal abscess, 500
the sclera, Elliott-Fergus operation, 250
Triangle, tracheotomy, 549, 562
Trichiasis, operation for, 299, 302
Trocar, Krause's, for nasal operations, 623
Trochar, aspirator, 127, 128
exploring, 127, 128
'Tubage,' 588
Tube and introducer, Butlin's, for laryngotomy, 550
empyema, Bilton Pollard's, 144
flanged, 144
Eustachian, *see* Eustachian tube
tracheotomy, removal of, 574
skiagram showing use of, 557
Tube-spatulæ, Bruenings's for laryngoscopy, 518
Killian's, 518
Tubes for intubation of the larynx, 592
changing the, 596
use of, in the treatment of laryngeal stenosis, 579
for upper bronchoscopy, 600
phonation, modified von Bruns's, 547
for tracheotomy, 566
Tubercle, diagnosis of, from carcinoma of the breast, 108
laryngeal, thyrotomy for, 526
Tuberculin, in the treatment of tuberculous testis, 45
in tuberculosis of seminal tract, 52
Tuberculosis, extirpation of the lung in, 163
in relation to empyema, 146, 156
of the larynx, operation for, 514, 518
nasal, operations for, 636
of seminal tract, treatment, operative, 52

Tuberculosis of testis, indication for epdidymectomy, 45, 46
castration for, 48
Tuberculous abscess of the lung, operation for, 162
'Tumbler,' in cataract operation, 224
Tumours, endolaryngeal, 513
involving the cornea, removal of, 267
laryngeal, operations for, 515
varieties of, 513
thyrotomy for, 525
of the chest-wall, removal of, 124
lung, removal of, 169
mediastinum, removal of, 170
ribs, 124
sternum. 124
Tunica vaginalis, excision of, for cure of hydrocele, cut showing, 32
hæmatocele of, castration in, 49
Turbinals, operations upon the, 626
Turbinotomy, 626
complete, 631
Tympanic antrum, opening the, 407
surgical anatomy of, 398
cavity, lavage of the, 396
operations within the, 359
surgical anatomy of the, 359
fold, posterior, division of the, 365
granulations, curetting of, 372
ligament, anterior, division of the, 365
membrane, anterior ligament of the, division of the, 365
artificial perforation of the, 364
free edge of, incision through, 368
operations upon the, 360
paracentesis of the, 360
posterior fold of the, division of the, 365
preservation of the, after mastoid operation, 424
surgical anatomy of the, 359
Tympanum, *see* Tympanic cavity
granulations of the, removal of, 372
lavage of the, 396
surgical anatomy of the, 359
Tyrrell's hook, use of, in iridotomy, 232, 233
in optical iridectomy, 237

Ulcerated growths of the breast, local treatment of, 116
Ulceration, tracheal, due to badly fitting tube, 576
in carcinoma of the breast, treatment, local, 116
in carcinoma of the breast, 105, 107
Ulcer of the cornea, cauterization of, 264
Undine for cleansing conjunctival sac, 201
Unusual forms of breast cancer, 109
Upper bronchoscopy, 602
Urea hydrochloride, use of, in aural operations, 336
Urethra, defects in, 3, 4
new, formation of, in the glans penis, 4
penile, repairing by means of the prepuce, 5
anterior, restoration of, in adults, 7
new penile, formation of, 8
Urine, examination of, preliminary to operations upon the eye, 195

Vaccine, use of, in panophthalmitis, 228
use of, preparatory to ophthalmic operations, 199
Varicocele, operations for, 33
Vas deferens, operations upon the, 35
Vasectomy, 35
Vaso-epididymotomy, 56
Vasorrhaphy, 35
Vasotomy, 52
Vectis, 215
Vein, jugular, *see* Jugular vein
Velum, post-syphilitic adhesions of the, operations for, 635
Vertigo, aural, intracranial division of the acoustic nerve for, 458
relief of, by operation upon the labyrinth, 447
Vesicles, seminal, inflammation of, treatment, operative, 51
palliative, 51
affections of, surgical indications in, 52
Vesiculectomy, 52
Vesiculitis, chronic, indication for surgical treatment of seminal vesicles, 52
Vesiculotomy, 52

Vesiculotomy in relation to chronic joint involvement, 52
Vessels, great, wounds of the, 121
Vestibule, opening the, 451
Vestibulotomy, 451
comparisons of the various methods, 456
double, 453
inferior, 452
superior, 451
Vestibule, opening the, 451
Villeneuve's method in seminal vesiculectomy, 55
Viscera, infection of, in malignant disease of the breast, 103, 105
Vision, defective, a complication of lens extraction, 230
'red,' a complication of lens extraction, 230
Vitreous, loss of, a complication of lens extraction, 227
sclerectomy, 252
Voelcker's method in vasotomy, 54
Voice after total laryngectomy, 546
Von Bruns's phonation tube, modified, 547
V-Y operation for ectropion, 308

Walsham's skiagraphs of laryngeal tumours, 514
Warfare, influence of, in thoracic surgery, 164
Warty growths in the penis, indication for partial operation, 21
Warren's method in breast operations, 82, 95, 96
Watson Cheyne's statistics of operation for breast cancer, 89
West and Scott's method for vestibulotomy, 451
Wharton Jones's operation for ectropion, 308
Whooping-cough, exciting cause of bronchiectasis, 160
Wilde's aural snare, 356
post-aural incision, 402
Williams's (Watson) handle for bronchoscope, 601
Window operation for septal deformities, 641
Wolf's complete mastoid operation, 422
method of skin-grafting for ectropion, 311
Wounds of the eyelids, suture of, 287
globe of the eye, operations for, 201, 259
great vessels, treatment of, 121
heart, repair of, 171
lung, treatment, 121
pericardium, repair of, 171

X-rays in treatment of carcinoma of the breast, 114
laryngeal tumours, 514
value of, in frontal sinus, operations, 680
X-rays, *see also* Radiograph and Skiagram

Yankauer's speculum for examination of the naso-pharynx, 388
Young's method in seminal vesiculectomy, 55

Zeroni's incus hook, 380
Ziegler's iridotomy operation, 234
Zinc chloride lotion in post-operative treatment of empyema, 149
Zorab's silk drain in glaucoma, 256